
NEUROLOGY AND NEUROSURGERY ILLUSTRATED

Kenneth W. Lindsay PhD FRCS

Consultant Neurosurgeon, Institute of Neurological Sciences;
Honorary Clinical Lecturer, University of Glasgow, UK
Formerly Consultant Neurosurgeon, Royal Free Hospital, London;
Honorary Senior Lecturer, Royal Free Hospital School of Medicine, University of London, UK

Ian Bone MRCP(UK) FRCP(G)

Consultant Neurologist, Institute of Neurological Sciences;
Honorary Clinical Professor, University of Glasgow, UK

Illustrated by

Robin Callander FFPh FMAA AIMBI

Medical Illustrator, Formerly Director of Medical Illustration, University of Glasgow, UK

Foreword by

J. van Gijn MD FRCPE

Professor and Chairman,
University Department of Neurology,
Utrecht,
The Netherlands

THIRD EDITION



**CHURCHILL
LIVINGSTONE**

EDINBURGH LONDON PHILADELPHIA TORONTO SYDNEY AND TOKYO 1997

CONTENTS

SECTION I

General Approach to History and Examination

General Approach to History and Examination	1-31
Nervous system – history and examination	2-4
Conscious level assessment	5
Higher cerebral function	7-8
Cranial nerve examination	9-18
– upper limbs	19-23
– trunk	24
– lower limbs	25-27
– posture and gait	28
Examination of the unconscious patient	29-30
The neurological observation chart	31

SECTION II

Investigations of the Central and Peripheral Nervous Systems

Investigations of the Central and Peripheral Nervous Systems	33-62
Skull X-ray	34
Computerised tomography (CT) scanning	35-38
Magnetic resonance imaging (MRI)	39-41
Ultrasound	42
Angiography	43-45
Radionuclide imaging	46-48
Electroencephalography (EEG)	49
Intracranial pressure monitoring	50-51
Evoked potentials	52-53
Lumbar puncture	54
Cerebrospinal fluid	55
Electromyography/nerve conduction studies	56-59
Neuro-otological tests	60-62

SECTION III

Clinical presentation, anatomical concepts and diagnostic approach

Clinical presentation, anatomical concepts and diagnostic approach	63-212
Headache	64-70
Meningism	71
Raised intracranial pressure	72-80
Coma and impaired conscious level	81-85

Transient loss of consciousness	86
Confusional states and delirium	87
Epilepsy	88-101
Disorders of sleep	102-104
Higher cortical dysfunction	105-114
Disorders of memory	115
Disorders of speech and language	116-120
Dementias	121-128
Impairment of vision	129-136
Disorders of smell	137
Pupillary disorders	138-142
Diplopia – impaired ocular movement	143-150
Disorders of gaze	151-153
Facial pain and sensory loss	154-165
Bells palsy	166
Other facial nerve disorders	167
Deafness, tinnitus and vertigo	168-170
Disorders of the lower cranial nerves	171-174
Causes of lower cranial nerve palsies	175
Cerebellar dysfunction	176-179
Nystagmus	180-183
Tremor	184-185
Myoclonus	186
Disorders of stance and gait	187
Specific disorders of stance and gait	188
Limb weakness	189-194
Sensory impairment	195-199
Pain	200-205
Limb pain	206-207
Muscle pain (myalgia)	208-209
Outcome after brain damage	210
Brain death	211-212

SECTION IV

Localised neurological disease and its management

Localised neurological disease and its management	213-468
A. Intracranial	
Head injury	214-233
Chronic subdural haematoma	234-235
Cerebrovascular disease	236-238
Occlusive and stenotic cerebrovascular disease	239

CONTENTS

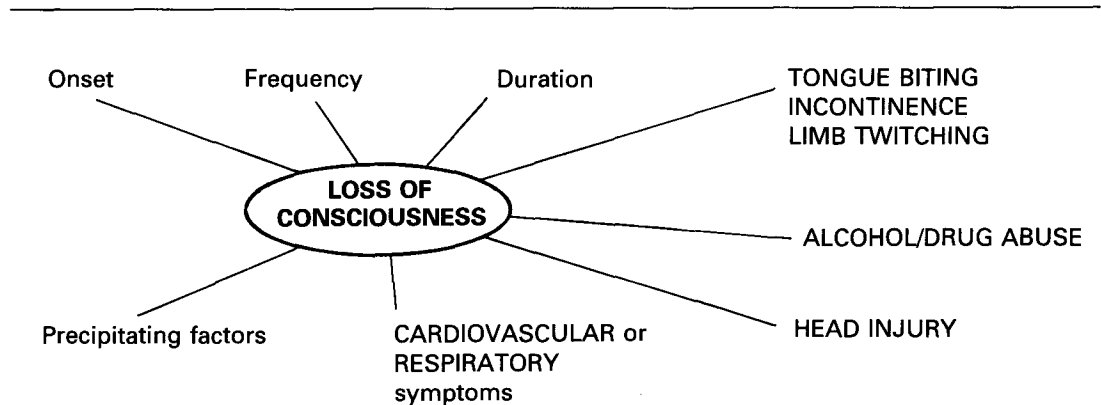
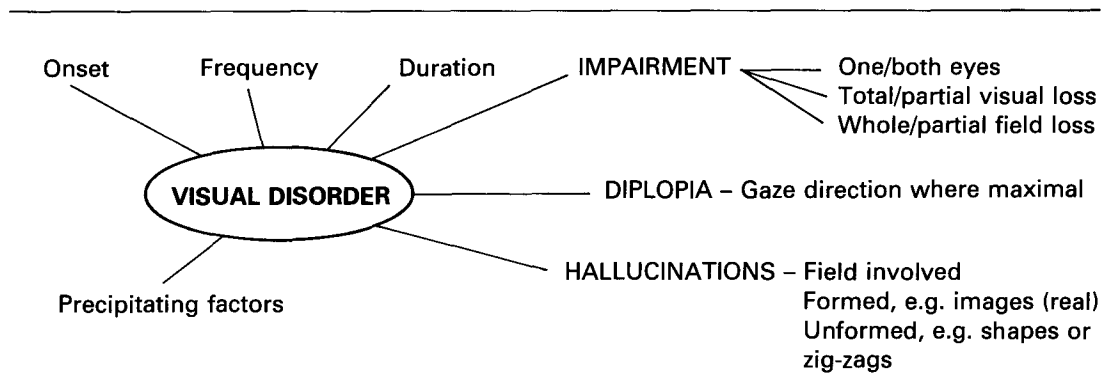
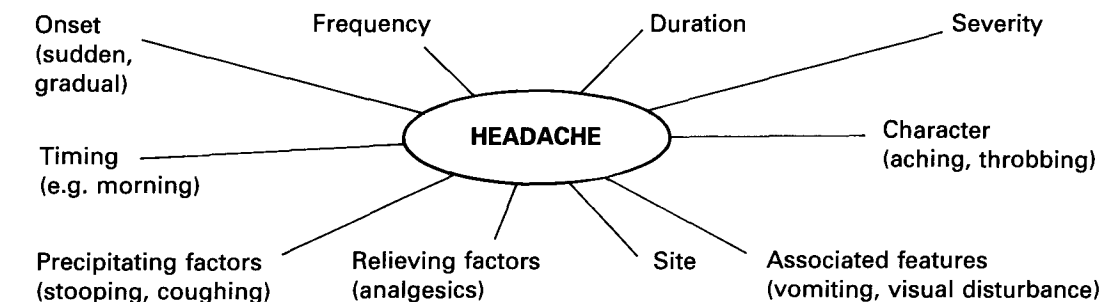
Inflammatory myopathy	456–458	Multiple sclerosis	500–508
Endocrine/metabolic myopathies	459	Other demyelinating diseases	509–511
Metabolic myopathies	460–461	Neurological complications of drugs and toxins	512
Mitochondrial disorders	462	Drug-induced neurological syndromes	513
Myasthenia gravis	463–468	Specific syndromes of drugs and toxins	514–515
SECTION V		Metabolic encephalopathies	516
Multifocal neurological disease and its management		Classification and biochemical evaluation	517
Bacterial infections – meningitis	470	Specific encephalopathies	517–520
Acute bacterial meningitis	471–473	Nutritional disorders	521
Bacterial infections – CNS tuberculosis	474	Wernicke Korsakoff syndrome	522
Tuberculous meningitis	475–476	Subacute combined degeneration of the spinal cord	523–524
Other forms of CNS tuberculous infection	477	Polyneuropathy	525
Spirochaetal infections of the nervous system	478–482	Toxic and nutritional amblyopia	526
Parasitic infections of the nervous system – protozoa	483	Alcohol related disorders	526–527
Viral infections	484–493	Non-metastatic manifestations of malignant disease	528–529
Opportunistic infections	494	Degenerative disorders	530
Acquired immunodeficiency syndrome (AIDS)	495	Progressive blindness	531
Neurological presentations of HIV infection	496	Progressive ataxia	532–534
Subacute/chronic meningitis	497–498	Motor neuron disease	535–538
Demyelinating diseases – introduction	499	Inherited motor neuron disorders	539
		Neurocutaneous syndromes	540–542
		Further Reading	543
		Index	545

**GENERAL APPROACH TO HISTORY
AND EXAMINATION**

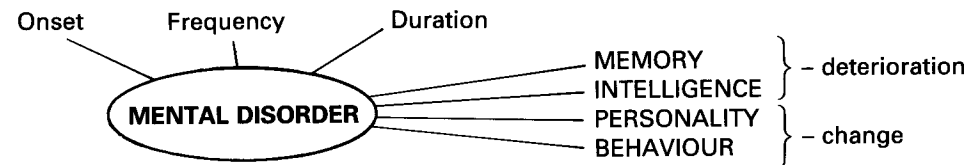
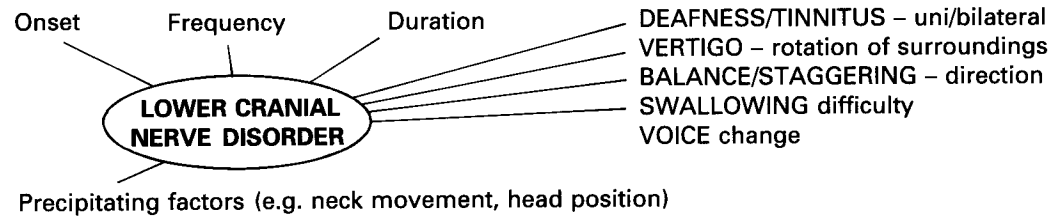

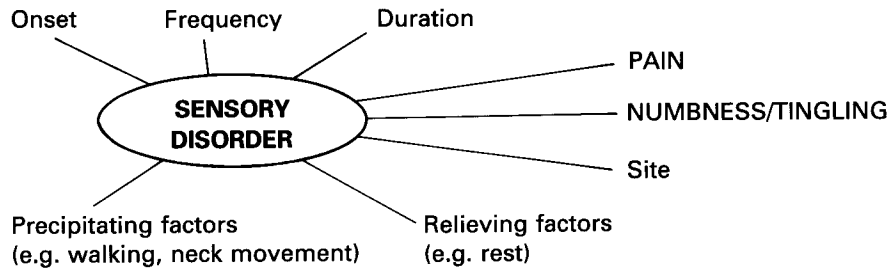
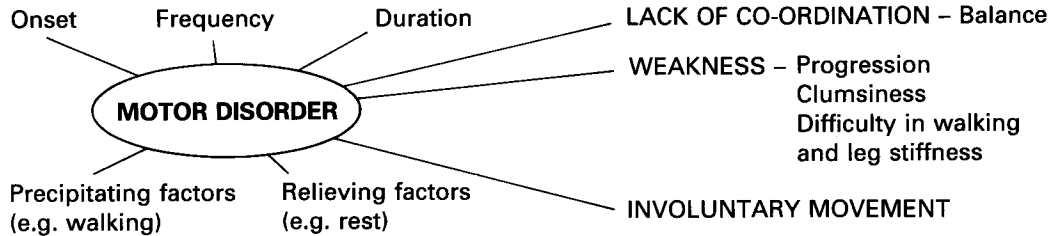
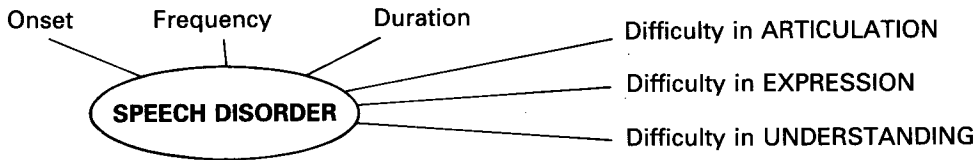
NERVOUS SYSTEM – HISTORY

An accurate description of the patient's neurological symptoms is an important aid in establishing the diagnosis; but this must be taken in conjunction with information from other systems, previous medical history, family and social history and current medication. Often the patient's history requires confirmation from a relative or friend.

The following outline indicates the relevant information to obtain for each symptom, although some may require further clarification.



NERVOUS SYSTEM – HISTORY

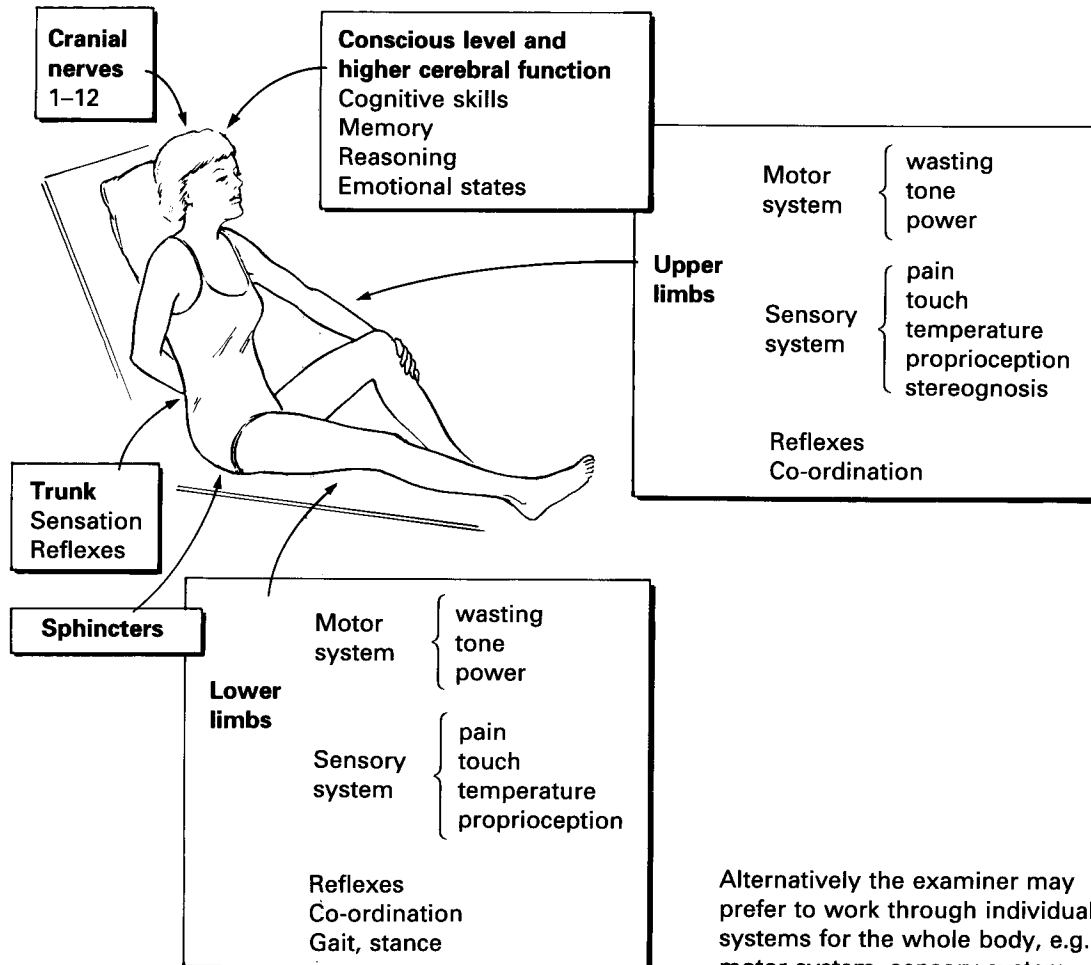


NERVOUS SYSTEM – EXAMINATION

Neurological disease may produce systemic signs and systemic disease may affect the nervous system. A complete general examination must therefore accompany that of the central nervous system. In particular, note the following:

Temperature	Evidence of weight loss	Septic source, e.g. teeth, ears,
Blood pressure	Breast lumps	Skin marks, e.g. rashes
Neck stiffness	Lymphadenopathy	cafe-au-lait spots
Pulse irregularity	Hepatic and splenic	angiomata
Carotid bruit	enlargement	Anterior fontanelle } in baby
Cardiac murmurs	Prostatic irregularity	Head circumference }
Cyanosis/respiratory insufficiency		

CNS examination is described systematically from the head downwards and includes:



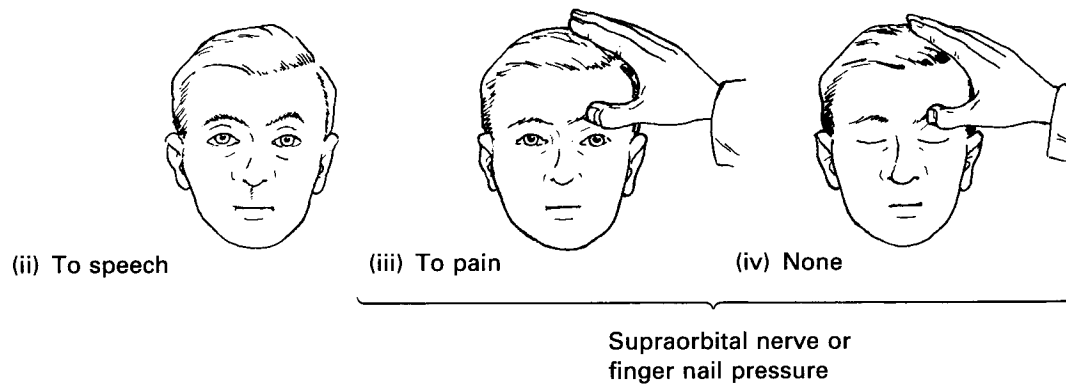
EXAMINATION – CONSCIOUS LEVEL ASSESSMENT

A wide variety of systemic and intracranial problems produce depression of conscious level. Accurate assessment and recording are essential to determine deterioration or improvement in a patient's condition. In 1974 Teasdale and Jennett, in Glasgow, developed a system for conscious level assessment. They discarded vague terms such as stupor, semicoma and deep coma, and described conscious level in terms of EYE opening, VERBAL response and MOTOR response.

The Glasgow coma scale is now used widely in Britain and in many centres throughout the world. Recording is consistent irrespective of the status of the observer and can be carried out just as reliably by nurse as by neurosurgeon.

EYE OPENING – 4 categories

(i) Spontaneous



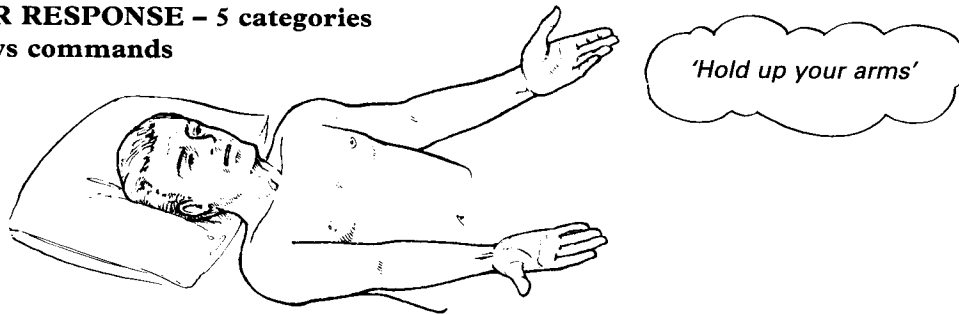
VERBAL RESPONSE - 5 categories

- (i) *Orientated* – Knows place, e.g. Royal Free Hospital and time, e.g. day, month and year
- (ii) *Confused* – Talking in sentences but disorientated in time and place
- (iii) *Words* – Utters occasional words rather than sentences
- (iv) *Sounds* – Groans or grunts, but no words
- (v) *None*

EXAMINATION – CONSCIOUS LEVEL ASSESSMENT

MOTOR RESPONSE – 5 categories

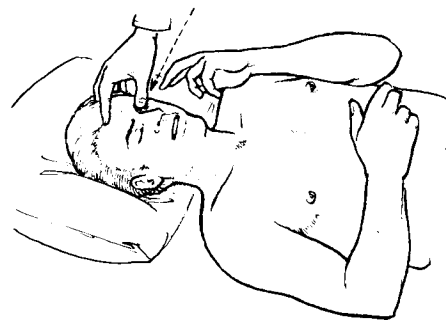
(i) Obeys commands



(ii) Localising to pain

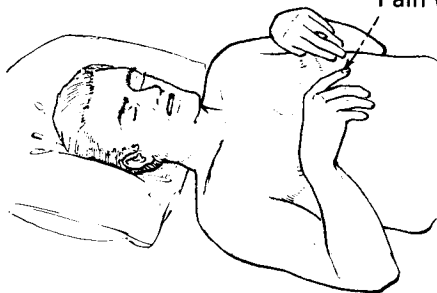Apply a painful stimulus to the supraorbital nerve, e.g. rub thumb nail in the supraorbital groove, increasing pressure until a response is obtained. If the patient responds by bringing the hand up beyond the chin = 'localising to pain'. (Pressure to nail beds or sternum at this stage may not differentiate 'localising' from 'flexing'.)

Pain (Supraorbital pressure)



(iii) Flexing to pain

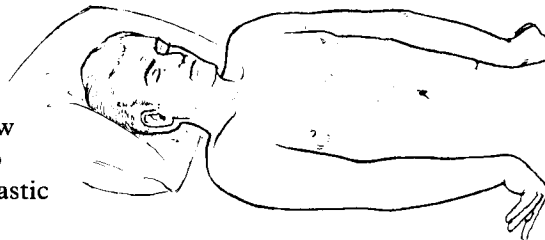
Pain (Nailbed pressure)



If the patient does not localise to supraorbital pressure, apply pressure with a pen or hard object to the nail bed. Record elbow flexion as 'flexing to pain'. Spastic wrist flexion may or may not accompany this response.

(iv) Extending to pain

If in response to the same stimulus elbow extension occurs, record as 'extending to pain'. This is always accompanied by spastic flexion of the wrist.



(v) None

Before recording a patient at this level, ensure that the painful stimulus is adequate.

During examination the motor response may vary. Supraorbital pain may produce an extension response, whereas finger nail pressure produces flexion. Alternatively one arm may localise to pain; the other may flex. When this occurs record the *best* response during the period of examination (this correlates best with final outcome). For the purpose of conscious level assessment use only the *arm* response. Leg response to pain gives less consistent results, often producing movements arising from spinal rather than cerebral origin.

EXAMINATION – HIGHER CEREBRAL FUNCTION

COGNITIVE SKILL

Dominant hemisphere disorders

Listen to language pattern – hesitant – fluent	Expressive dysphasia Receptive dysphasia
Does the patient understand simple/complex spoken commands? e.g. 'Hold up both arms, touch the right ear with the left fifth finger.'	Receptive dysphasia
Ask the patient to name objects.	Nominal dysphasia
Does the patient read correctly?	Dyslexia
Does the patient write correctly?	Dysgraphia
Ask the patient to perform a numerical calculation, e.g. serial 7 test, where 7 is subtracted serially from 100.	Dyscalculia
Can the patient recognise objects? e.g. ask patient to select an object from a group.	Agnosia

Non-dominant hemisphere disorders

Note patient's ability to find his way around the ward or his home.	Geographical agnosia
Can the patient dress himself?	Dressing apraxia
Note the patient's ability to copy a geometric pattern, e.g. ask patient to form a star with matches or copy a drawing of a cube.	Constructional apraxia

Mini mental function tests and Functional activity questionnaire are used in the assessment of DEMENTIA (page 123).

EXAMINATION – HIGHER CEREBRAL FUNCTION

MEMORY TEST

Testing requires alertness and is not possible in a confused or dysphasic patient.

- | | | |
|--------------------|--------------------------------------------------------------------------------------------------|---|
| IMMEDIATE memory – | Digit span – ask patient to repeat a sequence of 5, 6 or 7 random numbers. | } |
| RECENT memory – | Ask patient to describe present illness, duration of hospital stay or recent events in the news. | |
| REMOTE memory – | Ask about events and circumstances occurring more than 5 years previously. | |
| VERBAL memory – | Ask patient to remember a sentence or a short story and test after 15 minutes. | |
| VISUAL memory – | Ask patient to remember objects on a tray and test after 15 minutes. | |

Note: Retrograde amnesia – loss of memory of events leading up to a brain injury or insult.

Post-traumatic amnesia – permanent loss of memory of events for a period following a head injury.

REASONING AND PROBLEM SOLVING

Test patient with two-step calculations, e.g. 'I wish to buy 12 articles at 7 pence each.

How much change will I receive from £1?'

Ask patient to reverse 3 or 4 random numbers.

Ask patient to explain proverbs.

Ask patient to sort cards into suits.

The examiner must compare patient's present reasoning ability with expected abilities based on job history and/or school work.

EMOTIONAL STATE

Note: Anxiety or excitement

Depression or apathy

Emotional behaviour

Uninhibited behaviour

Slowness of movement or responses


Personality type or change.

CRANIAL NERVE EXAMINATION

OLFACTORY NERVE (I)

Test both perception and identification using aromatic non-irritant materials that avoid stimulation of trigeminal nerve fibres in the nasal mucosa, e.g. soap, tobacco.

One nostril is closed while the patient sniffs with the other.

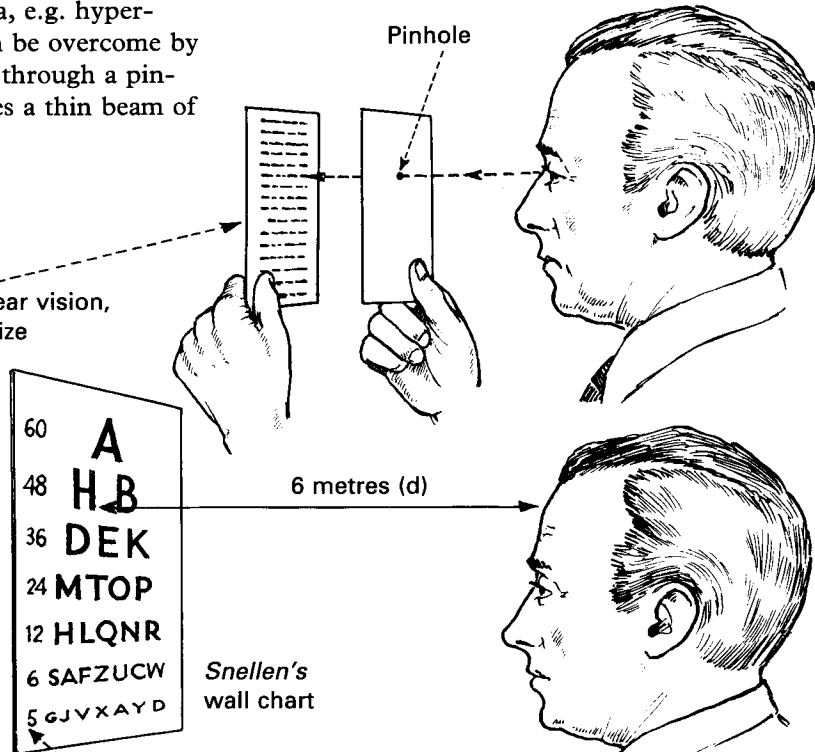


OPTIC NERVE (II)

Visual acuity $\left\{ \begin{array}{l} \textit{severe} \text{ deficit} - \text{ Can patient see } \begin{array}{l} \text{light?} \\ \text{movement?} \end{array} \\ \text{Can patient count fingers?} \\ \textit{mild} \text{ deficit} - \text{ Record reading acuity with wall or hand chart.} \end{array} \right.$

N.B. *Refractive error* (i.e. inadequate focussing on the retina, e.g. hypermetropia, myopia) can be overcome by testing reading acuity through a pinhole. This concentrates a thin beam of vision on the macula.

Jaeger type card for near vision, labelled according to size [N5 (smallest print) - N48 (largest print)].



Visual acuity is expressed as:

$$\frac{d}{D}$$

e.g. $\frac{6}{12}$

Distances (D) at which patient is expected to read letters (metres)

Test each eye separately.

CRANIAL NERVE EXAMINATION

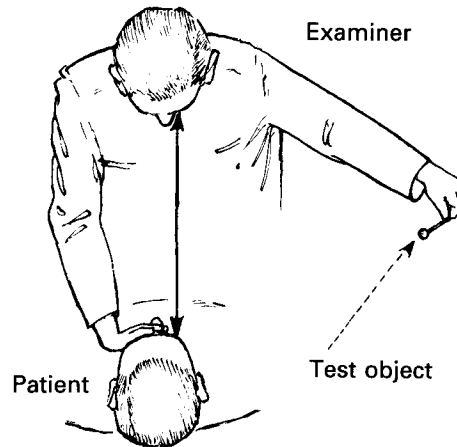
Visual fields

1. Gross testing by CONFRONTATION.

Compare the patient's fields of vision by advancing a moving finger or, more accurately, a red 5 mm pin from the extreme periphery towards the fixation point. This maps out 'cone' vision. A 2 mm pin will define central field defects which may only manifest as a loss of colour perception.

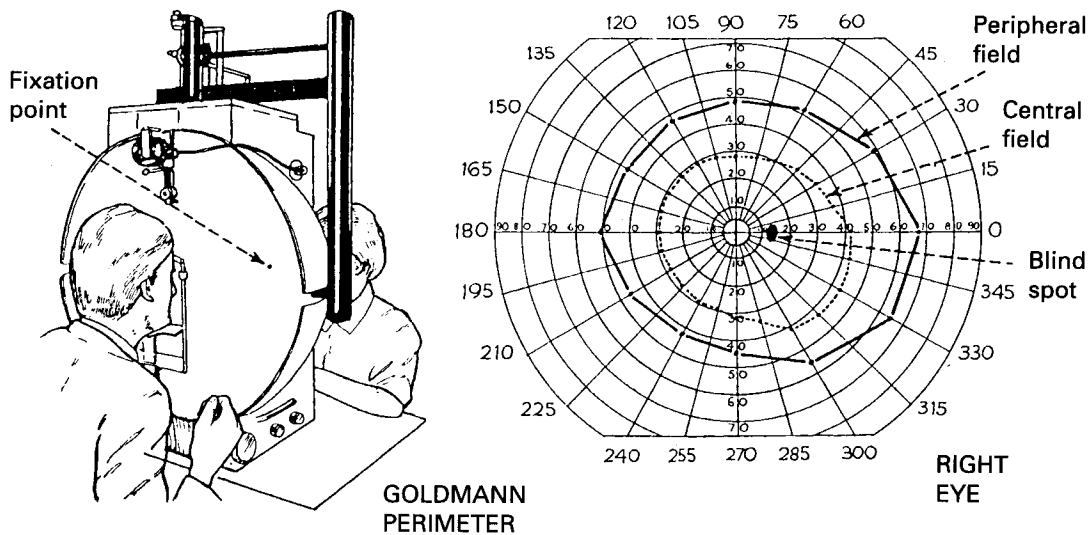
In the temporal portion of the visual field the physiological blind spot may be detected. A 3 mm object should disappear here.

The patient must fixate on the examiner's pupil.



2. *Peripheral visual fields* are more sensitive to a *moving* target and are tested with a GOLDMANN PERIMETER.

The patient fixes on a central point. A point of light is moved centrally from the extreme periphery. The position at which the patient observes the target is marked on a chart. Repeated testing from multiple directions provides an accurate record of visual fields.



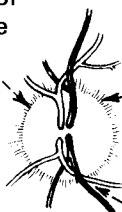3. *Central fields* are charted with either a Goldmann perimeter using a small light source of lesser intensity or a TANGENT (BJERRUM) SCREEN. The HUMPHREY FIELD ANALYSER provides an alternative and particularly sensitive method of testing central fields. This records the *threshold* at which the patient observes a static light source of increasing intensity.

CRANIAL NERVE EXAMINATION

Optic fundus (*Ophthalmoscopy*)

Ask the patient to fixate on a distant object away from any bright light. Use the right eye to examine the patient's right eye and the left eye to examine the patient's left eye.

Note clarity of the disc edge



Adjust the ophthalmoscope lens until the retinal vessels are in focus and trace these back to the *optic disc*

Ask the patient to look at the light of the ophthalmoscope. This brings the *macula* into view

Look for haemorrhages or white patches of exudate

Note width of blood vessels and look for arteriovenous nipping at cross-over points.

If small pupil size prevents fundal examination, then dilate pupil with homatropine. This is contraindicated if either an acute expanding lesion or glaucoma is suspected.

Pupils

Note: Size

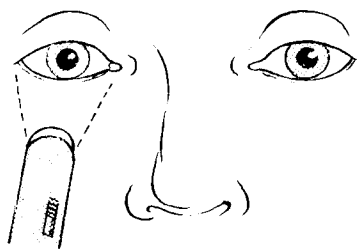
Shape

Equality

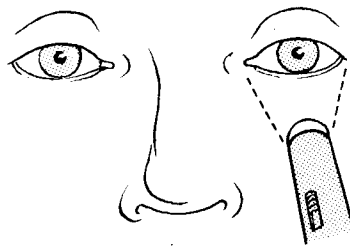
Reaction to light: both pupils constrict when light is shone in either eye

Reaction to accommodation and convergence: pupil constriction occurs when gaze is transferred to a near point object.

A lesion of the *optic nerve* will abolish pupillary response to light on the same side as well as in the contra-lateral eye.



When light is shone in the *normal* eye, it and the contralateral pupil will constrict.



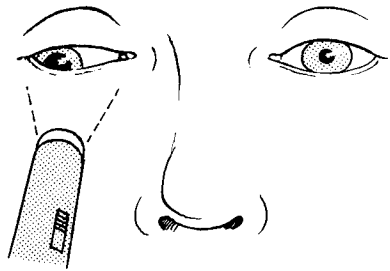
CRANIAL NERVE EXAMINATION

OCULOMOTOR (III), TROCHLEAR (IV) AND ABDUCENS (VI) NERVES

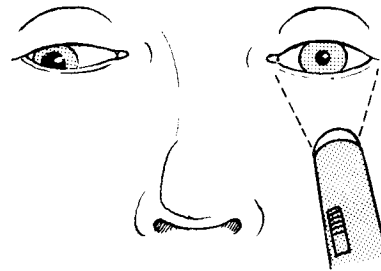
A lesion of the III nerve produces impairment of eye and lid movement as well as disturbance of pupillary response.

Pupil: The pupil dilates and becomes 'fixed' to light.


Shine torch in *affected* eye – contralateral pupil constricts (its III nerve intact). Absent or impaired response in illuminated eye.



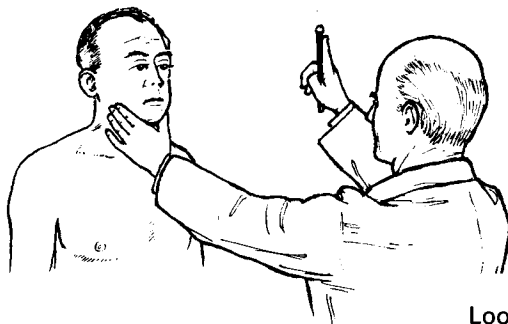
When light is shone into the *normal* eye, only the pupil on that side constricts.



Ptosis: Ptosis is present if the eyelid droops over the pupil when the eyes are fully open. Since the levator palpebrae muscle contains both skeletal and smooth muscle, ptosis signifies either a III nerve palsy or a sympathetic lesion and is more prominent with the former.



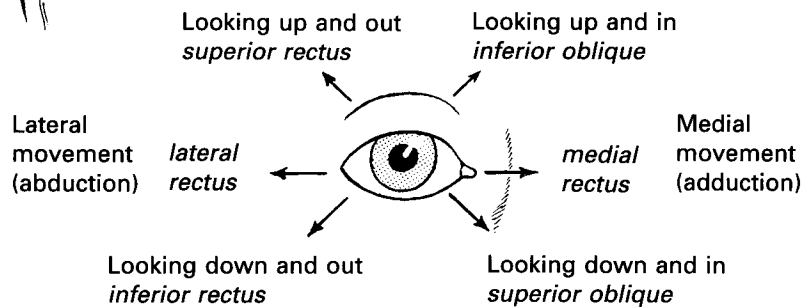
Ocular movement



Steady the patient's head and ask him to follow an object held at arm's length. Observe the full range of horizontal and vertical eye movements.

Note any *malalignment* or *limitation of range*.

Examine eye movements in the six different directions of gaze representing maximal individual muscle strength.

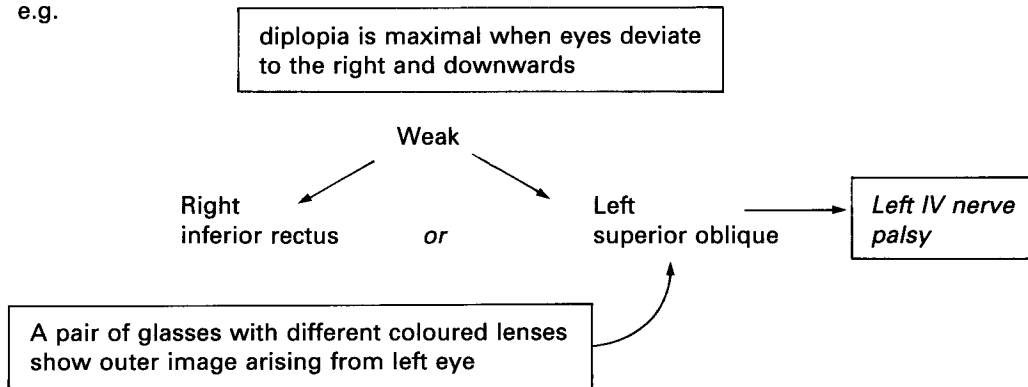


CRANIAL NERVE EXAMINATION

Question patient about *diplopia*; the patient is more likely to notice this before the examiner can detect impairment of eye movement. If present:


- note the *direction of maximum displacement* of the images and determine the pair of muscles involved
- identify the source of the *outer image* (from the defective eye) using a transparent coloured lens.

e.g.



Conjugate movement: Note the ability of the eyes to move together (conjugately) in horizontal or vertical direction or tendency for gaze to fix in one particular direction.

Nystagmus: This is an upset in the normal balance of eye control. A slow drift in one direction is followed by a fast corrective movement. Nystagmus is maximal when the eyes are turned in the direction of the fast phase. Nystagmus 'direction' is usually described in terms of the fast phase and may be horizontal or vertical. Test as for other eye movements, but remember that 'physiological' nystagmus can occur when the eyes deviate to the endpoint of gaze.



e.g. Nystagmus to the left maximal on left lateral gaze.

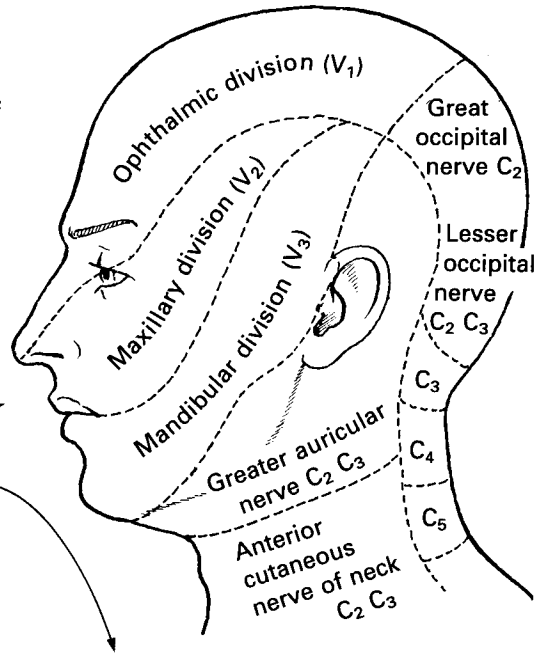
CRANIAL NERVE EXAMINATION

TRIGEMINAL NERVE (V)

Test *pain* (pin prick) sensation } over
temperature (cold object or } whole
 hot/cold tubes } face
light touch

Compare each side.
 Map out the sensory deficit,
 testing from the abnormal
 to the normal region.

Does distribution involve
 - a *root* pattern?
 - or a *brain stem* 'onion skin' pattern?



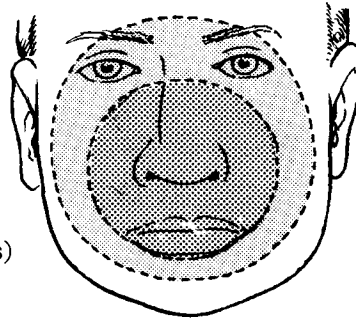
Corneal reflex

Test corneal sensation by touching
 with wisp of wet cotton wool. A blink
 response should occur bilaterally.

Afferent route - ophthalmic division V
 (light touch - main sensory nucleus)

Efferent route - facial nerve VII

This test is the most sensitive indicator
 of trigeminal nerve damage.



Motor examination

Observe for wasting and thinning of temporalis muscle - 'hollowing out' the temporalis fossa.

Ask the patient to clamp jaws together. Feel temporalis and masseter muscles. Attempt to open patient's jaws by applying pressure to chin. Ask patient to open mouth. If pterygoid muscles are weak the jaw will deviate to the weak side, being pushed over by the unopposed pterygoid muscles of the good side.

CRANIAL NERVE EXAMINATION

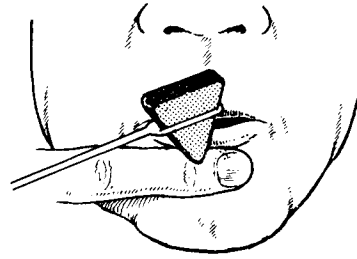
TRIGEMINAL NERVE (V) (contd)

Jaw jerk

Ask patient to relax jaw. Place finger on the chin and tap with hammer:

Slight jerk – normal

Increased jerk – bilateral upper neuron lesion.



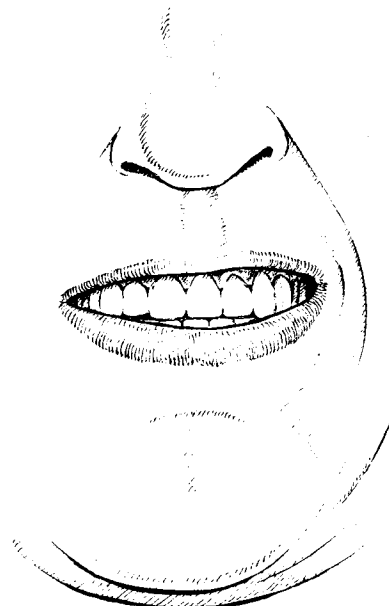
FACIAL NERVE (VII)

Observe patient as he talks and smiles, watching for:

- eye closure
- asymmetrical elevation of one corner of mouth
- flattening of nasolabial fold.

Patient is then instructed to:

- wrinkle forehead (frontalis)
(by looking upwards)
- close eyes while examiner attempts to open them (orbicularis oculi)
- purse lips while examiner presses cheeks (buccinator)
- show teeth (orbicularis oris)



Taste may be tested by using sugar, tartaric acid or sodium chloride. A small quantity of each substance is placed anteriorly on the appropriate side of the protruded tongue.

CRANIAL NERVE EXAMINATION

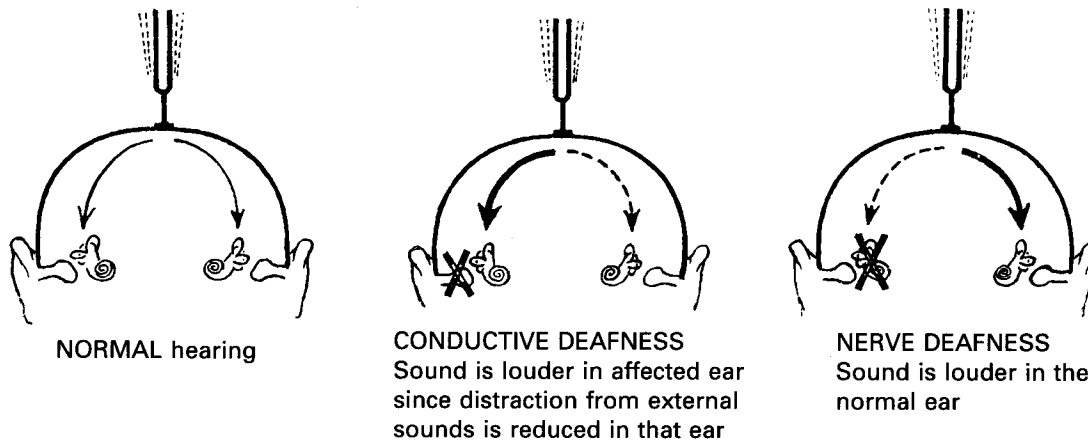
AUDITORY NERVE (VIII)

Cochlear component


Test by whispering numbers into one ear while masking hearing in the other ear by occluding and rubbing the external meatus. If hearing is impaired, examine external meatus and the tympanic membrane with auroscope to exclude wax or infection.

Differentiate conductive (middle ear) deafness from perceptive (nerve) deafness by:

1. **Weber's test:** Hold base of tuning fork (256 or 512 Hz) against the vertex. Ask patient if sound is heard more loudly in one ear.



2. **Rinne's test:** Hold the base of a vibrating tuning fork against the mastoid bone. Ask the patient if note is heard. When note disappears – hold tuning fork near the external meatus. Patient should hear sound again since air conduction via the ossicles is better than bone conduction.



In *conductive deafness*, bone conduction is better than air conduction.
In *nerve deafness*, both bone and air conduction are impaired.

Further auditory testing and examination of the **vestibular component** requires specialised investigation (see pages 60–62).

CRANIAL NERVE EXAMINATION

GLOSSOPHARYNGEAL NERVE (IX): VAGUS NERVE (X)

These nerves are considered jointly since they are examined together and their actions are seldom individually impaired.

Note patient's *voice* – if there is vocal cord paresis (X nerve palsy), voice may be high pitched. (Vocal cord examination is best left to an ENT specialist.)

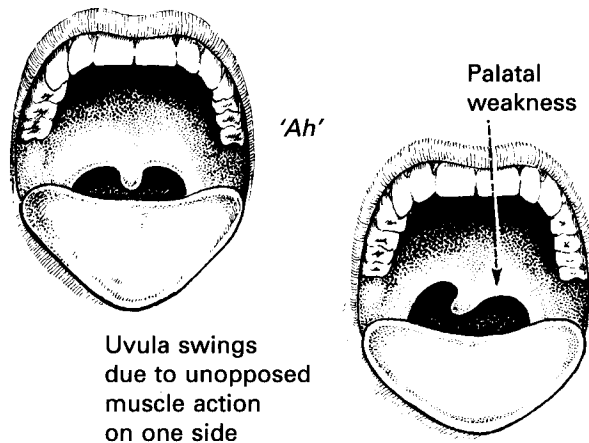
Note any *swallowing* difficulty or nasal regurgitation of fluids.

Ask patient to open mouth and say 'Ah'. Note any *asymmetry* of palatal movements (X nerve palsy).

Gag reflex

Depress patient's tongue and touch palate, pharynx or tonsil on one side until the patient 'gags'. Compare sensitivity on each side (*afferent* route – IX nerve) and observe symmetry of palatal contraction (*efferent* route – X nerve).

Absent gag reflex = loss of sensation and/or loss of motor power. (Taste in the posterior third of the tongue (IX) is impractical to test.)

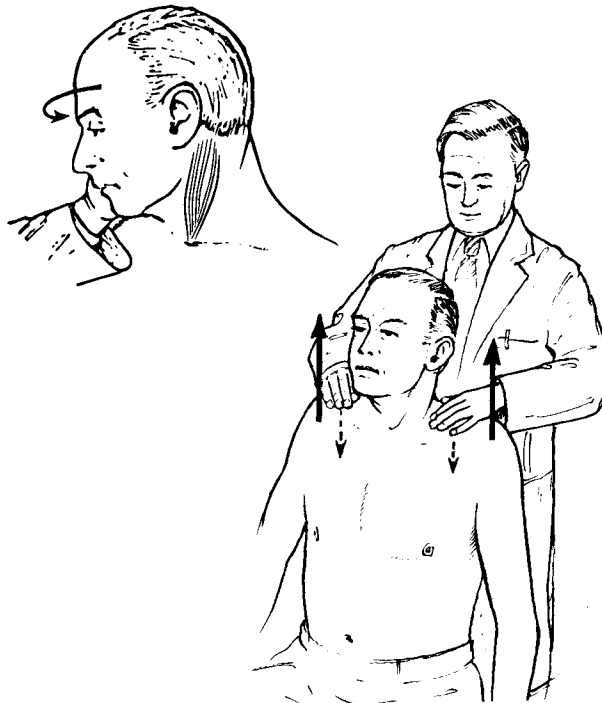


ACCESSORY NERVE (XI)

Sternomastoid

Ask patient to rotate head against resistance. Compare power and muscle bulk on each side. Also compare each side with the patient pulling head forward against resistance.

N.B. The left sternomastoid turns the head to the right and *vice versa*.



Trapezius

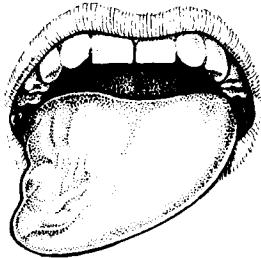Ask patient to 'shrug' shoulders and to hold them in this position against resistance. Compare power on each side. Patient should manage to resist any effort to depress shoulders.

CRANIAL NERVE EXAMINATION

HYPOGLOSSAL NERVE (XII)

Ask patient to open mouth; inspect tongue.

Look for – evidence of atrophy (increased folds, wasting)
– fibrillation (small wriggling movements).



Ask patient to protrude tongue. Note any difficulty or deviation. (N.B. apparent deviation may occur with facial weakness – if present, assess tongue in relation to teeth.)

Protruded tongue deviates towards side of weakness.

Non protruded tongue cannot move to the opposite side.

Dysarthria and dysphagia are minimal.

EXAMINATION – UPPER LIMBS

MOTOR SYSTEM

Appearance

- Note: – any *asymmetry* or *deformity*
- muscle *wasting* } If in doubt, measure circumference at fixed distance
 - muscle *hypertrophy* } above/below joint. Note muscle group involved.
 - muscle *fasciculation* – irregular, non-rhythmical contraction of groups of motor units, increased after exercise and on tapping muscle surface.
- N.B. Fasciculation may occur in normal individuals, particularly in the orbicularis oculi. Distinguish from 'fibrillation', which is excessive activity of a single motor unit and is only detectable with electromyography except in the tongue.

Tone

Ensure that the patient is relaxed, and assess tone by alternately flexing and extending the elbow or wrist.

Note: – decrease in tone

- increase in tone {
 - 'Clasp-knife': the initial resistance to the movement is suddenly overcome (upper motor neuron lesion).
 - 'Lead-pipe': a steady increase in resistance throughout the movement (extrapyramidal lesion).
 - 'Cog-wheel': ratchet-like increase in resistance (extrapyramidal lesion).

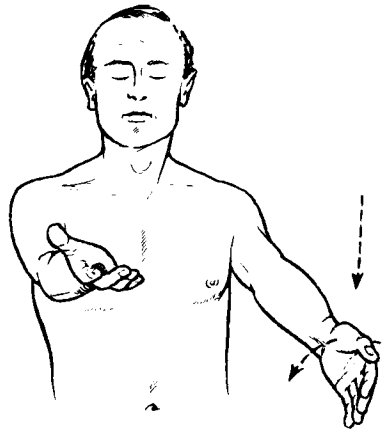
Power

If a pyramidal weakness is suspected (i.e. a weakness arising from damage to the motor cortex or descending motor tracts (see pages 189–193) the following test is simple, quick, yet sensitive.

Ask the patient to hold arms outstretched with the hands supinated for up to one minute. The eyes are closed (otherwise visual compensation occurs). The weak arm gradually pronates and drifts downwards.

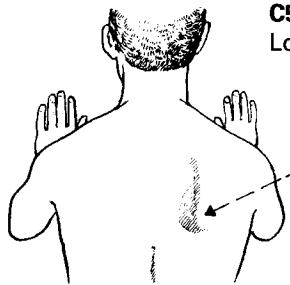
With possible involvement at the spinal root or nerve level (lower motor neuron), it is essential to test individual muscle groups to help localise the lesion.

When testing muscle groups, think of *root* supply and *nerve* supply.



EXAMINATION – UPPER LIMBS

Test for *Serratus anterior*:

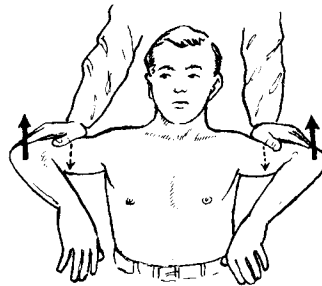


C5, C6, C7 roots
Long thoracic nerve

Patient presses arms against wall

Look for winging of scapula i.e. rises from chest wall

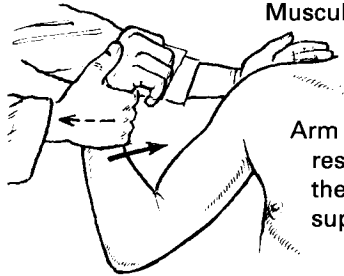
Shoulder abduction



Deltoid:
C5, C6 roots
Axillary nerve

Arm (at more than 15° from the vertical) abducts against resistance

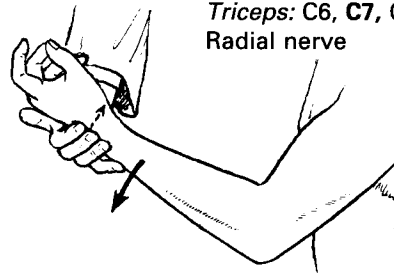
Elbow flexion



Biceps: C5, C6 roots
Musculocutaneous nerve

Arm flexed against resistance with the hand fully supinated

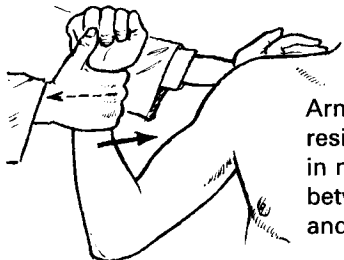
Elbow extension



Triceps: C6, C7, C8 roots
Radial nerve

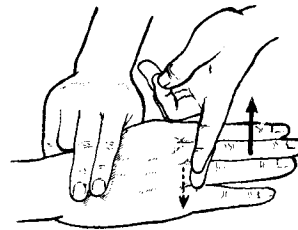
Patient extends arm against resistance

Brachioradialis: C5, C6 roots.
Radial nerve



Arm flexed against resistance with hand in mid-position between pronation and supination

Finger extension

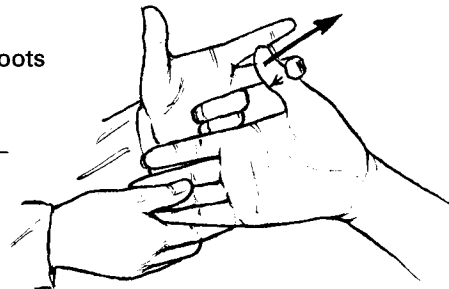


Extensor digitorum: C7, C8 roots
Posterior interosseous nerve

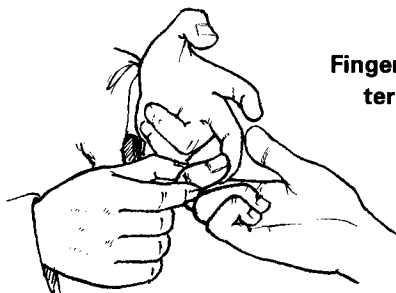
Patient extends fingers against resistance

Thumb extension – terminal phalanx

Extensor pollicis longus and brevis: C7, C8 roots
Posterior interosseous nerve
Thumb is extended against resistance



Finger flexion – terminal phalanx



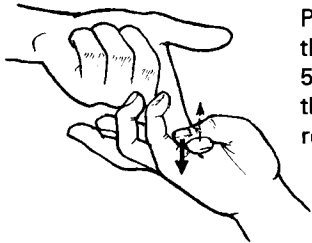
Flexor digitorum profundus I and II: C7, C8 roots
Median nerve
Flexor digitorum profundus III and IV: C7, C8 roots
Ulnar nerve

Examiner tries to extend patient's flexed terminal phalanges

EXAMINATION – UPPER LIMBS

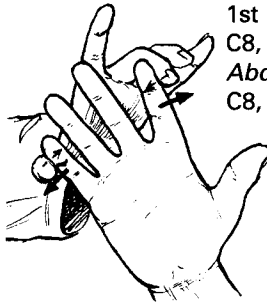
Thumb opposition

Opponens pollicis: C8, T1 roots. Median nerve



Patient tries to touch the base of the 5th finger with thumb against resistance

Finger abduction



1st dorsal interosseus: C8, T1 roots. Ulnar nerve
Abductor digiti minimi: C8, T1 roots. Ulnar nerve

Fingers abducted against resistance

[Note: not all muscle groups are included in the foregoing, but only those required to identify and differentiate nerve and root lesions.]

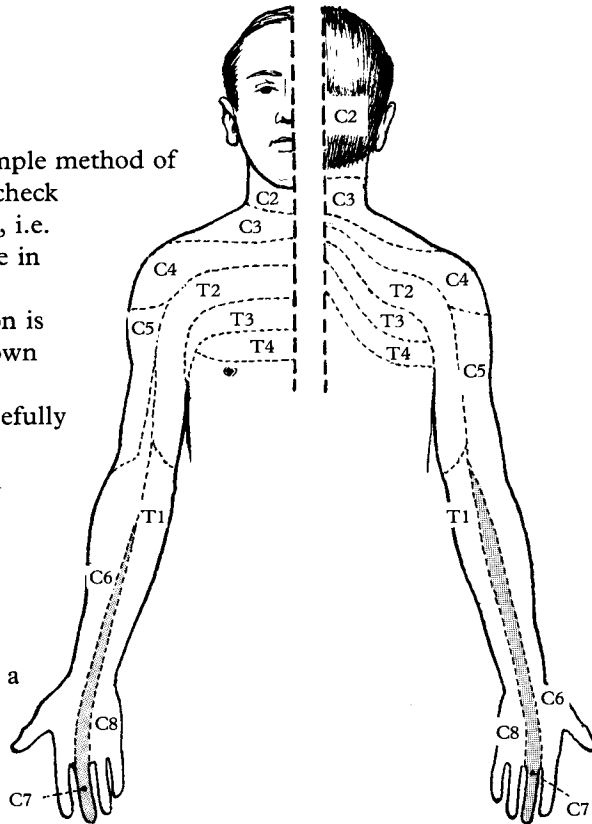
SENSATION

Pain

Pin prick with a sterile pin provides a simple method of testing this important modality. Firstly, check that the patient detects the pin as 'sharp', i.e. painful, then rapidly test each dermatome in turn.

Memorising the dermatome distribution is simplified by noting that 'C7' extends down the middle finger.

If pin prick is impaired, then more carefully map out the extent of the abnormality, moving from the abnormal to the normal area.



Light touch

This is tested in a similar manner, using a wisp of cotton wool.

Temperature

Temperature testing seldom provides any additional information. If required, use a cold object or hot and cold test tubes.

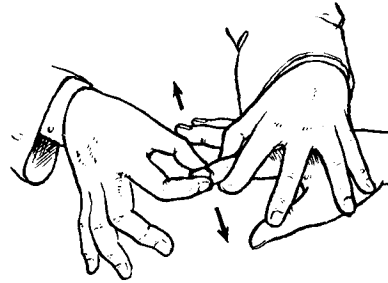
EXAMINATION – UPPER LIMBS

Joint position sense

Hold the sides of the patient's finger or thumb and demonstrate 'up and down' movements.

Repeat with the patient's eyes closed. Ask patient to specify the direction of movement.

Ask the patient, with eyes closed, to touch his nose with his forefinger or to bring forefingers together with the arms outstretched.



Vibration

Place a vibrating tuning fork (usually 128 c/s) on a bony prominence, e.g. radius. Ask the patient to indicate when the vibration, if felt, ceases. If impaired, move more proximally and repeat. Vibration testing is of value in the early detection of demyelinating disease and peripheral neuropathy, but otherwise is of limited benefit.

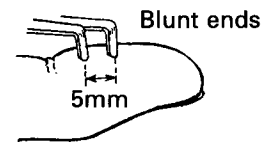
If the above sensory functions are normal and a cortical lesion is suspected, it is useful to test for the following:

Two point discrimination: the ability to discriminate two blunt points when simultaneously applied to the finger, 5 mm apart (cf, 4 cm in the legs).

Sensory inattention (perceptual rivalry): the ability to detect stimuli (pin prick or touch) in both limbs, when applied to both limbs simultaneously.

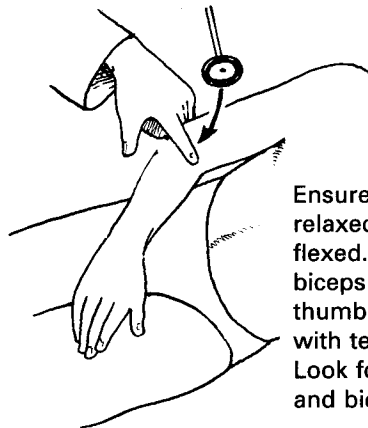
Stereognosis: the ability to recognise objects placed in the hand.

Graphaesthesia: the ability to recognise numbers or letters traced out on the palm.



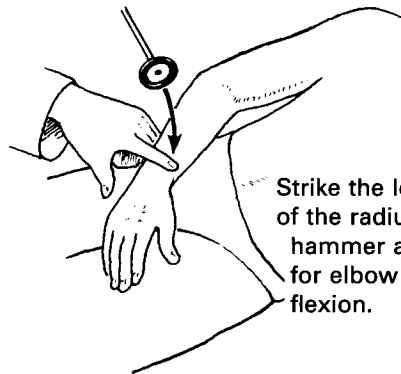REFLEXES

Biceps jerk C5, C6 roots. Musculocutaneous nerve



Ensure patient's arm is relaxed and slightly flexed. Palpate the biceps tendon with the thumb and strike with tendon hammer. Look for elbow flexion and biceps contraction.

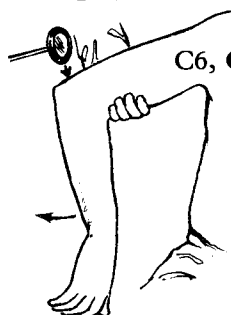
Supinator jerk C6, C7 roots. Radial nerve



Strike the lower end of the radius with the hammer and watch for elbow and finger flexion.

EXAMINATION – UPPER LIMBS

Triceps jerk

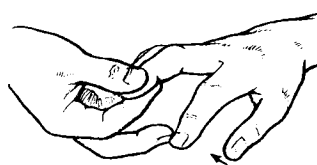


C6, C7, C8 roots.

Radial nerve.

Strike the patient's elbow a few inches above the olecranon process. Look for elbow extension and triceps contraction.

Hoffman reflex C7, C8



Flick the patient's terminal phalanx, suddenly stretching the flexor tendon on release. Thumb flexion indicates hyperreflexia. (May be present in normal subjects with brisk tendon reflexes.)

Reflex enhancement

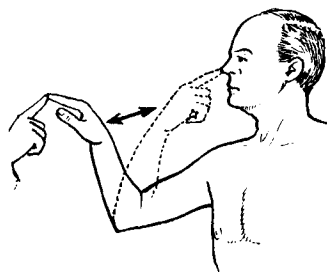
When reflexes are difficult to elicit, enhancement occurs if the patient is asked to 'clench the teeth'.

CO-ORDINATION

Inco-ordination (ataxia) is often a prominent feature of cerebellar disease (see page 178). Prior to testing, ensure that power and proprioception are normal.

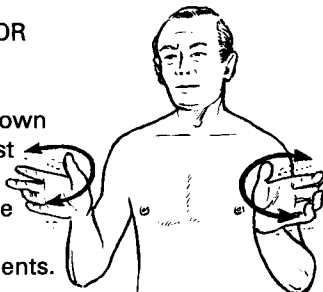
Inco-ordination

Finger – nose testing




Ask patient to touch his nose with finger (eyes open). Look for jerky movements – **DYSMETRIA** or an **INTENTION TREMOR** (tremor only occurring on voluntary movement).

Ask patient to alternately touch his own nose then the examiner's finger as fast as he can. This may exaggerate the intention tremor and may demonstrate **DYSDIADOCHOKINESIA** – an inability to perform rapidly alternating movements.



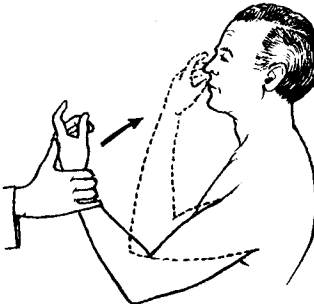
This may also be shown by asking the patient to rapidly supinate and pronate the forearms or to perform rapid and repeated tapping movements.

Arm bounce



Downward pressure and sudden release of the patient's outstretched arm causes excessive swinging.

Rebound phenomenon



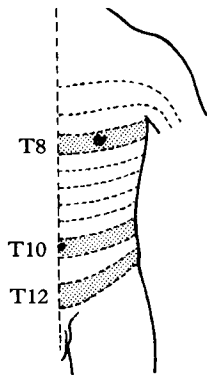
Ask the patient to flex elbow against resistance. Sudden release may cause the hand to strike the face due to delay in triceps contraction.

EXAMINATION – TRUNK

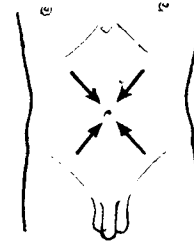
SENSATION

Test pin prick and light touch in dermatome distribution as for the upper limbs.

Levels to remember: T5 – at *nipple*
 T10 – at *umbilicus*
 T12 – at *inguinal ligament*.



Abdominal reflexes: T7 – T12 roots. Stroke or lightly scratch the skin towards the umbilicus in each quadrant in turn. Look for abdominal muscle contraction and note if absent or impaired. (N.B. Reflexes may be absent in obesity, after pregnancy, or after abdominal operations.)



Cremasteric reflex: L1 root. Scratch inner thigh. Observe contraction of cremasteric muscle causing testicular elevation.

SPHINCTERS

Examine abdomen for distended bladder.

Note evidence of urinary or faecal incontinence.

Note tone of anal sphincter during rectal examination.

Anal reflex: S4, S5 roots. A scratch on the skin beside the anus causes a reflex contraction of the anal sphincter.

EXAMINATION – LOWER LIMBS

MOTOR SYSTEM

Appearance: Note:
 – *asymmetry* or *deformity* } as in the upper limbs.
 – muscle *wasting*
 – muscle *hypertrophy*
 – muscle *fasciculation*

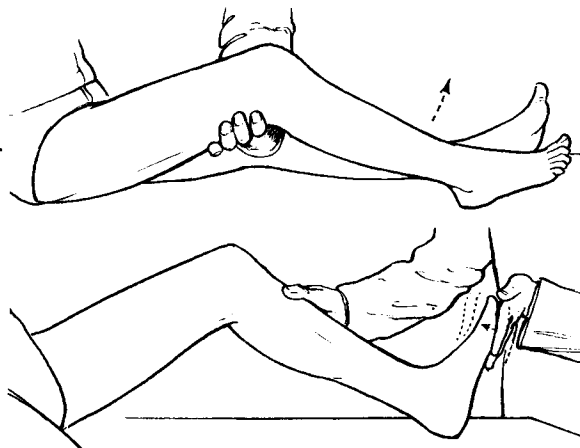
Tone

Try to relax the patient and alternately flex and extend the knee joint. Note the resistance.

Roll the patient's legs from side to side. Suddenly lift the thigh and note the response in the lower leg. With increased tone the leg kicks upwards.

Clonus

Ensure that the patient is relaxed. Apply sudden and sustained flexion to the ankle. A few oscillatory beats may occur in the normal subject, but when this persists it indicates increased tone.

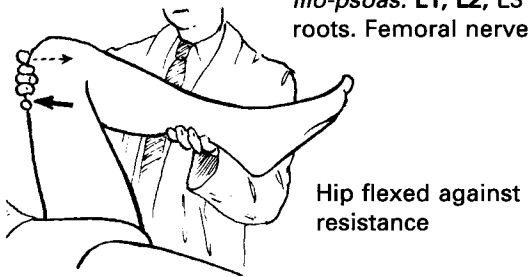


EXAMINATION – LOWER LIMBS

Power

When testing each muscle group, think of *root* and *nerve* supply.

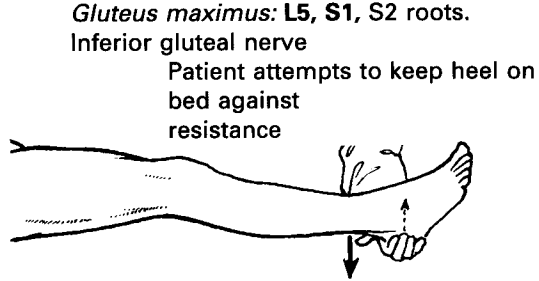
Hip flexion



Ilio-psoas: L1, L2, L3 roots. Femoral nerve

Hip flexed against resistance

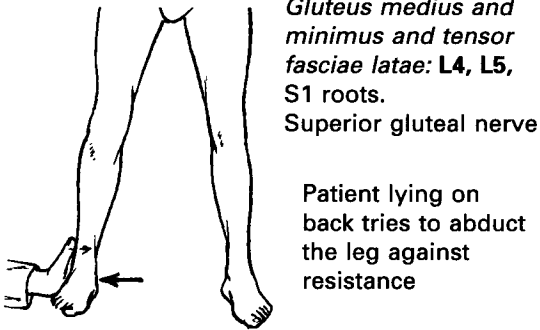
Hip extension



Gluteus maximus: L5, S1, S2 roots. Inferior gluteal nerve

Patient attempts to keep heel on bed against resistance

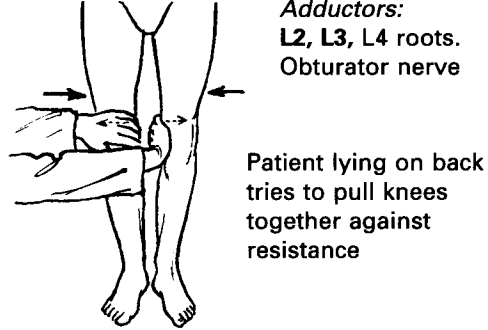
Hip abduction



Gluteus medius and minimus and tensor fasciae latae: L4, L5, S1 roots. Superior gluteal nerve

Patient lying on back tries to abduct the leg against resistance

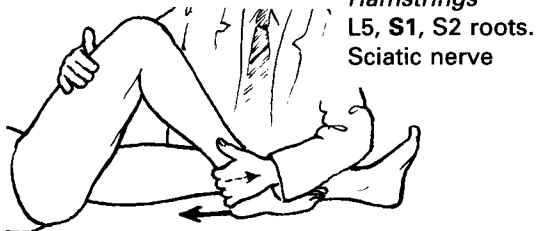
Hip adduction



Adductors: L2, L3, L4 roots. Obturator nerve

Patient lying on back tries to pull knees together against resistance

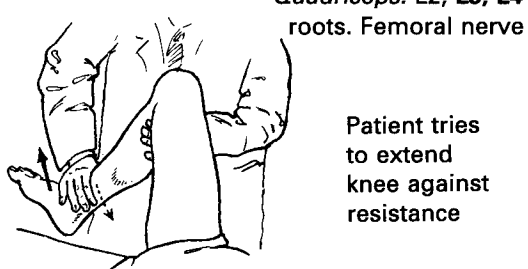
Knee flexion



Hamstrings: L5, S1, S2 roots. Sciatic nerve

Patient pulls heel towards the buttock and tries to maintain this position against resistance.

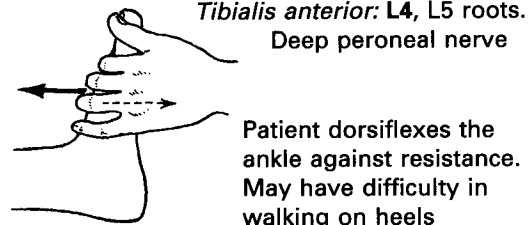
Knee extension



Quadriceps: L2, L3, L4 roots. Femoral nerve

Patient tries to extend knee against resistance

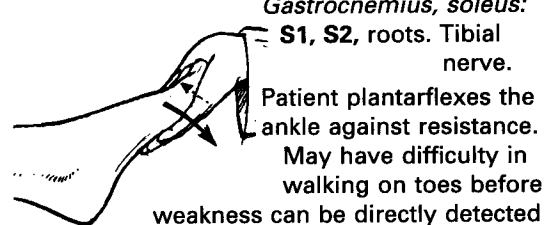
Dorsiflexion



Tibialis anterior: L4, L5 roots. Deep peroneal nerve

Patient dorsiflexes the ankle against resistance. May have difficulty in walking on heels

Plantarflexion

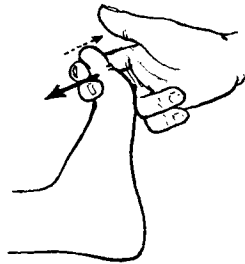


Gastrocnemius, soleus: S1, S2, roots. Tibial nerve.

Patient plantarflexes the ankle against resistance. May have difficulty in walking on toes before weakness can be directly detected

EXAMINATION – LOWER LIMBS


Toe extension



Extensor hallucis longus, extensor digitorum longus: L5, S1 roots.
Deep peroneal nerve

Patient dorsiflexes the toes against resistance

Inversion



Tibialis posterior: L4, L5 root.
Tibial nerve

Patient inverts foot against resistance

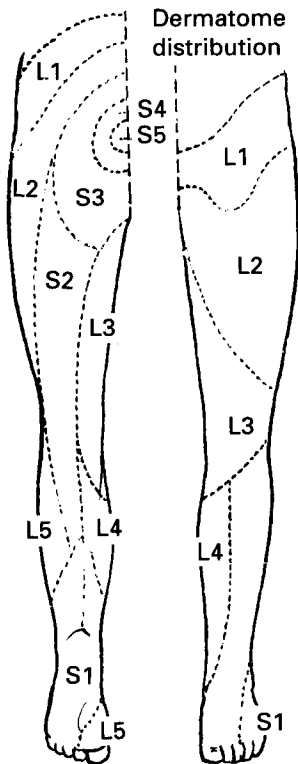
Eversion



Peroneus longus and brevis: L5, S1 roots.
Superficial peroneal nerve

Patient everts foot against resistance

SENSATION



Dermatome distribution

Test:

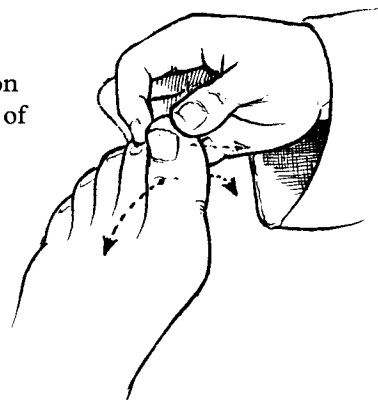
Pain
Light touch
(Temperature)

} follow the dermatome distribution as in the upper limb.

Joint position sense

Firstly, demonstrate flexion and extension movements of the big toe. Then ask patient to specify the direction with the eyes closed.

If deficient, test ankle joint sense in the same way.



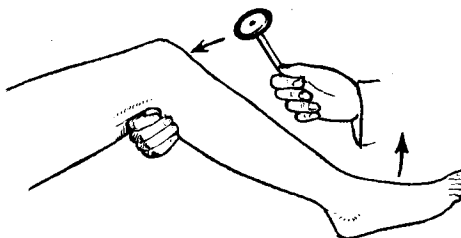
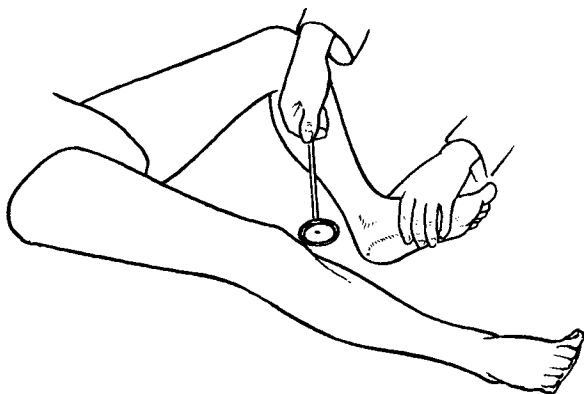
Vibration

Test vibration perception by placing a tuning fork on the malleolus. If deficient, move up to the head of the fibula or to the anterior superior iliac spine.

EXAMINATION – LOWER LIMBS

REFLEXES**Knee jerk:** L2, L3 L4 roots.

Ensure that the patient's leg is relaxed by resting it over examiner's arm or by hanging it over the edge of the bed. Tap the patellar tendon with the hammer and observe quadriceps contraction. Note impairment or exaggeration.

**Ankle jerk:** S1, S2 roots.

Externally rotate the patient's leg. Hold the foot in slight dorsiflexion. Ensure the foot is relaxed by palpating the tendon of tibialis anterior. If this is taut, then no ankle jerk will be elicited.

Tap the Achilles tendon and watch for calf muscle contraction and plantarflexion.

Reflex enhancement

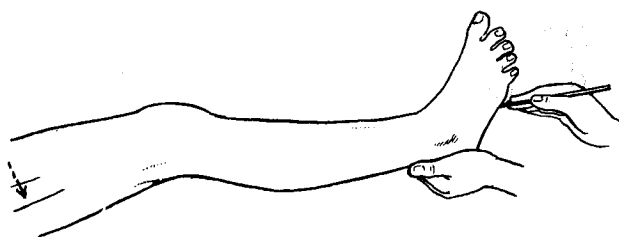
When reflexes are difficult to elicit, they may be enhanced by asking the patient to clench the teeth or to try to pull clasped hands apart (Jendressik's manoeuvre).

Plantar response

Check that the big toe is relaxed. Stroke the lateral aspect of the sole and across the ball of the foot. Note the first movement of the big toe. Flexion should occur. Extension due to contraction of extensor hallucis longus (a 'Babinski' reflex) indicates an upper motor neuron lesion. This is usually accompanied by synchronous contraction of the knee flexors and tensor fasciae latae.

Elicit Chaddock's sign by stimulating the lateral border of the foot. The big toe extends with upper motor neuron lesions.

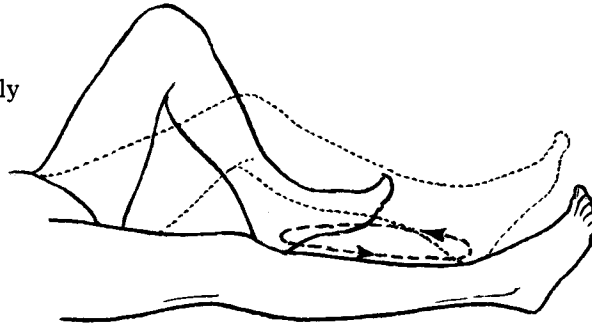
To avoid ambiguity do not touch the innermost aspect of the sole or the toes themselves.



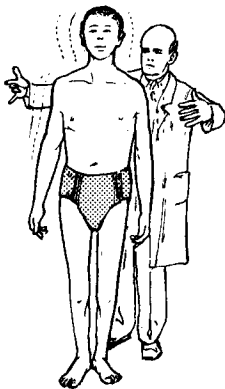
EXAMINATION – POSTURE AND GAIT

CO-ORDINATION

Ask patient to repeatedly run the heel from the opposite knee down the shin to the big toe. Look for ATAXIA (inco-ordination). Ask patient to repeatedly tap the floor with the foot. Note any DYSDIADOCHOKINESIA (difficulty with rapidly alternating movement).



Romberg's test



Ask patient to stand with the heels together, first with the eyes open, then with the eyes closed.

Note any excessive postural swaying or loss of balance

Present when eyes open or closed

= cerebellar deficit (cerebellar ataxia)

Present only when eyes are closed ('positive' Romberg's)

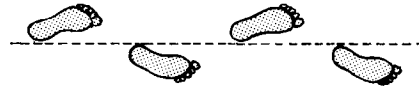
= proprioceptive deficit (sensory ataxia)

GAIT

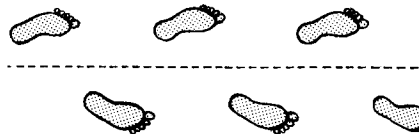
Note:

- Length of step and width of base
- Abnormal leg movements (e.g. excessively high step)
- Instability (gait ataxia)
- Associated postural movements (e.g. pelvic swinging)

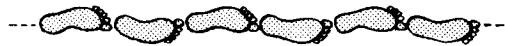Normal



Abnormal



If normal, repeat with *tandem* walking, i.e. heel to toe. This will exaggerate any instability.



EXAMINATION OF THE UNCONSCIOUS PATIENT

HISTORY

Questioning relatives, friends or the ambulance team is an essential part of the assessment of the unconscious or the unco-operative patient.

- Has the patient sustained a head injury – leading to admission, or in the preceding weeks?
- Did the patient collapse suddenly?
- Did limb twitching occur?
- Have symptoms occurred in the preceding weeks?
- Has the patient suffered a previous illness?
- Does the patient take medication?

GENERAL EXAMINATION

Lack of patient co-operation does not limit general examination and this may reveal important diagnostic signs. In addition to those features described on page 4, also look for signs of head injury, needle marks on the arm and evidence of tongue biting. Also note the smell of alcohol, but beware of attributing the patient's clinical state solely to alcohol excess.

NEUROLOGICAL EXAMINATION

Conscious level: This assessment is of major importance. It not only serves as an immediate prognostic guide, but also provides a baseline with which future examinations may be compared. Assess conscious level as described previously (page 5) in terms of:

Eye opening		Verbal response		Motor response	
Spontaneous	4	Orientated	5	Obeying commands	5
To speech	3	Confused	4	Localising	4
To pain	2	Words	3	Flexing	3
None	1	Sounds	2	Extending	2
		None	1	None	1

A score may be applied to each category of the grading system and the total summed to give an overall value ranging from 3–14, e.g. no eye opening, no verbal response and extending to pain = 4.

Pupil response

Fundi

Corneal reflex

– tone

Limb – reflexes

– plantar response

Lack of patient co-operation does not prevent objective assessment of these features described before, but elucidation of other relevant neurological signs requires a different approach.


EXAMINATION OF THE UNCONSCIOUS PATIENT

Eye movements

Observe any **spontaneous** eye movements.



(Eyes held open by examiner)



Elicit the **oculocephalic (doll's eye) reflex**.

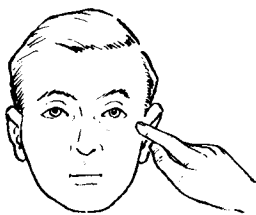
Rotation or flexion/extension of the head in a comatose patient produces transient eye movements in a direction opposite to that of the movement.

Note whether the movements, if present, are *conjugate* (i.e. the eyes move in parallel) or *dysconjugate* (i.e. the eyes do not move in parallel). These ocular movements assess midbrain and pontine function.

Elicit the **oculovestibular reflex** (caloric testing, see page 62).

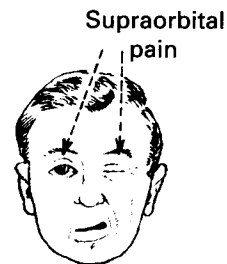
Visual fields

In the unco-operative patient, the examiner may detect a hemianopic field defect when 'menacing' from one side fails to produce a 'blink'.



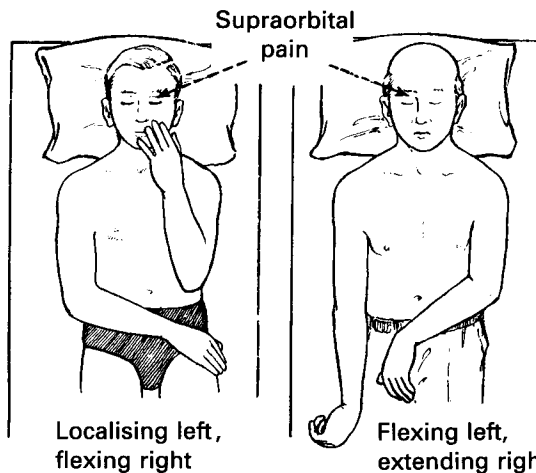
Facial weakness

Failure to 'grimace' on one side in response to bilateral supraorbital pain indicates a facial weakness.



Limb weakness

Detect by comparing the response in the limbs to painful stimuli. If pain produces an *asymmetric* response, then limb weakness is present. (If the patient 'localises' with one arm, hold this down and retest to ensure that a similar response cannot be elicited from the other limb).



e.g.

Localising left, flexing right

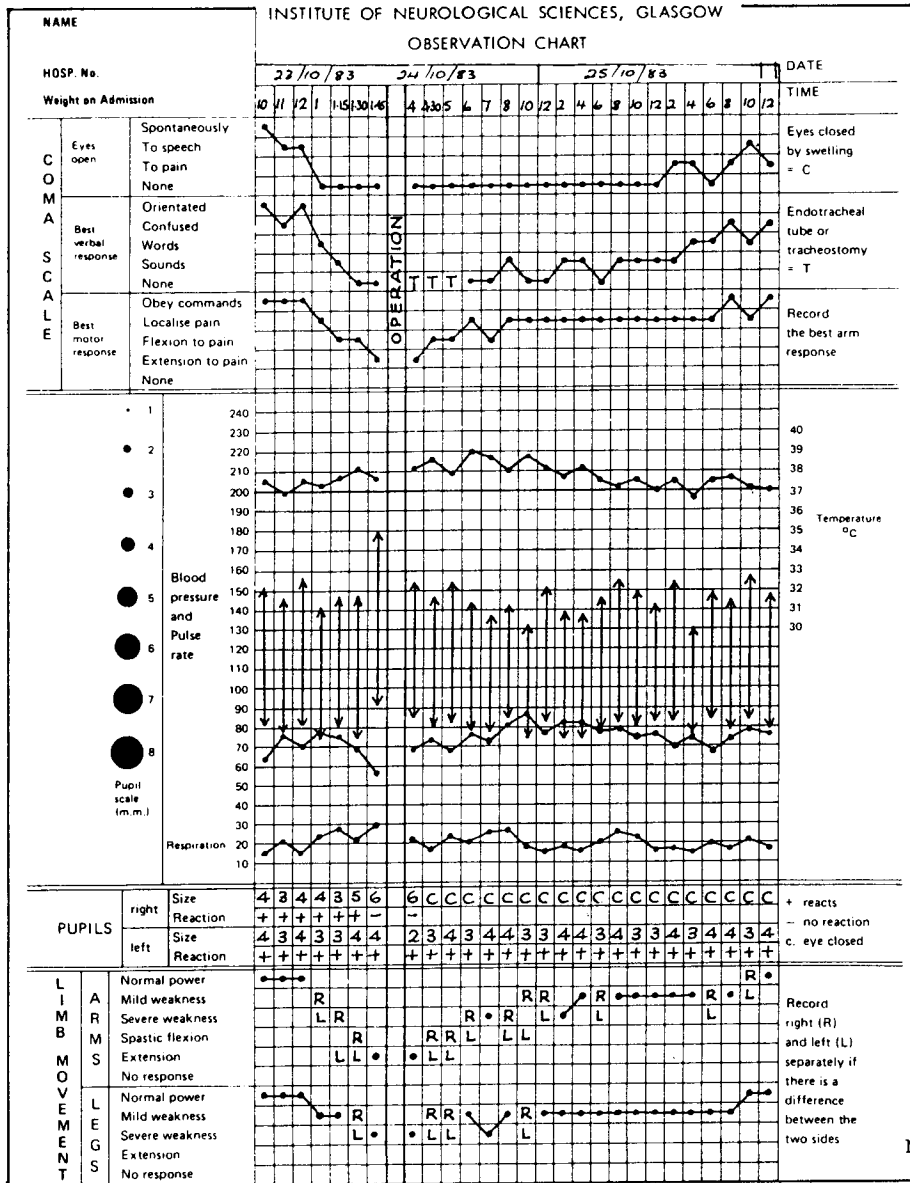
Flexing left, extending right

Both patients are in coma; both have an asymmetric response to pain indicating a right arm weakness and focal brain damage.

Pain stimulus applied to the toe nails or Achilles tendon similarly tests power in the lower limbs. Variation in tone, reflexes or plantar responses between each side also indicates a focal deficit. In practice, if the examiner fails to detect a difference in response to painful stimuli, these additional features seldom provide convincing evidence.

THE NEUROLOGICAL OBSERVATION CHART

Despite major advances in intracranial investigative techniques, none has replaced clinical assessment for monitoring the patient's neurological state. The neurological observation chart produced by Jennett and Teasdale incorporates the most relevant clinical features, i.e. *coma scale (eye opening, verbal and motor response)*, *pupil size and reaction to light*, *limb responses* and *vital signs*. The frequency of observation (normally 2-hourly) depends on the individual patient's needs. The chart enables immediate evaluation of the trend in the patient's clinical state.



By permission of the Nursing Times

**INVESTIGATIONS OF THE
CENTRAL AND PERIPHERAL
NERVOUS SYSTEMS**

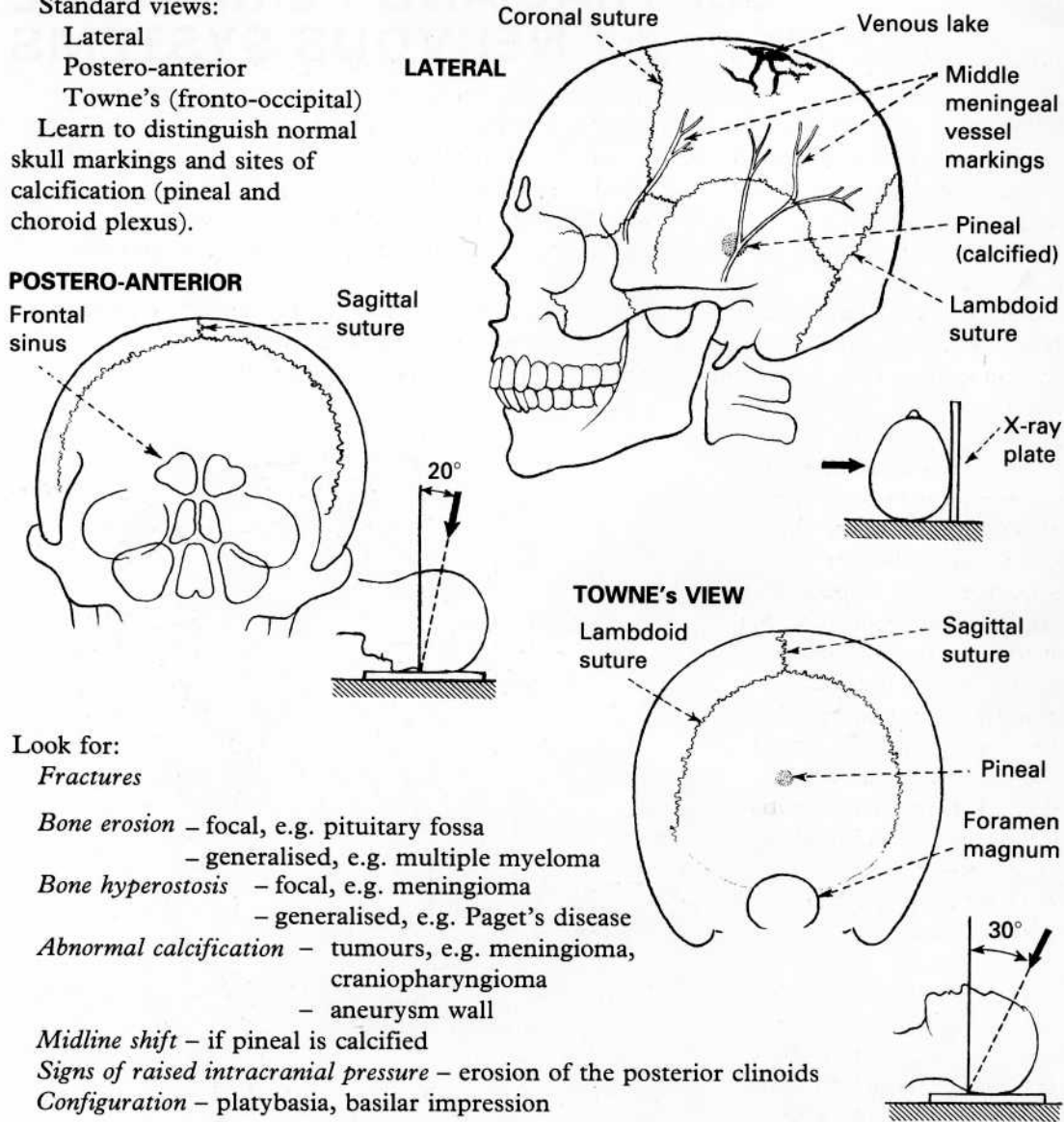
SKULL X-RAY

Despite the development of advanced radiological techniques, skull X-ray is still a useful preliminary investigation especially in head injured patients.

Standard views:

- Lateral
- Postero-anterior
- Towne's (fronto-occipital)

Learn to distinguish normal skull markings and sites of calcification (pineal and choroid plexus).



Look for:

Fractures

Bone erosion – focal, e.g. pituitary fossa
 – generalised, e.g. multiple myeloma

Bone hyperostosis – focal, e.g. meningioma
 – generalised, e.g. Paget's disease

Abnormal calcification – tumours, e.g. meningioma,
 craniopharyngioma
 – aneurysm wall

Midline shift – if pineal is calcified

Signs of raised intracranial pressure – erosion of the posterior clinoids

Configuration – platybasia, basilar impression

More specific views depend on clinical indications and the availability of other imaging techniques, e.g.

Base of skull (submentovertical) – cranial nerve palsies

Optic foramina – progressive blindness

Sella turcica – visual field defects

Petrous/internal auditory meatus – sensorineural deafness.

COMPUTERISED TOMOGRAPHY (CT) SCANNING

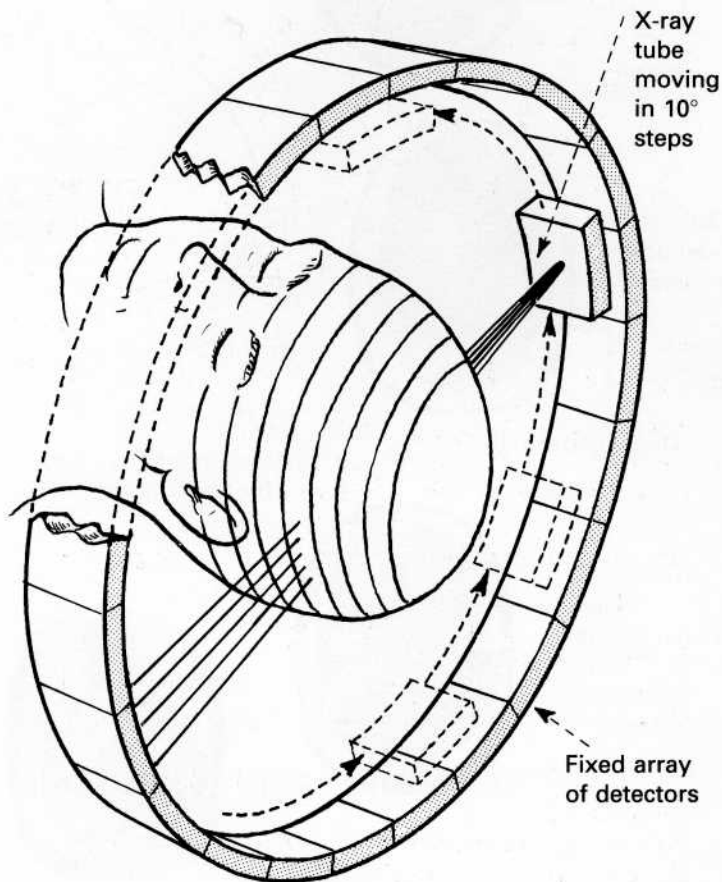
The development of this non-invasive technique in the 1970s revolutionised the investigative approach to intracranial pathology and it is now used routinely for 'body' and spine.

A pencil beam of X-ray traverses the patient's head and a diametrically opposed detector measures the extent of its absorption. Computer processing, multiple rotating beams and detectors arranged in a complete circle around the patient's head enable determination of absorption values for multiple small blocks of tissue (voxels). Reconstruction of these areas on a two-dimensional display (pixels) provides the characteristic CT scan appearance. For routine scanning, slices are 5–10 mm wide. Slices of 1–2 mm width provide even greater detail but these 'high definition' views take longer to acquire and process and this technique is usually reserved for examination of the orbit, the pituitary region and the posterior fossa.

Selecting different window levels displays tissues of different X-ray density more clearly. Some centres routinely provide two images for each scanned level of the lumbar spine, one to demonstrate bone structures, the other to show soft tissue within and outwith the spinal canal.

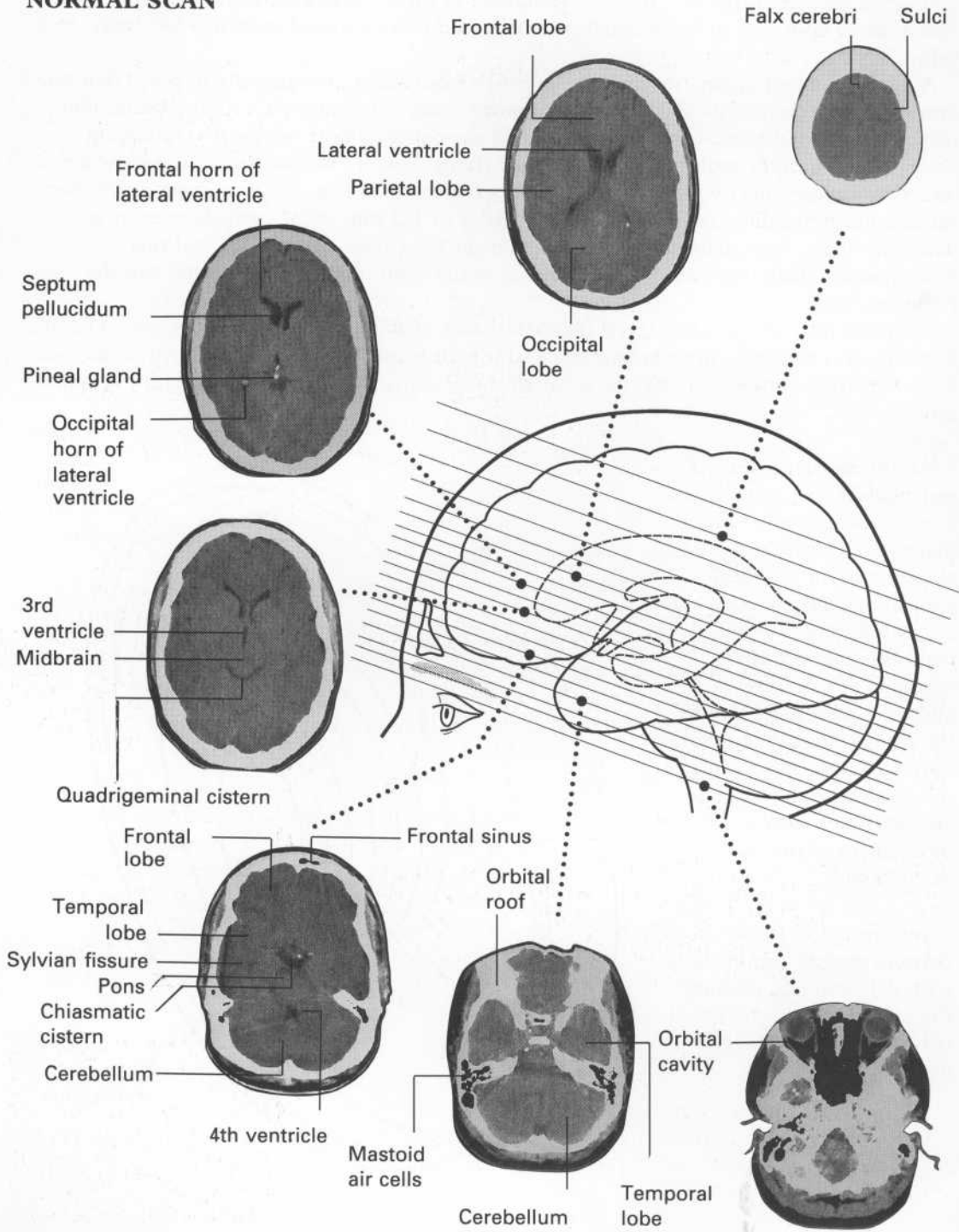
An *intravenous iodinated water-soluble contrast medium* is administered when the plain scan reveals an abnormality or if specific clinical indications exist, e.g. suspected arteriovenous malformation, acoustic neuroma or intracerebral abscess – with these lesions the plain scan may appear normal. Intravenous contrast shows areas with increased vascularity or with impairment of the blood-brain barrier.

Intrathecal water-soluble contrast medium combined with CT scanning outlines the basal cisterns, the spinal cord and the lumbosacral nerve roots.



COMPUTERISED TOMOGRAPHY (CT) SCANNING

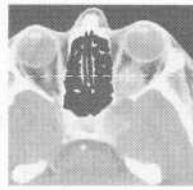NORMAL SCAN



COMPUTERISED TOMOGRAPHY (CT) SCANNING

Coronal and sagittal reconstruction

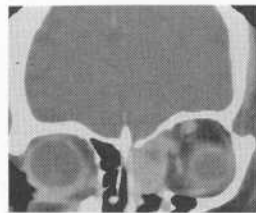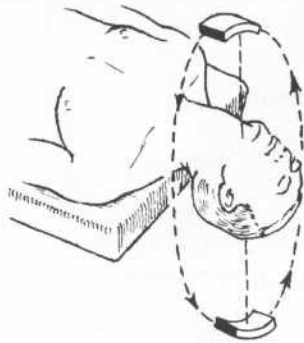
CT imaging in the coronal plane is difficult and in the sagittal plane, virtually impossible. Two dimensional reconstruction of a selected plane may provide more information, but requires CT slices of narrow width e.g. 2-3 mm.



Reconstruction showing orbital tumour and relationships in the coronal plane.



Coronal CT scanning



Coronal scan showing a tumour of the ethmoidal sinus

Full neck extension combined with maximal angulation of the CT gantry permits direct coronal scanning and may give greater definition than reconstructed views.

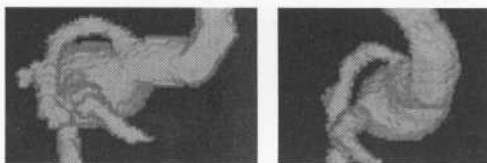
Dynamic CT scanning

Scanning during infusion of i.v. contrast followed by two-dimensional reconstruction of the image provides a non-invasive method of showing intracranial vessels. Although this technique may demonstrate aneurysms as small as 2 mm, it is only practical to examine a small section of the vasculature at any one time and angiography gives better definition.

Dynamic CT scan showing posterior communicating aneurysm



Three dimensional reconstruction



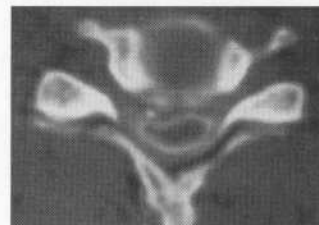Sophisticated computer programmes now produce stunning 3-D reconstructed images which can be rotated on a monitor screen. In practice these images seldom provide additional clinical information.

This 3-D reconstruction of a dynamic CT scan identified the configuration of vessels entering a vertebro-basilar aneurysm.

Spinal CT scanning

Plain CT of the spine provides useful information of disc disease, particularly at the lumbosacral level. CT scanning after instilling a small amount of intrathecal contrast more clearly demonstrates lesions compressing the spinal cord or the cervico-medullary junction.

Cervical disc compressing one side of the spinal cord.



COMPUTERISED TOMOGRAPHY (CT) SCANNING

Interpretation of the cranial CT scan

Before contrast enhancement note:

VENTRICULAR SYSTEM

- Size
- Position
- Compression of one or more horns, i.e. frontal, temporal or occipital

WIDTH OF CORTICAL SULCI AND THE SYLVIAN FISSURES

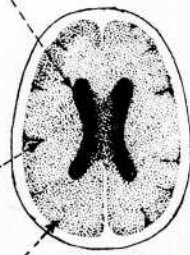
SKULL BASE AND VAULT

- Hyperostosis
- Osteolytic lesion
- Remodelling
- Depressed fracture

MULTIPLE LESIONS

may result from:

- Tumour – metastases
- lymphoma
- Abscesses
- Granuloma
- Infarction
- Trauma



ABNORMAL TISSUE DENSITY

Identify the site, and whether the lesion lies within or without the brain substance.
 Note the 'MASS EFFECT':

- midline shift
- ventricular compression
- obliteration of the basal cisterns, sulci

High density

- Blood
 - Calcification – tumour
 - arteriovenous malformation/aneurysm
 - hamartoma
- (Calcification of the pineal gland, choroid plexus, basal ganglia and falx may occur in normal scans.)

Low density

- Infarction (arterial/venous)
- Tumour
- Abscess
- Oedema
- Encephalitis
- Resolving haematoma

Mixed density

- Tumour
- Abscess
- Arteriovenous malformation
- Contusion
- Haemorrhagic infarct

After contrast enhancement:

Vessels in the circle of Willis appear in the basal slices. Look at the extent and pattern of contrast uptake in any abnormal region. Some lesions may only appear after contrast enhancement.

MAGNETIC RESONANCE IMAGING (MRI)

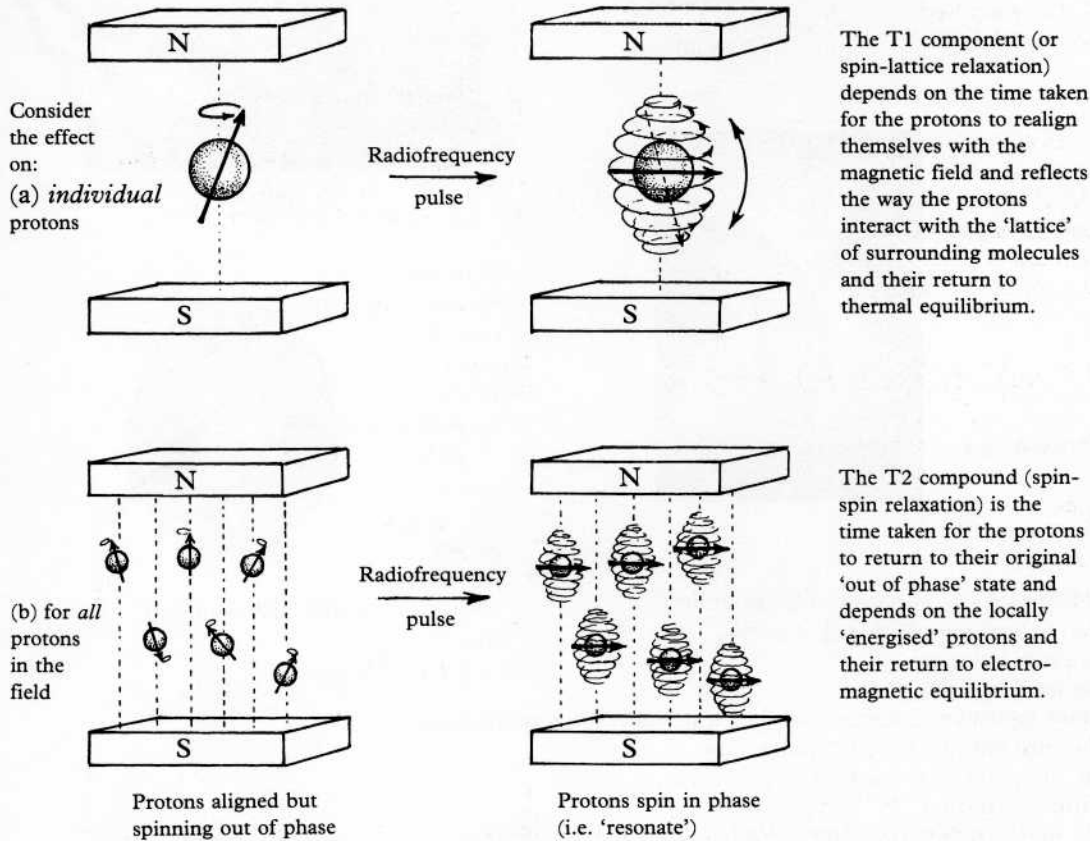
For many years, magnetic resonance techniques aided chemical analysis in the food and petrochemical industries. The development of large-bore homogeneous magnets and computer assisted imaging (as in CT scanning) extended its use to the mapping of hydrogen nuclei (i.e. water) densities and their effect on surrounding molecules in vivo. Since these vary from tissue to tissue, MRI can provide a detailed image of both head and body structures.

Physical basis

When a substance is placed in a magnetic field, spinning protons within the nuclei act like small magnets and align themselves within the field.

A superimposed electromagnetic pulse (radiowave) at a specific frequency displaces the hydrogen protons.

The transverse component of the magnetisation vector generates the MRI signal.

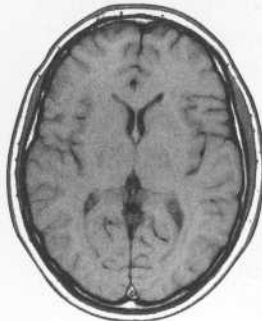

A variety of different radiofrequency pulse sequences (saturation recovery (SR), inversion recovery (IR) and spin echo (SE) combined with computerised imaging produce an image of either proton density or of T1 or T2 weighting depending on the sequence employed.

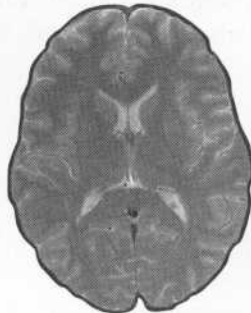
MAGNETIC RESONANCE IMAGING (MRI)

Normal MRI images (T1/T2 weighting in relation to normal grey/white matter)

axial views – head

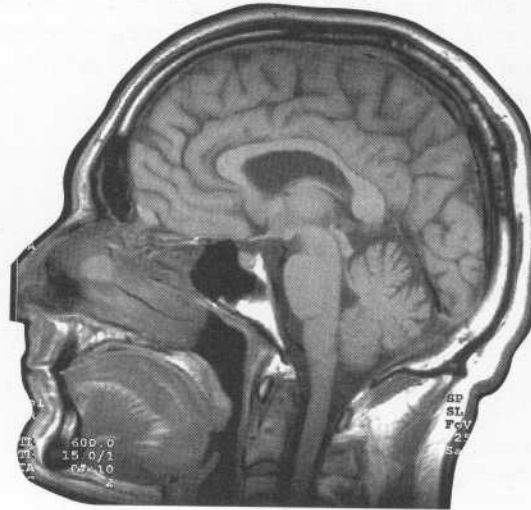


T1 weighted



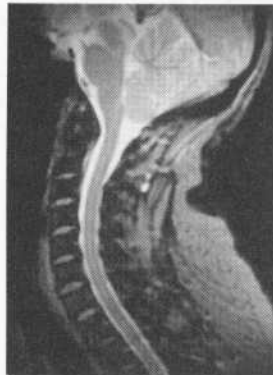
T2 weighted

Sagittal view – head



T1 weighted

Cervicodorsal spine (sagittal view)



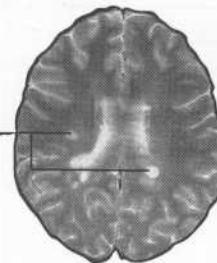
T2 weighted

Advantages (compared to CT scanning)

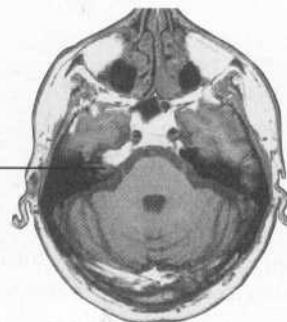- Can select any plane, e.g. coronal, sagittal, oblique.
- No ionising radiation.
- More sensitive to tissue changes, e.g. demyelination plaques (but not specific for each pathology, i.e. does not distinguish demyelination from ischaemia).
- No bone artifacts, e.g. intracanalicular acoustic neuroma.

Disadvantages

- Limited slice thickness – 3 mm (cf. CT – 1 mm).
- Bone imaging limited to display of marrow.
- Claustrophobia.
- Cannot use with pacemaker or ferromagnetic implant.



T2 weighted



T1 weighted

MAGNETIC RESONANCE IMAGING (MRI)

Interpretation of abnormal MRI image

Look for structural abnormalities and abnormal intensities indicating a change in tissue T1 or T2 weighting *in relation to normal grey and white matter*. (A prolonged T1 relaxation time gives hypointensity, i.e. more black; a prolonged T2 relaxation time gives hyperintensity, i.e. more white).

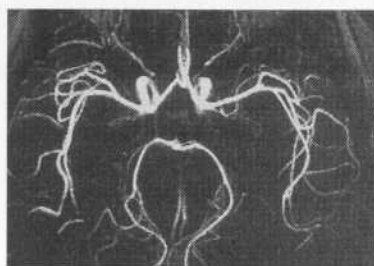
T1 relaxation time	T2 relaxation time	Tissue/lesion
↓↓ Intensity	↑ Intensity	CSF, cyst, hygroma, cerebromalacia
↓ Intensity	↑ Intensity	Ischaemia, oedema, demyelination, most malignant tumours
↑ Intensity	slight ↑ Intensity	subacute/chronic haemorrhage
↑ Intensity	↑ Intensity	Fat, e.g. dermoid tumour, lipoma, some metastasis, atheroma
Isointense	↓ Intensity	Acute haemorrhage
Isointense	Isointense	Meningioma (usually identified from structural change or surrounding oedema)

Paramagnetic enhancement

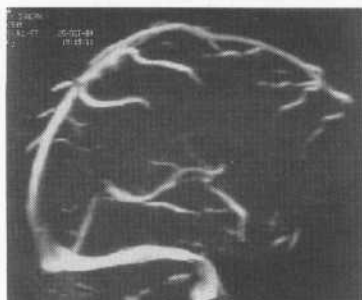
Some substances e.g. gadolinium, induce strong local magnetic fields – particularly shortening the T1 component. After intravenous administration, leakage of gadolinium through regions of damaged blood-brain barrier produces marked enhancement of the MRI signal, e.g. in ischaemia, infection, tumours and demyelination. Gadolinium may also help differentiate tumour tissue from surrounding oedema.

MR Angiography (MRA)

Rapidly flowing protons can create different intensities from stationary protons and the resultant signals obtained by special sequences can demonstrate vessels, aneurysms and arteriovenous malformations. Vessels displayed simultaneously, may make interpretation



difficult, but selection of a specific MR section can demonstrate a single vessel or bifurcation. By selecting a specific flow velocity, MRA will show either arteries or veins. The resolution does not match other techniques. MRA will only detect 95% of those aneurysms seen on intra-arterial DSA (see page 43).



Cerebral veins – oblique view showing sagittal sinus

ULTRASOUND

Extracranial

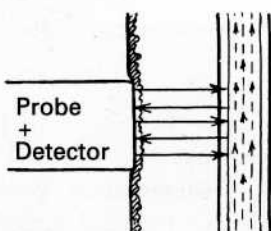
When the probe (i.e. a transducer) – frequency 5–10 MHz, is applied to the skin surface, a proportion of the ultrasonic waves emitted are reflected back from structures of varying acoustic impedance and are detected by the same probe. These reflected waves are reconverted into electrical energy and displayed as a two-dimensional image (β -mode).

When the probe is directed at moving structures, such as red blood cells within a blood vessel lumen, frequency shift of the reflected waves occurs (the Doppler effect) proportional to the velocity of flowing blood. Doppler ultrasound uses *continuous wave* (CW) or *pulsed wave* (PW). The former measures frequency shift anywhere along the path of the probe. Pulsed ultrasound records frequency shift at a specific depth.

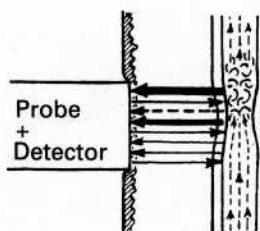
Duplex scanning combines β -mode with doppler, simultaneously providing images from the vessels from which the velocity is recorded.

Colour Coded Duplex (CCD) uses colour coding to superimpose flow velocities on a two dimensional ultrasound image.

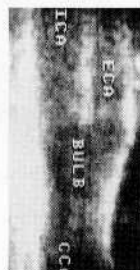Normal vessels exhibit laminar flow and the probe detects a constant velocity.



With stenosis the probe detects a wide spectrum of velocity



β -mode (real time) scanning images the arterial wall rather than the passage of red blood cells – producing a 'map' of the lumen.



Applications: assessment of extracranial carotid and vertebral arteries.

Intracranial – transcranial Doppler ultrasound

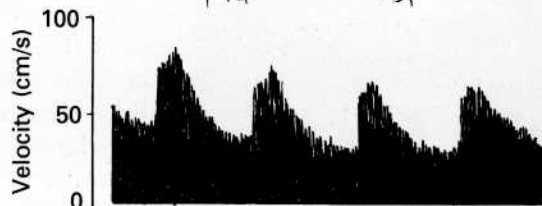
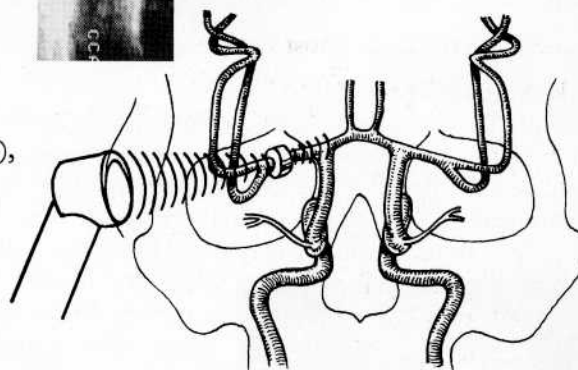
By selecting lower frequencies (2 MHz), ultrasound is able to penetrate the thinner parts of the skull bone.

Combining this with a pulsed system gives reliable measurements and flow velocity in the anterior, middle and posterior cerebral arteries and in the basilar artery.

Applications:

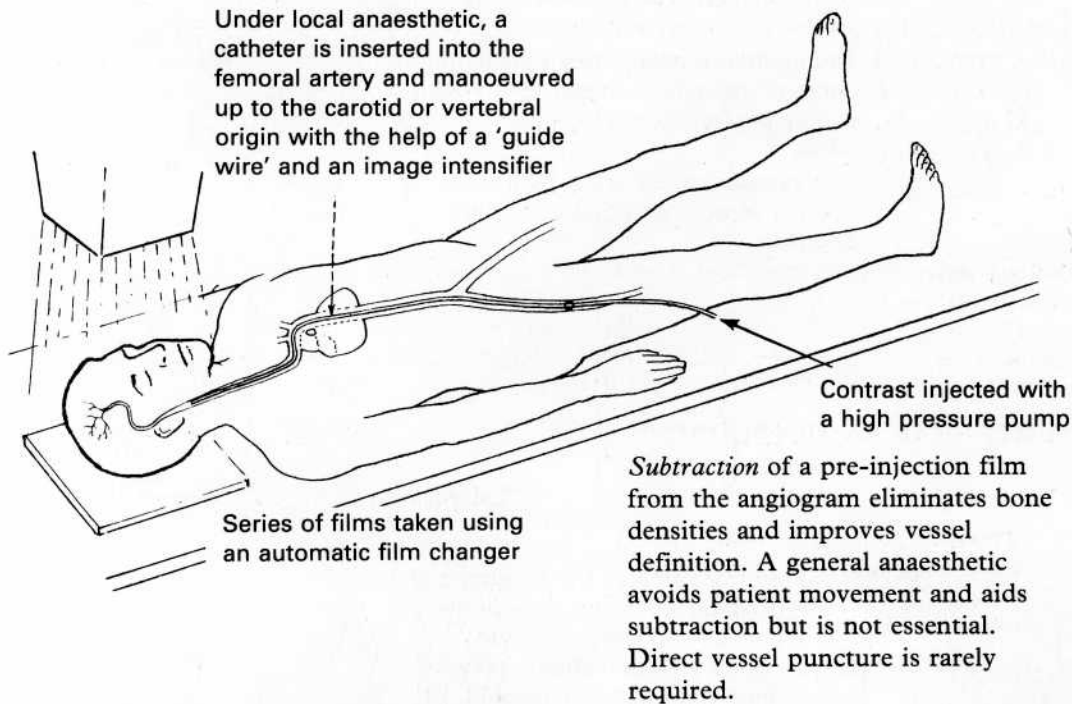
Assessment of intracranial haemodynamics in extracranial occlusive/stenotic vascular disease.

Detection of vasospasm in subarachnoid haemorrhage.



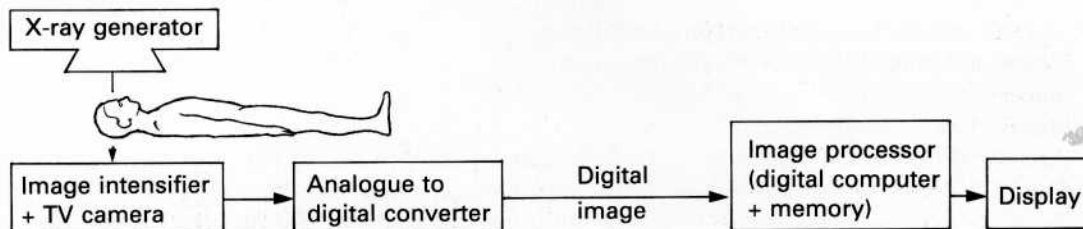
ANGIOGRAPHY

Many neurological and neurosurgical conditions require accurate delineation of both intra- and extracranial vessels. Intra-arterial injection of contrast remains the standard angiographic technique, either imaged directly on X-ray film or by digital subtraction (DSA). Intravenous DSA is of sufficient quality to be of value when investigating certain conditions e.g. carotid stenosis, sagittal sinus thrombosis.



- | | | |
|-------|-------------|---------------------------------------------------------------------------------------------------------------------------------------------------------------------------------------|
| Phase | - arterial | } Most information is now derived from the arterial phase.
Prior to the availability of CT scanning, the position of the cerebral vessels helped localise intracranial structures. |
| | - capillary | |
| | - venous | |

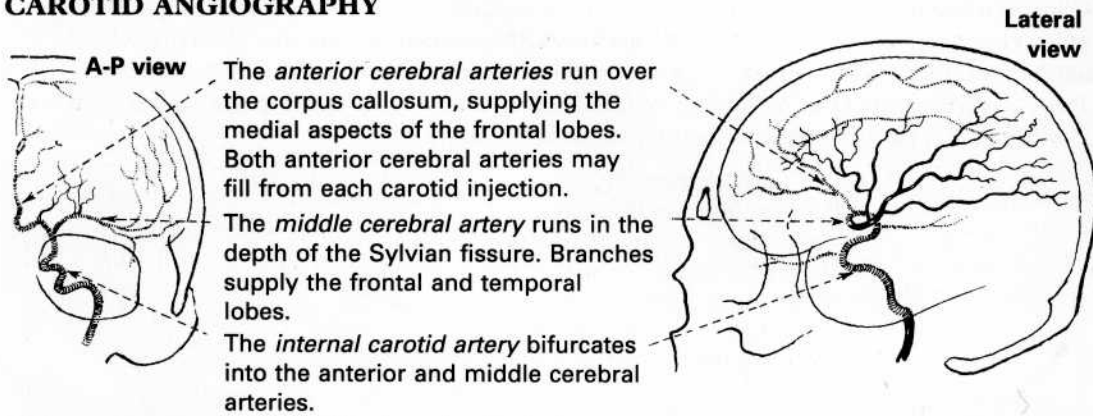
Digital subtraction angiography (DSA) depends upon high-speed digital computing. Exposures taken before and after the administration of contrast agents are instantly subtracted 'pixel by pixel'. Data manipulation allows enhancement of small differences of shading as well as magnification of specific areas of study.



DSA results in improved contrast sensitivity, permitting the use of much lower concentrations of contrast material.

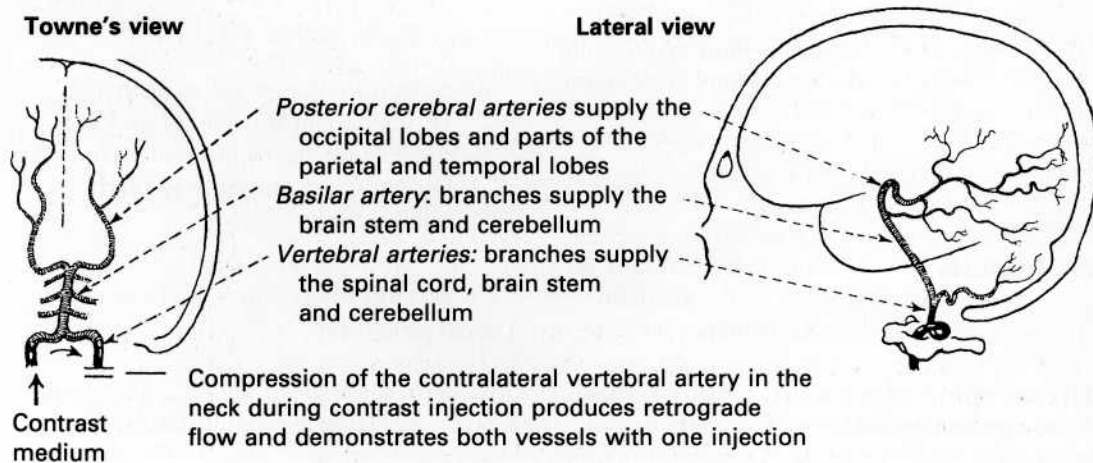
ANGIOGRAPHY

CAROTID ANGIOGRAPHY



Oblique views may aid identification of some lesions, e.g. aneurysms.

VERTEBRAL ANGIOGRAPHY



In *carotid* and *vertebral* angiography look for:

Vessel *occlusion*, *stenosis* or *plaque formation*

Aneurysms

Arterio-venous malformations

Abnormal *tumour circulation*

Vessel *displacement* or *compression*.

Although superseded by the CT scan in tumour detection, angiography may give useful information about feeding vessels and the extent of vessel involvement with the tumour.

ANGIOGRAPHY

Complications

The development of non-ionic contrast mediums, e.g. iohexol, iopamidol, has considerably reduced the risk of complications during or following angiography.

Cerebral ischaemia: caused by emboli from an arteriosclerotic plaque broken off by the catheter tip, hypotension or vessel spasm following contrast injection. The reduced amount of contrast used for intra-arterial DSA carries less risk. In the hands of experienced radiologists, permanent neurological deficit occurs in only one in every 5,000 investigations.

Contrast sensitivity: mild sensitivity to the contrast occasionally develops, but this rarely causes severe problems.

Magnetic Resonance Angiography (MRA) (see page 41)

INTERVENTIONAL ANGIOGRAPHY

With recent advances, endovascular techniques now play an important role in neurosurgical management.

Embolisation: *Particles* (e.g. Ivalon sponge) injected through the arterial catheter will occlude small vessels; e.g. those feeding meningioma or glomus jugulare tumours, thus minimising operative haemorrhage.

'*Glue*' (isobutyl-2-cyanocrylate) can be injected into both high and low flow arteriovenous malformations. Operative excision is greatly facilitated; if the lesion is completely obliterated, this may even serve as a definitive treatment.

Platinum coils inserted into the aneurysm fundus through the angiographic catheter can induce thrombosis and complete or partial obliteration. Whether this permanently protects against rebleeding awaits long-term follow-up (see page 283).

Balloons inflated, then detached from the catheter tip will occlude high flow systems involving large vessels, e.g. carotico-cavernous fistula, high flow arteriovenous malformations.

All techniques carry some risk of cerebral (or spinal) infarction from inadvertent distal embolisation when used in the internal carotid or spinal systems.

Angioplasty: Inflation of an intravascular balloon within a vasospastic segment of a major vessel may reverse cerebral ischaemia, but the technique is not without risk and experience is still limited in most centres. Trials are currently addressing its role in the management of carotid stenosis and vasospasm after subarachnoid haemorrhage.

RADIONUCLEOTIDE IMAGING

There are two components to imaging with radioactive tracers – the detecting system and the labelled chemical. Each of these has become increasingly sophisticated in recent years.

Conventional gamma camera scanning

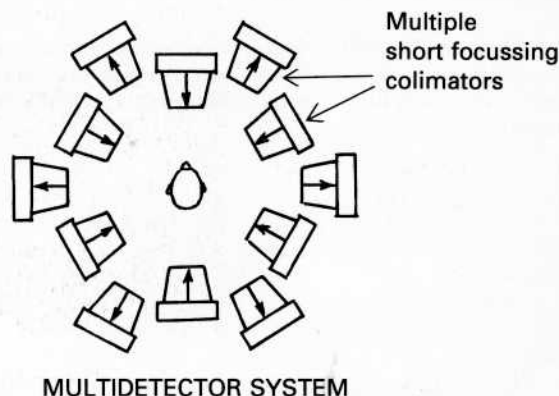
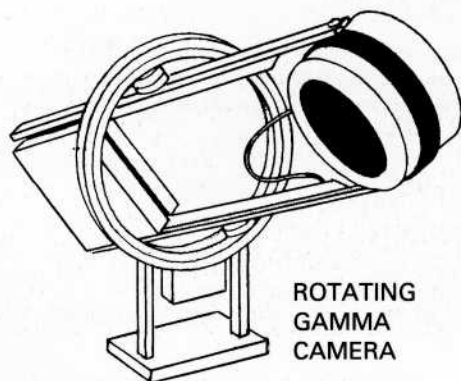
Following a blocking dose of potassium perchlorate (to prevent uptake in the choroid plexus and salivary glands), sodium pertechnetate, labelled with technetium^{99m}, is injected intravenously and its distribution within the brain detected with a gamma camera placed in the lateral, anterior or posterior positions. *Where CT scanning is available, this technique is now obsolete.*

Single photon emission tomography (SPECT)

This technique also uses compounds labelled with gamma-emitting tracers (ligands), but unlike conventional scanning, acquires data from multiple sites around the head. Similar computing to CT scanning provides a two-dimensional image depicting the radioactivity emitted from each 'pixel'. This gives improved definition and localisation. Various ligands have been developed but a ^{99m}Tc^m labelled derivative of propylamine oxime (MHPAO) is the most frequently used. This tracer represents *cerebral blood flow* since it rapidly diffuses across the blood brain barrier, becomes trapped within the cells, and remains long enough to allow time for scanning. Of the total injected dose, 5% is taken up by the brain and 86% of this activity remains in the brain at least 24 hours.

Ligands for SPECT scanning	Purpose
HMPAO	- Cerebral blood flow
¹²³ I IBZM	- Dopamine D2 receptors
¹²³ I Iomazenil	- Benzodiazepine receptors
¹²³ I CNB	- Cholinergic receptors
¹²³ I MK801	- Glutamate receptors
¹²³ I tyrosine	- Amino-acid uptake (e.g. in tumours)

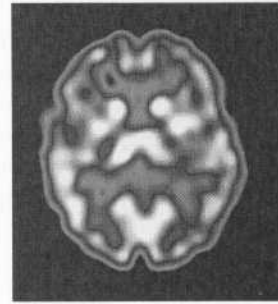
A rotating gamma camera is often used for detection, although new multidetector systems will produce higher quality images. Data are normally reconstructed to give axial images but coronal and sagittal can also be produced.



RADIONUCLIDEOTIDE IMAGING

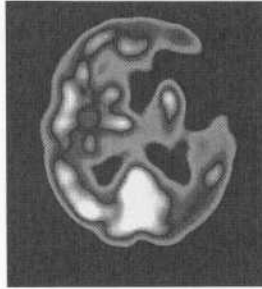Single photon emission computed tomography (SPECT) (contd)

The normal scan – HMPAO (10 mm resolution)
The tomogram is examined in conjunction with structural imaging (CT or MRI) to aid interpretation.

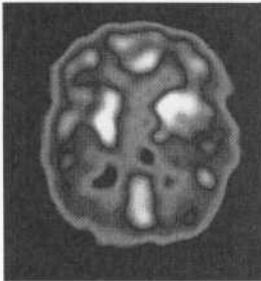


Clinical application

– Detection of early ischaemia in **OCCLUSIVE and HAEMORRHAGIC CEREBROVASCULAR DISEASE**



Absence of blood flow corresponds with area of infarction and tissue loss seen on structural imaging.



– Assessment of blood flow changes in **DEMENTIA**
Blood flow is generally reduced, especially in temporal and parietal lobes

– Evaluation of patients with intractable **EPILEPSY** of temporal lobe origin

Normal subject

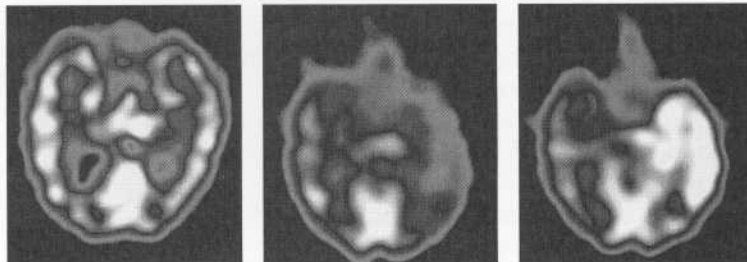Scan of temporal lobe showing symmetrical pattern of blood flow more prominent in grey matter

Patient with temporal lobe epilepsy

An *interictal* scan shows reduced flow throughout the temporal lobe

An *ictal* scan (i.e. HMPAO injected during the seizure) shows a marked hyperperfusion of the temporal lobe

The plane of scan lies in the same axis as the temporal lobe



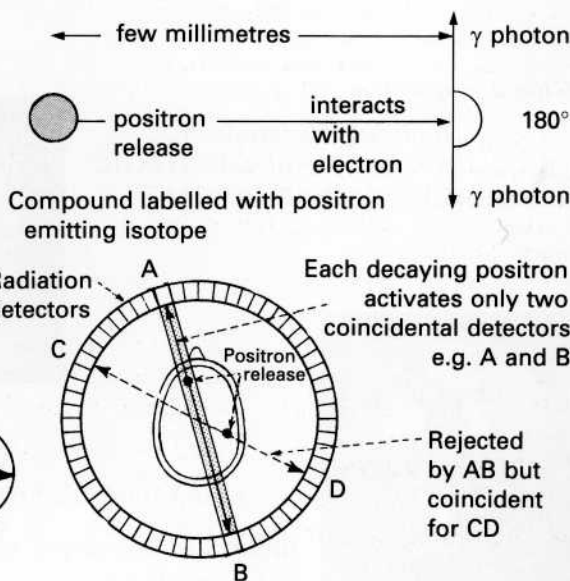
Such findings aid localisation of the epileptic focus and selection of patients for surgical treatment.

RADIONUCLEOTIDE IMAGING

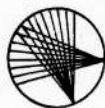Positron emission tomography (PET)

This new technique utilises positron-emitting isotopes (radionuclides) bound to compounds of biological interest to study specific physiological processes quantitatively. Positron-emitting isotopes depend on a cyclotron for production and their half-life is short, thus PET scanners only exist on adjacent sites. This limits availability for routine clinical use but PET scanners provide valuable research information.

Each decaying positron results in the release of two photons in diametric opposition; these activate two coincidental detectors. Multiple pairs of detectors and computer processing techniques enable quantitative determination of local radio-activity (and density of the labelled compound) for each 'voxel' (a cube of tissue) within the imaged field. Reconstruction using similar imaging techniques to CT scanning produces the positron emission scan.



Each detector is linked to several others in a fan shaped distribution

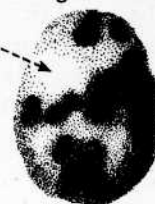

Isotope	Binding compound		Measurement under study
¹⁵ Oxygen	Carbon monoxide	- inhalation	Cerebral blood volume (CBV)
¹⁵ Oxygen	Water	- i.v. bolus	Cerebral blood flow (CBF)
¹⁸ Fluorine	Fluorodeoxyglucose	- i.v. bolus	Cerebral glucose metabolism (CMRgl)
¹⁵ Oxygen	Oxygen	- inhalation	Cerebral oxygen utilisation (CMRO ₂) Oxygen extraction factor (OEF)
¹¹ Carbon	Drug, e.g. phenytoin	- i.v. bolus	Drug receptor site
¹¹ Carbon	Methyl spiperone	- i.v. bolus	Dopamine binding site

Clinical and research uses

PET scanning is of particular value in elucidating the relationships between cerebral blood flow, oxygen utilisation and extraction in focal areas of ischaemia or infarction (page 237) and has been used to study patients with dementia, epilepsy and brain tumours. Identification of neurotransmitter and drug receptor sites has aided the understanding and management of psychiatric (schizophrenia) and movement disorders.

PET scan several days after a left middle cerebral infarct showing a reduction in blood flow



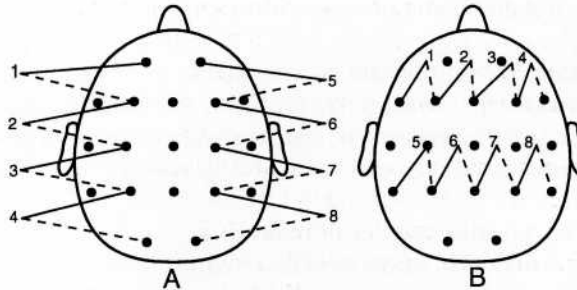
Oxygen utilisation is also reduced with a slight increase in oxygen extraction

ELECTROENCEPHALOGRAPHY (EEG)

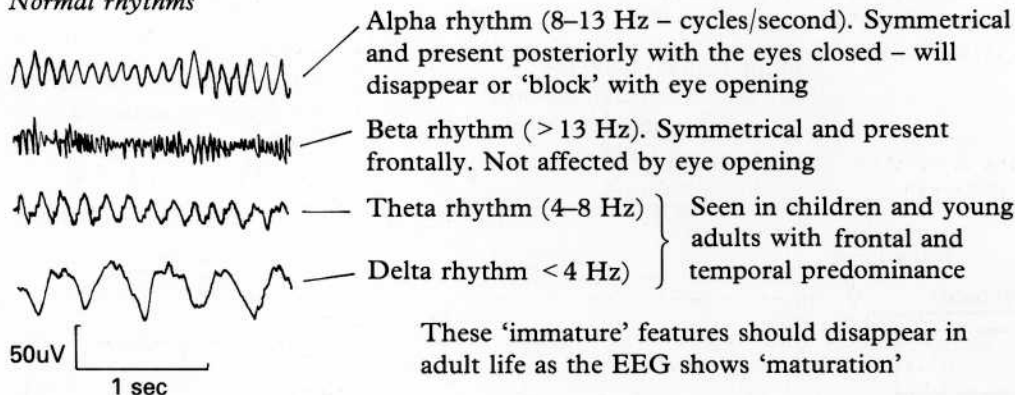
Electroencephalography examines by means of scalp electrodes the spontaneous electrical activity of the brain. Tiny electrical potentials, which measure millionths of volts, are recorded, amplified and displayed on either 8 or 165 channels of a pen recorder. Low and high frequency filters remove unwanted signals such as muscle artefact and mains interference.

The system of electrode placement is referred to as the 10/20 system because the distance between bony points, i.e. inion to nasion, is divided into lengths of either 10% or 20% of the total, and the electrodes placed at each distance.

A switch changes recording from A (parasagittal) to B (transverse). Other electrode arrangements are also 'preset'. The numbering indicates the write out from top to bottom of an 8-channel record.



Normal rhythms



These 'immature' features should disappear in adult life as the EEG shows 'maturation'

As well as recording a resting EEG using various 'preset' electrode arrangements, stressing the patient by hyperventilation and photic stimulation (a flashing strobe light) may result in an electrical discharge supporting a diagnosis of epilepsy.

More advanced methods of telemetry and foramen ovale recording may be necessary

- to establish the diagnosis of 'epilepsy' if doubt remains
- to determine the exact frequency and site of origin of the attacks
- to aid classification of seizure type.

Telemetry: utilises a continuous 24–48 hour recording of EEG, often combined with a videotape recording of the patient.

Foramen ovale recording: a needle electrode is passed percutaneously through the foramen ovale to record activity from the adjacent temporal lobe.

Magnetoencephalography

A new technique which measures changes in the magnetic field generated by the brain's electrical activity. It allows detection of the depth and location of current changes with better temporal and spatial resolution than the EEG.

INTRACRANIAL PRESSURE MONITORING

Although CSF pressure may be measured during lumbar puncture, this method is of limited value in intracranial pressure measurement:

An isolated pressure reading does not indicate the trend or detect pressure waves.

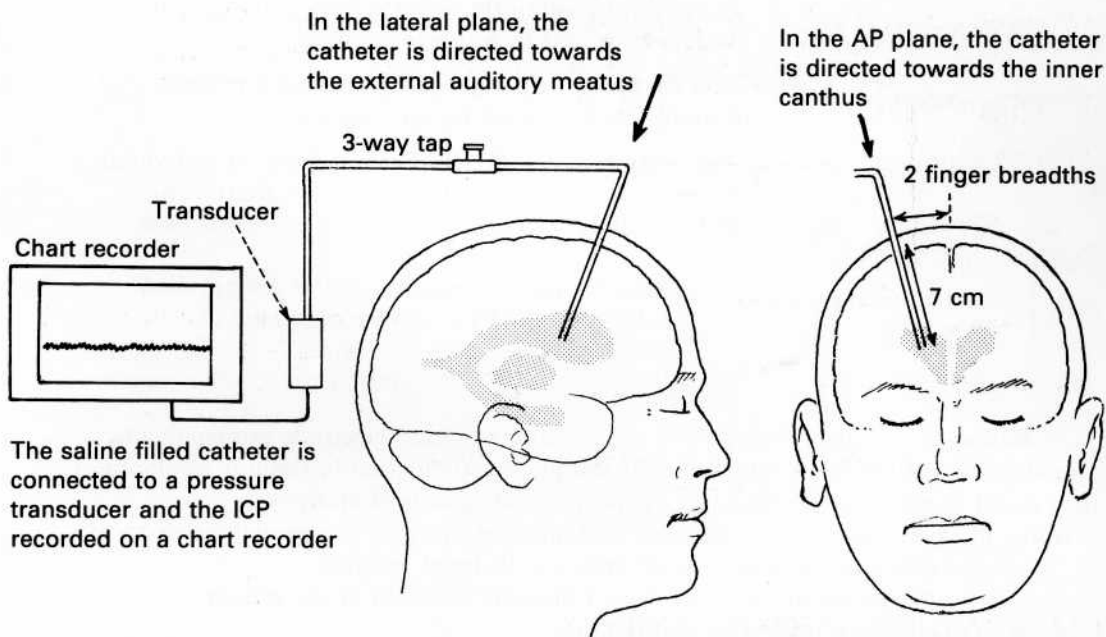
Lumbar puncture is contraindicated in the presence of an intracranial mass.

Pressure gradients exist between different intracranial and spinal compartments, especially in the presence of brain shift.

Many techniques are now available to measure intracranial pressure, including a *fibre-optic transducer (Camino)* inserted into the brain surface, or extra or intradural devices measuring pressure on the hemisphere surface, but a catheter inserted into the lateral ventricle remains the standard by which other methods are compared.

Ventricular catheter insertion

A ventricular catheter is inserted into the frontal horn of the lateral ventricle through a frontal burr hole or small drill hole situated two finger breadths from the midline, behind the hairline and anterior to the coronal suture.



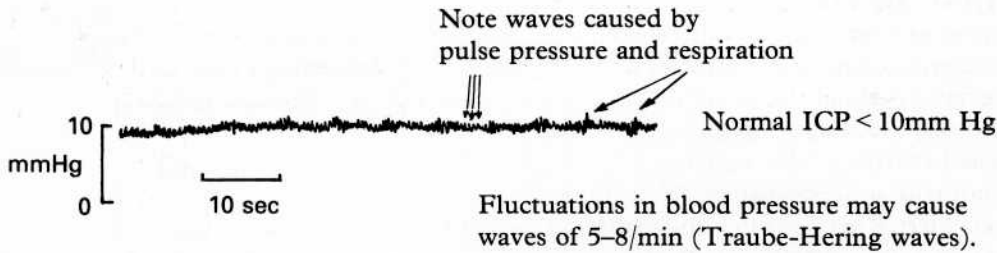
Complications

Intracerebral haemorrhage following catheter insertion rarely occurs.

Ventriculitis seldom occurs provided monitoring does not continue for more than three days.

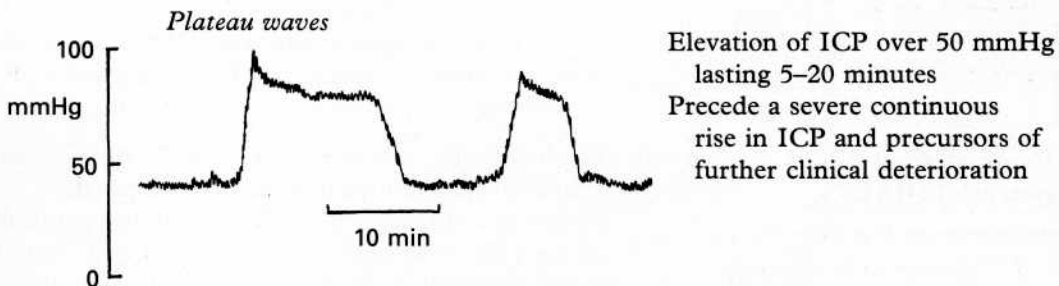
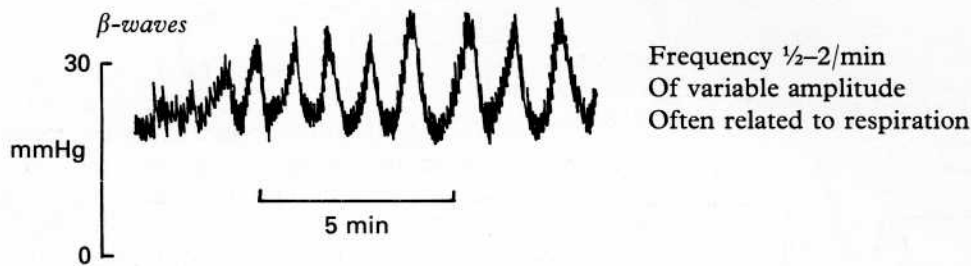
INTRACRANIAL PRESSURE MONITORING

NORMAL PRESSURE TRACE



ABNORMAL PRESSURE TRACE

Look for: Increase in the mean pressure – > 20 mmHg – moderate elevation
 > 40 mmHg – severe increase in pressure
 N.B. As ICP increases, the amplitude of the pulse pressure wave increases.



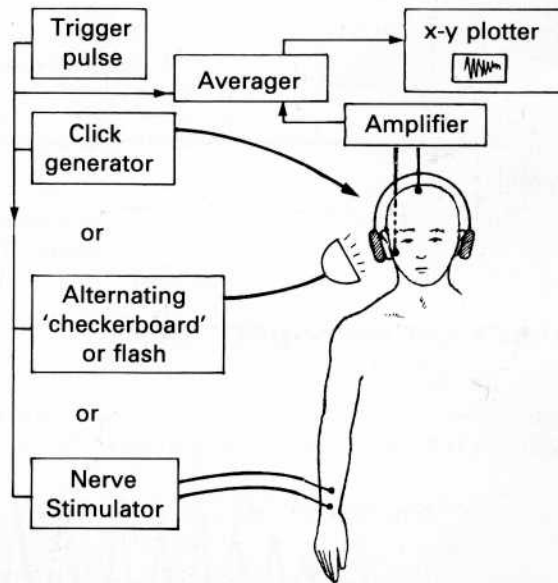
CLINICAL USES OF ICP MONITORING

- Investigation of normal pressure hydrocephalus – the presence of β waves for > 5% of a 24-hour period suggests impaired CSF absorption and the need for a drainage operation.
- Postoperative monitoring – a rise in ICP may precede clinical evidence of haematoma formation or cerebral swelling.
- Small traumatic haematomas – ICP monitoring may guide management and indicate the need for operative removal.
- ICP monitoring is required during treatment aimed at reducing a raised ICP and maintaining cerebral perfusion pressure.

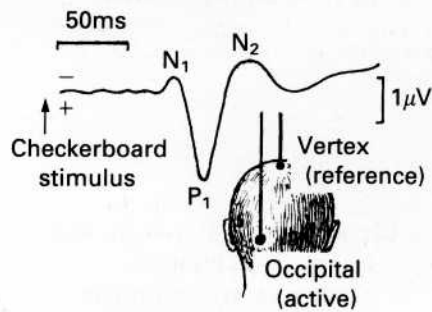
EVOKED POTENTIALS – VISUAL, AUDITORY AND SOMATOSENSORY

RECORDING METHODS

Stimulation of any sensory receptor evokes a minute electrical signal (i.e. microvolts) in the appropriate region of the cerebral cortex. Averaging techniques permit recording and analysis of this signal normally lost within the background electrical activity. When sensitive apparatus is triggered to record cortical activity at a specific time after the stimulus, the background electrical 'noise' averages out, i.e. random positive activity subtracts from random negative activity, leaving the signal evoked from the specific stimulus.



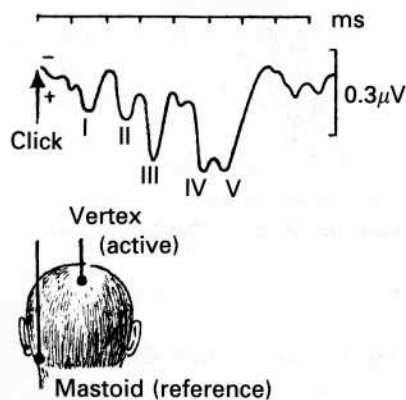
Visual evoked potential (VEP)



A stroboscopic flash diffusely stimulates the retina; alternatively an alternating checkerboard pattern stimulates the macula and produces more consistent results. The evoked visual signal is recorded over the occipital cortex. The first large positive wave (P_1) provides a useful point for measuring conduction through the visual pathways.

Uses: *Multiple sclerosis detection* – 30% with normal ophthalmological examination have abnormal VEP. *Peroperative monitoring* – pituitary surgery.

Brain stem auditory evoked potential (BAEP)

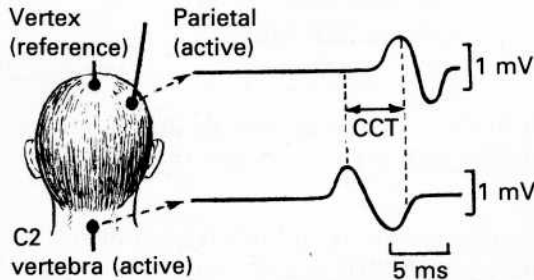


Electrical activity evoked in the first 10 milliseconds after a 'click' stimulus provides a wave pattern related to conduction through the auditory pathways in the VIII nerve and nucleus (waves I and II) and in the pons and midbrain (waves III-V). Longer latency potentials (up to 500 ms), recorded from the auditory cortex in response to a 'tone' stimulus, are of less clinical value.

Uses: *Hearing assessment* – especially in children. *Detection of intrinsic and extrinsic brain stem and cerebellopontine angle lesions*, e.g. acoustic tumours. *Peroperative recording* during acoustic tumour operations. *Assessment of brain stem function in coma.*

EVOKED POTENTIALS – SOMATOSENSORY

Somatosensory evoked potentials (SEP)



The sensory evoked potential is recorded over the parietal cortex in response to stimulation of a peripheral nerve (e.g. median nerve). Other electrodes sited at different points along the sensory pathway record the ascending activity. Subtraction of the latencies between peaks provides conduction time between these sites.

Central conduction time (CCT): sensory conduction time from the dorsal columns (or nuclei) to the parietal cortex.

Uses: *Detection of lesions in the sensory pathways* – brachial plexus injury
 – spinal cord and brainstem tumours or demyelination.

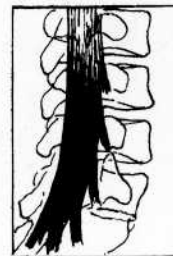
Peroperative recording – straightening of scoliosis
 – removal of spinal tumours/AVM } – spinal conduction
 – aneurysm operation with temporary vessel occlusion – CCT.

Motor Evoked Potential (MEP)

Subtraction of the latencies between motor evoked potentials elicited by applying a brief magnetic stimulus to either the motor cortex, the spinal cord or the peripheral nerves gives *peripheral* and *central motor conduction velocities*. The use of MEP in clinical practice awaits further evaluation.

MYELOGRAPHY

Injection of water-soluble contrast into the lumbar theca and imaging flow up to the cervicomedullary junction provides a rapid (although invasive) method of screening the whole spinal cord and cauda equina for compressive lesions (e.g. disc disease or spondylosis, tumours, abscesses or cysts). For suspected lumbosacral disc disease, contrast is screened up to the level of the conus i.e. **RADICULOGRAPHY** (but a normal study does not exclude the possibility of a laterally situated disc). CT scanning and MRI have gradually replaced the need for myelography, but the introduction of a low dose of water-soluble contrast considerably enhances axial CT scan images of the spinal cord and nerve roots.



Oblique view

Note contrast filling the nerve roots.

Problems

Headache occurs in 30%, *nausea* and *vomiting* in 20% and *seizures* in 0.5%.

Arachnoiditis – previously a major complication with oil based contrast MYODIL, but rarely occurs with water soluble contrast.

Subdural injection (accidental) – prevents correct interpretation.

Haematoma – occurs rarely at the injection site.

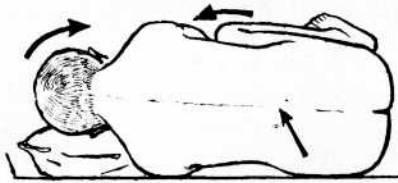
Impaction of spinal tumour – may follow CSF escape and aggravate the effects of cord compression, leading to clinical deterioration.

LUMBAR PUNCTURE

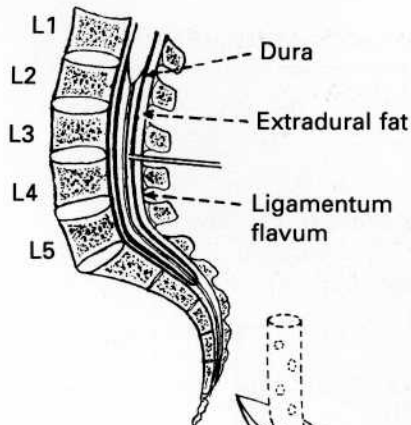
- Lumbar puncture permits:
- acquisition of cerebrospinal fluid for analysis.
 - CSF drainage and pressure reduction, e.g. in communicating hydrocephalus/CSF fistula.

TECHNIQUE

1. *Correct positioning of the patient is essential.* Open the vertebral laminae by drawing the knees up to the chest and flexing the neck. Ensure the back is perpendicular to the bed to avoid rotation of the spinal column.
2. Identify the site. The L3/4 space lies level with the iliac crests and this is most often used, but since the spinal cord ends at L1 any space from L2/L3 to L5/S1 provides a safe approach.
3. Clean the area and insert a few millilitres of local anaesthetic.



4. Ensure the stylet of a 20G lumbar puncture needle is fully home (22G for children) and insert at a slight angle towards the head, so that it parallels the spinous processes. Some resistance is felt as the needle passes through the ligamentum flavum, the dura and arachnoid layers.



5. Withdraw the stylet and collect the CSF. If bone is encountered, withdraw the needle and reinsert at a different angle. If the position appears correct yet no CSF appears, rotate the needle to free obstructive nerve roots.

A similar technique employing a TUOHY needle allows insertion of intra- or epidural cannula (for CSF drainage or drug instillation) or stimulating electrodes (for pain management).

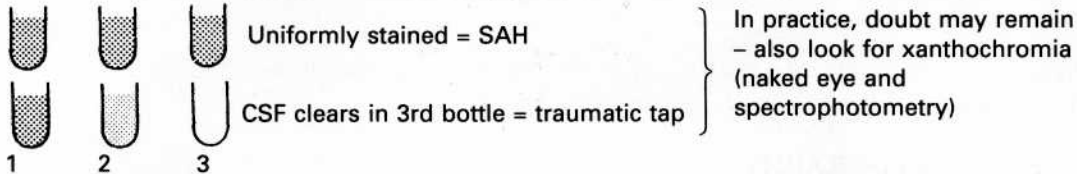
Avoid lumbar puncture

- if raised intracranial pressure is suspect. Even a fine needle leaves a hole through which CSF will leak. In the presence of a space-occupying lesion, especially in the posterior fossa, CSF withdrawal creates a pressure gradient which may precipitate tentorial herniation.
- if platelet count is less than 40,000 and prothrombin time is less than 50% of control.

CEREBROSPINAL FLUID

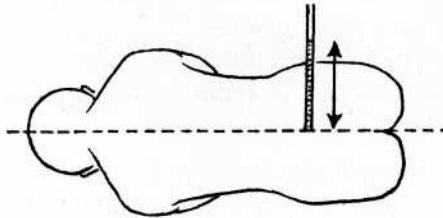
CSF COLLECTION

Subarachnoid haemorrhage (SAH), or puncture of a blood vessel by the needle, may account for blood stained CSF. To differentiate, collect CSF in three bottles.



CSF PRESSURE MEASUREMENT

Check that the patient's head (foramen of Munro) is level with the lumbar puncture. Connect a manometer via a 3-way tap to the needle and allow CSF to run up the column. Read off the height. Normal value: 100–150 mm CSF.



CSF ANALYSIS

Standard tests

1. Bacteriological
 - RBC and differential WBC (normal = < 5 WBCs per mm³)
 - Gram stain and culture
 - appearance of supernatant. Xanthochromia (yellow staining) results from subarachnoid haemorrhage with RBC breakdown, high CSF protein or jaundice.
2. Biochemical
 - protein (normal = 0.15–0.45 g/l)
 - glucose (normal = 0.45–0.70 g/l) 40–60% of blood glucose simultaneously sampled.

Special tests

Suspected:

- Malignant tumour
 - cytology
- Tubercle
 - Ziehl-Neelson stain, Lowenstein-Jensen culture
- Non-bacterial infection
 - virology, fungal and parasitic studies
- Demyelinating disease
 - oligoclonal bands
- Neurosyphilis
 - VDRL (Venereal Disease Research Laboratory) test
 - FTA-ABS (Fluorescent treponemal antibody absorption) test
 - Treponema pallidum immobilisation test (TPI)
- Cryptococcus
 - culture and antigen detection
- HIV
 - culture, antigen detection and antiviral antibodies (anti-HIV-IgG).

Complications

- tonsillar herniation (see page 77)
- transient headache (10%), radicular pain (10%), or ocular palsy (1%)
- epidural haemorrhage very rare.

ELECTROMYOGRAPH/NERVE CONDUCTION STUDIES

Needle electromyography records the electrical activity occurring within a particular muscle.

Nerve conduction studies measure conduction in nerves in response to an electrical stimulus.

Both are essential in the investigation of diseases of nerve (neuropathy) and muscle (myopathy).


Repetitive nerve stimulation tests are important in the evaluation of disorders of neuromuscular transmission, e.g. myasthenia gravis.

ELECTROMYOGRAPHY

A concentric needle electrode is inserted into muscle. The central wire is the active electrode and the outer casing the reference electrode. This records from an area of $300\mu\text{r}$ adius.

The potential difference between the two electrodes is amplified and displayed on an oscilloscope. An audio monitor enables the investigator to 'hear' the pattern of electrical activity.

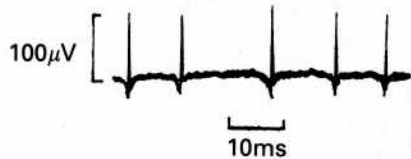Normal muscle at rest is electrically 'silent' with a resting potential of 90 mV; as the muscle gradually contracts, *motor unit potentials* appear . . . followed by the development of



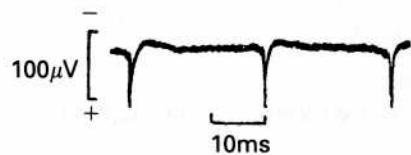The recruitment of more and more motor units prevents identification of individual potentials

Abnormalities take the form of:
 Spontaneous activity in muscle when at rest.
 Abnormalities of the motor unit potential.
 Abnormalities of the interference pattern.
 Special phenomena, e.g. myotonia.

Spontaneous activity at rest



Fibrillation potentials are due to single muscle fibre contraction and indicate active denervation. They usually occur in neurogenic disorders, e.g. neuropathy.



Slow negative waves preceded by sharp positive spikes. Seen in chronically denervated muscle, e.g. motor neuron disease, but also in acute myopathy, e.g. polymyositis. These waves probably represent injury potentials.

ELECTROMYOGRAPHY/NERVE CONDUCTION STUDIES


Abnormalities (contd)

Motor unit potential

In myopathies and muscular dystrophies, potentials are polyphasic and of small amplitude and short duration.



In neuropathy, the surviving motor unit potentials are also polyphasic but of large amplitude and long duration.



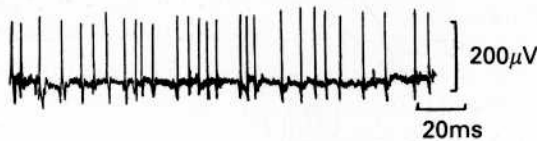
The enlarged potentials result from collateral reinnervation.

Interference pattern

In myopathy, recruitment of motor units and the interference pattern remain normal. The interference pattern may even appear to increase due to fragmentation of motor units.



In neuropathy, there is a reduction in interference due to a loss of motor units under voluntary control.



Myotonia

High frequency repetitive discharge may occur after voluntary movement. The amplitude and frequency of the potentials wax and wane giving rise to the typical 'dive bomber' sound on the audio monitor.



An abnormal myotonic discharge provoked by moving the needle electrode.

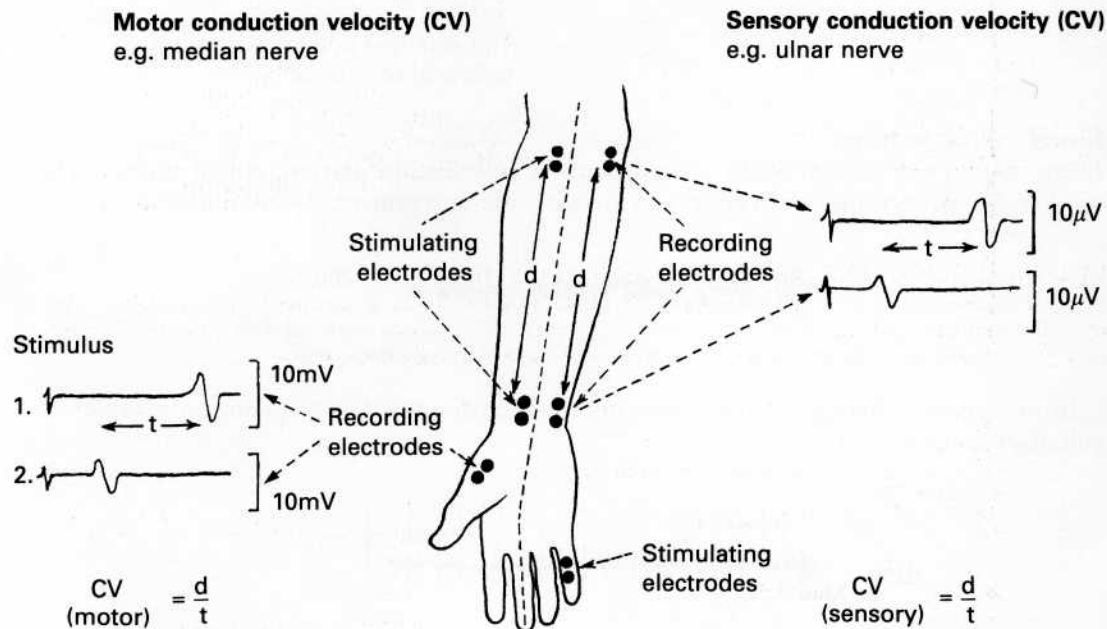
ELECTROMYOGRAPHY/NERVE CONDUCTION STUDIES

NERVE CONDUCTION STUDIES

Distal latency (latency from stimulus to recording electrodes), *amplitude* of the evoked response and *conduction velocity* all provide information on motor and sensory nerve function.

Conduction velocity: measurement made by stimulating or recording from two different sites along the course of a peripheral nerve.

$$\frac{\text{Distance between two sites}}{\text{Difference in conduction times between two sites}} = \text{Conduction velocity}$$



Normal values (motor)

Ulnar and median nerves – 50–60 m/s
Common peroneal nerve – 45–55 m/s

Normal values (sensory)

Ulnar and median nerves – 60–70 m/s
Common peroneal nerve – 50–70 m/s

Motor conduction velocities slow with age.

Body temperature is important; a fall of 1°C slows conduction in motor nerves by approximately 2 metres per second.

Pathological delay occurs with nerve entrapments, demyelinating neuropathies (Guillain Barré syndrome) and multifocal motor neuropathy.

ELECTROMYOGRAPHY/NERVE CONDUCTION STUDIES

REPETITIVE STIMULATION

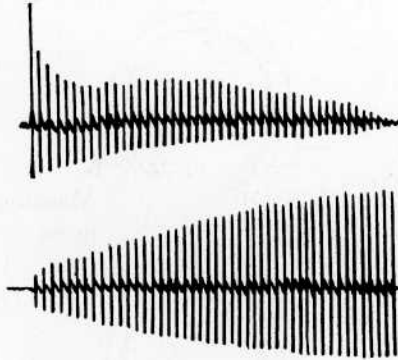
In the normal subject, repetitive stimulation of a motor nerve at a frequency of $< 30/\text{sec}$ produces a muscle potential of constant form and amplitude. Increasing the stimulus frequency to $> 30/\text{second}$ results in fatigue manifest by a decline or 'decrement' in the amplitude. In patients with disorders of neuromuscular transmission, repetitive stimulation aids diagnosis:

Myasthenia gravis

A decrementing response occurs with a stimulus rate of 3–5/second.


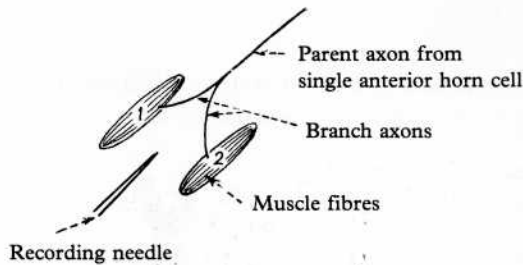
Myasthenic (Eaton Lambert) syndrome

With a stimulation rate of 20–50/second (i.e. rapid) a small amplitude response increases to normal amplitude – incrementing response.

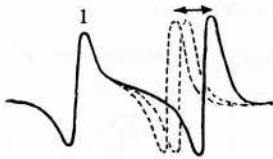


SINGLE FIBRE ELECTROMYOGRAPHY

A standard concentric needle within muscle will record electrical activity 0.5–1 mm from its tip – sampling from up to 20 motor units. A 'single fibre' electromyography needle with a smaller recording surface detects electrical activity within 300 μm of its tip – sampling 1–3 muscle fibres from a single motor unit.



Action potentials recorded from two muscle fibres are not synchronous. The gap between each is variable and can be measured if the first recorded potential is 'locked' on the oscilloscope.



This variability is referred to as JITTER – normally 20–25 μs (2–5 μs due to transmission in the branch axon – 15–20 μs to variation in neuromuscular transmission).

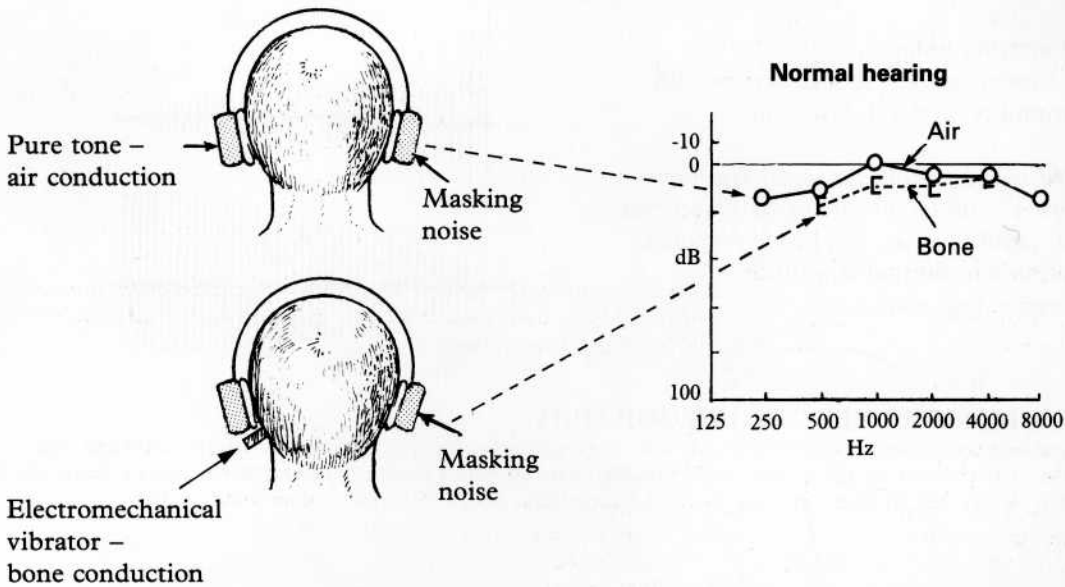
Single fibre electromyography is occasionally helpful in the investigation of disorders of neuromuscular transmission. In ocular myasthenia, the affected muscles are not accessible and frontalis is sampled instead.

NEURO-OTOLOGICAL TESTS

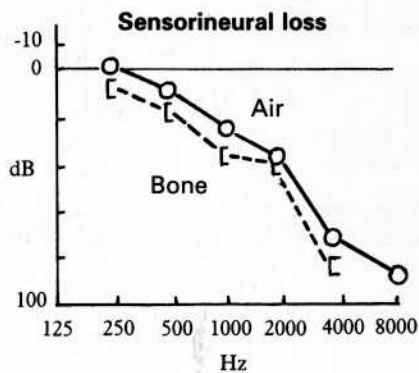
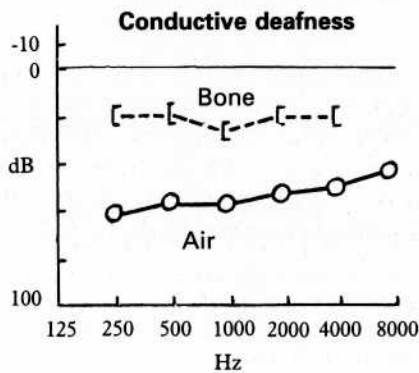
AUDITORY SYSTEM

Neuro-otological tests help differentiate conductive, cochlear and retrocochlear causes of impaired hearing. They supplement Weber's and Rinne's test (page 16).

PURE TONE AUDIOMETRY Thresholds for air and bone conduction are measured at different frequencies from 250 Hz to 8k Hz.




Sound conducted through air requires an intact ossicular system as well as a functioning cochlea and VIII nerve. Sound applied directly to the bone bypasses the ossicles.



NEURO-OTOLOGICAL TESTS

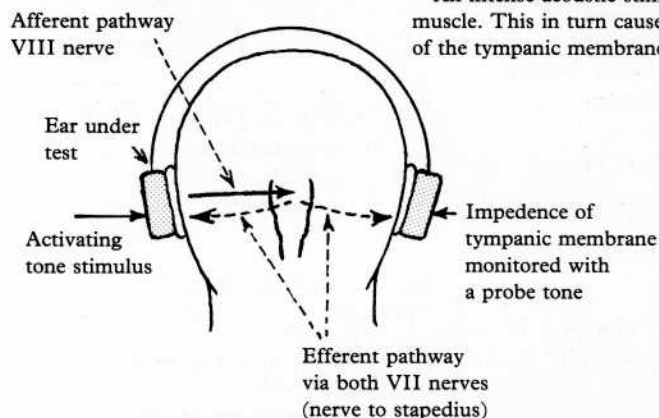
SPEECH AUDIOMETRY

This test measures the percentage of words correctly interpreted as a function of the intensity of presentation and indicates the usefulness of hearing. The graph shows how different types of hearing loss can be differentiated.



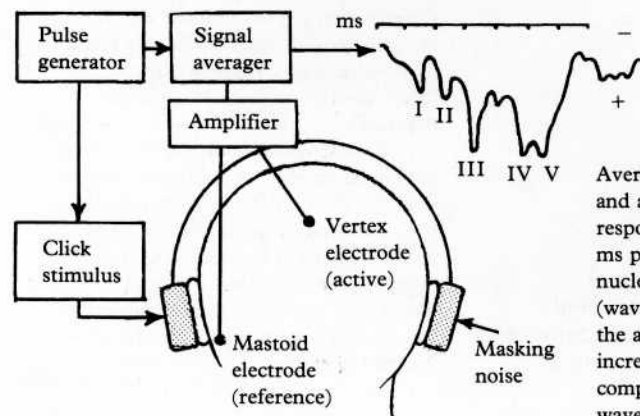
STAPEDIAL REFLEX DECAY

An intense acoustic stimulus causes reflex contraction of the stapedius muscle. This in turn causes reduced compliance (increased impedance) of the tympanic membrane.



Rapid decay of the reflex response suggests a lesion of the auditory nerve

AUDITORY BRAINSTEM EVOKED POTENTIAL



Averaging techniques (page 52) permit the recording and analysis of small electrical potentials evoked in response to auditory stimuli. Activity in the first 10 ms provides information about the VIII nerve and nucleus (waves I and II) and the pons and midbrain (waves III - V). Lesions of the VIII nerve diminish the amplitude and/or the latency of wave I or II and increase the wave I to V interpeak latency. In comparison, cochlear lesions seldom affect either wave pattern or latency.

NEURO-OTOLOGICAL TESTS

VESTIBULAR SYSTEM

Caloric testing (vestibulo-ocular reflex)

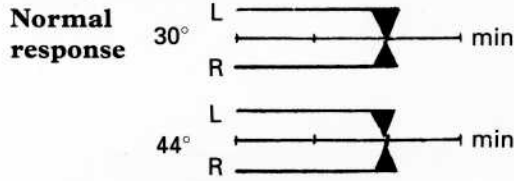
Compensatory mechanisms may mask clinical evidence of vestibular damage – spontaneous and positional nystagmus. Caloric testing provides useful supplementary information and may reveal undetected vestibular dysfunction.

Method: Water at 30°C irrigated into the external auditory meatus. Nystagmus usually develops after a 20 second delay and lasts for more than a minute. The test is repeated after 5 minutes with water at 44°C.

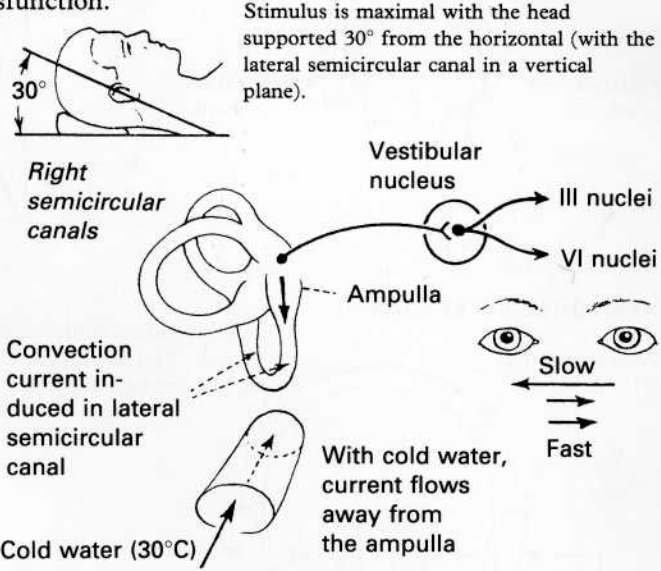
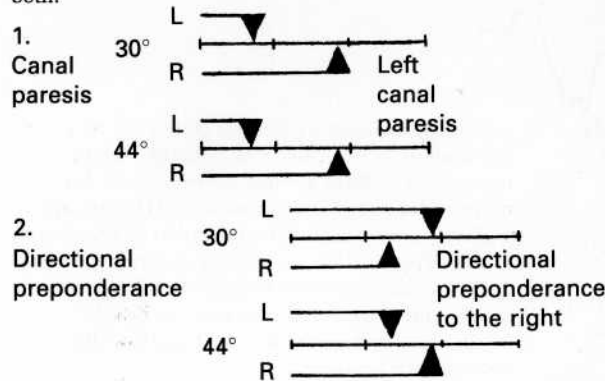
Cold water effectively reduces the vestibular output from one side, creating an imbalance and producing eye drift towards the irrigated ear. Rapid corrective movements result in 'nystagmus' to the opposite ear. Hot water (44°) reverses the convection current, increases the vestibular output and changes the direction of nystagmus.

N.B. Ice water ensures a maximal stimulus when caloric testing for brain death or head injury prognostication.

Time from onset of irrigation to the cessation of nystagmus is plotted for each ear, at each temperature



Damage to the labyrinth, vestibular nerve or nucleus results in one of two abnormal patterns, or a combination of both.



Stimulus is maximal with the head supported 30° from the horizontal (with the lateral semicircular canal in a vertical plane).

Electronystagmography: The potential difference across the eye (the corneoretinal potential) permits recording of eye movements with laterally placed electrodes and enables detection of spontaneous or reflex induced nystagmus in darkness or with eyes closed.

This eliminates optical fixation which may reduce or even abolish nystagmus. *Canal paresis* implies reduced duration of nystagmus on one side. It may result from either a peripheral or central (brain stem or cerebellum) lesion on that side.

Directional preponderance implies a more prolonged duration of nystagmus in one direction than the other. It may result from a central lesion on the side of the preponderance or from a peripheral lesion on the other side.

These tests combined with audiometry should differentiate a peripheral from a central lesion.

**CLINICAL PRESENTATION
ANATOMICAL CONCEPTS AND
DIAGNOSTIC APPROACH**

HEADACHE – DIAGNOSTIC APPROACH

History: most information is derived from determining:

- the first attack or previous attacks
- whether onset is acute or gradual (days or weeks)
- whether attacks have recurred for many years (chronic)
- site of headache
- accompanying symptoms
- precipitating factors

The following table classifies causes in these categories:

Cause	Associated features which (if present) aid diagnosis	RECURRENT ATTACKS	Further investigations (if required)
ACUTE			
<i>Sinusitis</i>	Preceding 'cold' nasal discharge	*	X-ray nasal sinuses
<i>Migraine</i>	Visual/neurological aura, nausea, vomiting	*	
<i>Cluster headache</i>	Lacrimation, rhinorrhoea	*	
<i>Glaucoma</i>	'Misting' of vision 'haloes' around objects	*	Ophthalmological referral
<i>Retrolbulbar neuritis</i>	Loss of vision (unilateral)		Visual evoked response
<i>Post-traumatic</i>	Following head injury		Skull X-ray, CT scan
<i>Drugs/toxins</i>	On vasodilator drugs		
<i>Haemorrhage</i>	Instantaneous onset vomiting, neck stiffness impaired conscious level		} CT scan, lumbar puncture (see page 54)
<i>Infection (meningitis, encephalitis)</i>	As above but more gradual onset with pyrexia	*	
<i>Hydrocephalus</i>	Impaired conscious level, leg weakness impaired upward gaze	* (if CSF fistula)	CT scan
SUBACUTE			
<i>Infection (subacute, chronic meningitis, e.g. TB cerebral abscess)</i>	Impaired conscious level, pyrexia, neck stiffness, focal neurological signs		CT scan lumbar puncture
<i>Intracranial tumour</i>	} Vomiting, papilloedema, impaired conscious level ± focal neurological signs	*	CT scan
<i>Chronic subdural haematoma</i>			
<i>Hydrocephalus</i>			
<i>Benign intracranial hypertension</i>	Vomiting, papilloedema	*	CT scan, CSF pressure monitoring
<i>Temporal arteritis</i>	Thickened, tender, scalp arteries		ESR, temporal artery biopsy
CHRONIC			
<i>Tension-type headache</i>	Anxiety, depression	*	
<i>Ocular 'eye strain'</i>	Impaired visual acuity	*	Refractive errors
<i>Drugs/toxins</i>	On vasodilator drugs		
<i>Cervical spondylosis</i>	Neck, shoulder, arm pain	*	X-ray cervical spine

HEADACHE – DIAGNOSTIC APPROACH

Headache in children

All causes of adult headache (except in retrobulbar neuritis, glaucoma, temporal arteritis and cervical spondylosis) may cause headache in children. In this age group, the commonest type of headache is that accompanying any *febrile illness* or *infection of the nasal passages or sinuses*.

The clinician must not take a complaint of headache lightly; the younger the child, the more likely the presence of an underlying organic disease. Pyrexia may not only represent a mild 'constitutional' upset, but may result from *meningitis*, *encephalitis* or *cerebral abscess*. The presence of neck stiffness and/or impaired conscious level indicates the need for urgent investigation.

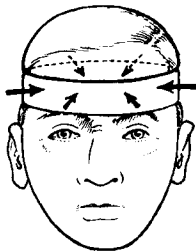
Although *intracranial tumours* are uncommon in childhood, when they occur they tend to lie in the *midline* (e.g. medulloblastoma, pineal region tumours.) As a result, obstructive hydrocephalus often develops acutely with headache as a prominent initial symptom.

In a child with 'unexplained' headache, *CT scan* should be performed:

- if the presentation is acute
- if the severity progressively increases
- if school performance declines, or other symptoms, e.g. personality change, develop
- if the head circumference increases
- if the child is under 5 years.

HEADACHE – SPECIFIC CAUSES

TENSION TYPE HEADACHE



This is the commonest form of headache experienced by 70% of males and 90% of females at some time in their lives.

Characteristics: Diffuse, dull, aching, 'band-like' headache, worse on touching the scalp and aggravated by noise; associated with 'tension' but not with other physical symptoms.

Duration: Many hours – days.

Frequency: Infrequent or daily; worse towards the end of the day. May persist over many years.

Mechanism: 'Muscular' due to persistent contraction, e.g. clenching teeth, head posture, frowning of brow.

Treatment: Reassurance
Attempt to reduce psychological stress
Benzodiazepines, e.g. diazepam (short course)
Antidepressants.

HEADACHE – SPECIFIC CAUSES

MIGRAINE

Migraine is a common, often familial disorder characterised by *unilateral throbbing headache*.

Onset: Childhood or early adult life.

Incidence: Affects 5–10% of the population.

Female: male ratio: 2:1

Family history: Obtained in 70% of all sufferers.

Two recognisable forms exist:

MIGRAINE WITH AURA

An *aura* or warning of visual, sensory or motor type followed by headache – throbbing, unilateral, worsened by bright light, relieved by sleep, associated with nausea and, occasionally, vomiting.

MIGRAINE WITHOUT AURA (COMMON MIGRAINE)

The *aura* is absent. The headache has similar features, but it is often poorly localised and its description may merge with that of 'tension' headache.

The aura of migraine may take many forms. The visual forms comprise: flashing lights, zig-zags (fortifications), scintillating scotoma (central vision) and may precede visual field defects. Such auras are of visual (occipital) cortex origin.

The headache is paroxysmal, lasting from 2 to 48 hours and rarely occurring more frequently than twice weekly. In *migraine equivalents* the aura occurs without ensuing headache.

Mechanism

Whether migraine is primarily a VASCULAR or NEURONAL disorder remains controversial. Chemical neurotransmitters, 5 hydroxytryptamine (5HT syn. serotonin) and noradrenaline seem responsible for controlling the diameter of extra- and intracranial blood vessels.

SPECIFIC TYPES OF MIGRAINE WITH AURA

Basilar: Characterised by bilateral visual symptoms, unsteadiness, dysarthria, vertigo, limb paraesthesia, even tetraparesis. Loss of consciousness may ensue and precede the onset of headache. This form of migraine affects young women.

Hemiplegic: Characterised by an aura of unilateral paralysis (hemiplegia) which unusually persist for some days after the headache has settled. Often misdiagnosed as a 'stroke'. When familial, mendelian dominant inheritance is noted. Recovery is the rule.

Ophthalmoplegic: Characterised by extraocular nerve palsies, usually the IIIrd, rarely the VIth. These may result from dilatation of the internal carotid artery with stretching of the III or VI cranial nerve within the cavernous sinus.

Rarely migraine can present as episodic coma – **MIGRAINE COMA**.

HEADACHE – SPECIFIC CAUSES

Precipitating factors in migraine

- Dietary: alcohol, chocolate and cheese (contain tyramine).
- Hormonal: often premenstrual or related to oral contraceptive (fluctuations in oestrogen).
- Stress, physical fatigue, exercise, sleep deprivation and minor head trauma.

Diagnosis

Clinical history with – occasional positive family history

- travel sickness or migraine variants (abdominal pains) in childhood
- onset in childhood, adolescence, early adult life or menopause

Distinguish from: – partial (focal) epilepsy (in hemiplegic or hemisensory migraine)

- aneurysm compressing III cranial nerve (in ophthalmoplegic migraine)
- transient ischaemic attack (in hemiplegic or hemisensory migraine)
- arteriovenous malformation – gives well localised but chronic headache
- hypoglycaemia

Management

- (i) Identification and avoidance of precipitating factors
- (ii) Prophylaxis: use only for frequent and severe attacks

Pizotifen (5HT₂ receptor blocker)

Propranolol (beta adrenergic receptor blocker)

Methysergide (5HT₂ receptor blocker) – use with caution in view of side effects, e.g. retroperitoneal fibrosis.

In resistant cases, use *calcium antagonists*, *antidepressants* and *anticonvulsants*.

- (iii) Treatment of an acute attack:

Simple *analgesics* (e.g. aspirin) with *metoclopramide* to enhance reduced absorption during an attack.

Sumatriptan (a selective 5HT₁ agonist) – effectively reverses dilatation in extracranial vessels. Given orally or subcutaneously.

Ergotamine – widespread action on 5HT receptors reversing dilatation. Give orally or by inhalation, injection or by suppository.

Methylprednisolone *i.m.* or *i.v.* will halt the attack when prolonged (status migrainosus).

CLUSTER HEADACHES (Histamine cephalgia or migrainous neuralgia)

Cluster headaches occur less frequently than migraine, and more often in men than women, with onset in middle age.

Characteristics: Severe unilateral pain around one eye, associated with conjunctival injection, lacrimation, rhinorrhea and occasionally a transient Horner's syndrome.

Duration: 10 minutes to 2 hours.

Frequency: Once to many times per day, often wakening from sleep at night. 'Clusters' of attacks separated by weeks or even many months. Alcohol may precipitate the attacks.

Mechanism: Serum histamine levels rise during the attacks, hence 'histamine cephalgia'.

Treatment: Antihistamines give disappointing results. *Ergotamine* and *sumatriptan* may give relief. Use *prednisolone* 30 mgs daily in refractory cases. For prevention, use

methysergide, *calcium channel blockers* or *lithium carbonate*.

HEADACHE – SPECIFIC CAUSES

POST-TRAUMATIC HEADACHE

A 'common migraine' or 'tension-like' headache may arise after head injury and accompany other symptoms including light-headedness, irritability, difficulty in concentration and in coping with work. Although once thought to have a purely 'psychological' origin, especially with impending litigation, it is now recognised that injuries severe enough to cause loss of consciousness or a period of post-traumatic amnesia result in some neuronal damage and abnormalities of evoked responses. A headache similar to migraine can occur after neck injury and responds to propranolol.

Treatment: As for tension headache.

GIANT CELL (TEMPORAL) ARTERITIS

Giant cell arteritis, an autoimmune disease of unknown cause, presents with headache in the elderly. This is severe and throbbing in nature and overlies the involved vessel – usually the superficial temporal artery, although the condition may affect any extra- or intracranial vessel.

Palpation reveals a thickened, tender, but nonpulsatile artery.

Neurological symptoms: strokes, hearing loss, myelopathy and neuropathy may result.

Jaw claudication: pain when chewing or talking due to ischaemia of the masseter muscles is pathognomonic and occurs in a high proportion of patients.

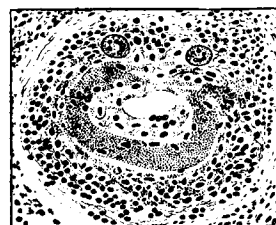
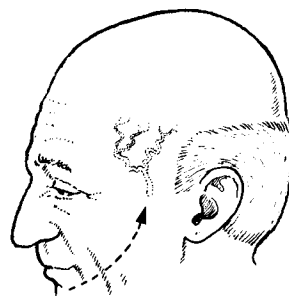
Visual symptoms are common with blindness (transient or permanent) or diplopia.

Associated systemic symptoms – weight loss, lassitude and generalised muscle aches – polymyalgia rheumatica in one-fifth of cases.

Duration: the headache is intractable, lasting until treatment commences.

Mechanism:

Large and medium-sized arteries undergo intense 'giant cell' infiltration, with fragmentation of the lamina and narrowing of the lumen, resulting in distal ischaemia as well as stimulating pain sensitive fibres. Occlusion of important end arteries, e.g. the ophthalmic artery, may result in blindness; occlusion of the basilar artery may cause brain stem or bilateral occipital infarction.



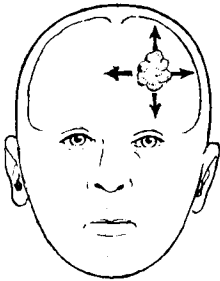
Thickened wall with giant cell infiltrate

Diagnosis: ESR usually high. Blood film shows anaemia or thrombocytosis. C-reactive protein and hepatic alkaline phosphatase elevated. Biopsy of 1 cm length of temporal artery is often diagnostic.

Treatment: Urgent treatment, prednisolone 60 mg daily, prevents visual loss or brain-stem stroke, as well as relieving the headache. If complications have already occurred e.g. blindness, give parenteral high dose steroids. Monitoring the ESR allows gradual reduction in steroid dosage over several weeks to a maintenance level, e.g. 5 mg daily. Most patients eventually come off steroids; 25% require long-term treatment and if so, complications commonly occur.

HEADACHE – SPECIFIC CAUSES

HEADACHE FROM RAISED INTRACRANIAL PRESSURE



Characteristics:

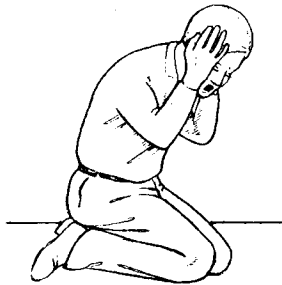- generalised.
- aggravated by bending or coughing.
- worse in the morning on awakening; may awaken patient from sleep.
- the severity of the headache gradually progresses.

Associated features:

- vomiting in later stages.
- transient loss of vision (obscuration) with sudden change in posture.
- eventual impairment of conscious level.

Management: further investigations are essential – CT or MRI

HEADACHE DUE TO INTRACRANIAL HAEMORRHAGE



Characteristics:

- instantaneous onset.
- severe pain, spreading over the vertex to the occiput, or described as a ‘sudden blow to the back of the head’.
- patient may drop to knees or lose consciousness.

Associated features:

- usually accompanied by vomiting.
- focal neurological signs suggest a haematoma.

Management: further investigation – CT scan/lumbar puncture (see Meningism, page 71).

NON-NEUROLOGICAL CAUSES OF HEADACHE

Local causes:

Sinuses: Well localised. Worse in morning. Affected by posture, e.g. bending.

X-ray – sinus opacified. Treatment – decongestants or drainage.

Ocular: Refraction errors may result in ‘muscle contraction’ headaches – resolves when corrected with glasses.

Glaucoma does not produce headache without other symptoms, e.g. misting of vision, ‘haloes’. Cupping seen on fundoscopy.

Dental disease: Discomfort localised to teeth. Check for malocclusion.

Check temporomandibular joints.

Systemic causes:

Headache may accompany any febrile illness or may be the presenting feature of accelerated hypertension or metabolic disease, e.g. hypoglycaemia, hypercalcaemia.

Many drugs produce headache

- through vasodilatation e.g. bronchodilators, antihistamines
- on withdrawal e.g. amphetamines, benzodiazepines, caffeine.

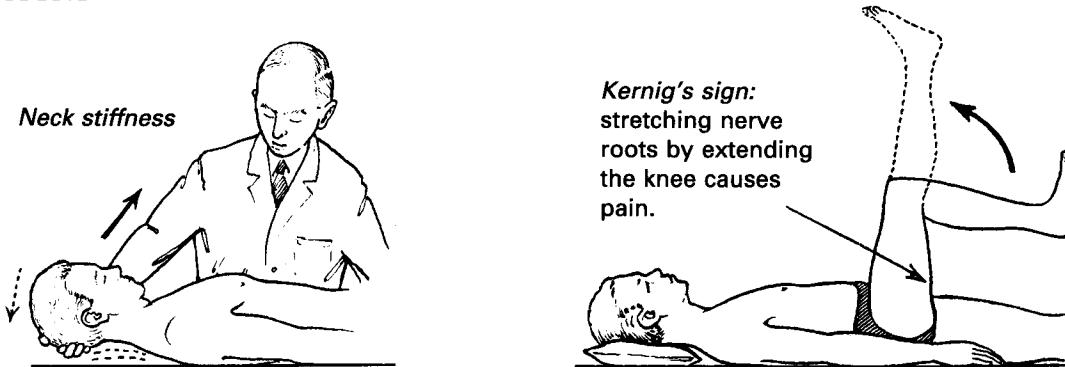
MENINGISM

Evidence of meningeal irritation caused by infection or subarachnoid haemorrhage results in characteristic clinical features:

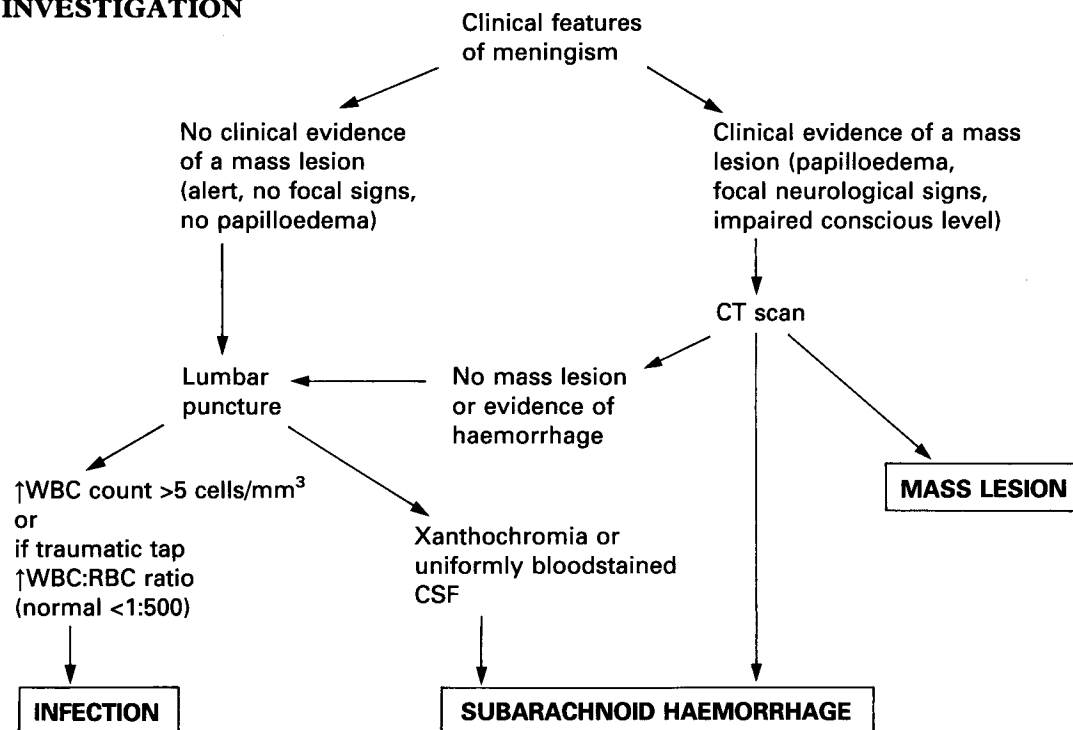
SYMPTOMS

1. Headache
2. Vomiting
3. Photophobia

SIGNS



INVESTIGATION

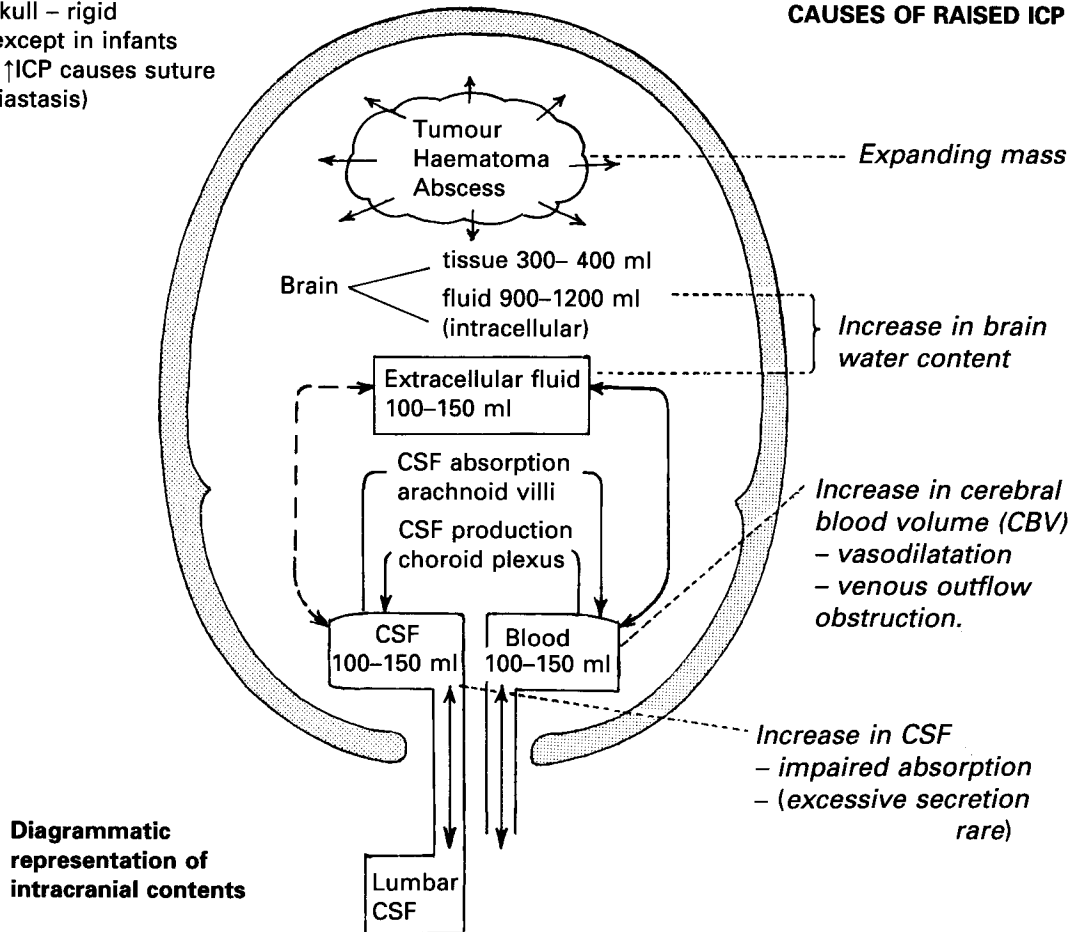


RAISED INTRACRANIAL PRESSURE

The skull is basically a rigid structure. Since its contents – brain, blood and cerebrospinal fluid (CSF) – are incompressible, an increase in one constituent or an expanding mass within the skull results in an increase in intracranial pressure (ICP) – the ‘Monro-Kellie doctrine’.

Skull – rigid
(except in infants
– ↑ICP causes suture
diastasis)

CAUSES OF RAISED ICP



Compensatory mechanisms for an expanding intracranial mass lesion:

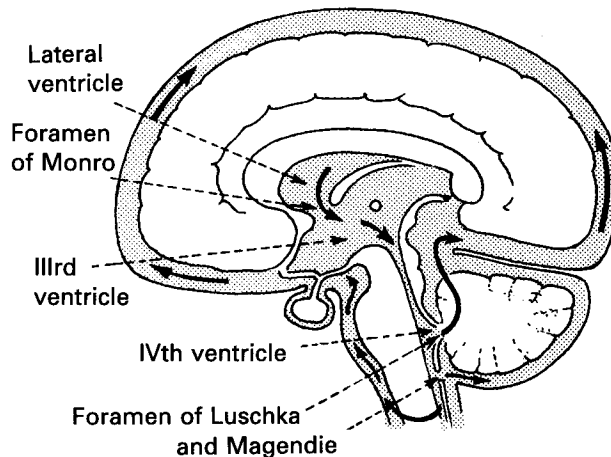
- Immediate { 1. ↓ CSF volume – CSF outflow to the lumbar theca
- 2. ↓ Cerebral blood volume
- Delayed - 3. ↓ Extracellular fluid

RAISED INTRACRANIAL PRESSURE

CEREBROSPINAL FLUID (CSF)

Secreted at a rate of 500 ml per day from the choroid plexus, CSF flows through the ventricular system and enters the subarachnoid space via the 4th ventricular foramina of Magendie and Luschka.

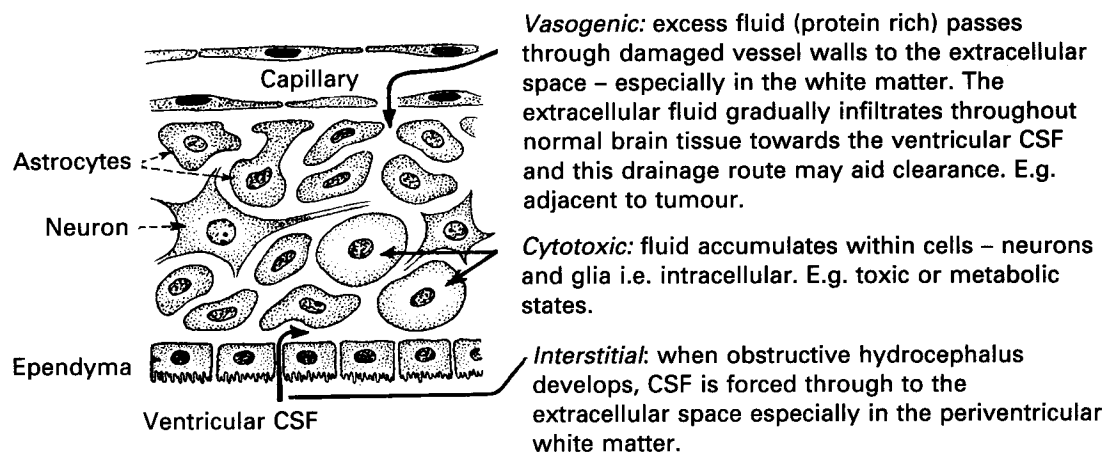
Under normal conditions, CSF flows freely through the subarachnoid space and is absorbed into the venous system through the arachnoid villi. If flow is obstructed at any point in the pathway, *hydrocephalus* with an associated rise in intracranial pressure develops, as a result of continued CSF production. With an expanding intracranial mass lesion, normal pressure is initially maintained by CSF expulsion to the expandable lumbar theca. Further expansion and subsequent brain shift may obstruct the free flow of CSF not only to the lumbar theca but also to the arachnoid villi, causing an acute rise in intracranial pressure.



BRAIN WATER/OEDEMA

Cerebral oedema – an excess of brain water – may develop around an intrinsic lesion within the brain tissue, e.g. tumour or abscess or in relation to traumatic or ischaemic brain damage, and contribute to the space-occupying effect.

Different forms of cerebral oedema exist:



With *ischaemic* damage, as cell metabolism fails, intracellular Na^+ and Ca^{2+} increase and the cells swell i.e. cytotoxic oedema. Capillary damage follows and vasogenic oedema supervenes.

RAISED INTRACRANIAL PRESSURE

CEREBRAL BLOOD FLOW (CBF)/CEREBRAL BLOOD VOLUME (CBV)

Blood flow is dependent on blood pressure and the vascular resistance:

$$\text{Flow} = \frac{\text{Pressure}}{\text{Resistance}}$$

Inside the skull, intracranial pressure must be taken into account:

$$\text{Cerebral blood flow (CBF)} = \frac{\text{Cerebral perfusion pressure (CPP)} \text{ (i.e. systemic BP - intracranial pressure)}}{\text{Cerebral vascular resistance (CVR)}}$$

Under normal conditions the cerebral blood flow is coupled to the energy requirements of brain tissue. Various regulatory mechanisms acting on the arterioles maintain a cerebral blood flow sufficient to meet the metabolic demands.

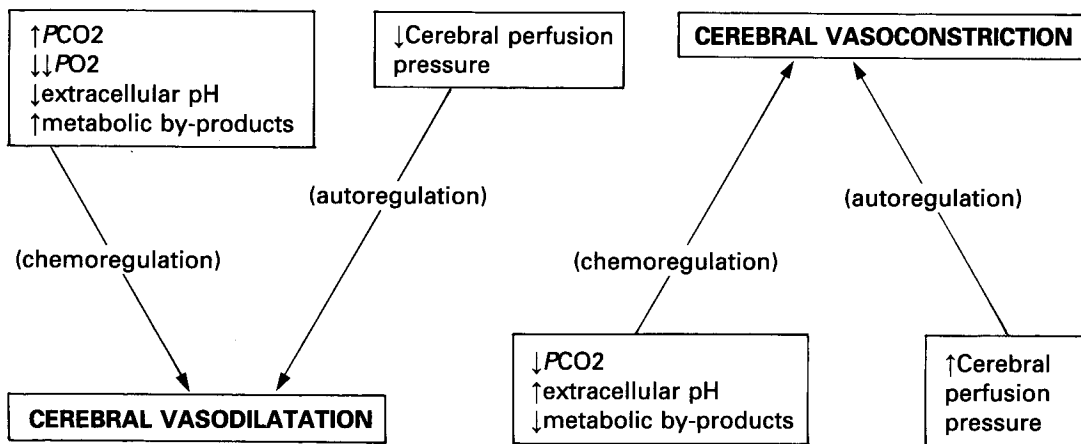
FACTORS AFFECTING THE CEREBRAL VASCULATURE

Chemoregulation

- Change in extracellular pH or an accumulation of metabolic by-products directly affects the vessel calibre.
- Any change in arteriolar PCO_2 has a direct effect on cerebral vessels, but only a reduction of PO_2 to < 50 mmHg has a significant effect.

Autoregulation

- A change in the cerebral perfusion pressure results in a compensatory change in vessel calibre.



Any change in blood vessel diameter results in considerable variation in cerebral blood volume and this, in turn, directly affects intracranial pressure.

Energy requirements differ in different parts of the brain. To meet such needs in the white matter, flow is 20 ml/100 g/min, whereas in the grey matter flow is as high as 100 ml/100g/min.

RAISED INTRACRANIAL PRESSURE

CEREBRAL BLOOD FLOW (contd)

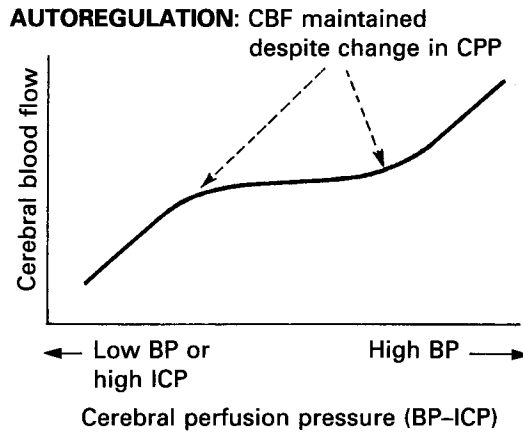
Autoregulation is a compensatory mechanism which permits fluctuation in the cerebral perfusion pressure within certain limits without significantly altering cerebral blood flow.

A drop in cerebral perfusion pressure produces vasodilation (probably due to a direct 'myogenic' effect on the vascular smooth muscle) thereby maintaining flow; a rise in the cerebral perfusion pressure causes vasoconstriction.

Neurogenic influences appear to have little direct effect on the cerebral vessels but they may alter the range of pressure changes over which autoregulation acts.

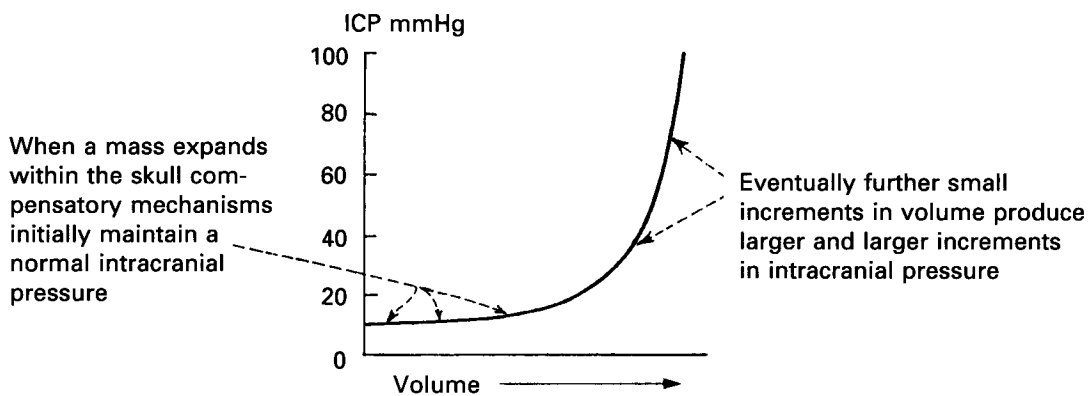
Autoregulation fails when the cerebral perfusion pressure falls below 60 mmHg or rises above 160 mmHg. At these extremes, cerebral blood flow is more directly related to the perfusion pressure.

In damaged brain (e.g. after head injury or subarachnoid haemorrhage), autoregulation is impaired; a drop in cerebral perfusion pressure is more likely to reduce cerebral blood flow and cause ischaemia. Conversely, a high cerebral perfusion may increase the cerebral blood flow, break down the blood-brain barrier and produce cerebral oedema as in hypertensive encephalopathy.



INTRACRANIAL PRESSURE (ICP)

Intracranial pressure, measured relative to the foramen of Monro, under normal conditions ranges from 0–135 mm CSF (0–10 mmHg) although very high pressures, e.g., 1000 mm CSF may occur transiently during coughing or straining.



RAISED INTRACRANIAL PRESSURE

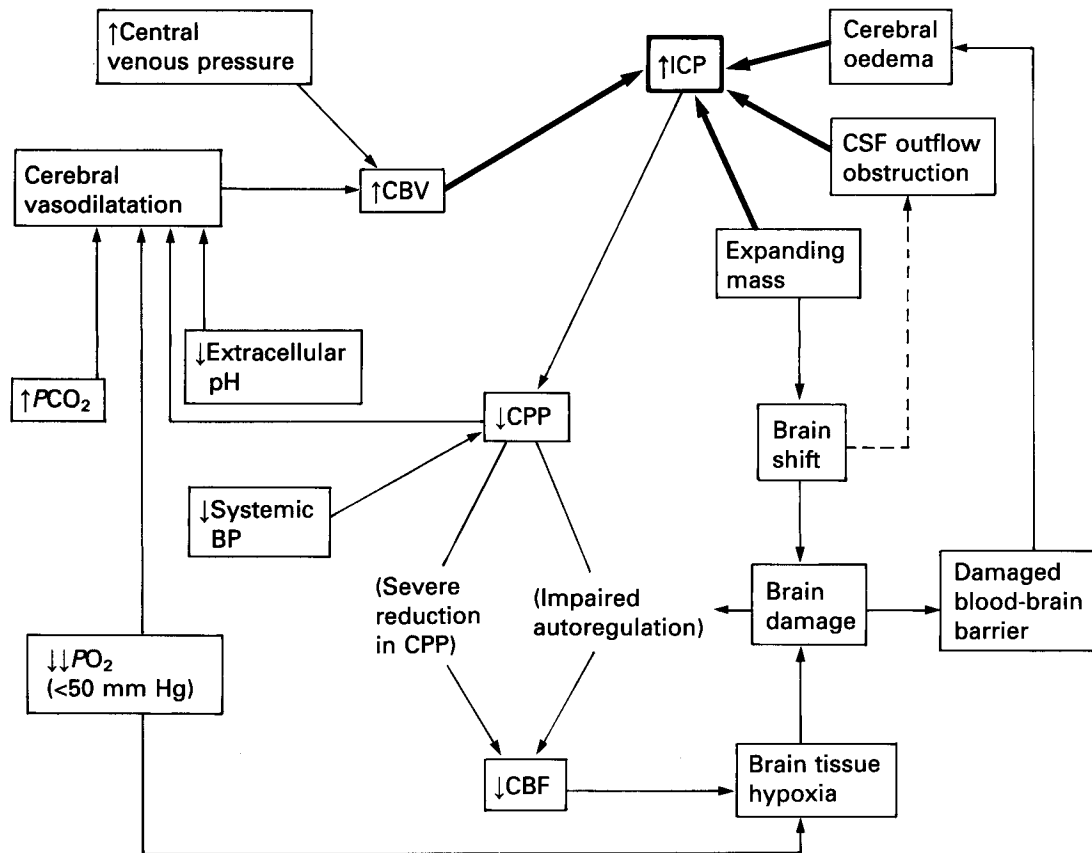
ICP (contd)

When intracranial pressure is monitored with a ventricular catheter, regular waves due to pulse and respiratory effects are recorded (page 51). As an intracranial mass expands and as the compensatory reserves diminish, transient pressure elevations (pressure waves) are superimposed. These become more frequent and more prominent as the mean pressure rises.

Eventually the rise in intracranial pressure and resultant fall in cerebral perfusion pressure reach a critical level and a significant reduction in cerebral blood flow occurs. Electrical activity in the cortex fails at flow rates about 20 ml/100 g/min. If autoregulation is already impaired these effects develop even earlier. When intracranial pressure reaches the mean arterial blood pressure, cerebral blood flow ceases.

INTERRELATIONSHIPS

Many factors affect intracranial pressure and these should not be considered in isolation. Inter-relationships are complex and feedback pathways may merely serve to compound the brain damage.



RAISED INTRACRANIAL PRESSURE

CLINICAL EFFECTS OF RAISED INTRACRANIAL PRESSURE

A raised ICP will produce symptoms and signs but does not cause neuronal damage provided cerebral blood flow is maintained. Damage does, however, result from brain shift – tentorial or tonsillar herniation.

Clinical features due to ↑ICP:

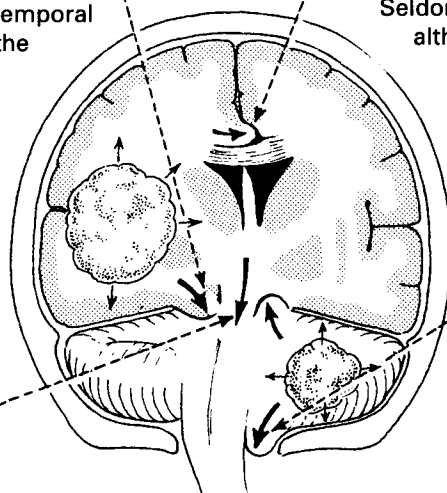
1. *Headache* – worse in the mornings, aggravated by stooping and bending.
2. *Vomiting* – occurs with an acute rise in ICP.
3. *Papilloedema* – occurs in a proportion of patients with ↑ICP. It is related to CSF obstruction and does not necessarily occur with brain shift alone. Increased CSF pressure in the optic nerve sheath impedes venous drainage and axoplasmic flow in optic neurons. Swelling of the optic disc and retinal and disc haemorrhages result. Vision is only at risk when papilloedema is both severe and prolonged.

BRAIN SHIFT – TYPES

TENTORIAL HERNIATION (lateral):

a unilateral expanding mass causes tentorial (uncal) herniation as the medial edge of the temporal lobe herniates through the tentorial hiatus. As the intracranial pressure continues to rise, 'central' herniation follows.

SUBFALCINE 'MIDLINE' SHIFT: occurs early with unilateral space-occupying lesions. Seldom produces any clinical effect, although ipsilateral anterior cerebral artery occlusion has been recorded.



TENTORIAL HERNIATION

(central): a midline lesion or diffuse swelling of the cerebral hemispheres results in a vertical displacement of the midbrain and diencephalon through the tentorial hiatus. Damage to these structures occurs either from mechanical distortion or from ischaemia secondary to stretching of the perforating vessels.

TONSILLAR HERNIATION: a subtentorial expanding mass causes herniation of the cerebellar tonsils through the foramen magnum. A degree of *upward* herniation through the tentorial hiatus may also occur. Clinical effects are difficult to distinguish from effects of direct brainstem/midbrain compression.

Unchecked lateral tentorial herniation leads to central tentorial and tonsillar herniation, associated with progressive brain stem dysfunction from midbrain to medulla.

RAISED INTRACRANIAL PRESSURE

CLINICAL EFFECTS OF BRAIN SHIFT

TENTORIAL HERNIATION - Lateral

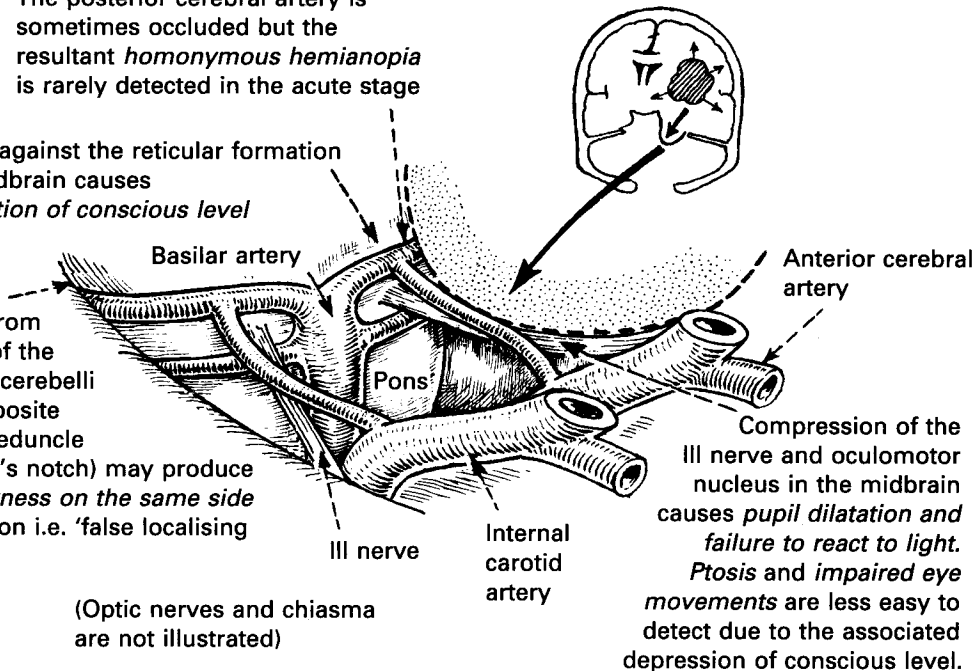
The posterior cerebral artery is sometimes occluded but the resultant *homonymous hemianopia* is rarely detected in the acute stage

The rate of symptom progression is related to the rate of lesion expansion.

Pressure against the reticular formation in the midbrain causes *deterioration of conscious level*

Pressure from the edge of the tentorium cerebelli on the opposite cerebral peduncle (Kernohan's notch) may produce *limb weakness on the same side as the lesion* i.e. 'false localising sign'

(Optic nerves and chiasma are not illustrated)



Compression of the III nerve and oculomotor nucleus in the midbrain causes *pupil dilatation and failure to react to light. Ptosis and impaired eye movements* are less easy to detect due to the associated depression of conscious level.

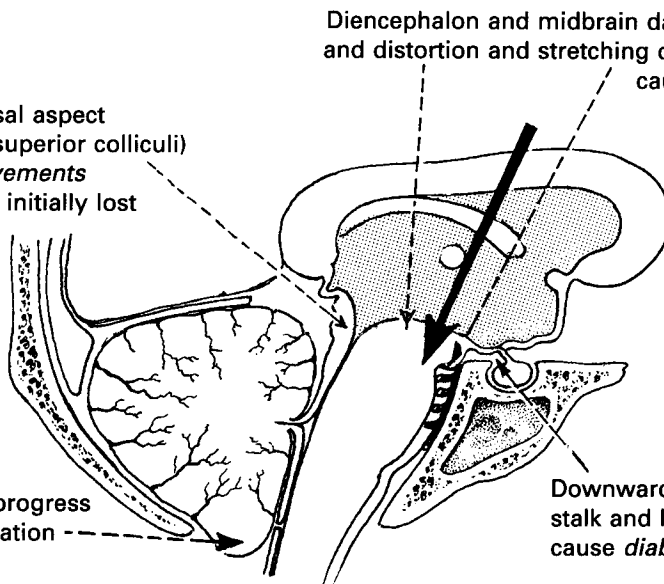
TENTORIAL HERNIATION - Central

Pressure on dorsal aspect (pretectum and superior colliculi) *impairs eye movements* - upward gaze is initially lost

Diencephalon and midbrain damage from buckling and distortion and stretching of perforating vessels causes: *deterioration of conscious level. Pupils initially small, become moderately dilated and fixed to light*

Central tentorial herniation may progress to tonsillar herniation

Downward traction on pituitary stalk and hypothalamus may cause *diabetes insipidus*

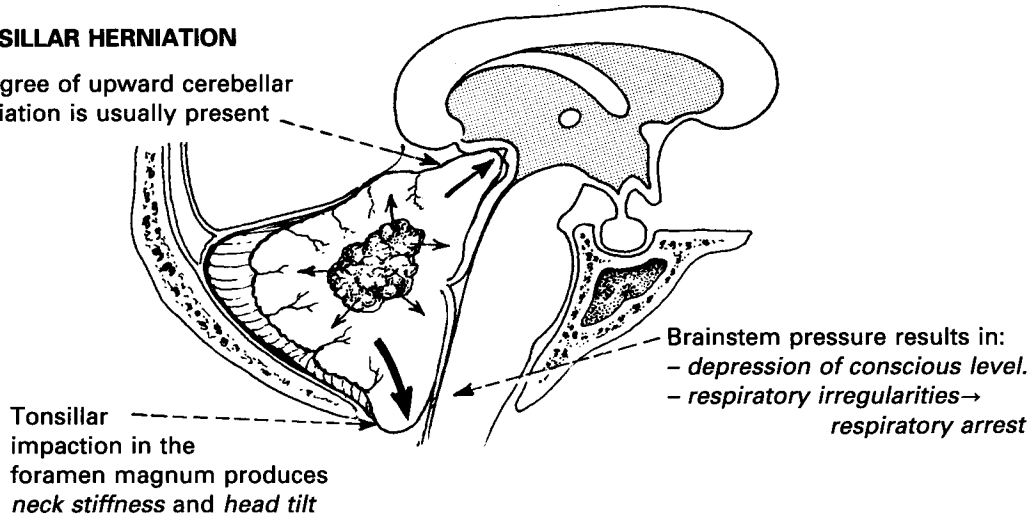


RAISED INTRACRANIAL PRESSURE

CLINICAL EFFECTS OF BRAIN SHIFT (*cont'd*)

TONSILLAR HERNIATION

A degree of upward cerebellar herniation is usually present



An injudicious lumbar puncture in the presence of a subtentorial mass may create a pressure gradient sufficient to induce tonsillar herniation.

N.B. Harvey Cushing described cardiovascular changes – an increase in blood pressure and a fall in pulse rate, associated with an expanding intracranial mass, and probably resulting from direct medullary compression. The clinical value of these observations is often overemphasised. They are often absent; when present they are invariably preceded by a deterioration in conscious level.

INVESTIGATIONS

Patients with suspected raised intracranial pressure require an urgent CT scan. Intracranial pressure monitoring where appropriate (see page 51).

TREATMENT OF RAISED INTRACRANIAL PRESSURE

When a rising intracranial pressure is caused by an expanding mass, or is compounded by respiratory problems, treatment is clear-cut; the mass must be removed and blood gases restored to normal levels – by ventilation if necessary.

In some patients, despite the above measures, cerebral swelling may produce a marked increase in intracranial pressure. This may follow removal of a tumour or haematoma or may complicate a diffuse head injury. Artificial methods of lowering intracranial pressure may prevent brain damage and death from brain shift, but some methods lead to reduced cerebral blood flow, which in itself may cause brain damage (see page 80).

Intracranial pressure is monitored with a ventricular catheter or surface pressure recording device (see page 50).

Treatment may be instituted when the mean ICP is > 30 mmHg.

RAISED INTRACRANIAL PRESSURE

TREATMENT (*cont'd*)

Methods of reducing intracranial pressure

Mannitol infusion: An i.v. bolus of 100 ml of 20% mannitol infused over 15 minutes reduces intracranial pressure by establishing an osmotic gradient between the plasma and brain tissue. *This method 'buys' time prior to craniotomy in a patient deteriorating from a mass lesion.* Mannitol is also used 6 hourly for a 24–48 hour period in an attempt to reduce raised ICP. Repeated infusions, however, lead to equilibration and a high intracellular osmotic pressure, thus counteracting further treatment. In addition, repeated doses may precipitate lethal rises in arterial blood pressure and acute tubular necrosis. Its use is therefore best reserved for emergency situations.

Controlled hyperventilation: Bringing the PCO_2 down to 3.5kPa by hyperventilating the sedated or paralysed patient causes vasoconstriction. Although this reduces intracranial pressure, the resultant reduction in cerebral blood flow may in itself cause brain damage. Maintaining the blood pressure and the *cerebral perfusion pressure* (CPP) (> 70 mmHg) appears to be as, if not more, important than lowering intracranial pressure. Only by monitoring the amount of oxygen extracted from the brain can one determine whether or not the brain tissue can withstand further vasoconstriction caused by hyperventilation (see page 227).

CSF withdrawal: Removal of a few millilitres of CSF from the ventricle will immediately reduce the intracranial pressure. Within minutes, however, the pressure will rise and further CSF withdrawal will be required. In practice, this method is of limited value, since CSF outflow to the lumbar theca results in a diminished intracranial CSF volume and the lateral ventricles are often collapsed. Continuous CSF drainage may make most advantage of this method.

Sedatives: If intracranial pressure fails to respond to standard measures then sedation may help under carefully controlled conditions.

Propofol, a short acting anaesthetic agent, reduces intracranial pressure but causes systemic vasodilatation. If this occurs pressor agents may be required to prevent a fall in blood pressure and a reduction in cerebral perfusion.

Barbiturates (thiopentone) reduce neuronal activity and depress cerebral metabolism; a fall in energy requirements theoretically protects ischaemic areas. Associated vasoconstriction can reduce cerebral blood volume and intracranial pressure but systemic hypotension and myocardial depression also occur. *Clinical trials of barbiturate therapy have not demonstrated any improvement in outcome.*

Etomidate also provides cerebral protection by reducing cerebral metabolism and intracranial pressure without producing cardiodepression. It inhibits endogenous steroid synthesis, and therefore requires steroid cover.

Steroids: There is no doubt that steroids play an important rôle in treating patients with intracranial tumours and surrounding oedema. Cell membranes are stabilised, but it is not certain that their beneficial effect in tumour management is a result of reducing ICP. Steroids appear to be of no value in the treatment of traumatic or ischaemic damage. Experimental evidence suggests that they may help if administered before the damage occurs, but clearly this is seldom of practical value.

COMA AND IMPAIRED CONSCIOUS LEVEL

Consciousness is regarded as a state of awareness of self and surroundings. Impaired consciousness is due to disturbed arousal or content of mental function.

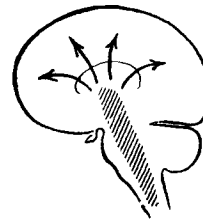
Many pathological processes may impair conscious level and numerous terms have been employed to describe the various clinical states which result, including obtundation, stupor, semicoma and deep-coma. These terms result in ambiguity and inconsistency when used by different observers. Recording conscious level with the *Glasgow coma scale* (page 5) avoids these difficulties and clearly describes the level of arousal. With this scale:

COMA = NO SPEECH, NO EYE OPENING, NO MOTOR RESPONSE

In this section we describe conditions which may present with, or lead to, coma. Patients experiencing 'transient disturbance of conscious level' require a different approach.

Pathophysiology of coma

A 'conscious' state depends on intact cerebral hemispheres, interacting with the ascending reticular activating system in the brain stem, midbrain, hypothalamus and thalamus. Lesions diffusely affecting the cerebral hemispheres, or directly affecting the reticular activating system cause impairment of conscious level:



Diffuse hemisphere damage

- e.g.
- trauma
 - ischaemia
 - hypoglycaemia
 - hepatic or renal failure

Bilateral thalamic involvement,
e.g. astrocytoma

Supratentorial mass causing
transtentorial herniation
and midbrain compression

[Note: focal damage
to part of the cortex
does *not* affect
conscious level]

Brain stem compression
- directly from infratentorial
mass lesion

- or indirectly from
tonsillar herniation

Brain stem involvement

- ischaemia
- haemorrhage
- tumour
- drugs (sedatives, hypnotics)

COMA AND IMPAIRED CONSCIOUS LEVEL

CAUSES

INTRACRANIAL

Trauma

Diffuse white matter injury
 Haematoma – extradural
 – subdural
 – ‘burst’ lobe

Neoplastic

Tumour with oedema

Other

Epilepsy
 Hydrocephalus

Vascular

Subarachnoid haemorrhage
 ‘Spontaneous’ intracerebral haematoma
 Cerebral infarct with oedema and ‘shift’
 Brain stem infarction or haemorrhage

Infective

Meningitis
 Abscess
 Encephalitis

EXTRACRANIAL

Metabolic

Hypo/hypernatraemia
 Hypo/hyperkalaemia
 Hypo/hypercalcaemia
 Hypo/hyperglycaemia
 Diabetic ketoacidosis
 Lactic acidosis
 Hypo/hyperthermia
 Uraemia
 Hepatic failure
 Porphyrria

Endocrine

Diabetes
 Hypopituitarism
 Adrenal crisis (Addison’s disease)
 Hypo/hyperparathyroidism
 Hypothyroidism

Respiratory insufficiency

Hypoventilation
 Diffusion deficiency
 Perfusion deficiency
 Anaemia

Hypercapnia
 Hypoxia

Reduced
 cerebral
 blood flow

Decreased cardiac output

Vasovagal attack
 Blood loss
 Valvular disease
 Myocardial infarction
 Cardiac arrhythmias
 Hypotensive drugs

Arterial occlusion

Vertebral artery disease
 Bilateral carotid disease

Drugs

Sedatives
 Opiates
 Antidepressants
 Anticonvulsants
 Anaesthetic agents

Toxins

Alcohol
 Carbon monoxide
 Heavy metals

Psychiatric disorders

Hysteria
 Catatonia (mutism with decreased motor activity)
 Fugue states

COMA AND IMPAIRED CONSCIOUS LEVEL

Examination of the unconscious patient (see pages 29, 30)

DIAGNOSTIC APPROACH

Questioning friends, relatives or the ambulance team, followed by general and neurological examination all provide important diagnostic information.

History

POSSIBLE CAUSE OF COMA/IMPAIRED CONSCIOUS LEVEL

Head injury leading to admission	→	<i>Diffuse shearing injury and/or intracranial haematoma</i>
Previous head injury (e.g. 6 weeks)	→	<i>Chronic subdural haematoma</i>
Sudden collapse	→	<i>Intracerebral haemorrhage Subarachnoid haemorrhage</i>
Limb twitching, incontinence	→	<i>Epilepsy/postictal state</i>
Gradual development of symptoms	→	<i>Mass lesion, metabolic or infective cause</i>
Previous illness – diabetes	→	<i>Hypo- or (less likely) hyperglycaemia</i>
– epilepsy	→	<i>Postictal state</i>
– psychiatric illness	→	<i>Drug overdose</i>
– alcoholism	→	<i>Drug toxicity</i>
or drug abuse		
– viral infection	→	<i>Encephalitis</i>
– malignancy	→	<i>Intracranial metastasis</i>

General examination

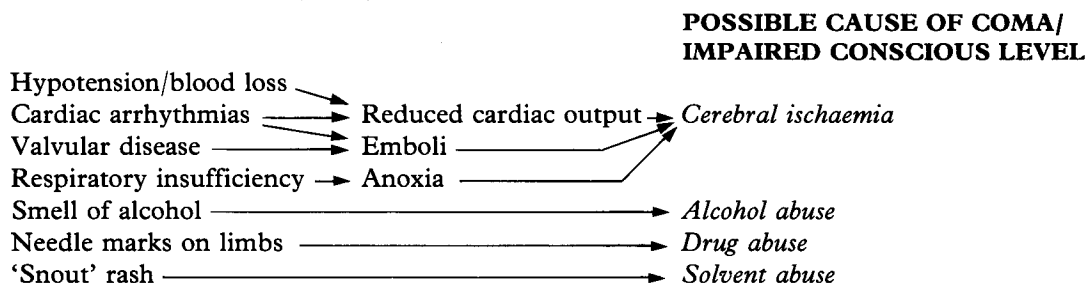
Note the presence of:

Laceration, bruising, CSF leak	→	<i>Head injury</i>
Internal auditory meatus – bleeding	→	<i>Head injury</i>
pus	→	<i>Cerebral abscess/meningitis</i>
Enlarged head	} In infant	→ <i>Raised intracranial pressure</i>
Tense anterior fontanelle		
Neck stiffness, retraction	→	<i>Tonsillar herniation</i>
Positive Kernig's sign	→	<i>Meningitis</i>
Tongue biting	→	<i>Epilepsy/postictal state</i>
Emaciation, hepatomegaly, lymphadenopathy	→	<i>Intracranial metastasis</i>
Infection source (ears, sinus, lungs, valvular disease)	→	<i>Cerebral abscess, meningitis</i>
Pyrexia	→	<i>Subarachnoid, intracerebral, pontine haemorrhage</i>

COMA AND IMPAIRED CONSCIOUS LEVEL

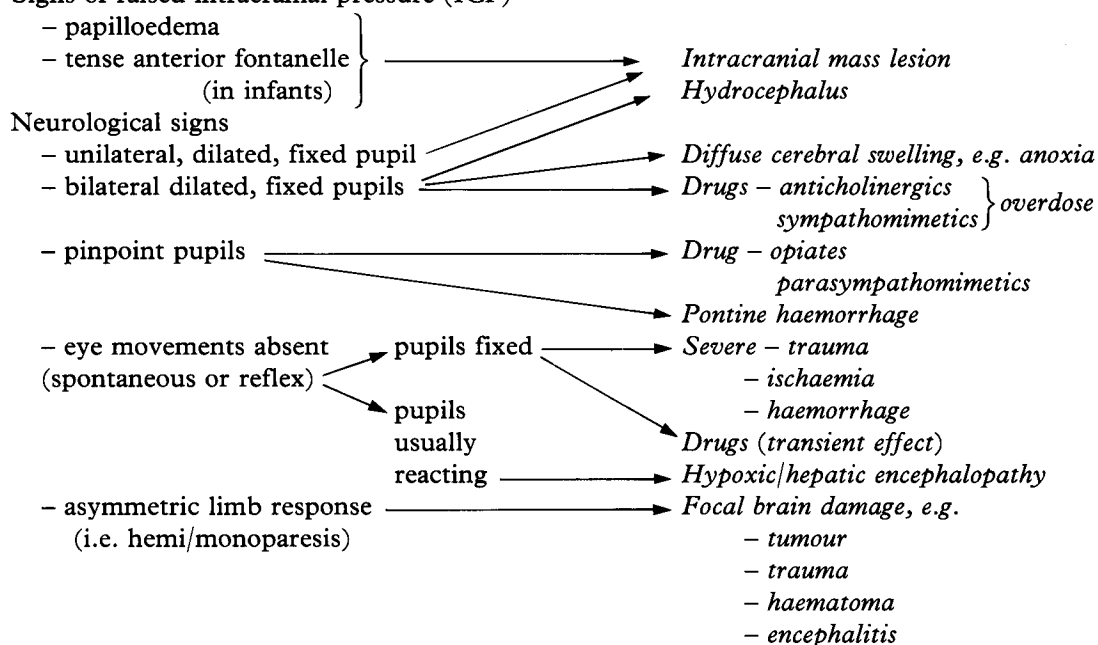
DIAGNOSTIC APPROACH (contd)

General examination (contd)

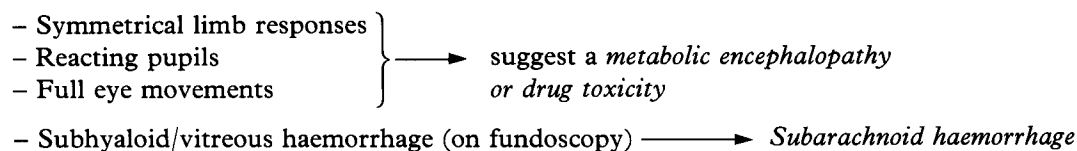


Neurological examination

Signs of raised intracranial pressure (ICP)



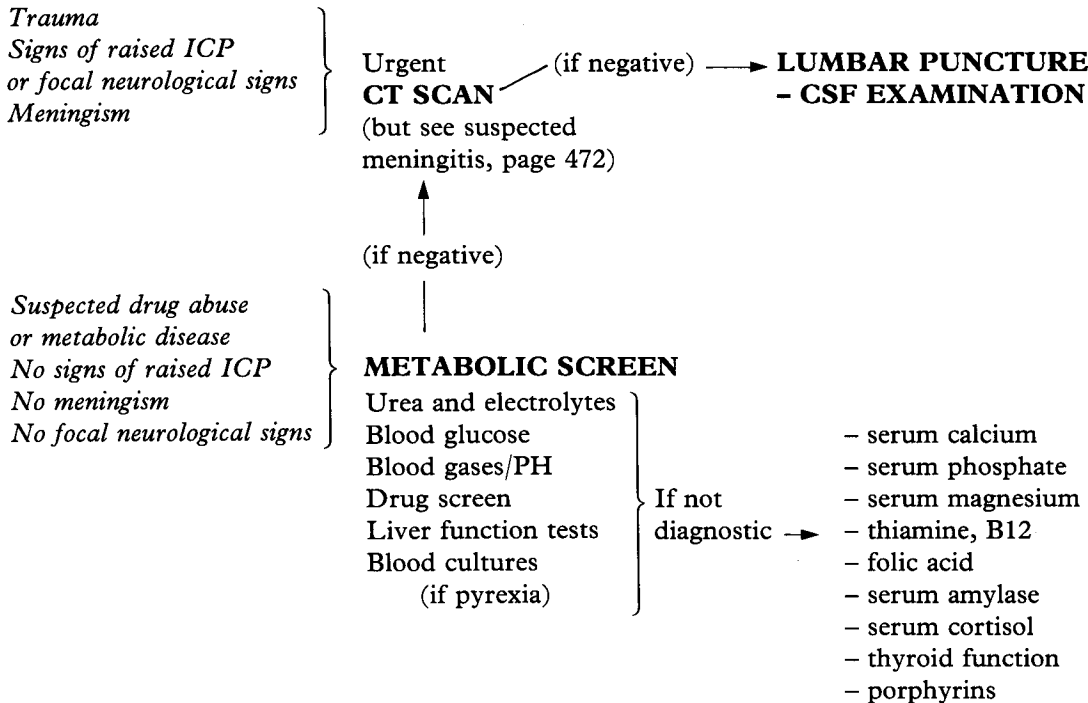
[N.B. - *hepatic encephalopathy*
- *hypoclycaemia*
- *uraemia*] → occasionally produce asymmetrical responses]



COMA AND IMPAIRED CONSCIOUS LEVEL

Investigations

The sequence of investigations depends on clinical suspicion:



In addition:

SKULL X-RAY – may reveal an unsuspected fracture, pineal shift, calcification or an osteolytic lesion.

CHEST X-RAY – may reveal a bronchial carcinoma.

ELECTROENCEPHALOGRAPHY – may provide evidence of – subclinical epilepsy
– herpes simplex encephalitis
– metabolic encephalopathy.

MRI – has a limited role in the investigation of coma. More sensitive than CT scan in demonstrating small ischaemic changes and early encephalitis.

Prognosis

Although *conscious level examination* does not aid diagnosis, it plays an essential rôle in patient management and along with the *duration of coma, pupil response and eye movements* provides valuable prognostic information. Non-traumatic coma tends to carry a better prognosis (see page 210).

TRANSIENT LOSS OF CONSCIOUSNESS

Many conditions causing coma may also transiently affect a patient's conscious level. This results from:

Reduction in cerebral arterial oxygen supply	<ul style="list-style-type: none"> - <i>cardiac arrhythmias</i> - <i>cardiac outflow obstruction</i> - <i>vasovagal attack</i> - <i>vertebrobasilar ischaemia</i> 	} <i>reduced cardiac output</i>	} Clinical details – see page 95
Neuronal suppression	<ul style="list-style-type: none"> - <i>basilar migraine</i> - <i>hypoglycaemia</i> 		
Neuronal excitation	<ul style="list-style-type: none"> - <i>epilepsy</i> 		
Drug abuse – <i>alcohol, solvents or barbiturates</i> – may cause transient, intermittent confusion.			

DIAGNOSTIC APPROACH

History

The patient's own description of the attack or that of an eyewitness may establish the diagnosis. Prodromal features of pallor, nausea and sweating accompany *vasovagal attacks*. Clonic/tonic movements occur shortly after the onset of an *epileptic 'grand mal' attack* (but either movement can occur with a prolonged vasovagal attack or cardiac arrhythmia).

Palpitations, sweating, behavioural disturbances and seizures may precede loss of consciousness from *hypoglycaemia*. Vertigo and scintillating teichopsia often precede *basilar migraine*.

Electroencephalography (EEG) may reveal a focal disturbance – *epilepsy*.

Electrocardiography (ECG) may reveal a *cardiac arrhythmia*.

Echocardiography may reveal *cardiomyopathy*.

Blood glucose may indicate *hypoglycaemia*.

If an eyewitness account and the above tests provide no evidence of the cause, proceed to:

1. **Telemetric EEG and ECG monitoring** over a 24-hour period.
2. **72-hour fast** – if symptoms appear, check **blood glucose** and **insulin** levels.

Often attacks of unconsciousness remain unexplained and possibly have a psychological or attention-seeking basis. The circumstances of the attack (e.g. during an argument), the non-stereotyped nature of the episode and the lack of personal trauma with repeated falls all suggest a 'functional' *non-organic* explanation.

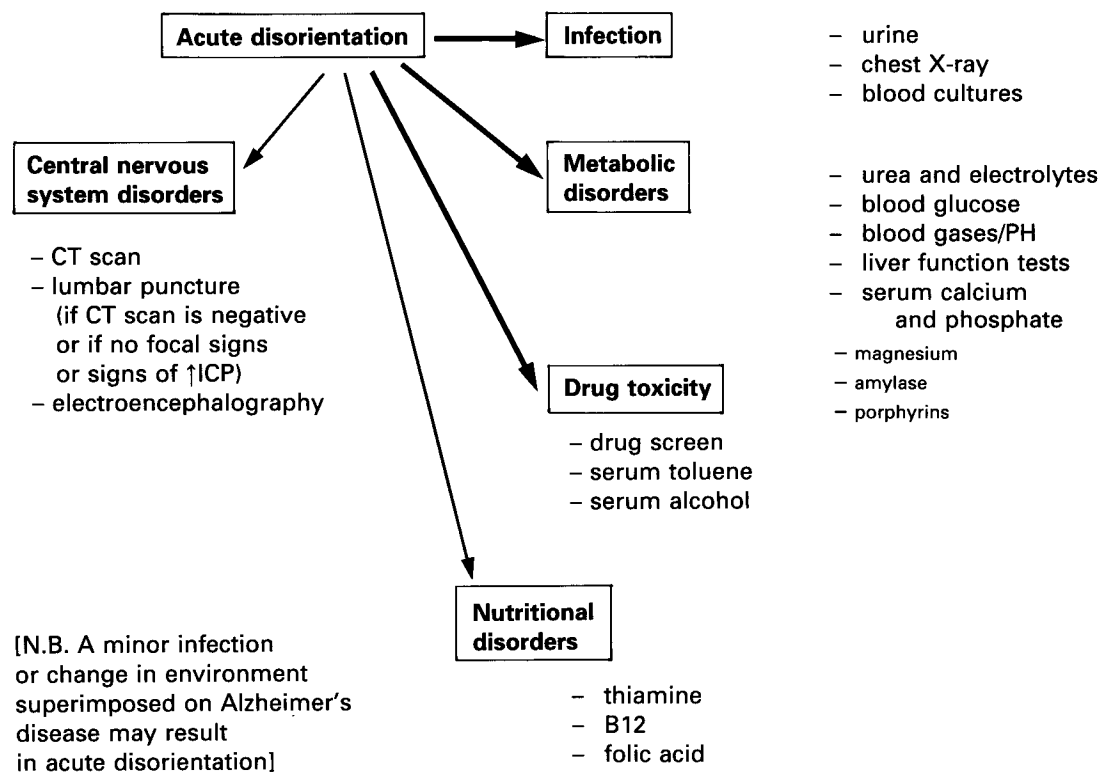
CONFUSIONAL STATES AND DELIRIUM

Of all acute medical admissions, 5–10% present with a **confused verbal response**, i.e. disorientation in time and/or place. Most patients are easily distracted, have slowed thought processes and a limited concentration span. Some may lose interest in the examination to the point of drifting off to sleep.

Perceptual disorders (illusions and hallucinations) may accompany the confused state – **delirium**. This is often associated with withdrawal and lack of awareness or with restlessness and hyperactivity.

Primary neurological disorders contribute to only 10% of those patients presenting with an acute confusional state. In the elderly, postoperative disorientation is particularly common and multiple factors probably apply; in these patients the prognosis is good.

DIAGNOSTIC APPROACH



EPILEPSY

Definitions

A seizure or epileptic attack is the consequence of a paroxysmal uncontrolled discharge of neurons within the central nervous system. The clinical manifestations range from a major motor convulsion to a brief period of lack of awareness.

The *prodrome* refers to mood or behavioural changes which may precede the attack by some hours.

The *aura* refers to the symptom immediately before a seizure and will localise the attack to its point of origin within the nervous system.

The *ictus* refers to the attack or seizure itself.

The *postictal period* refers to the time immediately after the ictus during which the patient may be confused, disorientated and demonstrate automatic behaviour.

The stereotyped and uncontrollable nature of the attack is characteristic of epilepsy.

Pathogenesis

Epilepsy has been described since ancient times. The 19th century neurologist Hughlings-Jackson suggested 'a sudden excessive disorderly discharge of cerebral neurons' as the causation of the attack. Berger (1929) recorded the first electroencephalogram (EEG) and not long after, it was appreciated that certain seizures were characterised by particular EEG abnormalities.

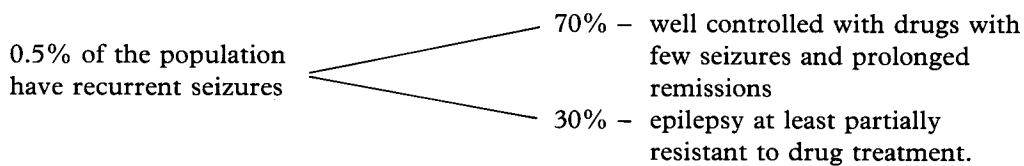
Recent studies in animal models of *focal epilepsy* suggest a central role for the excitatory neurotransmitter glutamate. This produces a depolarisation shift by activating receptors which in turn facilitate cellular influx of Na^+ , K^+ and Ca^{2+} . Gamma amino butyric acid (GABA) has an important inhibitory influence in containing abnormal cortical discharges and preventing the development of generalised seizures.

All humans have a biological tendency to seizures and genetic factors play a role in susceptibility.

Incidence and course

Epilepsy usually presents in childhood or adolescence but may occur for the first time at any age.

5% of the population suffer a single seizure at some time.



Though there is considerable variability depending on seizure type, 6 years after diagnosis 40% of patients have had a substantial remission; after 20 years – 75%.

EPILEPSY IS A SYMPTOM OF NUMEROUS DISORDERS, BUT IN THE MAJORITY OF SUFFERERS THE CAUSE REMAINS UNCLEAR DESPITE CAREFUL HISTORY TAKING, EXAMINATION AND INVESTIGATION.

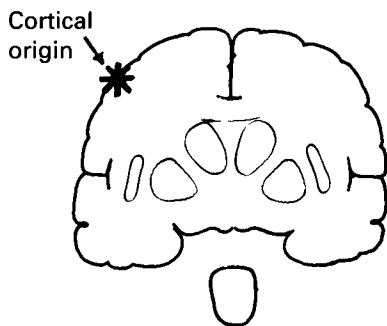
EPILEPSY – CLASSIFICATION

The modern classification of the epilepsies is based upon the *nature* of the attack rather than the presence or absence of an underlying cause. The use of the electroencephalogram (EEG) has greatly increased our understanding of the source of 'point of origin' of any particular type of epileptic attack.

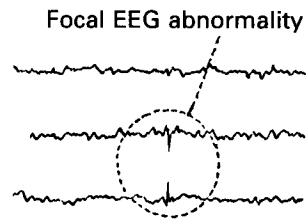
Attacks which begin **focally** from a single location within one hemisphere are thus distinguished from those of a **generalised** nature which probably commence in deeper midline structures and project to both hemispheres simultaneously.

INTERNATIONAL CLASSIFICATION OF EPILEPTIC SEIZURES (I.C.E.S. 1981)

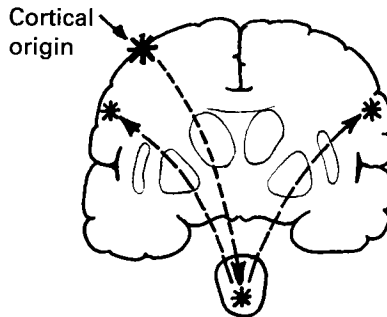
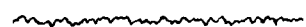1 PARTIAL (focal, local) SEIZURES



- A. Simple partial seizures
 - motor
 - sensory

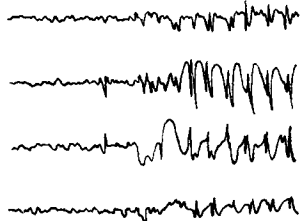


- B. Complex partial seizures
 (when partial seizure is accompanied by any degree of impaired conscious level)

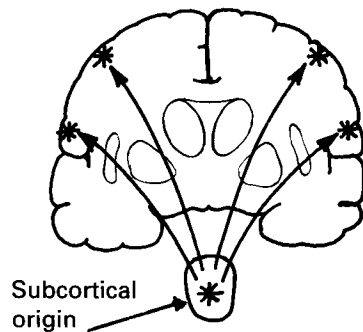


- C. Partial seizures evolving to tonic/clonic convulsion

Focal → generalised EEG abnormality

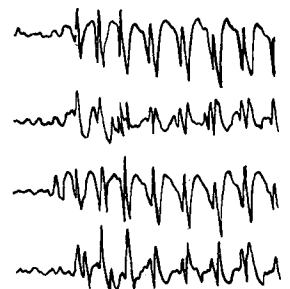

2 GENERALISED SEIZURES (convulsive or non-convulsive)



- A. Absences
 B. Myoclonic seizures
 C. Clonic seizures
 D. Tonic seizures
 E. Tonic/clonic seizures
 F. Atonic seizures

Generalised EEG abnormality

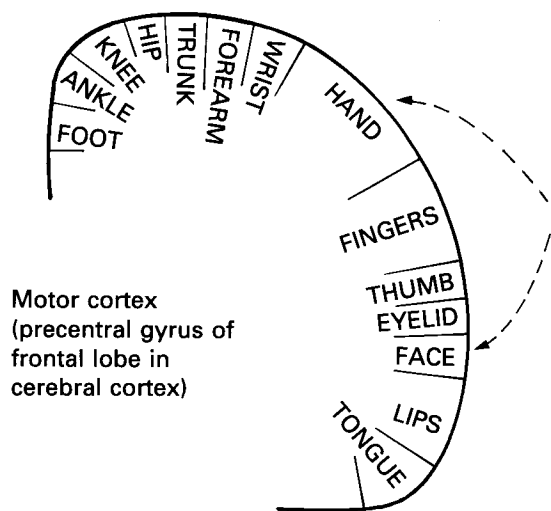


- 3 UNCLASSIFIED SEIZURES, e.g. Some neonatal seizures
 Rhythmic eye movement disorders

THE PARTIAL SEIZURES

Partial seizures account for 80% of adult epilepsies.

SIMPLE MOTOR SEIZURES



Motor cortex
(precentral gyrus of frontal lobe in cerebral cortex)

These arise in the frontal motor cortex with movements occurring in contralateral face, trunk or limbs.

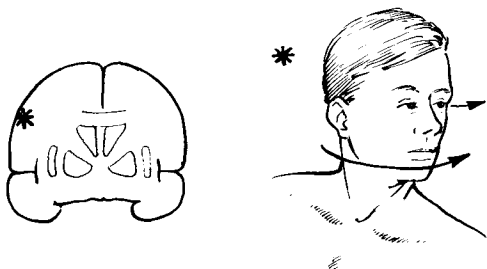
The **Jacksonian** motor seizure consists of a 'march' of involuntary movement from one muscle group to the next.

Movement is clonic (shaking) and usually begins in hand or face – these having the largest representative cortical area.

Motor seizures with the above 'march' are quite rare, usually they are less localised, involving many muscle groups simultaneously and are tonic (rigid) or clonic.

After a motor seizure the affected limb(s) may remain weak for some hours before return of function occurs – **Todd's paralysis**.

Adversive seizures



The patient is aware of movement of the head. Attacks often progress to loss of consciousness and tonic/clonic epilepsy.

The patient's eyes and head turn away from the site of the focal origin usually in the supplementary motor cortex of the frontal lobe with involvement of the frontal 'gaze centre'. Some doubt the localising value of such an attack.

SIMPLE SENSORY SEIZURES

These arise in the sensory cortex, the patient describing paraesthesia or tingling in an extremity or on the face sometimes associated with a sensation of distortion of body image. A 'march' similar to the Jacksonian motor seizure may occur. Motor symptoms occur concurrently – the limb appears weak without involuntary movement.

The representation of limbs, trunk, etc. in the post-Rolandic sensory cortex is similar to that of the motor cortex.

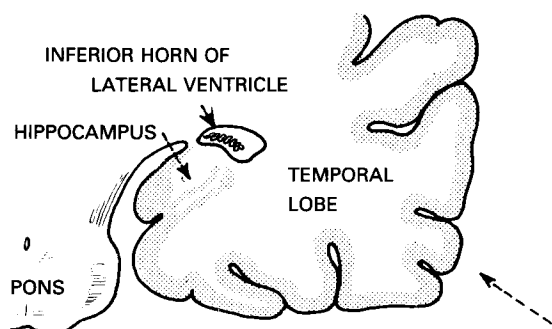
VISUAL, AUDITORY and AUTONOMIC simple partial seizures occur, but are rare.

Motor and sensory seizures indicate structural brain disease, the focal onset localising the lesion. Full investigation is mandatory.

THE PARTIAL SEIZURES

COMPLEX PARTIAL SEIZURES

These attacks usually originate within the temporal lobe and are characterised by a complex aura (initial symptom) and some impairment of consciousness.



Coronal section through the pons showing medial aspect of the temporal lobe and hippocampus

Complex partial seizures are generally synonymous with **psychomotor epilepsy** and **temporal lobe epilepsy** (though motor, sensory and other partial seizures can be associated with impaired consciousness when propagated through the temporal lobe – extratemporal complex partial seizures).

The seizure origin lies in the medial part of the temporal lobe, hippocampus or lateral surface of the lobe.

The nature of the attack

The content of attacks may vary in an individual patient. Commonly encountered symptoms include:

Visceral disturbance: Gustatory (taste) and olfactory (smell) hallucinations, lip smacking, epigastric fullness, choking sensation, nausea, pallor, pupillary changes (dilatation), tachycardia.

Memory disturbance: Deja vu ('something has happened before'), jamais vu ('feeling of unfamiliarity'), depersonalisation, derealisation, flashbacks, formed visual or auditory hallucinations.

Motor disturbance: Fumbling movement, rubbing, chewing, semi-purposeful limb movements.

Affective disturbance: Displeasure, pleasure, depression, elation, fear.

A constellation of these symptoms associated with subtle clouding of consciousness characterises a complex partial seizure.

AUTOMATISM occurs during the state of clouding of consciousness either during or after the attack (postictal) and takes the form on involuntary, often complicated, motor activity. In ambulatory automatism, subjects may 'wander off'.


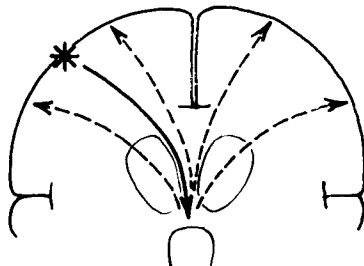
Confusion and headache after an attack are common. The whole episode may last for seconds but occasionally may be prolonged and a rapid succession or cluster of attacks may occur. Attacks show an increased incidence in adolescence and early adult life. A history of birth trauma or febrile convulsions in infancy may be obtained. Lesions in the hippocampus occur as a result of anoxia or from the convulsion itself and act as a source of further epilepsy. When surgery is carried out, hippocampal sclerosis is often found. Occasionally other pathologies are identified, such as hamartomas, vascular malformations and low-grade malignant astrocytomas.

PARTIAL SEIZURES EVOLVING TO TONIC/CLONIC CONVULSION

Seizure discharges have the capacity to spread from their point of origin and excite other structures. When spread occurs to the subcortical structures (thalamus and upper reticular formation) their excitation releases a discharge which spreads back to the cerebral cortex of both hemispheres, resulting in a tonic/clonic seizure. This chain of events is reflected in the electroencephalogram (EEG).

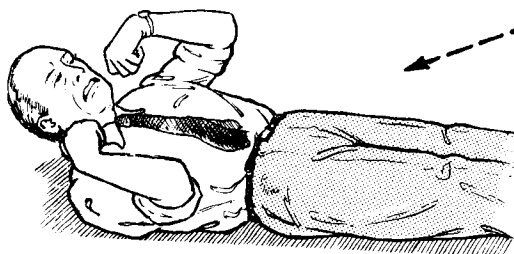
The symptoms before the tonic/clonic convulsion give a clue to the site of the initial discharge (simple partial or complex partial).

An eyewitness account is important because retrograde amnesia may prevent recall of the onset.



TONIC/CLONIC ATTACKS

Loss of consciousness;
falls to the ground.

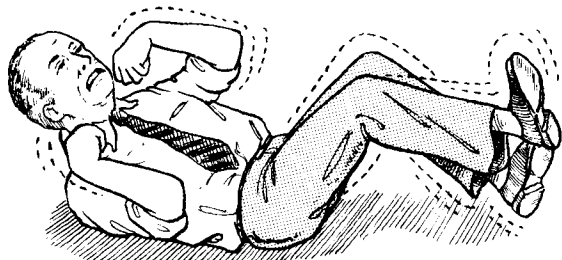


1. Tonic phase (10 seconds)

Eyes open. Elbows flexed.
Arms pronated. Legs extended.
Teeth clenched. Pupils dilated.
Breath held – cyanosis.
Bowel/bladder control may be lost at the end of this phase.

2. Clonic phase (1–2 minutes) – - - - ->

Tremor gives way to violent generalised shaking.
Eyes roll backwards and forwards.
Tongue may be bitten. Tachycardia develops. Breathing recommences at end of phase.



The patient then sleeps with stertorous respiration and cannot be roused. On regaining consciousness, confusion and headache are present. He may feel exhausted for hours or even days afterwards. Muscles may ache as a result of violent movement and muscle damage occurs with elevation of the muscle enzyme creatinine phosphokinase (CPK). Trauma occurs frequently, either as a result of the fall, or as a result of the movements, e.g. posterior dislocation of the shoulder. Very rarely sudden death may occur from inhalation or an associated cardiac arrhythmia.

GENERALISED SEIZURES

Generalised seizure attacks arise from subcortical structures and involve both hemispheres. Consciousness may be impaired and motor manifestations are bilateral.

ABSENCES (SYN: *Petit mal*)

Onset usually in childhood (between 4 and 12 years of age). Family history in 40% of patients.

The absence may occur many times a day with a duration of 5–15 seconds.

The patient stares vacantly, eyes may blink and myoclonic jerks occur.

Attacks may be induced by hyperventilation.

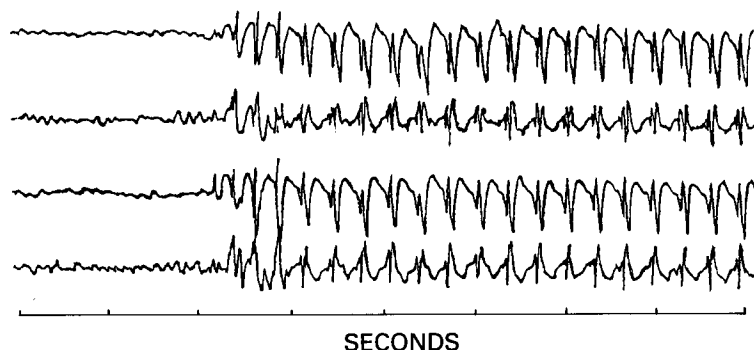
Frequent episodes lead to falling off in scholastic performance.

Attacks rarely present beyond adolescence.

In 30% of children, adolescence may bring tonic/clonic seizures (**Grand mal**).

Distinction of absences from complex partial seizures is easy; the latter are longer – 30 seconds or more – and followed by headache, lethargy, confusion and automatism.

The *ELECTROENCEPHALOGRAPH (EEG)* is diagnostic.



3 per second spike and wave activity occurs in all leads, persisting as long as the seizure.

Hyperventilation evokes this appearance during recording.

Similarly, photic stimulation – flashing a light in both eyes – may produce spike and wave discharge.

PETIT MAL STATUS

Long periods of clouding of consciousness with continuing 'spike and wave' activity on the EEG.

MYOCLONIC SEIZURES

Sudden, brief, generalised muscle contractions. They often occur in the morning and are occasionally associated with tonic/clonic seizures. The commonest disorder is benign juvenile myoclonic epilepsy (JME) with onset after puberty. Myoclonus also occurs in degenerative and metabolic disease (see page 186).

TONIC SEIZURES

Sudden sustained muscular contraction associated with immediate loss of consciousness.

Tonic episodes occur as frequently as tonic/clonic episodes in children and should alert the physician to a possible anoxic aetiology.

In adults, tonic attacks are rare.

GENERALISED SEIZURES

TONIC/CLONIC SEIZURES (SYN: Grand mal)

It is the absence of a focal onset which may distinguish this *primary* generalised seizure from that evolving from a partial seizure.

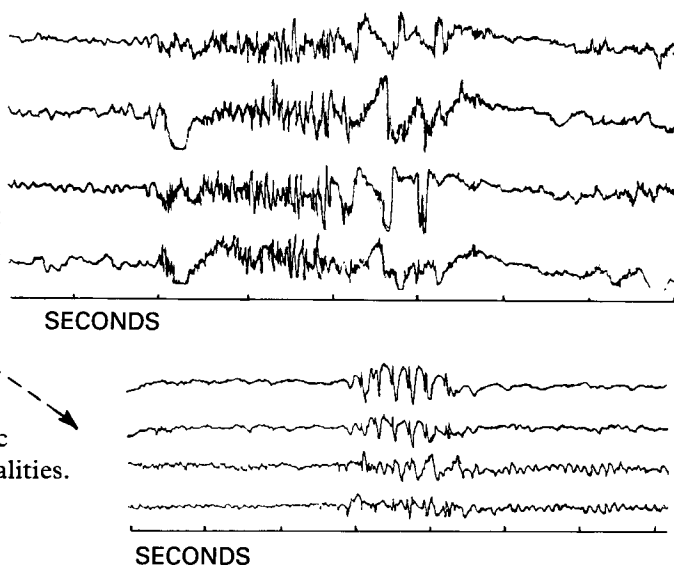
The *epileptic cry* must not be confused with a seizure of focal onset. This results from tonic contraction of respiratory muscles with partial closure of vocal cords. The tonic phase is associated with rapid neuronal discharge. The clonic phase begins as neuronal discharge slows.

The EEG during an attack is, not surprisingly, marred by movement artefact. 10–14 Hz spike activity may be seen.

When the seizure ends, the record may be 'silent' and then gradually picks up. Slow rhythm may persist for some hours – postictal changes.

The record between attacks may be normal or slow with occasional clinically silent bursts of seizure activity.

Again, hyperventilation or photic stimulation may bring out abnormalities.



ATONIC SEIZURES

These are characterised by a loss of muscle tone and a sudden fall. Consciousness may only be lost briefly. The EEG shows polyspike activity or low voltage fast activity.

UNCLASSIFIED SEIZURES

West Syndrome

Infants present with diffusely abnormal EEGs, tonic clonic convulsions, myoclonic jerks and mental retardation following perinatal trauma or asphyxia. The seizures are sometimes called infantile spasms and the abnormal EEG pattern between events – hypsarrhythmia. Mortality or severe disability is high.

Lennox-Gastaut Syndrome

This similar syndrome presents later between 1–7 years of age. The response to anticonvulsant treatment and the degree of retardation is variable. The condition is associated with a large number of disorders including hypoxia, intracranial haemorrhage, toxoplasmosis, cytomegalovirus infection and tuberous sclerosis.

The **REFLEX EPILEPSIES** are a rare group of seizure disorders in which tonic/clonic or complex partial seizures are evoked by sensory stimuli. A primary generalised seizure induced by photic stimulation may be regarded as a reflex epilepsy, but the term is usually reserved for:

1. **Musicogenic epilepsy** in which certain musical themes or tones 'trigger' seizures.
2. **Reading epilepsy** in which reading a passage will evoke involuntary jaw movements followed by a seizure.
3. **Arithmetical epilepsy** in which performing calculations will 'trigger' seizures.

EPILEPSY – DIFFERENTIAL DIAGNOSIS

The following should be considered in the differential diagnosis of epilepsy –

SYNCOPE (VASOVAGAL) ATTACKS

These attacks occur usually when the patient is standing and result from a global reduction of cerebral blood flow.

Prodromal pallor, nausea and sweating occur; if the patient sits down, the attack may pass off or proceed to a brief loss of consciousness.

Tonic and clonic movements may develop if impaired cerebral blood flow is prolonged ('anoxic' seizures).

Mechanism: Peripheral vasodilatation with drop in blood pressure followed by vagal overactivity with fall in heart rate.

Syncopal attacks occur in hot, crowded rooms (e.g. classroom) or in response to pain or emotional disturbance.

'Reflex' syncope from cardiac slowing may occur with carotid sinus compression. Similarly, cough syncope may result from vigorous coughing.

CARDIAC ARRHYTHMIAS

Seen in situations such as complete heart block (Adams-Stokes attacks).

Prolonged arrest of cardiac rate or critical reduction will progressively lead to loss of consciousness – tonic jerks – cyanosis/stertorous respiration – fixed pupils and extensor plantar responses.

On recovery of normal cardiac rhythm, the degree of persisting neurological damage depends upon the duration of the episode and the presence of pre-existing cerebrovascular disease. In suspected patients, electrocardiography is mandatory. Continuous (24 hours) ECG monitoring may be necessary.

MIGRAINE

The slow evolution of focal hemisensory or hemimotor symptoms in complicated migraine contrasts with the more rapid 'spread' of such manifestations in simple partial seizures. Basilar migraine may produce a transient loss of consciousness.

HYPOGLYCAEMIA

Amongst other neuroglycopenic manifestations, seizures or intermittent behavioural disturbances may occur. A rapid fall of blood sugar is associated with symptoms of catecholamine release, e.g. palpitations, sweating, etc. In 'atypical' seizures exclude a metabolic cause by blood sugar estimation when symptomatic.

EPISODIC CONFUSION

Intermittent confusional episodes caused by drugs (e.g. barbiturates) or toxins (e.g. solvents).

PANIC ATTACKS Hyperventilation can induce focal sensory symptoms.

NARCOLEPSY

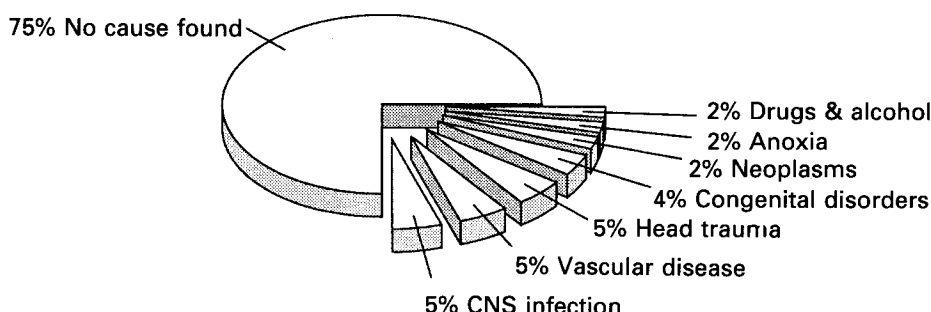
Inappropriate sudden sleep episodes may easily be confused with epilepsy (see page 103).

PSEUDOSEIZURES (non epileptiform seizures)

A difficult distinction lies between genuine epilepsy and attention seeking, hysterical or malingering episodes in which violent shaking and feigned loss of consciousness occurs. Often true epileptics will also manifest such attacks. Patients are usually suggestible, manipulative and with personality disorder. Many affected women have histories of sexual exploitation. EEG studies, serum prolactin and muscle enzyme studies may help discriminate.

EPILEPSY – CAUSATION

Epilepsy is often a symptom of disease rather than a disease itself. The approach to investigation depends on knowledge of potential causes:



Where no obvious cause is found there is often an increase in 'risk factors' – family history, febrile convulsion or difficult delivery.

Partial seizures with or without secondary generalisation

Age of onset gives a clue to causation. Each list is in order of frequency.

Newborn

Asphyxia
Intracranial haemorrhage
Hypocalcaemia
Hypoglycaemia
Hyperbilirubinaemia
Water intoxication
Inborn errors of metabolism
Trauma

Infancy

Febrile convulsions
CNS Infection
Trauma
Congenital defects
Inborn errors of metabolism

Childhood

Trauma
CNS Infection
Arteriovenous malformations
Congenital defects
Tumours

Adolescence and early adulthood

Trauma
CNS Infection
Tumours
Arteriovenous malformation
Drugs and alcohol

Late Adult

Drugs and alcohol
Trauma
Neoplasms
Vascular disease
Degenerative disease
CNS infection

Other general or systemic disorders may be associated with seizures e.g. metabolic disease and collagen vascular disorder. Seizures may rarely occur in multiple sclerosis. Some drugs may cause seizures. Antidepressants, antipsychotics, sympathomimetics, antineoplastics and certain general anaesthetic agents have all been incriminated.

Generalised epilepsies

There appears to be no clearly definable cause. Genetic factors play a role; concordance in monozygote twins is 75% for petit mal. An autosomal dominant gene would appear responsible for spike and wave abnormalities seen in the EEGs of parents and siblings of patients with generalised epilepsy. The defect is assumed to be metabolic though its nature is unknown.

EPILEPSY – INVESTIGATION

With an incidence of 0.5% in the population, selectivity in investigation is often necessary. CT scanning is not always routinely available.

The concern of the clinician is that epilepsy may be symptomatic of a treatable cerebral lesion. Investigations serve to define a cause and to aid diagnosis in difficult cases.

Routine Investigations

Haematology
 Biochemistry (electrolytes,
 urea and calcium)
 Chest X-ray
 Electroencephalogram (EEG)

CT or MRI should always be performed when seizures are:

- late in onset
- partial in type
- refractory in nature (to drug treatment)
- associated with abnormal
 clinical signs

or when epilepsy presents as status epilepticus

In doubtful cases the diagnosis should be deferred rather than labelling the patient 'epileptic'.

Specialised neurophysiological investigations

Indicated if attacks of unconsciousness are frequent or persistent and the diagnosis remains unclear.

Sleep deprived electroencephalography (EEG).
 'Activated' EEG recording with procyclidine or other drugs.
 Telemetric EEG recording over 24–48 hours often combined
 with video recording of the patients (split screen display).

These investigations may reveal 'diagnostic' epileptic discharges or confirm non-epileptiform seizures.

Advanced investigations

These are reserved for cases of intractable epilepsy where surgery is considered.

Telemetric, sphenoidal, foramen ovale and intraoperative EEG recording.
 Magnetic resonance imaging may display low grade gliomas, hamartomas, neuronal migration disorders or mesial temporal sclerosis, lesions often missed on CT scanning.
 Positron emission tomography (PET) or single photon emission computed tomography (SPECT) localise functional changes in cerebral blood flow and metabolism.

EPILEPSY – TREATMENT

The majority of patients respond to drug therapy (anticonvulsants). In intractable cases surgery may be necessary. Drug treatment should be simple, preferably using one anticonvulsant (monotherapy). Polytherapy is to be avoided especially as drug interactions occur between major anticonvulsants.

Treatment is aimed at rendering the patient 'fit free', though not always achieved. If the patient goes three years without an attack, withdrawal of therapy should be considered. Withdrawal should be carried out only if the patient is satisfied that a further fit would not ruin employment etc. (e.g. car driver). The risk of teratogenicity is well known (6%) especially with phenytoin, but withdrawing drug therapy in pregnancy is perhaps more risky than continuation. All anticonvulsants probably have some risk of producing fetal abnormalities, though these are usually mild. Sodium valproate has been incriminated in neural tube defects – spina bifida.

The introduction of assay of blood anticonvulsant levels has led to:

1. Identification of non-compliers – a common problem at epilepsy clinics.
2. Tailoring of drug dose to patient's requirements.
3. The realisation of failure with therapeutic levels of one anticonvulsant and thus the logical change to another.

The commonest anticonvulsants in present clinical use are:

Carbamazepine Sodium valproate Clonazepam Ethosuximide
Phenobarbitone Primidone Phenytoin

Sodium valproate is the first-line drug in the treatment of the generalised epilepsies in adults. In childhood use ethosuximide. Carbamazepine is the first-line drug in the treatment of partial seizures and partial seizures evolving to tonic/clonic seizures.

	<i>Sodium valproate</i>	<i>Phenobarbitone</i>	<i>Phenytoin</i>	<i>Carbamazepine</i>
<i>Mode of action</i>	Inhibitor of GABA transaminase and glutamate decarboxylase	Opens postsynaptic Cl ⁻ ion channels decreasing Na ⁺ & Ca ²⁺ influx	Blocks voltage dependent Na ⁺ channels in neuronal cell membrane	Blocks voltage dependent Na ⁺ channels in neuronal cell membrane
<i>Metabolised</i>	Liver Protein bound Short variable half-life	Liver or excreted in urine unchanged Long half-life (60 hours)	Liver Can saturate enzyme systems Long half-life	Liver Enzyme inducer Short half-life (10 hours)
<i>Dose (ADULT)</i>	2-3 x daily 600 mg to 3 g total daily dose	Can be given as single dose, e.g. 90 mg at night	Can be given as single dose e.g. 150-400 mg at night	2-3 x daily 600 mg to 1.2 g total daily dose
<i>Side effects</i>	Gastrointestinal upset Thrombocytopenia Drug-induced hepatitis Hair loss Tremor/chorea	Sedation. Depression Behavioural disturbance in children Skin rashes Withdrawal seizures	Gum hypertrophy Acne. Coarsening of facial characteristics At toxic levels - nystagmus - ataxia, diplopia - neuropathy	Gastrointestinal upset Ataxia Skin rash Agranulocytosis Antidiuretic effect

New anticonvulsants are available, sometimes used in conjunction with conventional drugs – Vigabatrin (inhibits GABA transaminase), Gabapentin (GABA analogue), Lamotrigine (inhibits glutamate release) and Flunarizine (Ca²⁺ channel blocker).

EPILEPSY – SURGICAL TREATMENT

In some patients, particularly those with complex partial epilepsy, despite adequate drug administration (checked by serum levels), recurrent seizures prevent a normal lifestyle; of these a proportion benefit from operation, provided seizures arise from a single focus. Theoretically, removal of the focus abolishes the partial seizure and can prevent progression to a generalised seizure.

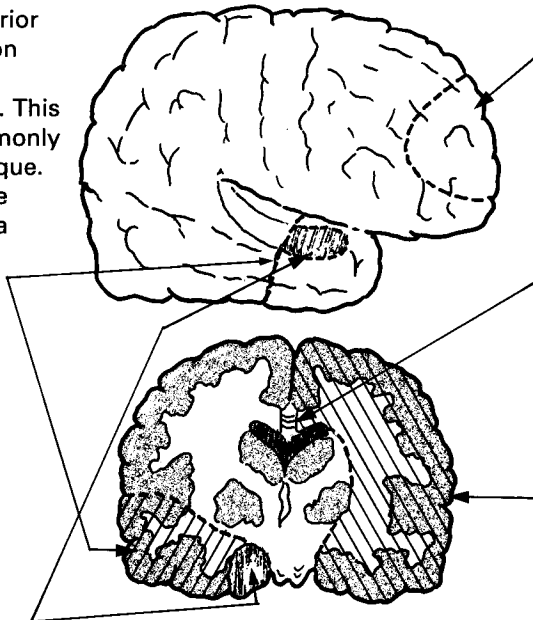
Extensive EEG investigation, and imaging with CT, MRI and SPECT or PET scanning helps identify the site of the primary focus. MRI may reveal an underlying structural abnormality (e.g. tumour, AVM, hamartoma or neuronal migration disorder) increasing the likelihood of improvement after operative removal. The discovery of a structural abnormality in itself may indicate the need for operation. In many patients with a temporal focus, MRI can also demonstrate asymmetry between medial temporal structures and signal change in a sclerotic, shrunken hippocampus, later confirmed by histology to show 'mesial temporal sclerosis'. It is not known whether this is the cause of the epilepsy or the result of anoxia during repeated attacks.

Operation is contraindicated in patients with severe mental retardation or with an underlying psychiatric problem.

Operative techniques

Temporal

Lobectomy: Anterior temporal resection incorporating the epileptogenic focus. This is the most commonly employed technique. Over half become seizure free and a further 30% gain significant improvement in seizure control.



Selective Amygdalo-hippocampectomy:

Possible when tests confirm a focus in medial temporal structures. Less tissue removed than with temporal lobectomy, but no evidence that this improves seizure control or reduces the mild cognitive changes occasionally seen.

Extra temporal cortical resection:

Incorporates the epileptogenic focus. Usually associated with focal pathology. Over half show some benefit after operation, but results less satisfactory than for temporal resection.

Corpus callosal section:

Prevents spread and reverberation of seizure activity between hemispheres. Most useful for patients with generalised atonic, tonic or myoclonic seizures, but only about two-thirds obtain some benefit. Few become seizure free.

Hemispherectomy:

Used in children with major irreversible damage to the whole hemisphere. Good results with over 80% becoming seizure free. Despite removing or disconnecting all but the basal ganglia, crude limb movements in the opposite limbs and walking are often preserved.

STATUS EPILEPTICUS

A succession of tonic/clonic convulsions, one after the other with a gap between each, is referred to as **serial epilepsy**.

When consciousness does not return between attacks the condition is then termed **status epilepticus**. This state may be life-threatening with the development of pyrexia, deepening coma and circulatory collapse.

Status epilepticus may occur with frontal lobe lesions, following head injury, on reducing drug therapy (especially phenobarbitone), with alcohol or other sedation withdrawal, drug intoxications (tricyclic antidepressants), infections, metabolic disturbances (hyponatraemia) or pregnancy.

TREATMENT

There is no completely satisfactory approach.
Death occurs in 5–10%.

NOTE: ALL DOSE REGIMES
APPLY TO ADULTS AND
NOT TO CHILDREN

General

Establish an airway.

O₂ inhalation 10 litres/minute.

I.V. infusion: 500 ml 5% dextrose/0.9N saline.

Vital signs recorded regularly – especially temperature.

Prevent hyperthermia (sponging, etc.).

Specific

Diazepam 5 mg i.v. followed, after 2 minutes gap, by further 5 mg i.v.

Effective for 10–20 minutes then seizures may return.

Beware respiratory depression with repeated injections.

When the effect of bolus injection wears off, a continuous diazepam infusion can be used (50–100 mg of diazepam in 500 ml dextrose/saline).

If not controlled then proceed to longer acting drug.

Phenytoin does not depress respiration.

Loading dose: 15 mg/kg given slowly i.v. at rate of 50 mg/min in normal saline.

Monitor ECG and blood pressure – there is a risk of arrhythmias and hypotension.

Contraindicated where known cardiac conduction defect or history of recent myocardial infarction.

Maintenance, 500 mg i.v. or orally, daily.

If condition persists 30 minutes after loading dose, phenobarbitone may be added, 200–300 mg i.v. given at rate of 50 mg/min.

Respiration should be monitored.

At this point seizures should be controlled.

120 mg phenobarbitone i.m. 4-hourly and 500 mg phenytoin i.v. daily should be given until oral therapy can be initiated.

Throughout treatment the patient should receive the previously established anticonvulsant treatment, especially when using drugs (e.g. diazepam) which have only a temporary effect.

STATUS EPILEPTICUS

Electrolytes as well as calcium and blood glucose should be checked initially and throughout. Blood gases should be estimated if clinically indicated.

Other drugs:

Chlormethiazole, midazolam and paraldehyde may be used in resistant status. Thiopentone at non-anaesthetising dosage, i.e. 2 ml/min i.v. for 30–60 minutes or general anaesthesia with neuromuscular blockade is reserved for life-threatening refractory status.

Non-convulsive status (complex partial and petit mal) as well as simple partial status do not threaten life and respond well to i.v. diazepam or i.v. phenytoin.

PROGNOSIS ON WITHDRAWAL OF DRUG TREATMENT

Several factors increase the likelihood of relapse of epilepsy after drug withdrawal:

- epilepsy associated with known cerebral damage
- infantile onset.

Drug withdrawal should be performed slowly. Within 2 years of withdrawing treatment, 50% of persons will suffer a further attack. EEG appearance does not predict outcome after withdrawing therapy. Withdrawal should only be considered after 3–5 years of continuing freedom from seizures.

EPILEPSY AND PREGNANCY

The frequency of seizures may decrease in pregnancy. The patient may present with the first seizure during pregnancy (when investigation is limited) or during the puerperium. Tumours and arteriovenous malformations can enlarge in pregnancy and produce such seizures; however, these causes are rare and most attacks are idiopathic. Cortical venous thrombosis and systemic lupus erythematosus should be considered as alternative explanations. Care must be taken when prescribing treatment in pregnancy although a change or withdrawal of medication is rarely necessary. The role of drugs in teratogenesis is complex; genetic mechanisms in epilepsy account for an increased incidence of birth defects. Over 90% of pregnant women with epilepsy will deliver a normal child.

THE FEBRILE CONVULSION

Febrile convulsions occur in the immature brain as a response to high fever, probably as a result of water and electrolyte disturbance.

No particular infection can be incriminated.

Usually occurs between 6 months and 3 years of age.

Rare after 5 years of age.

Recurrent in 50% of patients.

Long-term follow up suggests a liability to develop seizures in later life (unassociated with fever) especially in males, when seizures are prolonged and have focal features.

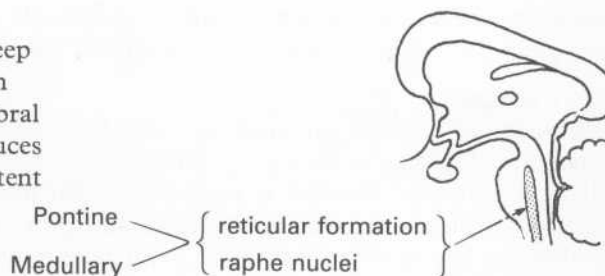
Treatment is aimed at preventing a prolonged seizure by sponging the patient and using rectal diazepam.

The role of prophylaxis after one seizure is debatable.

DISORDERS OF SLEEP

PHYSIOLOGY

Sleep results from activity in certain sleep producing areas of the brain rather than from reduced sensory input to the cerebral cortex. Stimulation of these areas produces sleep; damage results in states of persistent wakefulness.



Two states of sleep are recognised:

1. Rapid eye movement (REM) sleep

Characterised by: – Rapid conjugate eye movement
 – Fluctuation of temperature, BP, heart rate and respiration
 – Muscle twitching
 – Presence of dreams

Originates in: – Pontine reticular formation

Mediated by: – Noradrenaline

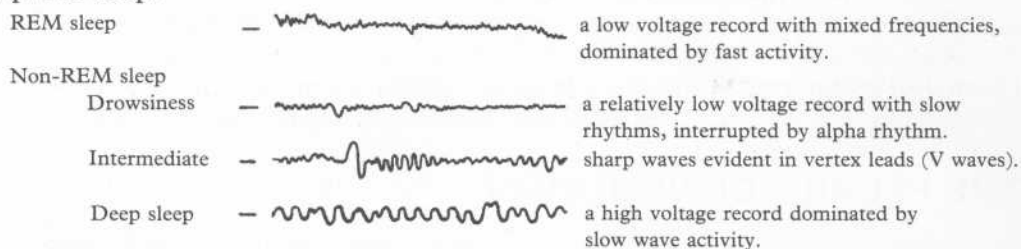
2. Non-rapid eye movement (non-REM) sleep

– Absence of eye movement
 – Stability of temperature, BP, heart rate and respiration
 – Absence of muscle twitching
 – Absence of dreams

– Midline pontine and medullary nuclei (raphe nuclei)

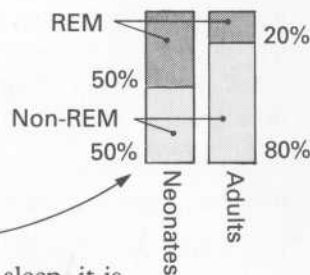
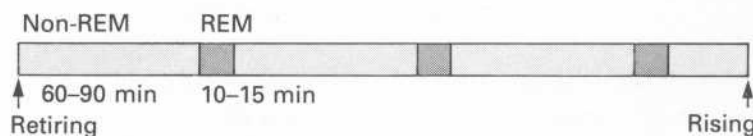
– Serotonin

The **electroencephalogram** shows characteristic patterns which correspond to the type and depth of sleep.



The sleep pattern

In adults non-REM and REM sleep alternate throughout the night.



The proportion of REM to non-REM varies with age.

In view of the important rôle of serotonin and noradrenaline in sleep, it is understandable that drugs may affect the duration and/or content of sleep.

DISORDERS OF SLEEP

NARCOLEPSY AND CATAPLEXY

Narcolepsy

An irresistible desire to sleep in inappropriate circumstances and places. Attacks occur suddenly and are of brief duration unless patient remains undisturbed.

Cataplexy

Sudden loss of postural tone. The patient crumples to the ground. Consciousness is preserved. Emotion – laughter or crying – can precipitate an attack.

The narcolepsy/cataplexy tetrad
Only 10% of patients manifest the complete tetrad

Sleep paralysis

On awakening, the patient is unable to move. This may last for 2–3 minutes.

Hypnagogic hallucinations

Vivid dreams or hallucinations occur as the patient falls asleep or occasionally when apparently awake.

Males are affected more than females. Prevalence 1:2000.

Onset is in adolescence/early adult life. The disorder is life long, but becomes less troublesome with age. It may have a familial incidence, or may occur after head injury, with multiple sclerosis, or with hypothalamic tumours. The cause remains unknown, though the increased incidence of certain histocompatibility antigens (DR2) in sufferers does suggest an immunological basis.

Diagnosis

The diagnosis is dependent upon the clinical history. The electroencephalogram may help, showing a REM pattern within 10 mins of sleep onset (normal – 90 minutes)

Treatment

Drugs which inhibit REM sleep may benefit: – amphetamines and their derivatives, e.g. dexamphetamine sulphate, methylphenidate hydrochloride.
– other drugs are preferable but have a selective effect: mazindol & pemoline for narcolepsy; clomipramine for cataplexy.

OTHER SLEEP DISORDERS (PARASOMNIAS)

NIGHT TERRORS (*pavor nocturnus*)

These occur in children, shortly after falling asleep and during deep to intermediate non-REM sleep. The child awakes in a state of fright with a marked tachycardia, yet in the morning cannot recollect the attack. Such attacks are not associated with psychological disturbance, are self limiting and if necessary will respond to diazepam.

NIGHTMARES

These occur during REM sleep. Drug or alcohol withdrawal promotes REM sleep and is often associated with vivid dreams.

SOMNAMBULISM (sleep walking)

Sleep walking varies from just sitting up in bed to walking around the house with the eyes open, performing complex major tasks. Episodes occur during intermediate or deep non-REM sleep. In childhood, somnambulism is associated with night terrors and bed wetting, but not with psychological disturbance. In adults, there is an increased incidence of psychoneurosis. Prevention of injury is important.

DISORDERS OF SLEEP

SLEEP STARTS (HYPNIC JERKS)

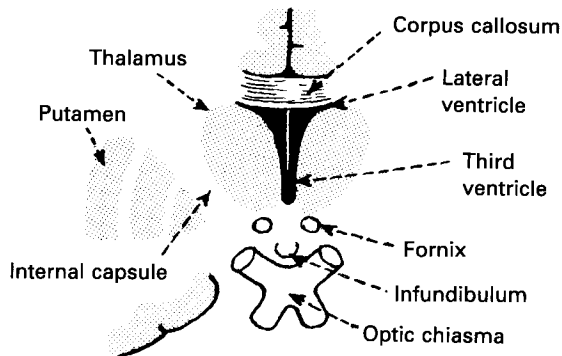
On entering sleep, sudden jerks of the arms or legs commonly occur and are especially frequent when a conscious effort is made to remain awake, e.g. during a lecture. This is a physiological form of myoclonus.

Other movement disorders in sleep: Restless legs, Dystonia, Bruxism (teeth grinding) and head banging.

HYPERSOMNIA

Lesions which affect the structures in the floor of the third ventricle may produce excessive sleepiness, e.g. tumours or encephalitis, and are often associated with diabetes insipidus.

Systemic disease such as myxoedema may result in hypersomnia, as may conditions which produce hypercapnia – chronic bronchitis, or primary muscle disease, e.g. dystrophia myotonica.



SLEEP APNOEA SYNDROMES

Respiratory rate fluctuates during REM sleep with occasional short episodes of apnoea. These are normal physiological events and are brief and infrequent.

Prolonged sleep apnoea results from central reduction of respiratory drive, a mechanical obstruction of the airway or a mixture of both.

Central causes:

Brain stem medullary infarction or following cervical/foramen magnum surgery.

Mechanical causes:

Obesity. Tonsillar enlargement.
Myxoedema. Acromegaly.

When breathing ceases, the resultant hypercapnia and hypoxia eventually stimulate respiration.

Patients may present with daytime sleepiness, nocturnal insomnia and early morning headache. Snoring and restless movements are characteristic. In severe cases of sleep apnoea, hypertension may develop with right heart failure secondary to pulmonary arterial hypertension. Polycythaemia and left heart failure may ensue.

Evaluation requires sleep oximetry and video recording with low level illumination. Fall in oxygen saturation may be as much as 50%.

Treatment depends on aetiology. Mechanical airway obstruction should be relieved; drugs such as theophylline are occasionally helpful. Continuous positive airway pressure (CPAP) applied to the nose may help. Surgical reconstruction of palate and oropharynx is offered in extreme cases.

The *Pickwickian syndrome*: sleep apnoea associated with obesity, named after the Dickens' fat boy who repeatedly fell asleep.

INSOMNIA

The most common sleep disorder, difficult to evaluate and of multiple causation including psychiatric, alcohol, drug related or due to systemic illness. Treatment depends on cause e.g. antidepressant.

HIGHER CORTICAL DYSFUNCTION

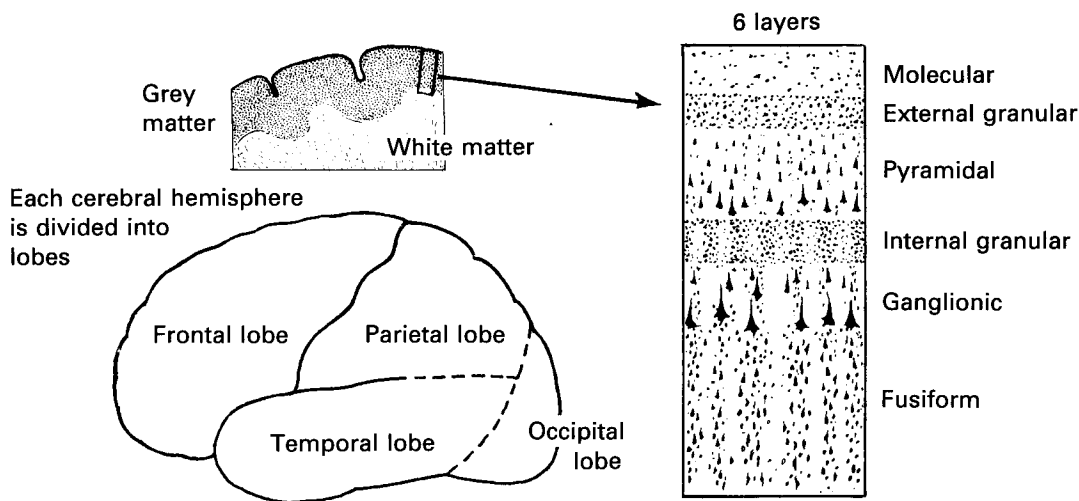
Specific parts of the cerebral hemispheres are responsible for a certain aspect of function. In normal circumstances these functions are integrated and the patient operates as a whole. Damage to part of the cortex will result in a characteristic disturbance of function. Interruption by disease of 'connections' between one part of the cortex and another will 'disconnect' function.

GENERAL ANATOMY

Brodmann, on the basis of histological differences, divided the cortex into 47 areas. Knowledge of these areas is not practical, though they are referred to often in some texts.

Six layers can be recognised in the cerebral cortex superficial to the junction with the underlying white matter.

The relative preponderance of each layer varies in different regions of the cortex and appears to be related to function.



The frontal motor cortex, dominated by pyramidal rather than granular layers, is termed the **AGRANULAR CORTEX**.

The parietal sensory cortex, dominated by granular layers, is termed the **GRANULAR CORTEX**.

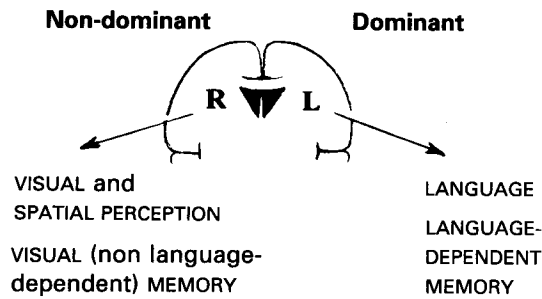
The largest cells of the agranular cortex are the giant cells of Betz. These give rise to some of the motor fibres of the corticospinal tract.

RIGHT AND LEFT HEMISPHERE FUNCTION

Unilateral brain damage reveals a difference in function between hemispheres. The left hemisphere is 'dominant' in right-handed people. In left-handed subjects the left hemisphere is dominant in the majority (up to 75%).

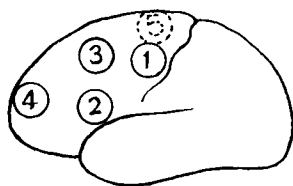
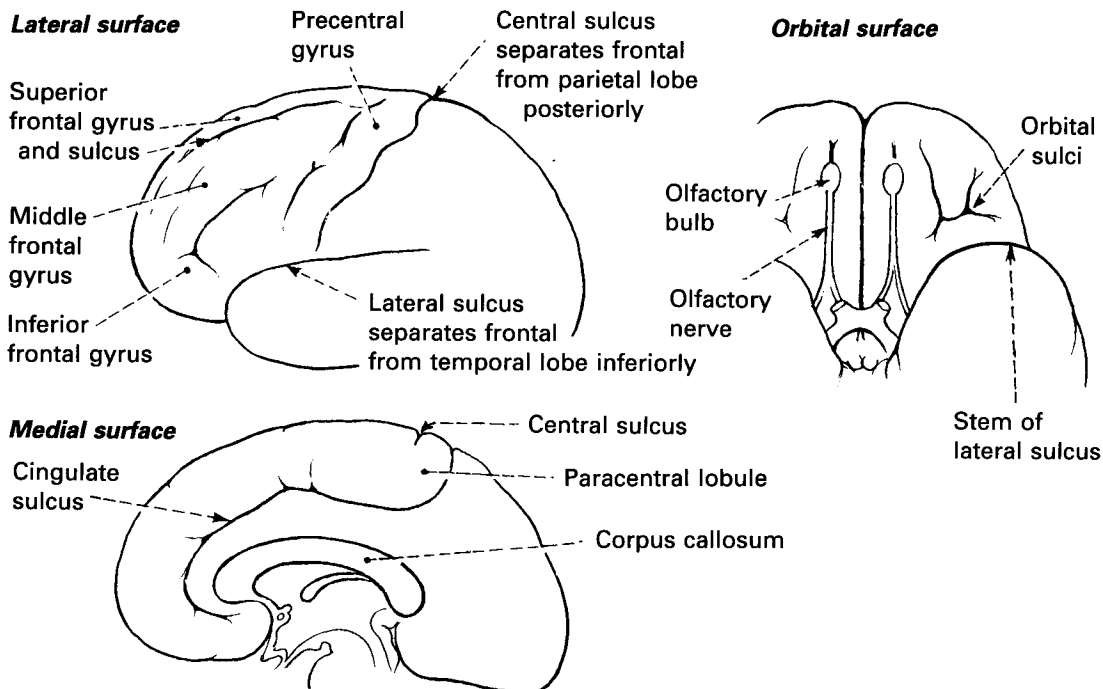
Hand preference may be hereditary, but in some cases disease of the left hemisphere in early life determines left-handedness.

HIGHER CORTICAL DYSFUNCTION



Hemisphere dominance may be demonstrated by the injection of sodium amytal into the internal carotid artery. On the dominant side this will produce an arrest of speech for up to 30 seconds – the WADA TEST. Such a test may be important before temporal lobectomy for epilepsy when handedness/hemisphere dominance is in doubt.

FRONTAL LOBES



FRONTAL LOBE FUNCTION

1. Precentral gyrus – motor cortex contralateral movement – face, arm, leg, trunk.
2. Broca's area – dominant hemisphere – expressive centre for speech.
3. Supplementary motor area – contralateral head and eye turning.
4. Prefrontal areas – 'personality', initiative.
5. Paracentral lobule – cortical inhibition of bladder and bowel voiding.

FRONTAL LOBES

IMPAIRMENT OF FRONTAL LOBE FUNCTION

1. Precentral gyrus

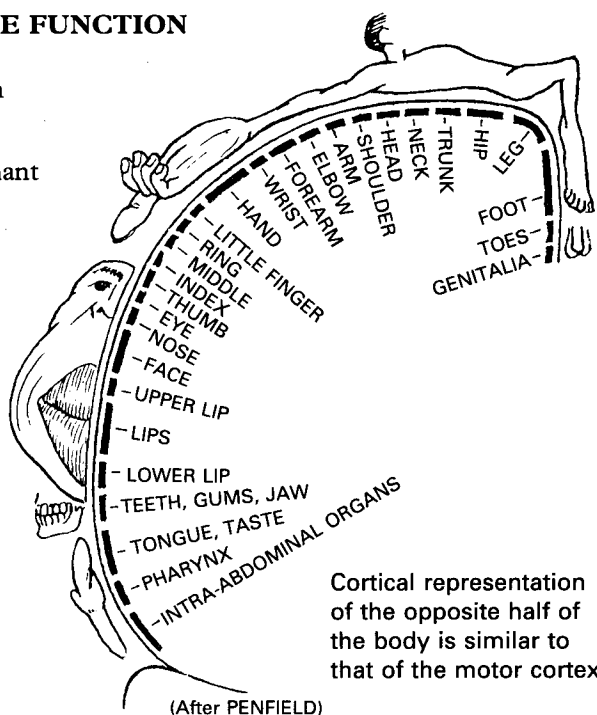
Monoplegia or hemiplegia depending on extent of damage.

2. Broca's area (inferior part of dominant frontal lobe)

Results in Broca's dysphasia (see page 120) (motor or expressive).

3. Supplementary motor area

Paralysis of head and eye movement to opposite side. Head turns 'towards' diseased hemisphere and eyes look in the same direction.



Cortical representation of the opposite half of the body is similar to that of the motor cortex.

(After PENFIELD)

4. Prefrontal areas (the vast part of the frontal lobes anterior to the motor cortex as well as undersurface – orbital – of frontal lobes)

Damage is often bilateral, e.g. infarction, following haemorrhage from anterior communicating artery aneurysm, neoplasm, trauma or anterior dementia, resulting in a change of personality with antisocial behaviour/loss of inhibitions.

Three pre-frontal syndromes are recognised

<i>Orbitofrontal syndrome</i>	<i>Frontal convexity syndrome</i>	<i>Medial frontal syndrome</i>
Disinhibition	Apathy	Akinetic
Poor judgement	Indifference	Incontinent
Emotional lability	Poor abstract thought	Sparse verbal output

Pre-frontal lesions are also associated with:

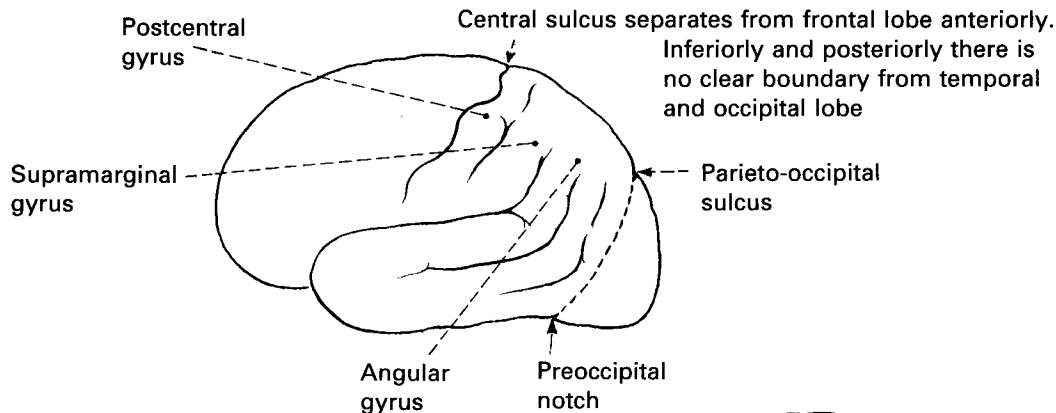
1. Primitive reflexes – grasp, pout, etc. (see page 123).
2. Disturbance of gait – 'gait apraxia'.
3. Resistance to passive movements of the limbs – paratonia.

Unilateral lesions may show minor degrees of such change.

5. Paracentral lobule

Damage to the posterior part of the superior frontal gyrus results in incontinence of urine and faeces – 'loss of cortical inhibition'. This is particularly likely with ventricular dilatation and is an important symptom of normal pressure hydrocephalus.

PARIETAL LOBES



PARIETAL LOBE FUNCTION

1. **Postcentral gyrus** (*granular cortex*)

The sensory cortex (representation similar to the motor cortex) receives afferent pathways for appreciation of posture, touch and passive movement.

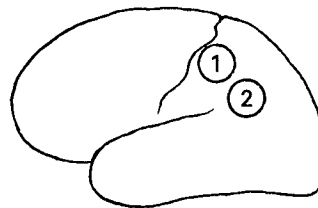
2. **Supramarginal and angular gyri** (*dominant hemisphere*) make up part of Wernicke's language area.

This is the receptive area where auditory and visual aspects of comprehension are integrated.

The **non-dominant** parietal lobe is important in the concept of body image and the awareness of the external environment. The ability to construct shapes, etc. results from such visual/proprioceptive skills.

The **dominant** parietal lobe is implicated in the skills of handling numbers/calculation.

The **visual pathways** – the fibres of the optic radiation (lower visual field) – pass deep through the parietal lobe.



IMPAIRMENT OF PARIETAL LOBE FUNCTION

1. Disease of **either dominant or non-dominant** sensory cortex (postcentral gyrus) will result in contralateral disturbance of cortical sensation:

Postural sensation disturbed.

Sensation of passive movement disturbed.

Accurate localisation of light touch may be disturbed.

Discrimination between one and two points (normally 4 mm on finger tips) is lost.

Appreciation of size, shape, texture and weight may be affected, with difficulty in distinguishing coins placed in hand, etc. (astereognosis).

Perceptual rivalry (sensory inattention) is characteristic of parietal lobe disease. Presented with two stimuli, one applied to each side (e.g. light touch to the palm of the hand) simultaneously, the patient is only aware of that one contralateral to the normal parietal lobe. As the gap between application of stimuli is increased (approaching 2–4 seconds) the patient becomes aware of both.

2. **Supramarginal and angular gyri** – Wernicke's dysphasia (see page 120).

PARIETAL LOBES


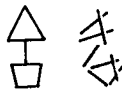
3. Non-dominant 4. Dominant

No longer aware of opposite (left-sided) limbs – even when densely hemiparetic; denies weakness – ANOSOGNOSIA.

Difficulty in dressing, e.g. getting arm into pyjamas – DRESSING APRAXIA.

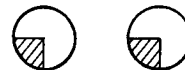Disturbance of geographical memory – GEOGRAPHICAL AGNOSIA (e.g. patient cannot find his bed in ward).

Cannot copy geometrical pattern – CONSTRUCTIONAL APRAXIA



Confusion of right and left limbs.
Difficulty in distinguishing fingers on hand – FINGER AGNOSIA.
Disturbance of calculation – ACALCULIA
Disturbance of writing – AGRAPHIA.

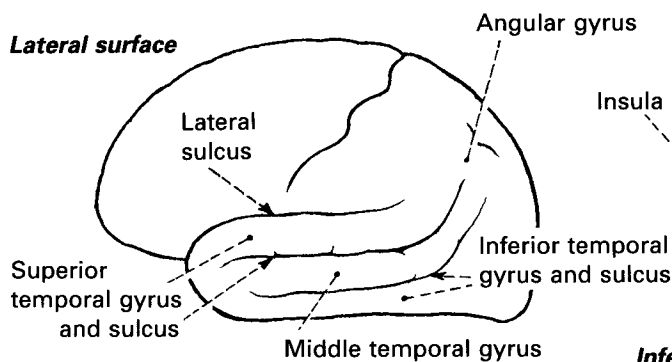
These comprise GERSTMANN'S SYNDROME



5. Damage to the **optic radiation** deep in the parietal lobe will produce a lower homonymous quadrantanopia

TEMPORAL LOBES

Lateral surface

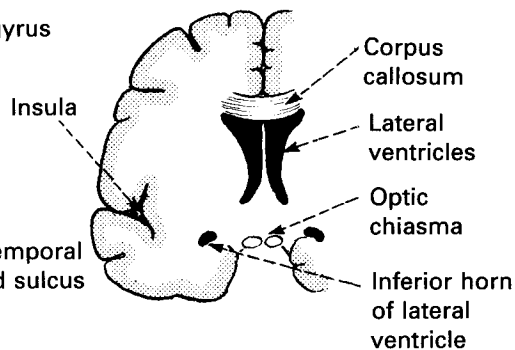


Anteriorly, the temporal lobe is separated from the frontal lobe by the lateral sulcus. Posteriorly and superiorly, separation from occipital and parietal lobes is less clearly defined.

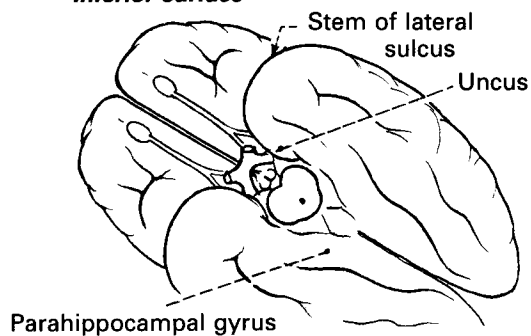
The lateral sulcus is deep and contains 'buried' temporal lobe. The buried island of cortex is referred to as the **INSULA**.

The temporal lobe also has a considerable inferior and medial surface in contact with the middle fossa.

Coronal section



Inferior surface



TEMPORAL LOBES

TEMPORAL LOBE FUNCTION

1. The **auditory cortex** lies on the upper surface of the superior temporal gyrus, buried in the lateral sulcus (Heschl's gyrus).

The **dominant** hemisphere is important in the hearing of language.

The **non-dominant** hemisphere is important in the hearing of sounds, rhythm and music. Close to the auditory cortex labyrinthine function is represented.

2. The **middle and inferior temporal gyri** are concerned with learning and memory (see later).

3. The **limbic lobe**: the inferior and medial portions of the temporal lobe, including the hippocampus and parahippocampal gyrus.

The sensation of olfaction is mediated through this structure as well as emotional/affective behaviour.

Olfactory fibres terminate in the uncus.

The limbic lobe or system also incorporates inferior frontal and medial parietal structures and will be discussed later.

4. The **visual pathways** pass deep in the temporal lobe around the posterior horn of the lateral ventricle.

IMPAIRMENT OF TEMPORAL LOBE FUNCTION

1. Auditory cortex

Cortical deafness: Bilateral lesions are rare but may result in complete deafness of which the patient may be unaware.

Lesions which involve surrounding association areas may result in difficulty in hearing spoken words (dominant) or difficulty in appreciating rhythm/music (non-dominant) – *AMUSIA*. Auditory hallucinations may occur in temporal lobe disease.

2. Middle and inferior temporal gyri

Disturbance of memory/learning will be discussed later.

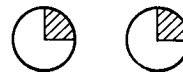Disordered memory may occur in complex partial seizures either after the event – postictal amnesia – or in the event – *deja vu, jamais vu*.

3. Limbic lobe damage may result in:

Olfactory hallucination with complex partial seizures.

Aggressive or antisocial behaviour.

Inability to establish new memories (see later).



4. Damage to **optic radiation** will produce an upper homonymous quadrantanopia. Dominant hemisphere lesions are associated with Wernicke's dysphasia.

OCCIPITAL LOBE

The occipital lobe merges anteriorly with the parietal and temporal lobes.

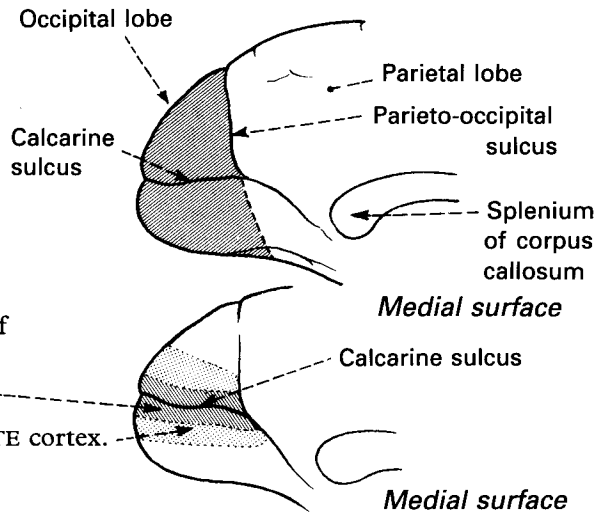
On the medial surface the calcarine sulcus extends forwards and the parieto-occipital sulcus separates occipital and parietal lobes.

OCCIPITAL LOBE FUNCTION

The occipital lobe is concerned with the perception of vision (the visual cortex).

The visual cortex lies along the banks of the calcarine sulcus – this area is referred to as the **STRIATE** cortex:

above and below this lies the **PARASTRIATE** cortex.



The *striate* cortex is the primary visual cortex and when stimulated by visual input relays information to the *parastriate* – association visual cortex. This, in turn, connects with the parietal, temporal and frontal lobes both on the same side and on the opposite side (through the posterior part of the corpus callosum) so that the meaning of a visual image may be interpreted, remembered, etc.

The visual field is represented upon the cortex in a specific manner (page 136).

IMPAIRMENT OF OCCIPITAL LOBE FUNCTION

A cortical lesion will result in a homonymous hemianopia with or without involvement of the macula, depending on the posterior extent of the lesion.

When only the occipital pole is affected, a central hemianopic field defect involving the macula occurs with a normal peripheral field of vision.

Cortical blindness

Extensive bilateral cortical lesions of the striate cortex will result in cortical **BLINDNESS**. In this, the pupillary light reflex is normal despite the absence of conscious perception of the presence of illumination (light reflex fibres terminate in the midbrain).

Anton's syndrome

Involvement of both the striate and the parastriate cortices affects the interpretation of vision. The patient is unaware of his visual loss and denies its presence. This denial in the presence of obvious blindness characterises Anton's syndrome.

Cortical blindness occurs mainly in vascular disease (posterior cerebral artery), but also following hypoxia and hypertensive encephalopathy or after surviving tentorial herniation.

Balint's syndrome

Inability to direct voluntary gaze, associated with visual agnosia (loss of visual recognition) due to bilateral parieto-occipital lesions.

OCCIPITAL LOBE

Visual hallucinations are common in migraine when the occipital lobe is involved; also in epilepsy when the seizure source lies here.

Hallucinations of occipital origin are elementary – unformed – appearing as patterns (zig-zags, flashes) and fill the hemianopic field, whereas hallucinations of temporal lobe origin are formed, complex and fill the whole of the visual field.

Visual illusions also may occur as a consequence of occipital lobe disease. Objects appear smaller (**MICROPSIA**) or larger (**MACROPSIA**) than reality. Distortion of a shape may occur or disappearance of colour from vision.

These illusions are more common with non-dominant occipital lobe disease.

Prosopagnosia: the patient, though able to see a familiar face, e.g. a member of the family, cannot name it. This is usually associated with other disturbances of 'interpretation' and naming with intact vision such as colour agnosia (recognition of colours and matching of pairs of colours). Bilateral lesions at occipito-temporal junction are responsible.

APRAXIA

A loss of ability to carry out skilled movement despite adequate understanding of the task and normal motor power.

Constructional and dressing apraxia: See page 109, non-dominant parietal disease.

Gait apraxia: Difficulty in initiating walking – frontal lobe/anterior corpus callosum disease.

Oculomotor apraxia: Impaired voluntary eye movement – parieto-occipital disease.

Ideomotor apraxia: Separation of idea of movement from execution – cannot carry out motor command but can perform the required movement under different circumstances – dominant hemisphere (see later).

Ideational apraxia: Inability to carry out a sequence of movements each of which can be performed separately – frontal lobe disease.

HIGHER CORTICAL DYSFUNCTION THE DISCONNECTION SYNDROMES

Cortical function is described, on the previous pages, 'lobe by lobe'. These functions integrate by means of connections between hemispheres and lobes. Lesions of these connecting pathways disorganise normal function, resulting in recognisable syndromes – the disconnection syndromes. APRAXIA is a feature of some of these disorders.

The connecting pathways may be divided into:

Intrahemispheric: lying in the subcortical white matter and linking parts of the same hemisphere.

Interhemispheric: traversing the corpus callosum and linking related parts of the two hemispheres.

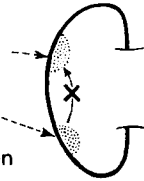
THE INTRAHEMISPHERIC DISCONNECTION SYNDROMES

1. Conduction Aphasia

Lesion of the arcuate fasciculus linking Wernicke's and Broca's speech areas.

Characterised by:

Fluent dysphasic speech. Good comprehension of written/spoken material. Poor repetition.

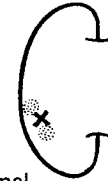

2. Pure word deafness

Lesion of the connection between the primary auditory cortex (Herschl's gyrus) and auditory association cortex.

Characterised by:

Impaired comprehension of spoken word. Self-initiated language is normal. The patient seems deaf, but audiometry is normal.



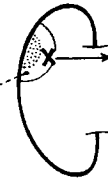
3. Buccal lingual and 'sympathetic' apraxia

Involves the links between left and right association motor cortices in the subcortical region.

Characterised by:

Right brachiofacial weakness and apraxia of tongue, lip and left limb movements.

Premotor motor cortex
Broca's area



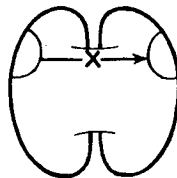
THE INTERHEMISPHERIC DISCONNECTION SYNDROMES

1. Left side apraxia

Lesion of the anterior corpus callosum with interruption of the connections between the left and right association motor cortices.

Characterised by:

Apraxia of left sided limb movements.

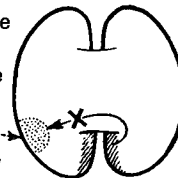


2. Pure word blindness or alexia without agraphia

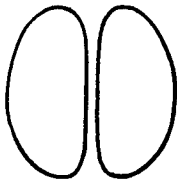
Lesion of the posterior corpus callosum and dominant occipital lobe with interruption of connections between the visual cortex and the angular gyrus/Wernicke's area.

Characterised by:

Inability to read, to name colours, to copy writing, but with normal spontaneous writing and the ability to identify colours.



3. Agenesis of the corpus callosum



This is a developmental disorder with no connection between the two hemispheres.

Characterised by:

A failure to name an object presented visually or by touch to the non-dominant hemisphere. (The right and left visual fields cannot match presented objects.)

HIGHER CORTICAL FUNCTION – MEMORY

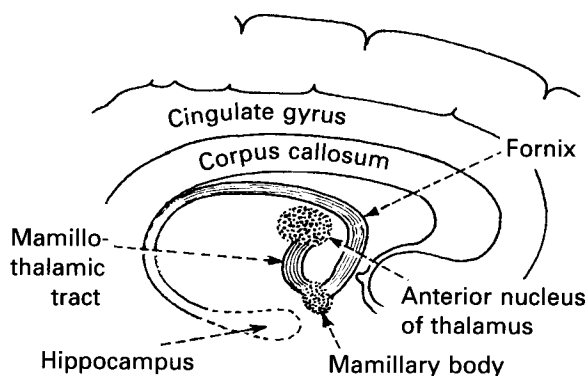
Normal memory involves the recognition, registering and cataloguing of a stimulus – *acquisition*, as well as the skill of appropriate recall – *retrieval*.

- Verbal memory:** refers to material presented in the verbal form.
- Visual memory:** denotes material presented without words or verbal meditation.
- Short term memory:** immediate recall of a short message.
- Long term memory:** retrieval of recent or remote events.
- Semantic memory:** refers to long established factual knowledge.

Disordered memory may be confused with disturbances of attention, motivation and concentration and requires detailed neuropsychological examination to properly assess.

THE ANATOMICAL BASIS OF MEMORY

The structures of the limbic system involved in the memory process are inferred from the pathological examination of diseases that disorder function. The *hippocampus*, a deep structure in the temporal lobe, rides the floor of the lateral ventricle. Fimbriae of the hippocampus connect this structure to the *fornix*. There appears to be a loop from hippocampus → fornix → mamillary body → thalamus → cingulate gyrus → back to hippocampus.



	Mamillary bodies	Thalamus	Orbito-frontal cortex	Medial temporal cortex/ hippocampus	Fornix
Korsakoff's	+	+			
Head trauma		+	+	+	+
Stroke		+		+	+
Encephalitis				+	+
Anoxia				+	+
Metabolic				+	+
Temporal lobectomy				+	
3rd ventricular operations					+

TESTS OF MEMORY (see examination, page 8)

These aim to distinguish loss of immediate, recent or remote memory.

Disorders may be further classified into those which affect memories established before the injury or damage – **RETROGRADE AMNESIA** – and those which affect memory of events following the injury or damage – **ANTEROGRADE** or **POST-TRAUMATIC AMNESIA**.

DISORDERS OF MEMORY

THE AMNESIC SYNDROME is characterised by –

- Retrograde amnesia* – impairment of memory for events that antedate illness or injury
- Anterograde amnesia* – inability to learn new verbal or non verbal information from onset of the illness or injury
- Intact retrieval of old information
- Intact intellectual function
- Intact personality
- Tendency to confabulate

CAUSES

Korsakoff's syndrome: results from – alcoholism
– encephalitis
– head injury

Lesions occur within the thalamus and the mamillary bodies. Commonly associated with confabulation – a false rationalisation of events and circumstances.

Post-traumatic amnesia: after trauma, retrograde amnesia may span several years, but with recovery, this gradually diminishes. The duration of post-traumatic amnesia on the other hand remains fixed and relates directly to the severity of the injury.

Amnesic stroke: bilateral medial temporal lobe infarction from a posterior circulation stroke is usually associated with hemiplegia and visual disturbance or loss e.g. Anton's or Ballint's syndrome (page 111).

Amnesia with tumours: tumours that compress thalamic structures or the fornix may produce amnesia – e.g. colloid cyst of the 3rd ventricle.

Temporal lobectomy: amnesia will only occur if function in the unoperated temporal lobe is abnormal. Pre-operative assessment during a unilateral carotid injection of sodium amytal minimises this risk.

Transient global amnesia: memory loss of less than 36 hours during which time patients will often carry out complex cognitive tasks e.g. drive to the office and do a day's work. There is usually nothing objectively wrong. Episodes are sometimes precipitated by exercise. The disorder is benign but requires investigation to exclude temporal lobe disease.

Psychogenic amnesia: affects overlearned and personally relevant aspects of memory e.g. 'What is my name?', while less well learned memory remains unaffected. Clinically evident acute mental stress may precipitate this. This inadequate defence mechanism suggests a serious underlying psychiatric or personality disorder.

DISORDERS OF MEMORY RETRIEVAL

Senescence – as part of normal aging, rapid retrieval of stored memory becomes defective.

Depression – impaired memory is a common complaint in depressive illness. The disorder is one of motivation and concentration.

Subcortical dementia – This will be described later (page 122). The major abnormality is that of a slowed (but correct) response rate to questions of memory function.

NB DEMENTIA, TUMOURS and CEREBROVASCULAR DISEASE are all often associated with memory loss but this is usually combined with evidence of more widespread disordered cognitive function.

DISORDERS OF SPEECH AND LANGUAGE

Introduction

Disturbed speech and language are important symptoms of neurological disease. The two are not synonymous. Language is a function of the dominant cerebral hemisphere and may be divided into (a) *emotional* – the instinctive expression of feelings representing the earliest forms of language acquired in infancy and (b) *symbolic or propositional* – conveying thoughts, opinions and concepts. This language is acquired over a 20-year period and is dependent upon culture, education and normal cerebral development.

An understanding of disorders of speech and language is essential, not just to the clinical diagnosis but also to improve communication between patient and doctor. All too often patients with language disorders are labelled 'confused' as a consequence of superficial evaluation.

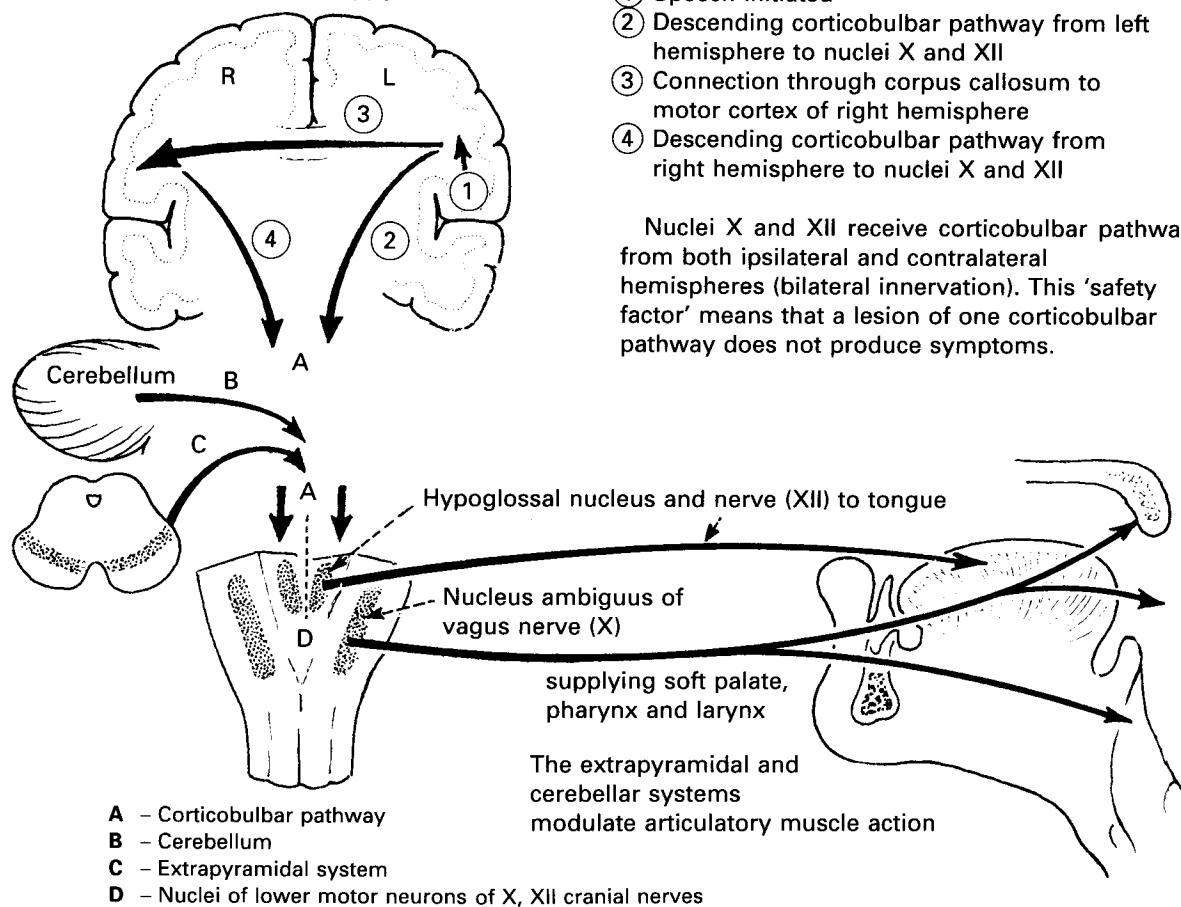
DYSARTHRIA

Dysarthria is a *disturbance of articulation* in which the content of speech – language – is unaffected.

Mechanism of articulation

- ① Speech initiated
- ② Descending corticobulbar pathway from left hemisphere to nuclei X and XII
- ③ Connection through corpus callosum to motor cortex of right hemisphere
- ④ Descending corticobulbar pathway from right hemisphere to nuclei X and XII

Nuclei X and XII receive corticobulbar pathway from both ipsilateral and contralateral hemispheres (bilateral innervation). This 'safety factor' means that a lesion of one corticobulbar pathway does not produce symptoms.



- A – Corticobulbar pathway
- B – Cerebellum
- C – Extrapyramidal system
- D – Nuclei of lower motor neurons of X, XII cranial nerves

Muscles of expression, innervated by the facial nerve, play an additional role in articulation and weakness also results in dysarthria.

DISORDERS OF SPEECH – DYSARTHRIA

DIAGNOSTIC APPROACH

Listen to spontaneous speech and ask the patient to read aloud.

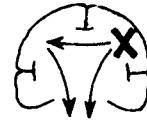
Observe: lingual consonants – ‘*ta ta ta*’ (made with the tongue), labial consonants – ‘*mm mm mm*’ (made with the lips), guttural consonants – ‘*ga ga ga*’ (laryngeal and pharyngeal/palatal). Difficulty with articulation = **DYSARTHRIA**

N.B. Beware misinterpretation of dialect or poorly fitting teeth.

Speech hoarse and strained; labial consonants especially affected.

Associated **contralateral hemiparesis or dysphasia**

→ SPASTIC DYSARTHRIA (Cortical origin)



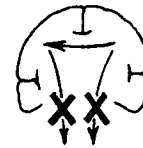
Causative diseases

e.g. Middle cerebral artery occlusion.
Neoplasm.

Speech slow and monotonous with abnormal separation of syllables – ‘*scanning speech*’; at times may sound explosive –

Other signs of pseudobulbar palsy (impaired chewing, swallowing)

→ SPASTIC DYSARTHRIA (Corticobulbar origin)



e.g. Bilateral small vessel occlusion.

Motor neuron disease.

Associated signs of cerebellar disease

→ ATAXIC DYSARTHRIA

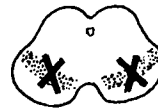

(Lesion in cerebellar vermis and paravermis)

e.g. Multiple sclerosis, Hereditary ataxias.

Soft and monotonous with poor volume and little inflection – and short rushes of speech

→ HYPOKINETIC (slow) HYPER-KINETIC (fast) DYSARTHRIA (Lesion of the extrapyramidal system)



Parkinson’s disease.

Huntington’s chorea.

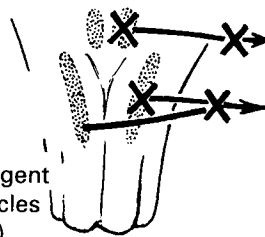
Associated signs of extrapyramidal disease

Labial consonants first affected, later gutturals. *Nasal speech* and progression to total loss of articulation (*anarthria*).

→ FLACCID DYSARTHRIA

Associated signs of l.m.n. weakness of X and XII

(Involvement of X and XII nuclei or emergent nerves to muscles of articulation,)



e.g. Motor neuron disease.
Bulbar poliomyelitis.
Cranial polyneuritis.

Many diseases affect multiple sites and a ‘mixed’ dysarthria occurs.

For example, multiple sclerosis with corticobulbar and cerebellar involvement will result in a mixed spastic/ataxic dysarthria.

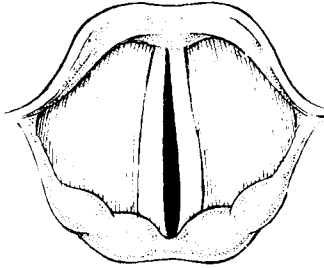
DISORDERS OF SPEECH – DYSPHONIA

Sound is produced by the passage of air over the vocal cords.

Respiratory disease or vocal cord paralysis results in a disturbance of this facility – **dysphonia**. A complete inability to produce sound is referred to as **aphonia**. Dysarthria often co-exists.

DIAGNOSTIC APPROACH

If, despite attempts, there is deficient sound production then examine the vocal cords by *indirect laryngoscopy*.

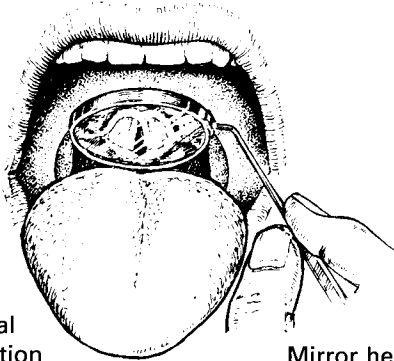


Causative Diseases

e.g. Medullary damage:
 – infarction
 – syringobulbia

Paralysis of both vocal cords

Patient speaks in whispers and inspiratory stridor is present.

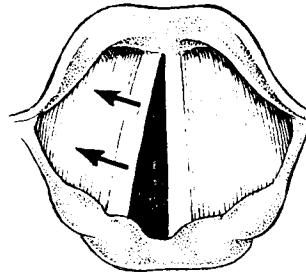


Normal abduction of vocal cords – 'Ahh'

Mirror held in posterior pharynx

Spastic Dysphonia

Sounds as though speaking while being strangled!
 May be a functional disorder, form of 'focal' dystonia, occurs with essential tremor or hypothyroidism.



e.g. Recurrent laryngeal nerve palsy:
 – following thyroid surgery
 – bronchial neoplasm
 – aortic aneurysm

Paralysis of left vocal cord

which does not move with 'Ahh' while right abducts. When patient says 'E' normal cord will move towards paralysed cord. The voice is weak and 'breathy' and the cough 'bovine'.

OTHER DISORDERS OF SPEECH

Mutism: An absence of any attempt at oral communication. It may be associated with bilateral frontal lobe or third ventricular pathology (see Akinetic mutism).

Echolalia: Constant repetition of words or sentences heard in dementing illnesses.

Palilalia: Repetition of last word or words of patient's speech. Heard in extrapyramidal disease.

Logorrhoea: Prolonged speech monologues; associated with Wernicke's dysphasia.

DISORDERS OF LANGUAGE - DYSPHASIA

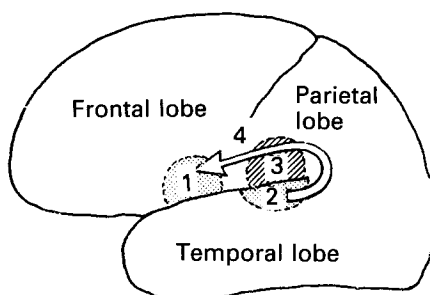
Dysphasia is an acquired loss of production or comprehension of spoken and/or written language secondary to brain damage.

Hand preference is associated with 'hemisphere dominance' for language. In right-handed people the left hemisphere is dominant; in left-handed people the left hemisphere is dominant in most, though 25% have a dominant right hemisphere.

The cortical centres for language reside in the dominant hemisphere.

1. Broca's area

Executive or motor area for the production of language – lies in the inferior part of the frontal lobe on the lateral surface of the cerebral hemisphere abutting the mouth of the Sylvian fissure.



2 and 3 Receptive areas

Here the spoken word is understood and the appropriate reply or action initiated. These areas lie at the posterior end of the Sylvian fissure on the lateral surface of the hemisphere.

The temporal lobe receptive area (2) lies close to the auditory cortex of the transverse gyrus of the temporal lobe. The parietal lobe receptive area (3) lies within the angular gyrus.

Receptive and expressive areas must be linked in order to integrate function. The link is provided by (4), the **arcuate fasciculus**, a fibre tract which runs forwards in the subcortical white matter.

Dysphasia may develop as a result of vascular, neoplastic, traumatic, infective or degenerative disease of the cerebrum when language areas are involved.

DISORDERS OF LANGUAGE – DYSPHASIA

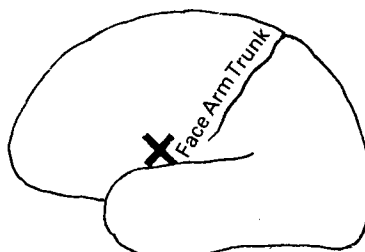
DIAGNOSTIC APPROACH

Listen to content and fluency of speech. Test comprehension, i.e. simple then complex commands

Assess
 - Spontaneous speech
 - Naming objects
 - Repetition
 - Reading
 - Writing

Non-fluent, hesitant speech; may be confined to a few repeated utterances or, in less severe cases, is of a 'telegraphic' nature with articles and conjunctions omitted. Good comprehension. Handwriting poor. Look for coexisting right arm and face weakness.

BROCA'S DYSPHASIA
 (Motor or expressive dysphasia)

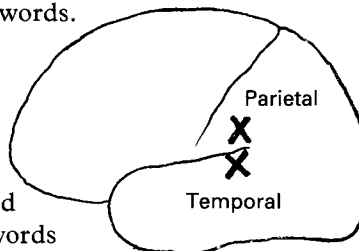


Causative diseases

- Vascular disease
- Neoplasm
- Trauma
- Infective disease
- Degenerative disease

Comprehension impaired. Speech nonsensical but fluent. neologisms – nonexistent words. paraphrasia – half right words. Patient unaware of language problem. Handwriting poor.

WERNICKE'S DYSPHASIA
 (Sensory or receptive dysphasia)



- Vascular disease
- Neoplasm
- Trauma
- Infective disease
- Degenerative disease

Differentiate from confused patient – construction of words and sentences are normal.

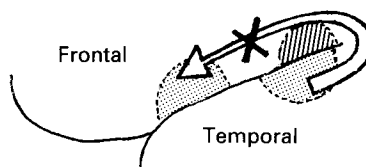
Non-fluent speech and impaired comprehension. Often associated with hemiplegia/hemianaesthesia and visual field deficit.

GLOBAL DYSPHASIA
 Damage involving a large area of the dominant hemisphere.

- Vascular disease
- Neoplasm
- Trauma
- Infective disease
- Degenerative disease

Speech nonsensical but fluent (neologisms and paraphrasia) yet comprehension is normal. Repetition is poor.

CONDUCTION DYSPHASIA



- Vascular disease
- Neoplasm
- Trauma
- Infective disease
- Degenerative disease

DEMENTIAS

Definition

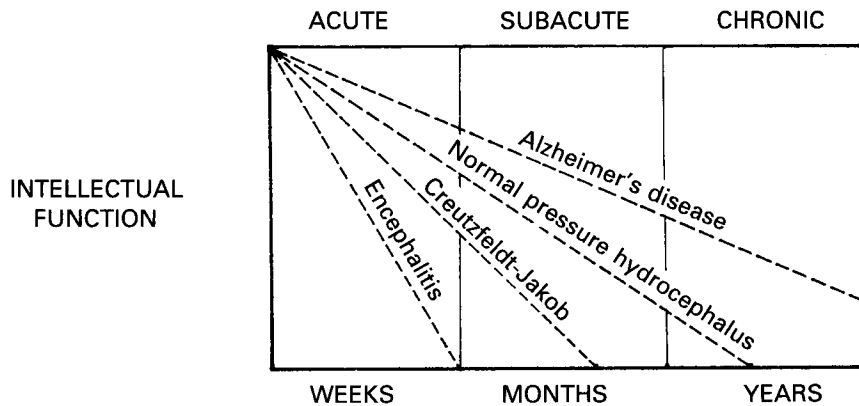
Progressive deterioration of intellect, behaviour and personality as a consequence of diffuse disease of the cerebral hemispheres, maximally affecting the cerebral cortex and hippocampus.

Distinguish from *delirium* which is an acute disturbance of cerebral function with impaired conscious level, hallucinations and autonomic overactivity as a consequence of toxic, metabolic or infective conditions.

Dementia may occur at any age but is more common in the elderly, accounting for 40% of long-term psychiatric in-patients over the age of 65 years. A recent study shows an annual incidence rate of 187/100 000 persons. Dementia is a symptom of disease rather than a single disease entity. When occurring under the age of 65 years it is labelled 'presenile' dementia. This term is artificial and does not suggest a specific aetiology.

Clinical course:

The rate of progression depends upon the underlying cause.



The duration of history helps establish the cause of dementia; Alzheimer's disease is slowly progressive over years, whereas encephalitis may be rapid over weeks. Dementia due to cerebrovascular disease appears to occur 'stroke by stroke'.

All dementias show a tendency to be accelerated by change of environment, intercurrent infection or surgical procedures.

Development of symptoms

Introspective. Unsure of self. →	Difficulty in coping with work and ordinary routine → (retained insight).	Loss of insight, behavioural changes, loss of inhibition.
	Mutism, incontinence and DEATH ←	↓ Long-term care. Cannot be left unattended.

This initial phase of dementia may be inseparable from the *pseudodementia* of depressive illness.

DEMENTIAS – CLASSIFICATION

Based on cause

Alzheimer's

Cerebrovascular

- Multi-infarct dementia
- Subcortical vascular disease (Binswanger's disease)

Neurodegenerative

- Pick's disease
- Huntington's chorea
- Parkinson's disease

Infectious

- Creutzfeld-Jakob disease
- HIV infection
- Viral encephalitis
- Progressive multifocal leucoencephalopathy

Normal pressure hydrocephalus

Nutritional

- Wernicke Korsakoff (thiamine deficiency)
- B₁₂ deficiency
- Folate deficiency

Metabolic

- Hepatic disease
- Thyroid disease
- Parathyroid disease
- Cushing's syndrome

Chronic inflammatory

- Collagen vascular disease and vasculitis
- Multiple sclerosis

Trauma

- Head injury
- 'Punch drunk' syndrome

Tumour

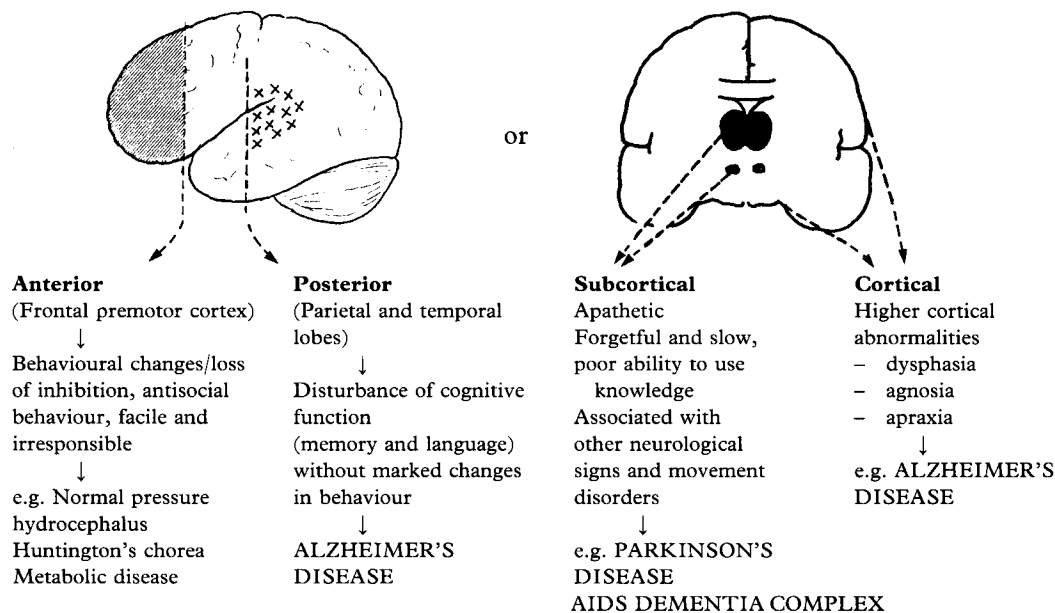
- e.g. Subfrontal meningioma

Alzheimer's disease accounts for 60% of all dementias; cerebrovascular disease 20%.

It is important to investigate all patients with dementia as many causes are treatable; in practice 10–15% can be reversed.

Based on site

Subdividing dementia depending upon the site of predominant clinical involvement is of questionable diagnostic value. However, many clinicians use this classification:



DEMENTIAS – HISTORY AND CLINICAL EXAMINATION

When obtaining a history from a demented person and relative, establish:

- Rate of intellectual decline
- Impairment of social function
- General health and relevant disorders, e.g. stroke, head injury
- Nutrition status
- Drug history
- Family history of dementia.

Tests to assess intellectual function are designed to check:

- Memory
- Abstract thought
- Judgement
- Specific higher cortical functions

A simple bedside battery of tests includes:

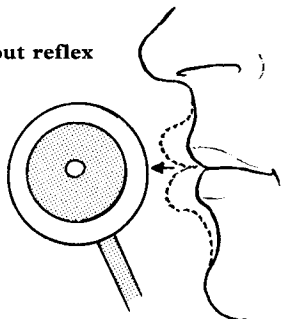
- Age
- Place of birth
- Date of birth
- School
- Date
- Time of day
- Season of year
- Prime Minister
- Dates of World War II
- Months backwards
- Interpretation of proverbs
- Following three stage commands
- Read and obey instructions
- Name objects
- Copy design
- Serial 7s

In early or pseudodementia a formal assessment from a clinical psychologist is advisable.

On neurological examination note:

- Focal signs
- Involuntary movements
- Pseudobulbar signs
- Primitive reflexes:

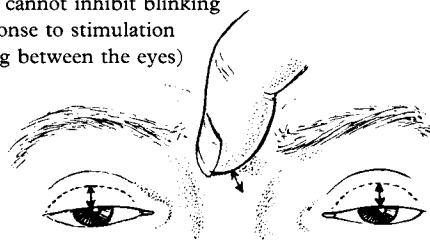
Pout reflex



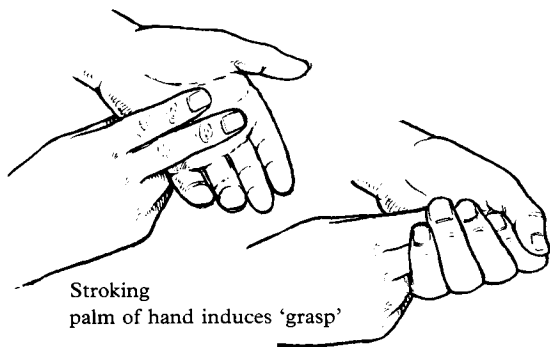
Tap lips with tendon hammer – a pout response is observed

Glabellar reflex

Patient cannot inhibit blinking in response to stimulation (tapping between the eyes)

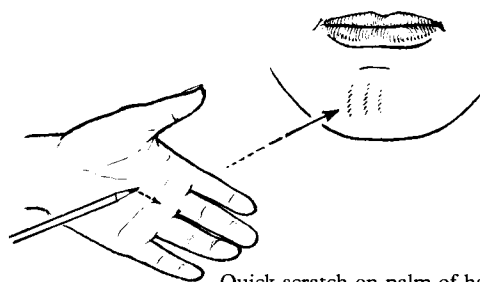


Grasp reflex



Stroking palm of hand induces 'grasp'

Palmomentary reflex



Quick scratch on palm of hand induces sudden contraction of mentalis muscle in face

Primitive reflexes are present in infancy and in aged people, as well as in dementia.

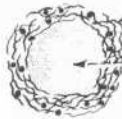
DEMENTIAS – SPECIFIC DISEASES

ALZHEIMER'S DISEASE

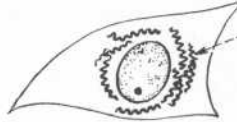
This is the commonest cause of dementia with an estimated half million sufferers in the UK. The disorder rarely occurs under the age of 45 years. The incidence increases with age. Up to 30% of cases are familial.

Pathology

(i) **Neuritic plaque:** a complex extracellular lesion of 15-100µm. Aggregates of filaments with a central core of amyloid. Found in the hippocampus and parietal lobes



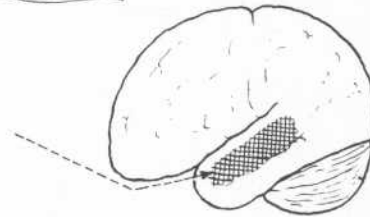
(ii) **Neurofibrillary tangle:** an intracellular lesion. Paired helical strands of protein close to nuclei of neurons. Mainly affecting pyramidal cells of cortex



These lesions are associated with neuronal loss and granulovacuolar degeneration

The brain is small with atrophy most evident in the superior and middle temporal gyri.

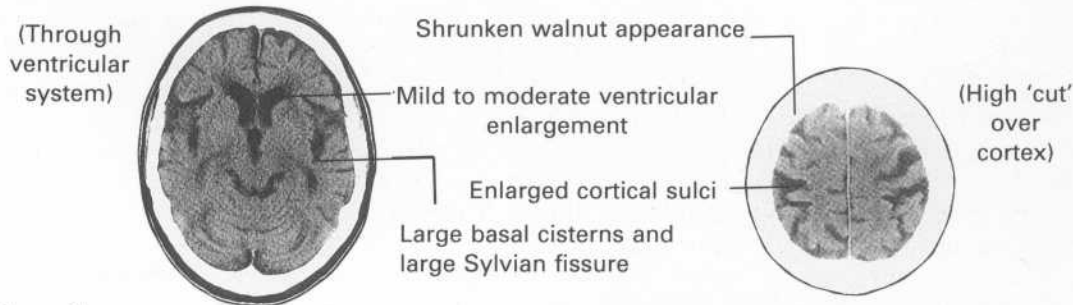
Subcortical origins of cholinergic projections are also involved.



Diagnosis may be established during life by the early memory failure and slow progression and by excluding other causes.

Recent claims that β amyloid deposition also occurs in skin and intestine raises hopes of biopsy as a diagnostic marker.

CT scanning: aids diagnosis by excluding multiple infarction or a mass lesion.



Causation

The cause of Alzheimer's disease is not known. An association with Down's syndrome suggests a disease locus on chromosome 21 (on which amyloid precursor protein is coded), and this has been confirmed in familial cases. The role of environmental toxins, especially aluminium, is uncertain. Early research suggested selective lesions of neurotransmitter pathways occurred and a disorder of cholinergic innervation was postulated. It is now known that many neurotransmitter pathways are defective.

Treatment

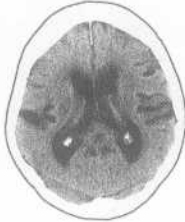No effective treatment exists. Transmitter augmentation therapy seems unlikely to be effective in view of the many neurotransmitters involved.

DEMENTIAS – SPECIFIC DISEASES

MULTI-INFARCT (arteriosclerotic dementia)

This is an overdiagnosed condition which accounts for less than 10% of cases of dementia. Dementia occurs 'stroke by stroke', with progressive focal loss of function. Clinical features of stroke profile – hypertension, diabetes, etc. – are present.

Diagnosis is obtained from the history and confirmed by CT scan.



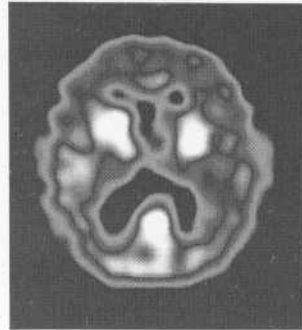Low density areas of infarction

These areas are not space-occupying and do not enhance after intravenous contrast

Treatment: Maintain adequate blood pressure control.
Anti-platelet aggregants (aspirin).

PICK'S DISEASE

This progressive condition accounts for 5% of all dementias. Usually sporadic, it more commonly affects women between 40 and 60 years. Frontal lobe dysfunction predominates with apathy, lack of initiative and personality changes. CT scan shows frontal atrophy. Blood flow studies (SPECT (HMPAO)) reveal anterior hypoperfusion. The disorder is characterised pathologically by *argyrophilic inclusion bodies* within the cytoplasm of cells of the frontotemporal cortex. There is no treatment, death occurring within 2–3 years of the onset.



PRIMARY PROGRESSIVE DYSPHASIA

Dominant hemisphere perisylvian atrophy is associated with progressive disturbance of language which, after many years, develops into a generalised dementia. Pathologically non specific cell loss or spongiform changes distinguish this rare condition from Alzheimer's disease. CT scanning confirms focal atrophy.

AIDS DEMENTIA COMPLEX (see pages 495–496)

Approximately two-thirds of persons with AIDS develop dementia, mostly due to AIDS dementia complex. In some patients HIV is found in the CNS at postmortem. In others an immune mechanism or an unidentified pathogen is blamed.

Dementia is initially of a 'subcortical' type.

CT shows atrophy; MRI shows increased T2 signal from white matter. Imaging excludes other infections and neoplastic causes of intellectual decline.

Treatment with Zidovudine (AZT) halts and partially reverses neuropsychological deficit.

METABOLIC DEMENTIA

General medical examination is important in suggesting underlying systemic disease. B₁₂ deficiency may produce dementia rather than subacute combined degeneration of the spinal cord.

In alcoholics, consider not only Wernicke Korsakoff syndrome but also *chronic subdural haematoma*.

DEMENTIAS – SPECIFIC DISEASES

NORMAL PRESSURE HYDROCEPHALUS

Normal pressure hydrocephalus (NPH) is the term applied to the triad of:

<p><i>Dementia</i> <i>Gait disturbance</i> <i>Urinary incontinence</i></p>	}	<p>occurring in conjunction with <i>hydrocephalus</i> and <i>normal</i> CSF pressure.</p>
------------------------------------------------------------------------------------	---	---------------------------------------------------------------------------------------------------

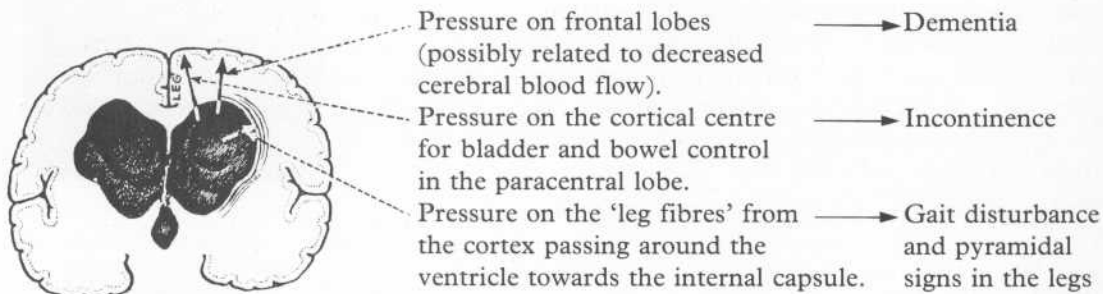
Two types occur:

- NPH with a *preceding cause*
 - subarachnoid haemorrhage
 - meningitis
 - trauma
 - radiation-induced

(This must be distinguished from hydrocephalus with raised intracranial pressure associated with these causes.)

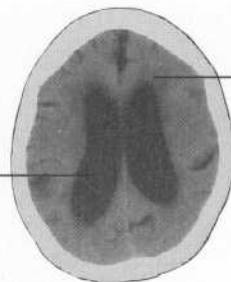
- NPH with no known preceding cause – *idiopathic* (50%).

Aetiology is unclear. It is presumed that at some preceding period, impedence to normal CSF flow causes raised intraventricular pressure and ventricular dilatation. Compensatory mechanisms permit a reduction in CSF pressure yet the ventricular dilatation persists and causes symptoms:



Diagnosis is based on clinical picture plus CT scan/MRI evidence of ventricular enlargement.

The lateral ventricles are often dilated more than the 3rd and 4th



Note the presence or absence of periventricular lucency (PVL) and width of cortical sulci

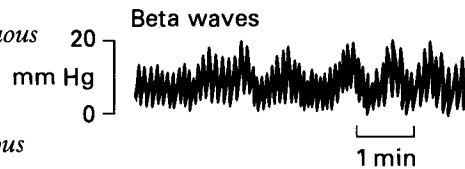
Normal pressure hydrocephalus must be differentiated from patients whose ventricular enlargement is merely the result of shrinkage of the surrounding brain, e.g. Alzheimer's disease. These patients do not respond to CSF shunting, whereas a proportion of patients with NPH (but not all) show a definitive improvement with shunting.

DEMENTIAS – SPECIFIC DISEASES

Investigations

Numerous tests have been assessed to predict those most likely to benefit from operation. The most reliable are –

- (i) The presence of *beta waves* on *continuous intracranial pressure monitoring* for more than 5% of a 24 hour period.
- (ii) Clinical improvement with *continuous lumbar CSF drainage* of 200 ml per day for three to five days.



Other tests include the presence of periventricular lucency or disproportionate sulcal width on CT scan, isotope cisternography and CSF infusion studies but none appear to produce a reliable guide.

Operation: Ventriculo-peritoneal shunting (see page 363).

Results: Improvement occurs in 50–70% of those patients with a known preceding cause e.g. subarachnoid haemorrhage. Only 30% of the idiopathic group respond to shunting.

TRAUMA

Reduction of intellectual function is common after severe head injury. Chronic subdural haematoma can also present as progressive dementia, especially in the elderly.

Punch-drunk encephalopathy (dementia pugilistica) is the cumulative result of repeated cerebral trauma. It occurs in both amateur and professional boxers and is manifest by dysarthria, ataxia and extrapyramidal signs associated with 'subcortical' dementia. There is no treatment for this progressive syndrome.

TUMOUR presenting as dementia

Concern is always expressed at the possibility of dementia being due to intracranial tumour. This is rare, but may happen when tumours occur in certain sites.

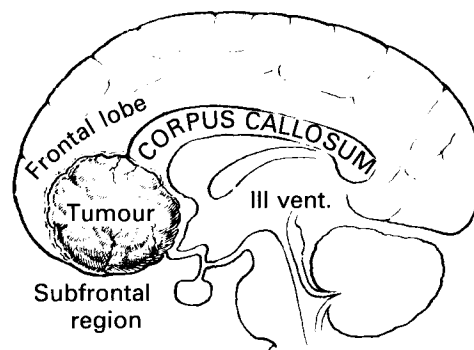
Mental or behavioural changes occur in 50–70% of all brain tumours as distinct from dementia which is associated with **frontal lobe tumours** (and subfrontal tumours), **III ventricle tumours** and **corpus callosum tumours**.

Suspect in recent onset dementia with focal signs, e.g. subfrontal lesions may be associated with loss of smell (I cranial nerve involvement) and optic atrophy (II cranial nerve involvement).

Cognitive impairment also occurs as a non metastatic complication of systemic malignancy.

N.B. Dementia can occur as a symptom of a more widespread degenerative disorder

- | | |
|--------------------------------|--------------------------------|
| e.g. Parkinson's disease | Huntington's disease |
| Diffuse Lewy body disease | Motor neurone disease |
| Progressive supranuclear palsy | These will be considered later |



DEMENTIA – DIAGNOSTIC APPROACH

It is neither practical nor essential to perform all the screening tests in every patient with dementia. The presenting features should guide investigations.

DEMENTIA	Suspected cause	Appropriate investigations
without neurological signs or systemic illness	<ul style="list-style-type: none"> - <i>Alzheimer's disease</i> → - <i>Pick's disease</i> 	CT/MR scan Confirmation: pathology (post mortem)
with neurological signs	<ul style="list-style-type: none"> - <i>Tumour</i> → - <i>Degenerative disease,</i> e.g. Huntington's chorea → 	CT/MR scan Confirmation: pathology (biopsy)
(gait disturbance and incontinence)	<ul style="list-style-type: none"> - <i>Normal pressure hydrocephalus</i> → - <i>Frontal lobe tumour</i> 	CT/MR scan Confirmation: CSF pressure monitoring (tumour-biopsy)
with neurological signs and systemic symptoms and signs	<ul style="list-style-type: none"> - <i>Inflammatory disease,</i> e.g. Demyelinating disease (page 499) Vasculitis & collagen vascular disease → - <i>Infective disease,</i> e.g. AIDS Syphilis Meningitis → 	Serum autoantibodies Evoked responses CSF (immunology) CT/MR scan Serum antibodies (viral) VDRL, TPHA HIV status CSF examination CT/MR scan
with 'stroke risk factors' (page 236)	<ul style="list-style-type: none"> - <i>Multi-infarct state</i> → 	CT/MR scan
with poor nutrition	<ul style="list-style-type: none"> - <i>Nutritional disease</i> → 	Serum B ₁ (thiamine) Red cell transketolase (thiamine) Serum B ₁₂ Serum folate
with metabolic and endocrine symptoms and signs	<ul style="list-style-type: none"> - <i>Metabolic and endocrine disease</i> → 	Function tests: - thyroid - parathyroid - renal - hepatic - adrenal
with history of head trauma	<ul style="list-style-type: none"> - <i>Post-traumatic dementia</i> → 	CT/MR scan

Neuropsychometric testing is performed:

- to diagnose early dementia
- to separate true dementia from pseudodementia
- to monitor progress or trials of treatment.

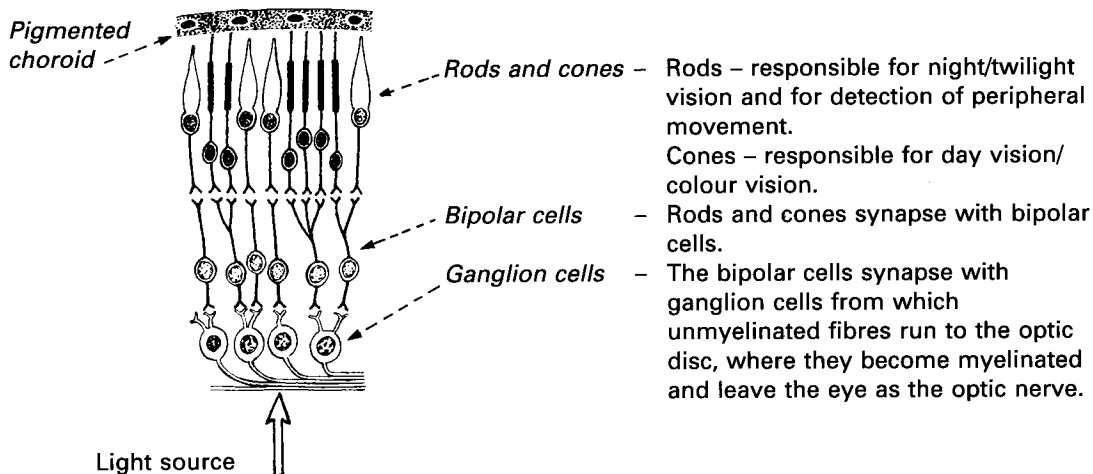
When the reason for dementia is unclear, comprehensive investigation is essential to ensure that treatable nutritional, infective, metabolic and structural causes are not overlooked.

IMPAIRMENT OF VISION

ANATOMY AND PHYSIOLOGY

Anatomically the visual system is contained in the supratentorial compartment. It is composed of peripheral receptors in the retina, central pathways and cortical centres. The control of ocular movement and pupillary responses are closely integrated.

The retina: three distinct layers of the retina are identified:

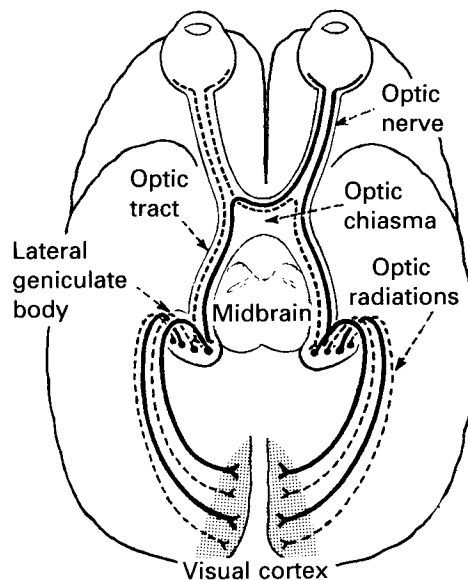


The *macular region* of the retina is its most important area for visual acuity. Here, cones lie in the greatest concentration whereas rods are more numerous in the surrounding retina.

The optic nerve leaves the orbit through the *optic foramen* and passes posteriorly to unite with the opposite optic nerve at the *optic chiasma*. Here, partial decussation occurs (axons from ganglion cells on the nasal side of the retina cross over to the opposite side).

The *optic tract* consisting of ipsilateral temporal and contralateral nasal fibres passes to the *lateral geniculate body*. A few fibres leave the tract before the lateral geniculate body and pass to the *superior colliculus* (fibres concerned with pupillary light reflex).

Axons of cell bodies in the lateral geniculate body make up the *optic radiation*. This enters the hemisphere in the most posterior part of the internal capsule, courses deep in parietal and temporal lobes and terminates in the *calcarine cortex* of the occipital lobe.



IMPAIRMENT OF VISION

CLINICAL APPROACH AND DIFFERENTIAL DIAGNOSIS

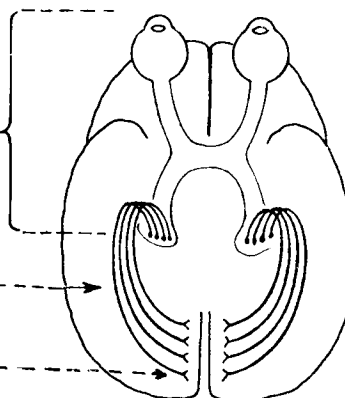
Patients presenting with visual impairment require a systematic examination, not only of *vision*, but also of the *pupillary response*, *eye movements*, and, unless the cause clearly lies within the globe, a *full neurological examination*.

The findings aid localisation of the lesion, e.g.

Impairment of vision + impaired pupil response indicates a lesion anterior to the lateral geniculate body

A homonymous hemianopia + sensory and cognitive deficit indicates a parieto-temporal lesion

An isolated homonymous hemianopia usually indicates an occipital lesion



Refractive errors are excluded by testing visual acuity through a pinhole or by correcting a lens deformity (page 9).

Four types of refractive error exist:

PRESBYOPIA – failure of accommodation with age

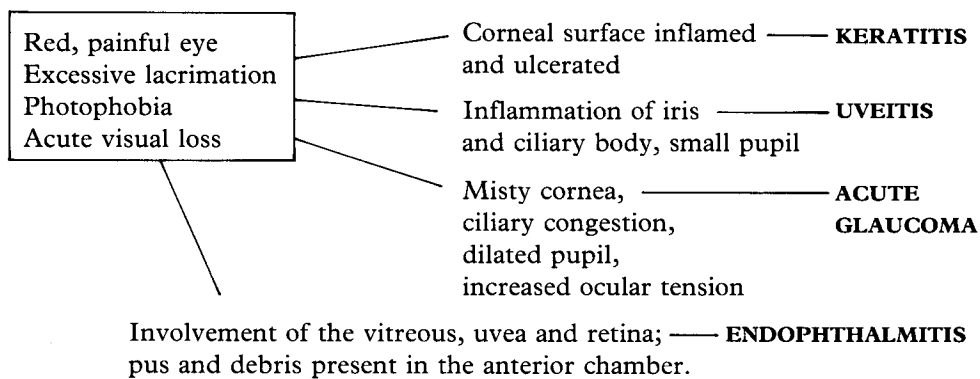
HYPERMETROPIA (long sightedness) – short eyeball

MYOPIA (short sightedness) – long eyeball

ASTIGMATISM – variation in corneal curvature

If this examination is normal, then the lesion lies in the retina, visual pathways or visual cortex.

Examine the globe and anterior chamber



Examine the lens with an ophthalmoscope

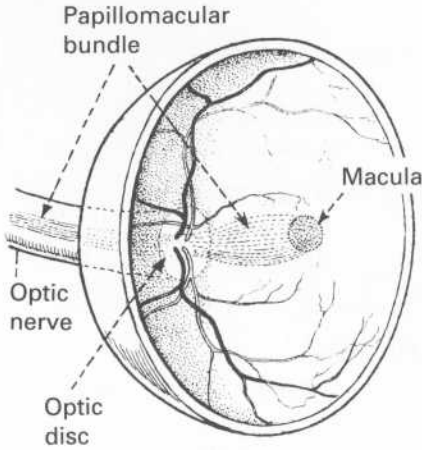
130 Opacification indicates CATARACT.

IMPAIRMENT OF VISION

CLINICAL APPROACH AND DIFFERENTIAL DIAGNOSIS (contd)

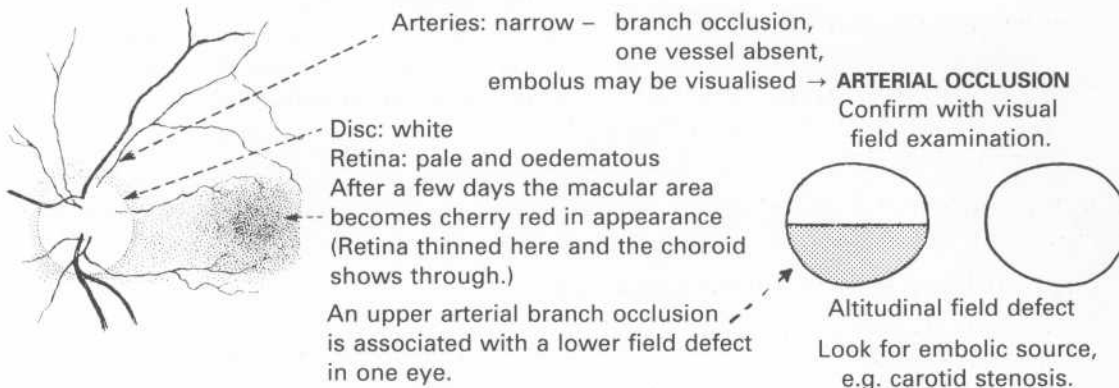
Examine the posterior segment of the eye with an ophthalmoscope.

Pupil dilatation may be required.

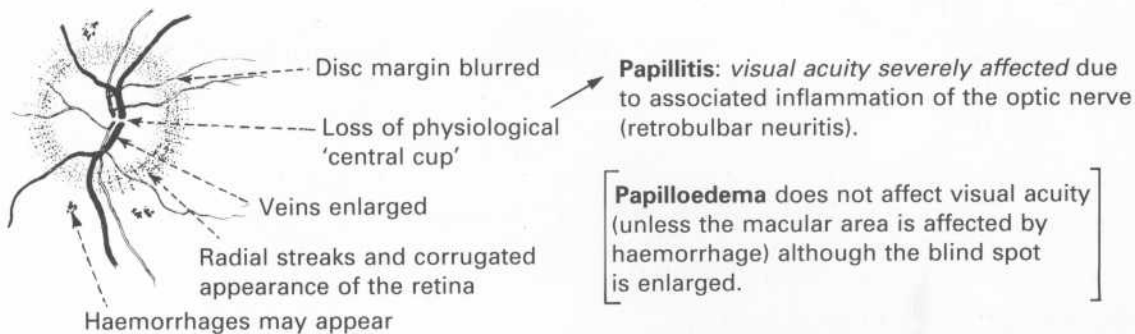


In the normal fundus, the *disc* is pale with a central cup and reddish-brown surrounding retina. Arteries and veins emerge from the optic disc. The *macula* is darker than the rest of the fundus and lies on the temporal side of the disc. One-third of all retinal fibres arise from the small macular region and pass to the optic nerve head (disc) as the *papillomacular bundle*. The macula is the region of sharpest vision (cone vision), whereas peripheral vision (rod vision) serves the purpose of perception of movement and directing central/macular vision. The optic nerve head contains no rods or cones and accounts for the physiological *blind spot* in normal vision. The macular fibres being so functionally active, are the most susceptible to damage and produce a specific defect in the visual field – a **scotoma**.

Retinal abnormality with acute impairment of vision



Loss of retinal colour (becomes milky white) and macular blush. → **CENTRAL RETINAL ARTERY OCCLUSION**



IMPAIRMENT OF VISION

CLINICAL APPROACH AND DIFFERENTIAL DIAGNOSIS (contd)

N.B. Distinguish:


HYPERMETROPIC patients who have a pale indistinct disc often difficult to differentiate from early papilloedema.

HYPERTENSIVE RETINOPATHY – superficial haemorrhages and ‘cotton wool’ exudates.

PSUEUDOPAPILLOEDEMA – ‘**DRUSEN**’ – hyaline bodies near the optic disc which raise the disc and blur the margin. This normal variant may be inherited.

Separation of the superficial retina from the pigment layer → **RETINAL DETACHMENT**
(traumatic or spontaneous)

Retinal abnormalities with gradual impairment of vision



Disc white like a 'tennis ball' with 'punched out' margins: blood supply is less prominent and the number of arteries reduced

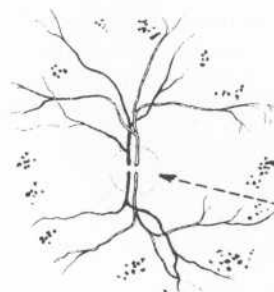
→ OPTIC ATROPHY

Primary (optic nerve disease): *compression, toxins, ischaemia, optic neuritis*

Secondary (following papilloedema):

↓
visual field charting (see later) may help differentiate cause

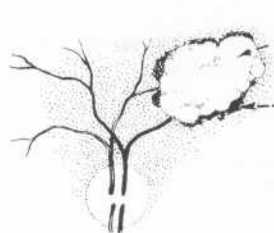
N.B. Any disease of the optic nerve or anterior visual pathway causing loss of vision will eventually result in optic atrophy.



Pigmentary deposits in the periphery of the retina

Progressive pallor of the optic disc

→ RETINITIS PIGMENTOSA

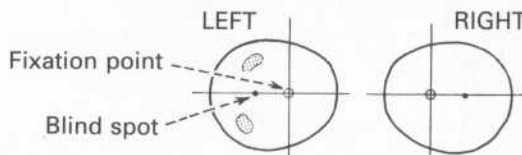


Areas of white sclera exposed along with areas of proliferation of retinal pigmentary epithelium – follows atrophy of the choroid

→ CHOROIDITIS

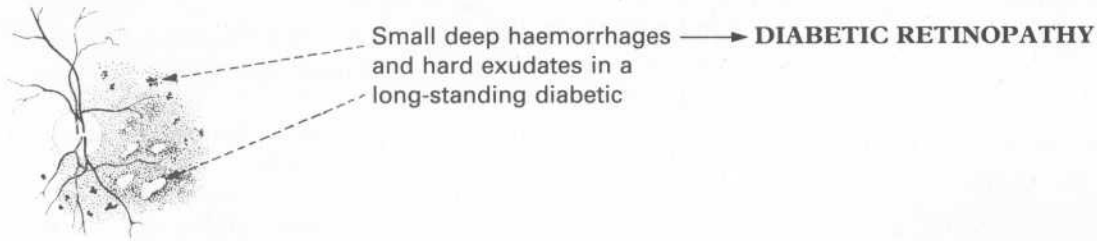
Occurs in *toxoplasmosis* and in *cytomegalovirus* infection

Field examination reveals a patchy loss.



IMPAIRMENT OF VISION

CLINICAL APPROACH AND DIFFERENTIAL DIAGNOSIS (contd)



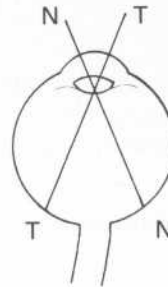Dark oval mass – possibly related to secondary retinal detachment — in middle aged patient → **MALIGNANT MELANOMA**

White mass behind the pupil — in infancy → **RETINOBLASTOMA**

Examine the visual fields

If ophthalmoscopic examination is normal, or if optic atrophy is evident, then visual field examination is essential. Visual confrontation is useful for detecting large defects, but smaller defects require visual field charting with a Goldmann perimeter (page 10).

In interpreting the results of examination it is important to remember that the ocular system *reverses* the image. The nasal side of the fundus picks up the temporal image and vice versa. Damage, therefore, to the nasal side of the retina will produce a temporal visual field defect.

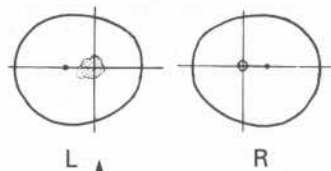


IMPAIRMENT OF VISION

CLINICAL APPROACH AND DIFFERENTIAL DIAGNOSIS (contd)

Central scotoma

Characteristic of most optic nerve lesions.



RETROBULBAR NEURITIS – associated papillitis may be evident on fundoscopy; may be first sign of *multiple sclerosis*.

OPTIC NERVE COMPRESSION

X-ray optic foramen
CT/MRI scan
(orbital/intracranial)

Orbital lesion (usually with proptosis)

- tumour
- granuloma

Lesion within optic canal

- tumour, e.g. meningioma
- granuloma
- hyperostosis, e.g. Paget's disease, fibrous dysplasia

Intracranial lesions

- tumour, e.g. meningioma (chordoma, dermoid)
- granuloma, e.g. tuberculoma, sarcoid (rare)
- aneurysm, e.g. ophthalmic → angiography confirms

Pupil response may be impaired (Marcus-Gunn pupil, see page 142)

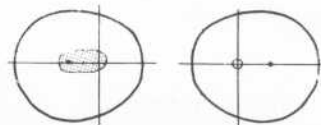
OPTIC NERVE GLIOMA →

LEBER'S OPTIC ATROPHY –

CT/MRI → exploration

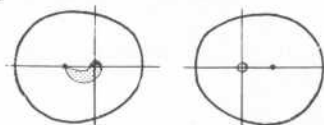
large bilateral scotoma

Centro-caecal scotoma



The scotoma extends to involve the blind spot. Characteristic of *toxic amblyopia* – alcohol, tobacco.

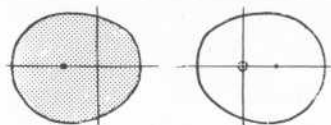
Arcuate scotoma



The scotoma extends from the blind spot following the course of nerve fibres.

Characteristic of *glaucoma*; seen also in small lesions close to the optic disc such as *choroiditis*.

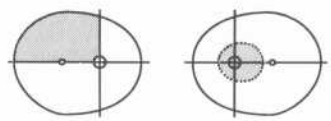
Mononuclear blindness



The end result of an inflammatory, vascular or compressive optic nerve lesion.

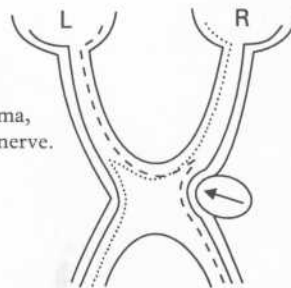
Direct pupillary response absent; consensual present.

Junctional scotoma



– indicates the presence of an *optic nerve lesion immediately anterior to the chiasma*.

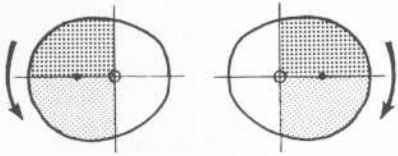
Nasal fibres not only decussate in the chiasma, but also loop forward into the opposite optic nerve. This lesion emphasises the importance of examining the 'normal' eye in monocular impairment of vision.



IMPAIRMENT OF VISION

CLINICAL APPROACH AND DIFFERENTIAL DIAGNOSIS (contd)

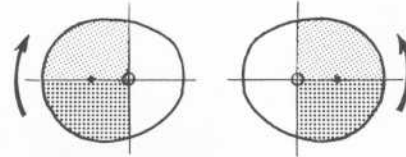
Bitemporal hemianopia/quadrantanopia



Involvement of the upper quadrants first indicates compression of the optic chiasma from below and suggests:

- PITUITARY ADENOMA
- NASOPHARYNGEAL CARCINOMA
- SPHENOID SINUS MUCOCELE

Skull X-ray/
CT scan/MRI

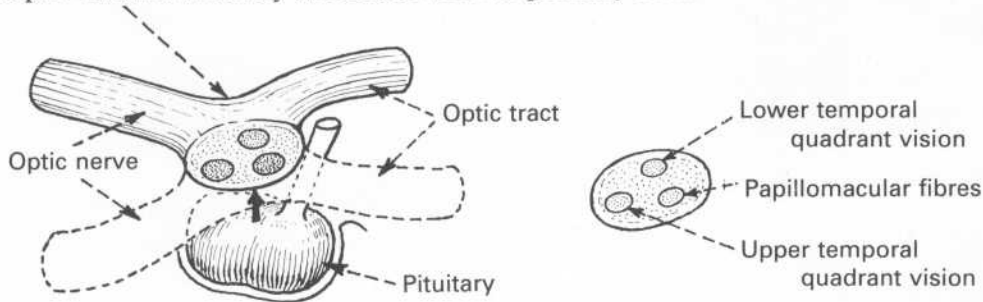


Involvement of the lower quadrants first indicates compression of the optic chiasma from above and suggests:

- CRANIOPHARYNGIOMA
- THIRD VENTRICULAR TUMOUR

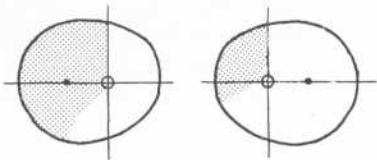
CT scan/MRI

The optic chiasma is closely associated with the pituitary fossa.



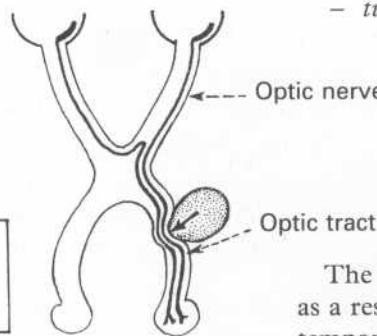
Homonymous hemianopia

An *incongruous homonymous hemianopia* (i.e. one eye more affected than the other) suggests a compressive lesion of the **optic tract** near the chiasma.



- vascular cause (sudden onset)
- tumour (gradual onset)

CT scan/MRI



N.B. Pupil response may be impaired when light is shone from affected field

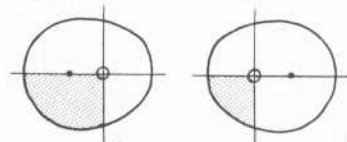
The 'incongruous' defect occurs as a result of rotation of nasal and temporal fibres.

IMPAIRMENT OF VISION

CLINICAL APPROACH AND DIFFERENTIAL DIAGNOSIS (contd)

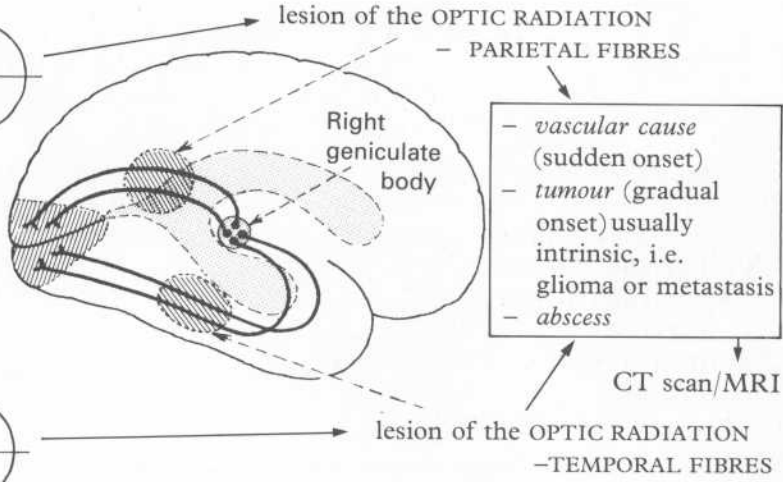
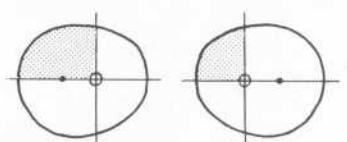
Congruous homonymous hemianopia (fields can be exactly superimposed)

Inferior quadrantanopia



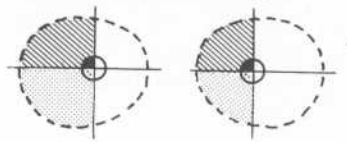
N.B. Pupil response intact.
Macula spared

Superior quadrantanopia

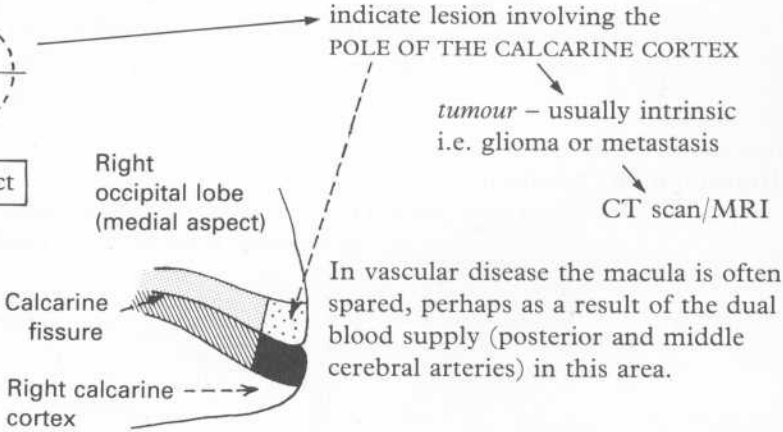


At the temporo-parietal junction where fibres meet, lesions produce a complete 'homonymous hemianopia'.

Homonymous hemianopia with macular involvement




N.B. Pupil response intact



Complete visual loss

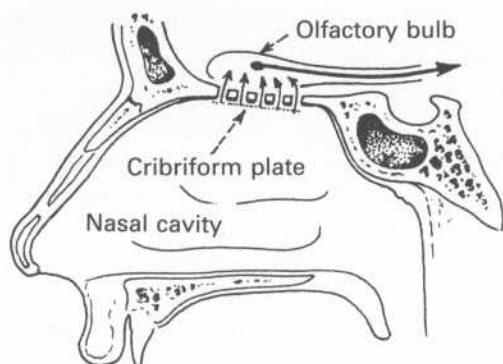
Pupil response spared



The interpretation of the visual image and its integration with other cortical functions is discussed under 'Higher cortical function'.

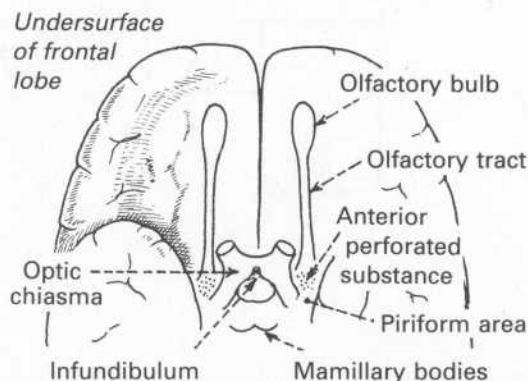
DISORDERS OF SMELL

OLFACTORY (I) cranial nerve conveys the sensation of smell.



The axons partially decussate as they pass back in the olfactory tract to the *piriform area* of the temporal lobe and the *amygdaloid nucleus*.

A number of fine nerves arising from receptor cells in the nasal mucosa pierce the *cribriform plate* of the ethmoid bone. These pass to the *olfactory bulb* where they synapse with neurons of the olfactory tract.



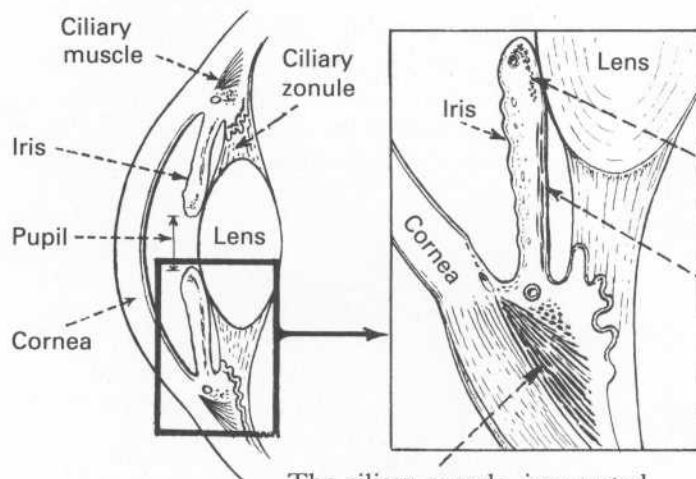
Differential diagnosis

IMPAIRMENT or LOSS OF SMELL (anosmia) - unilateral or bilateral	TEMPORARY-	<i>Upper respiratory tract infection:</i> inflammation of the nasal mucosa is the commonest cause of impairment or loss of smell.
	TEMPORARY/ PERMANENT	<ul style="list-style-type: none"> - <i>Head injury:</i> anosmia may occur with or without evidence of cribriform plate fracture. Recovery is usual. - <i>Viral infections:</i> any viral illness may cause anosmia which can be permanent - <i>Drugs:</i> penicillamine - <i>Endocrine disease:</i> Addison's disease and thyrotoxicosis - <i>Tumours:</i> Olfactory groove meningioma <ul style="list-style-type: none"> Frontal bone osteoma Pituitary tumours Frontal lobe glioma Frontal lobe abscess - <i>Aneurysm of the circle of Willis:</i> Anterior communicating, Ophthalmic - <i>Raised intracranial pressure:</i> without local damage to olfactory structures, may rarely cause anosmia
FOSTER-KENNEDY SYNDROME:	<ul style="list-style-type: none"> - Ipsilateral anosmia - Ipsilateral optic atrophy - Contralateral papilloedema 	— occurs with olfactory groove or sphenoid ridge masses

OLFACTORY HALLUCINATIONS — occur in complex partial seizures and migraine

PUPILLARY DISORDERS

ANATOMY/PHYSIOLOGY



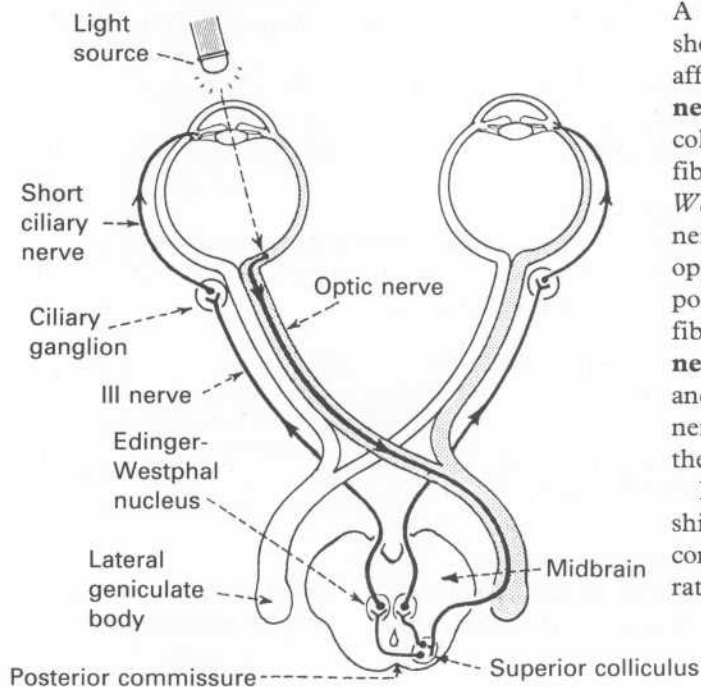
The iris controls the size of the pupil. It contains two groups of smooth muscle fibre:

1. *Sphincter pupillae*; a circular constrictor, innervated by the *parasympathetic* nervous system.
2. *Dilator pupillae*; a radial dilator, innervated by the *sympathetic* nervous system.

Pupillary size (normal 2–6 mm) depends on the balance between sympathetic and parasympathetic tone.

The ciliary muscle, innervated by the parasympathetic, controls the degree of convexity of the lens through the ciliary zonule.

Pathway of pupillary constriction and the light reflex (parasympathetic)

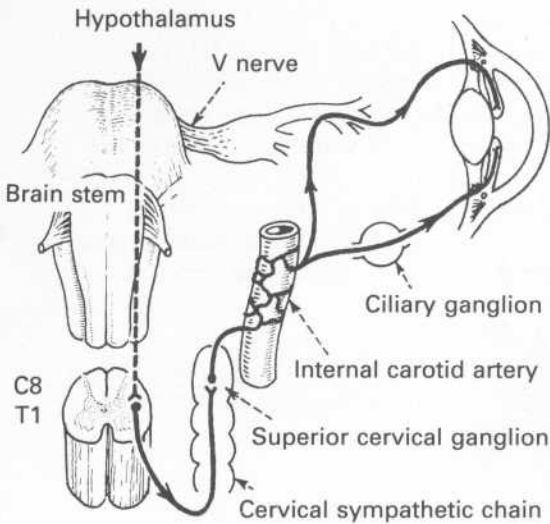


A stimulus, such as a bright light shone in the left eye, will send an afferent impulse along the **optic nerve** to the midbrain (superior colliculus); here a second order fibre passes to the *Edinger Westphal nucleus* (part of the III nerve nucleus) on the same and opposite side (through the posterior commissure). Efferent fibres leave in the **oculomotor nerve**, pass to the ciliary ganglion and thence, in the short ciliary nerve, to the constrictor fibres of the sphincter pupillae muscle.

If all pathways are intact, shining a light in one eye will constrict *both pupils* at an equal rate and to a similar degree.

PUPILLARY DISORDERS

Pathway of pupillary dilatation (sympathetic)



Sympathetic fibres descend from the ipsilateral hypothalamus through the lateral aspect of the brain stem into the spinal cord. The pupillary fibres pass out in the anterior roots of C8 and T1, enter the sympathetic chain and, in the superior cervical ganglion, give rise to postganglionic fibres which ascend on the wall of the internal carotid artery to enter the cranium. The fibres eventually leave the intracranial portion of the internal carotid artery and pass directly through the ciliary ganglion to the iris or join the cranial nerves III, IV, V and VI, running to the eye and iris. Sudomotor fibres (concerned with sweating) run up the external carotid artery to the dermis of the face.

Interruption of sympathetic supply affects:

1. Pupillary dilatation *causes* a small pupil (miosis)
2. Levator palpebrae muscle (30% supplied by sympathetic) *causes* drooping of eyelid (ptosis)
3. Vasoconstrictor fibres to orbit, eyelid and face *causes* absence of sweating.

Interruption of parasympathetic supply affects:

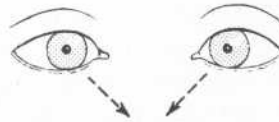
Pupil constriction causing a large pupil (mydriasis)

Mechanism of accommodation

When gaze is focused on a near object the medial rectus muscles contract, producing convergence, the ciliary muscles contract enabling the lens to produce a more convex shape and the pupil constricts (accommodation for near vision).

The pathway is poorly understood but must involve the visual cortex, Edinger-Westphal nuclei and both medial rectus components of the III nerve nucleus in the midbrain.

Inability of the pupil to constrict during accommodation need not always be associated with impairment of convergence, though usually this is the case.



Pupillary Inequality (Anisocoria)

A difference in pupil size occurs in 20% of the normal population and is distinguished from pathological states by a normal response to bright light.

PUPILLARY DISORDERS

PUPIL DILATATION - CAUSES

III nerve lesion



Examination of the light reflex (page 11) distinguishes lesions of the optic (II) and oculomotor (III) nerves. Failure of the pupil to constrict when light is shone into either the affected or the contralateral eye indicates a lesion of the parasympathetic component of the III nerve.

Look for - **ptosis** - 70% of levator palpebrae muscle is supplied by the oculomotor nerve
 - **impaired eye movements.**

Causes of a III nerve lesion are described on page 149.

In comatose patients, pupil dilatation and failure to react to light is the simplest way of detecting a III nerve lesion; after head injury or in patients with raised intracranial pressure this is an important sign of transtentorial herniation.

The tonic pupil - Adie's pupil

This is a benign condition usually affecting young women. Onset is usually acute and unilateral in 80%.

The pupil dilates and the patient complains of mistiness in the affected eye.



Pupil constriction to both direct and consensual light is often absent but very slow pupillary constriction occurs with accommodation.



When accommodation is relaxed, slow dilatation occurs.

Occasionally the pupil appears completely unreactive to both light and accommodation. When the pupil is associated with reduced or absent limb reflexes this is termed the *Holmes-Adie* syndrome. More widespread autonomic dysfunction-arthostatic hypotension segmental disturbance of sweating and diarrhoea can co-exist.

Diagnosis: confirmed by pupillary response to pilocarpine (0.1% or 0.05%) - the tonic pupil will constrict (denervation hypersensitivity); the normal eye is not affected.

The cause is unknown; the lesion probably lies in the midbrain or ciliary ganglion.

Migraine: Mydriasis persisting for some hours can accompany headache.

Drugs: Mydriasis occurs with anticholinergic drugs (atropine), tricyclic antidepressants, non-steroidal anti-inflammatories, antihistamines and oral contraceptives. It can precipitate an attack of acute angle-closure glaucoma.

PUPILLARY DISORDERS

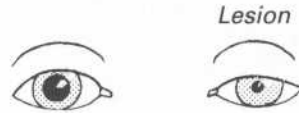PUPIL CONSTRICTION – CAUSES

Horner's syndrome

MIOSIS: the affected pupil is smaller than the opposite pupil. It does not dilate when the eye is shaded.

PTOSIS: the affected eyelid droops and may be slightly raised voluntarily. Ptosis is less marked than with a III nerve palsy.

DISTURBANCE OF SWEATING: depends on the site of the lesion. Absence of sweating occurs when the lesion is proximal to fibre separation along the internal and external carotid arteries.



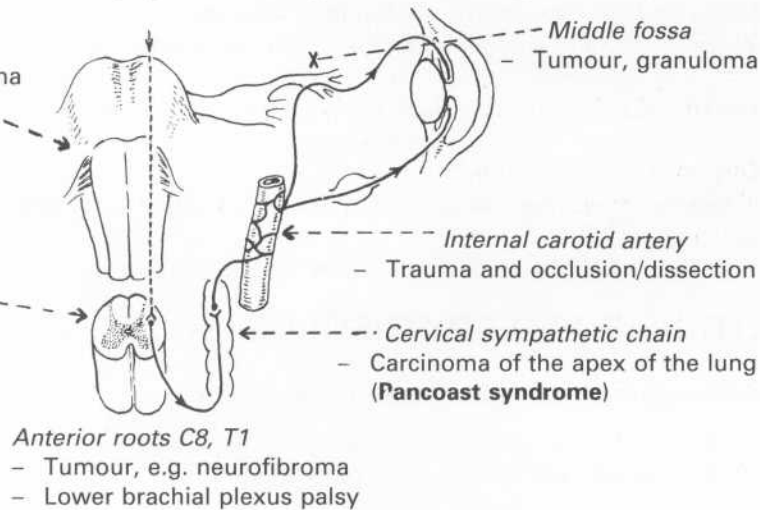
Horner's syndrome may result from sympathetic damage at the following sites:

Brain stem

- Intrinsic tumour, e.g. glioma
- Vascular lesion
- Syringobulbia

Cervical cord

- Intrinsic tumour e.g. glioma
- Syringomyelia



The congenital or familial form exists, often associated with lack of pigmentation of the iris. The lesion site is unknown.

Distinguish peripheral and central lesions by instilling drugs, e.g. 1% cocaine in eyes.

Preganglionic lesions

Right sided Horner's



Cocaine acts at the adrenergic nerve endings and, by preventing adrenaline uptake, causes pupil dilatation when the lesion is preganglionic.

Postganglionic lesions

Right sided Horner's



When the lesion is postganglionic, cocaine has little effect because there are no nerve endings on which the drug may act.

Investigative approach: depends on associated signs. Chest X-ray is mandatory to exclude an apical lung tumour.

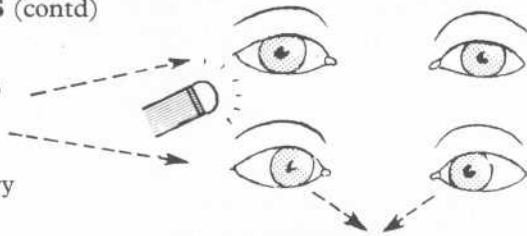
PUPILLARY DISORDERS

PUPIL CONSTRICTION – CAUSES (contd)

The Argyll-Robertson pupil

Small pupils irregular in shape, which do not react to light but react to accommodation.

They respond inadequately to pupillary dilator drugs.



Argyll-Robertson pupils are usually synonymous with *syphilitic infection*, but they may also result from *any midbrain lesion – neoplastic, vascular, inflammatory or demyelinative*.

The Argyll-Robertson pupil has also been described in *diabetes* and in *alcoholic neuropathy* as well as following infectious mononucleosis. The lesion could lie in the midbrain, involving fibres passing to the Edinger-Westphal nucleus, in the posterior commissure, or alternatively, in the ciliary ganglion. A central lesion seems most likely.

Investigative approach:

- look for associated signs of neurosyphilis
- blood serology – VDRL, Captia G.

Drugs

Parasympathomimetic drugs – Carbachol, phenothiazines and opiates produce miosis.

N.B Do not confuse with small pupils, normally occurring in the elderly.

OTHER PUPILLARY DISORDERS

Failure of accommodation and convergence

Impaired accommodation and convergence are of limited diagnostic value since other clinical features are usually more prominent.

Causes

- extrapyramidal disease, e.g. Parkinson's
- tumours of the pineal region.

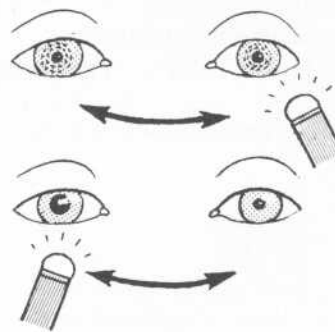
The Marcus Gunn pupil (pupillary escape)

Illumination of one eye normally produces pupillary constriction with a degree of waxing and waning (hippus).

When afferent transmission in the optic nerve is impaired, this 'escape' becomes more evident.

If the light source is 'swung' from eye to eye, dwelling 2–3 seconds on each, the affected pupil may eventually, paradoxically, dilate – a 'Marcus Gunn' pupil.

The swinging light test is a sensitive test of optic nerve damage but is also abnormal in retinal or macular disease.



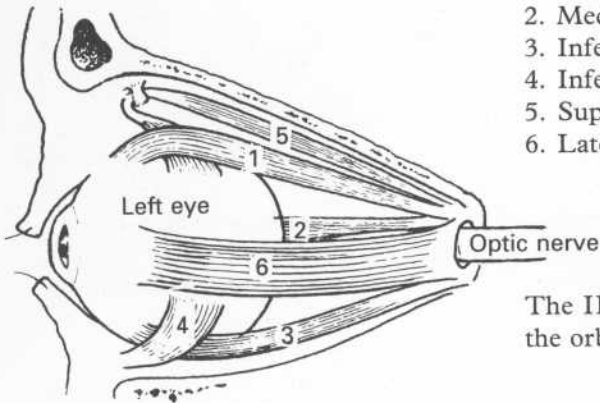
DIPLOPIA – IMPAIRED OCULAR MOVEMENT

Diplopia or double vision results from impaired ocular movement.

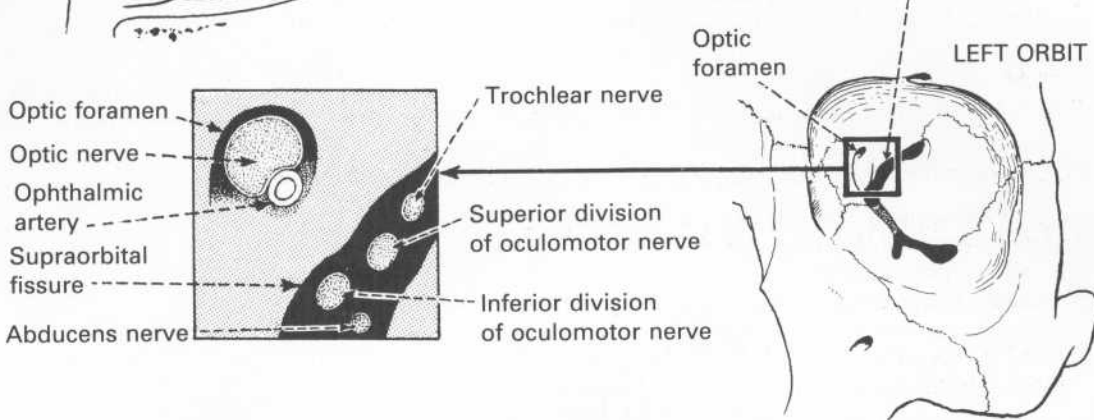
RELATED ANATOMY AND PHYSIOLOGY

Six muscles control eye movement:

- | | |
|--------------------------------------------|--------------------------|
| 1. Superior rectus | } III – oculomotor nerve |
| 2. Medial rectus | |
| 3. Inferior rectus | |
| 4. Inferior oblique | |
| 5. Superior oblique – IV – trochlear nerve | |
| 6. Lateral rectus – VI – abducens nerve | |

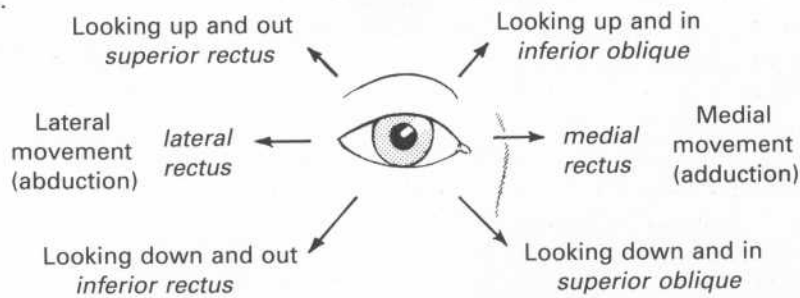


The III, IV and VI cranial nerves enter the orbit through the superior orbital fissure.



The line of action of individual ocular muscles

Eye movements result from a continuous interplay of all the ocular muscles, but each muscle has a direction of maximal efficiency. The oblique muscles move the eye up and down when it is turned in. The superior and inferior recti move the eye up and down when it is turned out.



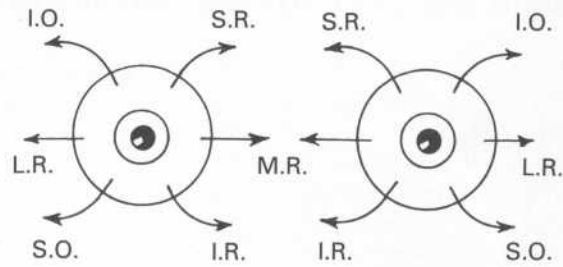
Eye movements are examined in the six different directions of gaze representing individual muscle action.

DIPLOPIA – IMPAIRED OCULAR MOVEMENT

The line of action of individual ocular muscles (*contd*)

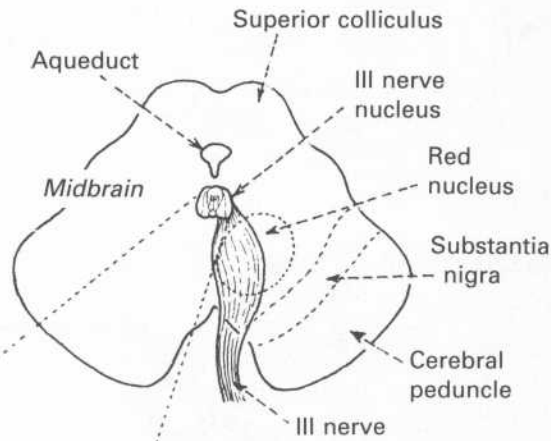
As a result of the angle of insertion into the globe, the inferior and superior recti and the oblique muscles also have a rotatory or torsion effect.

When the eye is turned out, the oblique muscles rotate the globe; when turned in, the inferior or superior recti rotate the globe.



OCULOMOTOR (III) nerve

The oculomotor nucleus lies in the *ventral periaqueductal grey matter* at the level of the *superior colliculus*. Nerve fibres pass through the *red nucleus* and *substantia nigra* and emerge medial to the *cerebral peduncle*.



The nucleus has a complex structure:

Perlia's nuclei (parasympathetic) concerned with convergence and accommodation.

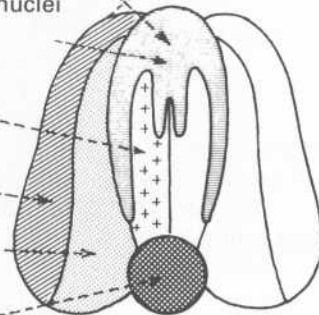
Edinger – Westphal nuclei (parasympathetic) concerned with pupil constriction

Medial rectus and inferior oblique

Inferior rectus

Superior rectus

Caudal nucleus of Perlia (levator of eyelid)

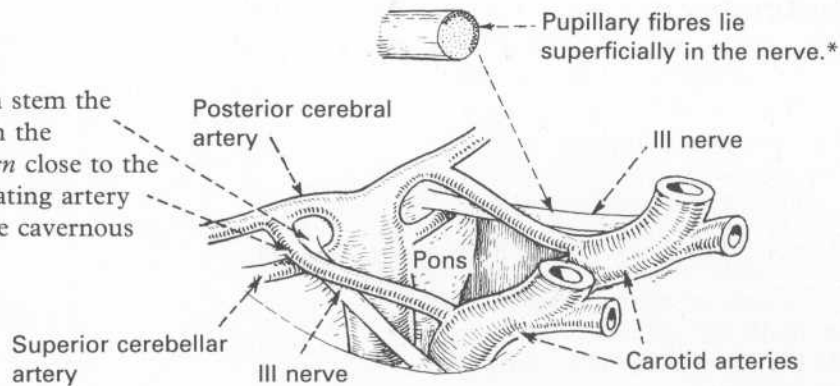


The nucleus is a paired structure which lies close to the midline, the portion representing the medial rectus abutting its neighbour.

DIPLOPIA – IMPAIRED OCULAR MOVEMENT

III nerve (contd)

On leaving the brain stem the nerve passes through the *interpeduncular cistern* close to the posterior communicating artery and runs towards the cavernous sinus.

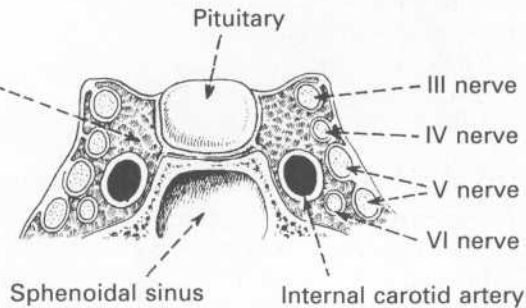


* This in part explains early pupillary involvement with III nerve compression and pupillary sparing with nerve infarction in hypertension and diabetes.

The nerve runs within the lateral wall of the *cavernous sinus* and then finally through the *superior orbital fissure* into the orbit.

Here it divides into:

1. Superior branch to the levator of the eyelid and the superior rectus.
2. Inferior branch to the inferior oblique, medial and inferior recti.

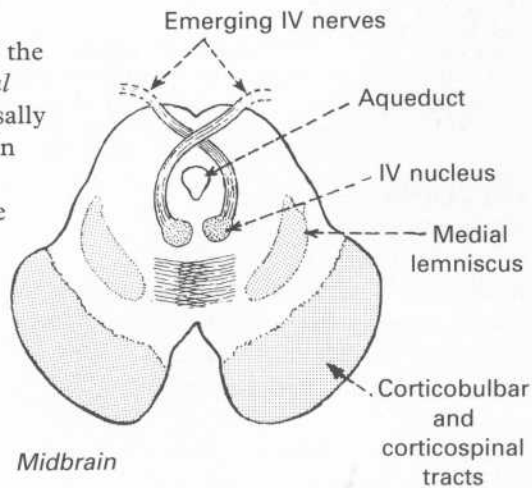


TROCHLEAR (IV) nerve

This nerve supplies the *superior oblique muscle* of the eye.

The nucleus lies in the midbrain at the level of the *inferior colliculus*, near the ventral *periaqueductal grey matter*. The nerve passes laterally and dorsally around the central grey matter and decussates in the dorsal aspect of the brain stem in close proximity to the *anterior medullary velum* of the cerebellum.

Emerging from the brain stem the nerve passes laterally around the *cerebral peduncle* and pierces the dura to lie in the lateral wall of the *cavernous sinus*. Finally, it passes through the *superior orbital fissure* into the orbit.



DIPLOPIA – IMPAIRED OCULAR MOVEMENT

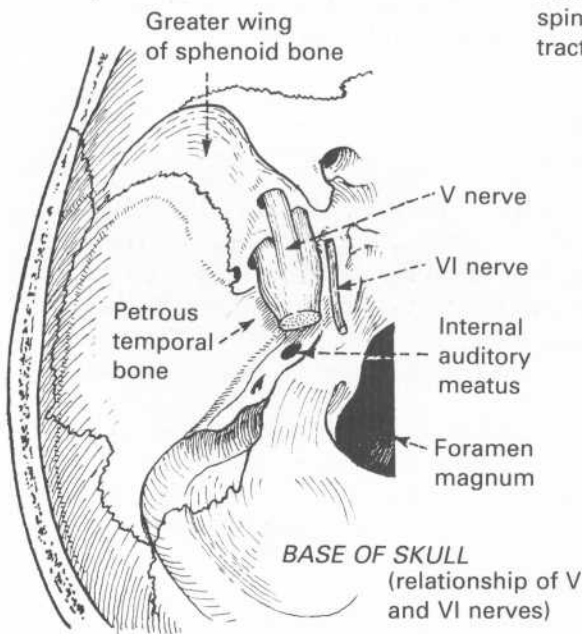
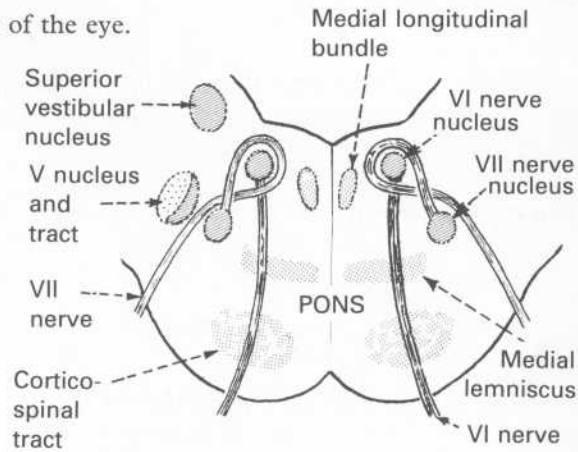
ABDUCENS (VI) nerve

This nerve supplies the *lateral rectus muscle* of the eye.

The nucleus lies in the floor of the IV ventricle within the lower portion of the *pons*. The axons pass ventrally through the *pons* without decussating.

Note the close association of the VI and VII nuclei.

Emerging from the brain stem the nerve runs up anterior to the *pons* for approximately 15 mm before piercing the *dura* overlying the *basilar portion* of the *occipital bone*.



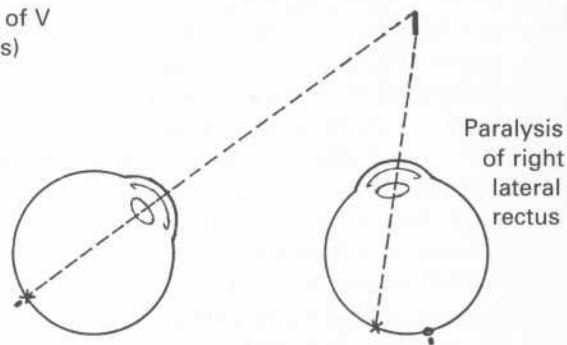
Under the *dura* the nerve runs up the *petrous portion* of the temporal bone and from its apex passes on to the lateral wall of the *cavernous sinus* and finally through the *superior orbital fissure*.

Note the long intracranial course and the proximity of the VI to the V cranial and greater superficial petrosal nerves at the apex of the petrous temporal bone.

DIPLOPIA

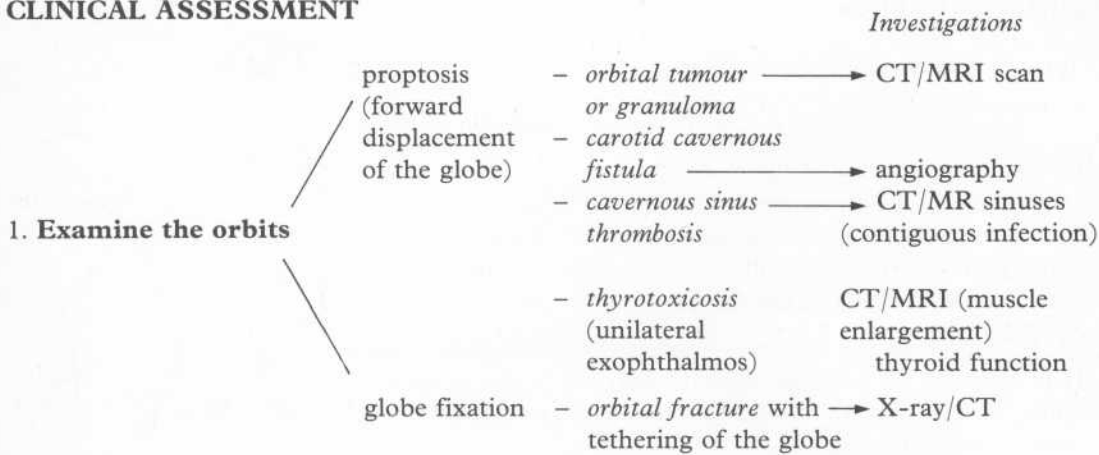
When the eyes fix on an image, impairment of movement of one eye results in projection of the image upon the macular area in the normal eye and to one side of the macula in the paretic eye; two images of the single object are thus perceived.

The image seen by the paretic eye is the *false image*; that seen by the normal eye is the *true image*. The false image is always *outermost*; this may lie in the vertical or the horizontal plane.

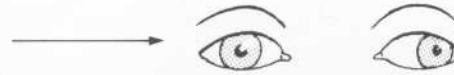

DIPLOPIA – IMPAIRED OCULAR MOVEMENT

CLINICAL ASSESSMENT



2. Examine ocular movement (page 12)
 - note the presence of a *squint* or *strabismus*
 i.e. when the axes of the eyes are not parallel.



Differentiate

Concomitant squint (heterotropia) – an ocular disorder. The eyes adopt an abnormal position in relation to each other and the deviation is constant in all directions of gaze. Such squints develop in the first few years of life before binocular vision is established, usually they are convergent (esotropia), occasionally divergent (exotropia). Suppression of vision from one eye (*amblyopia ex anopsia*) results in *absence of diplopia*. Occasionally patients subconsciously alternate vision from one eye to the other, retaining equal visual function in both – *strabismus alternans*. Correction of an underlying hypermetropia with convex lenses may offset the tendency for the eyes to converge.

Paralytic squint:

- Affected eye shows limited movement.
- Angle of eye deviation and diplopia greatest when looking in the direction controlled by the weak muscle.
- Diplopia is always present.
- The patient may assume a head tilt posture to minimise the diplopia. Paralytic squint results from disturbance of function of nerves or muscles.

III NERVE LESION

In the primary position, the affected eye deviates laterally (due to unopposed action of the lateral rectus) and **ptosis** and **pupil dilatation** are evident.



(Ptosis may be complete, unlike the partial ptosis of a Horner's syndrome which disappears on looking up.)

DIPLOPIA – IMPAIRED OCULAR MOVEMENT

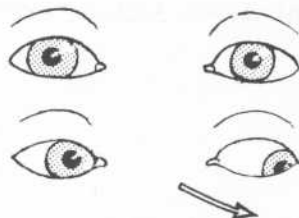
IV NERVE LESION

The eyes appear conjugate in the primary position. —————>

Testing eye movements reveals defective depression of the adducted eye. ----->

Symptomatically the patient complains of double vision when looking downwards, e.g. when descending stairs or reading, and the head may tilt to the side opposite the weak superior oblique to minimise the diplopia. ----->

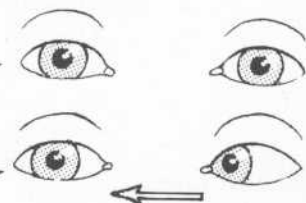
A IV nerve palsy is difficult to detect when associated with a III nerve palsy. If inward rotation (intorsion) is absent on looking downwards when the eye is abducted, then a IV nerve palsy coexists with the III nerve palsy.



VI NERVE LESION

The eyes appear conjugate in the primary position. —————>

On looking to the paralysed side (right) there is failure of abduction of the affected eye. ----->



Diplopia is horizontal (true and fake image side by side), is present only when looking to the paralysed side and is maximal at the extreme of binocular lateral vision.

NOTE: In partial oculomotor palsies, the patient may be aware of diplopia, although eye movements appear normal. When this occurs:

- check diplopia is 'true' by noting its disappearance on covering one eye.
- determine the direction of maximal image displacement and the eye responsible for the outermost image (see page 13).

This information is sufficient to differentiate a III, IV and VI nerve lesion.

OCULAR MUSCLES

If the limitation of eye movement is not restricted to one muscle, or group of muscles with a common innervation, and affects both eyes, look for:

- involvement of extraocular muscles
(levator palpebrae superioris, orbicularis oculi)
 - signs of fatigue on repeated testing
- } *myasthenia gravis*
} *ocular myopathy*

DIPLOPIA – IMPAIRED OCULAR MOVEMENT

CAUSES OF III NERVE LESION

Midbrain

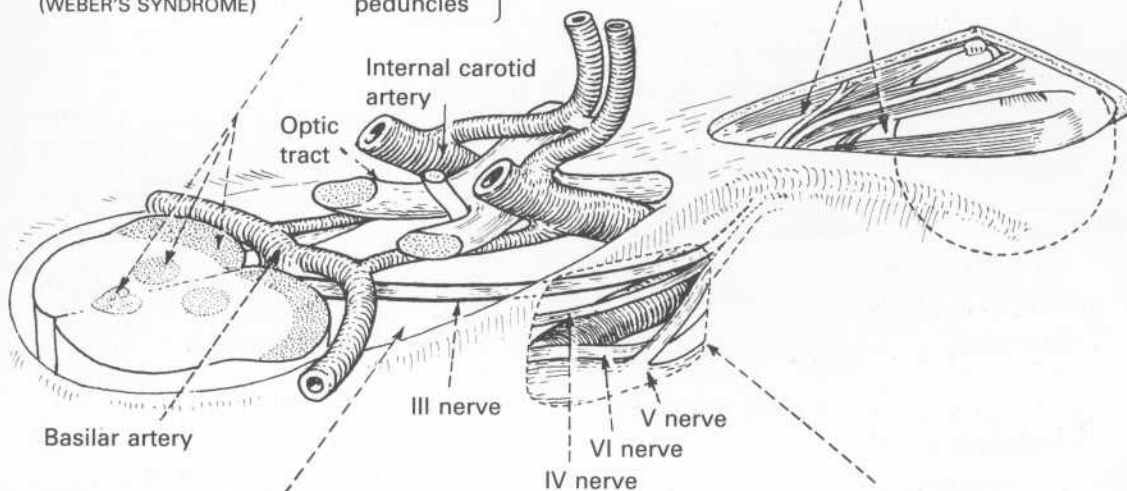
- When BILATERAL → oculomotor nucleus
- When III nerve lesion is associated with
- TREMOR or CONTRALATERAL HEMIPARESIS (WEBER'S SYNDROME) → red nucleus
- cerebral peduncles

Infarction, demyelination, intrinsic tumour, e.g glioma, basilar aneurysm compression

Orbital fissure/orbit

Look for PROPTOSIS and associated involvement of the IV, VI and FIRST DIVISION of the V NERVES

- Orbital tumour, granuloma,
- Periosteitis



Interpeduncular cistern

WHEN III NERVE LESION IS ASSOCIATED WITH:

- DETERIORATION OF CONSCIOUS LEVEL → *Transtentorial herniation*
- RETRO-ORBITAL PAIN ± SUB-ARACHNOID HAEMORRHAGE → *Aneurysm compression (posterior communicating or basilar aneurysm)*
- MENINGISM + OTHER CRANIAL NERVE PALSIES → *Basal meningitis*
- TB, syphilitic, bacterial, fungal
 - carcinomatous
- PUPIL REACTION SPARED SUDDEN ONSET → Nerve trunk infarction
- hypertension,
 - diabetes,
 - polyarteritis nodosa,
 - SLE

Cavernous sinus

Look for associated involvement of IV, VI and 1st DIVISION OF V NERVE

- Tumour e.g. pituitary adenoma, meningioma, metastasis, nasopharyngeal carcinoma
- Intracavernous aneurysm
- Cavernous sinus thrombosis

DIPLOPIA – IMPAIRED OCULAR MOVEMENT

CAUSES OF IV and VI NERVE LESIONS

Midbrain

When IV nerve lesion is associated with:

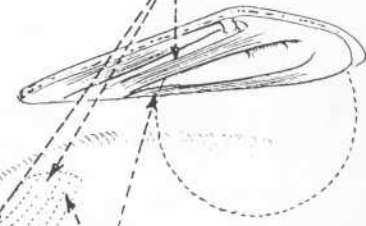
CONTRALATERAL HEMIPARESIS, CONTRALATERAL HEMISENSORY LOSS	} intrinsic midbrain lesion	} infarction, demyelination, intrinsic tumour, e.g. glioma
--------------------------------------------------------------	-----------------------------	------------------------------------------------------------

Proximity to anterior medullary velum and superior vermis } cerebellar tumour, e.g. medulloblastoma

Superior and inferior colliculi
Posterior cerebral and superior cerebellar arteries
Cerebellar peduncles
(Tentorium cerebelli and cerebellum omitted)

Lower pons

Orbital fissure orbit } Causes as for III nerve lesion
Cavernous sinus }



Orbital fissure orbit } Causes as for III nerve lesion
Cavernous sinus }

Petrous Bone

When VI nerve lesion is associated with:
PAIN in the distribution of trigeminal nerve (especially the first division) } petrositis – Gradenigo's syndrome
Excessive LACRIMATION – superior petrosal sinus involvement.

Long intracranial course may result in damage from raised intracranial pressure (false localising sign)

When VI nerve lesion is associated with:

CONTRALATERAL HEMIPARESIS, CONTRALATERAL HEMISENSORY LOSS, LOWER MOTOR NEURON VII LESION	} nuclear or intramedullary lesion	} infarction, demyelination, intrinsic tumour, e.g. glioma
------------------------------------------------------------------------------------------------	------------------------------------	------------------------------------------------------------

NOTE: Infective or carcinomatous meningitis and nerve trunk infarction may also involve the IV and VI nerves, although less often than the III nerve.

Investigative approach

Impaired ocular movement from III, IV or VI nerve lesions requires full investigation with conventional or dynamic CT scan, MRI and, where appropriate, CSF cytology. Unexplained III nerve lesions require angiography; only in elderly hypertensive or diabetic patients with pupillary sparing may angiography be omitted.

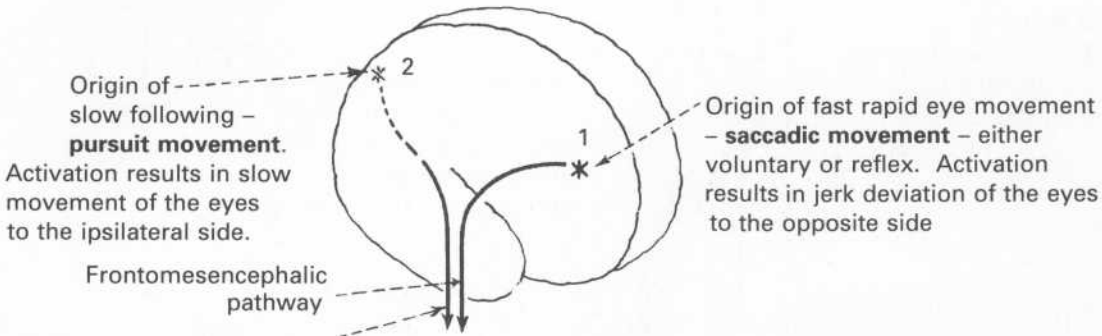
When myopathy or myasthenia gravis is suspected then appropriate investigations – acetyl choline receptor antibodies, EMG studies and occasionally muscle biopsy – may be necessary.

DISORDERS OF GAZE

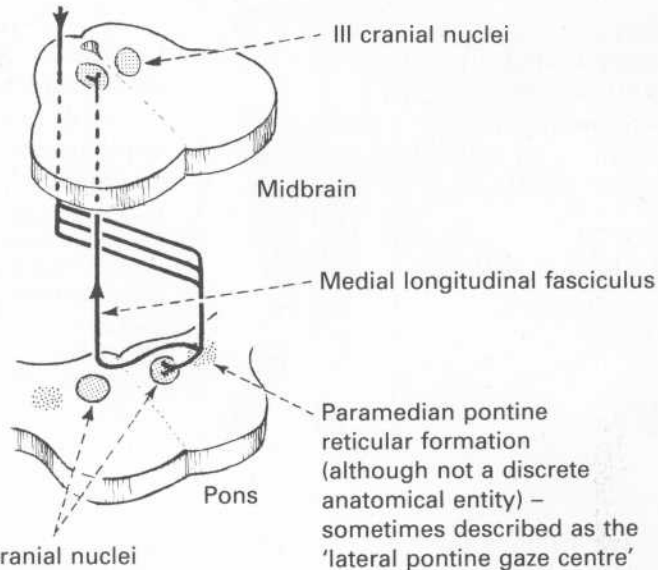
ANATOMY AND PHYSIOLOGY

Two cortical centres of ocular control are recognised:

1. Middle gyrus of frontal lobe (frontal eye field).
2. Occipital cortex.



Both project to the oculomotor III, trochlear IV and abducens VI cranial nuclei



Pathways for horizontal eye movement involving the III and VI nuclei are clearly delineated (as shown) but those controlling vertical eye movement are less well understood

Note that the cortical descending pathways from one side activate the ipsilateral III nucleus and the contralateral VI nucleus thus swinging the direction of gaze to the opposite side.

It is important to distinguish between **saccadic** and **pursuit** movement. When following an object a slow pursuit movement maintains the image on the macular area of the retina. To fixate on a new object, rapid saccadic movement aligns the new target on the macular area. When locked into the new target, pursuit movement maintains fixation.

Eye movement occurs voluntarily in a conjugate (parallel) manner in any direction. Eye movements also occur reflexly to labyrinthine stimulation.

DISORDERS OF GAZE

Gaze disorders usually follow vascular episodes (infarct or haemorrhage) but may also occur in traumatic, inflammatory or neoplastic disease. In gaze palsy eye movements are symmetrically limited in one direction.

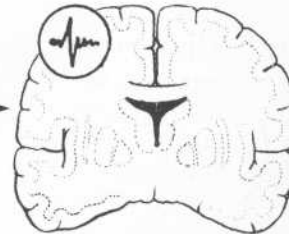
CONJUGATE DEVIATION OF THE EYES

Occurring during a seizure

Eyes deviate towards the affected limbs in a jerking fashion.



Indicates an epileptic focus in the frontal lobe contralateral to the direction of eye deviation.



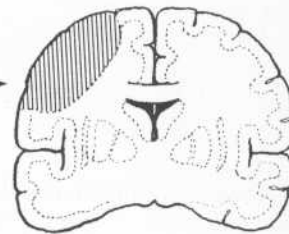
Accompanying a hemiparesis

Tonic deviation of the eyes *away* from the hemiparetic limb.



Indicates a lesion in the frontal lobe *ipsilateral* to the direction of eye deviation.

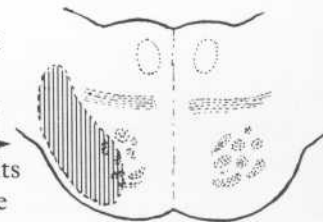
Haemorrhage deep in the cerebral hemisphere (thalamic) can cause deviation of eyes to the side of hemiparesis
- *wrong-way eyes*



Tonic deviation of the eyes *towards* the hemiparetic limb.



Usually indicates a lesion in the pons *contralateral* to the direction of eye deviation and results from damage to the paramedian pontine reticular formation (PPRF)



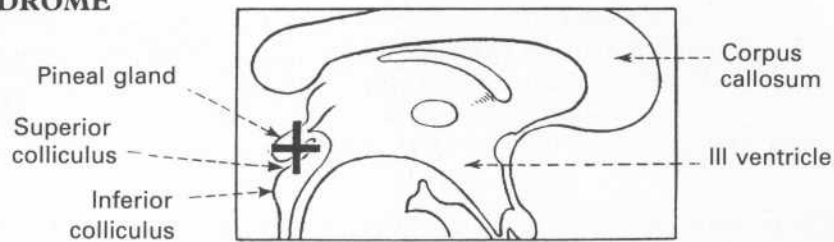
DISORDERS OF GAZE

VERTICAL GAZE PALSY

Midbrain or pontine lesions may produce failure of upward or downward gaze. Disturbed downward gaze alone occurs with periaqueductal (Sylvian aqueduct) lesions. Impaired vertical eye movement is common in extrapyramidal disease (Progressive supranuclear palsy, page 357).

PARINAUD'S SYNDROME

This syndrome is characterised by impaired upward eye movements in association with a dorsal midbrain lesion (+).



- upward gaze and convergence are lost
- the pupils may dilate and the response to light and accommodation is impaired

Causes:

- | | |
|---------------------------|---------------------------|
| Third ventricular tumours | Multiple sclerosis |
| Pineal region tumours | Wernicke's encephalopathy |
| Hydrocephalus | Encephalitis |

INTERNUCLEAR OPHTHALMOPLEGIA (ataxic nystagmus)

This disorder, caused by damage to the medial longitudinal bundle, is dealt with on page 182. It is an *internuclear* disorder of eye movement and produces a disconjugate gaze palsy.

Two unusual disconjugate gaze palsies are -

Wabino syndrome (wall eyes - bilateral internuclear ophthalmoplegia): characterised by bilateral exotropia and loss of convergence



'Look right'



'Look left'



The 'One and a half' syndrome: Conjugate gaze palsy to one side and impaired adduction on looking to the other side

OCULAR APRAXIA

Bilateral prefrontal motor cortex damage will produce this unusual finding in which the patient does not move the eyes voluntarily to command, yet has a full range of random eye movement.

FACIAL PAIN AND SENSORY LOSS

The fifth cranial nerve subserves facial sensation and innervates the muscles of mastication.

Anatomy

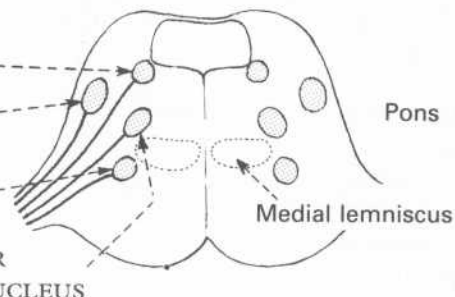
The anatomical arrangement of the trigeminal central connections are complex.

Proprioceptive fibres terminate in the
MESENCEPHALIC NUCLEUS

Light touch fibres terminate in the
MAIN SENSORY NUCLEUS

Pain and temperature fibres terminate in the
NUCLEUS of the DESCENDING
TRIGEMINAL TRACT

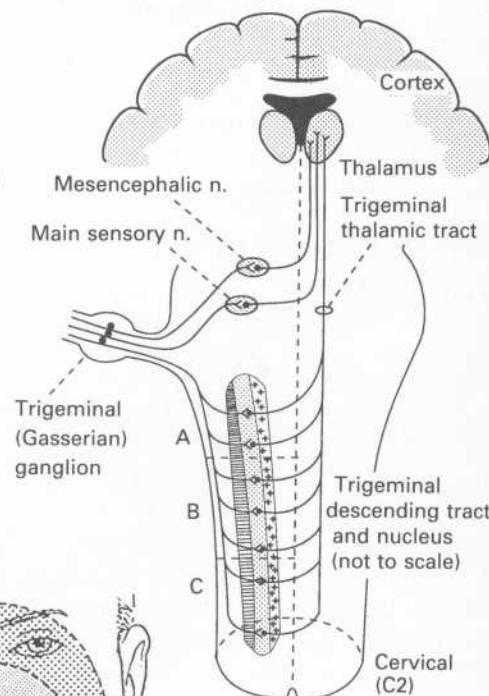
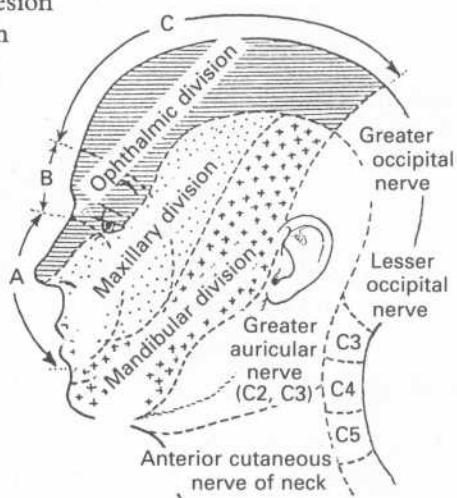
Motor fibres arise from the TRIGEMINAL MOTOR
NUCLEUS



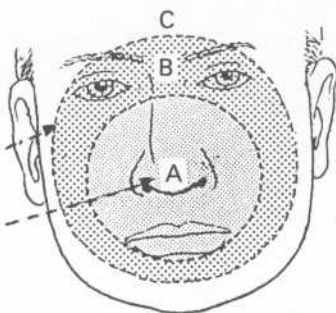
The separate location of the main sensory nucleus and nucleus of the descending trigeminal tract account for **dissociated sensory loss**,

i.e. a low pontine or medullary lesion will result in loss of pain and temperature sensation with preservation of light touch.

Longitudinal arrangement of the trigeminal nuclei (sensory paths)



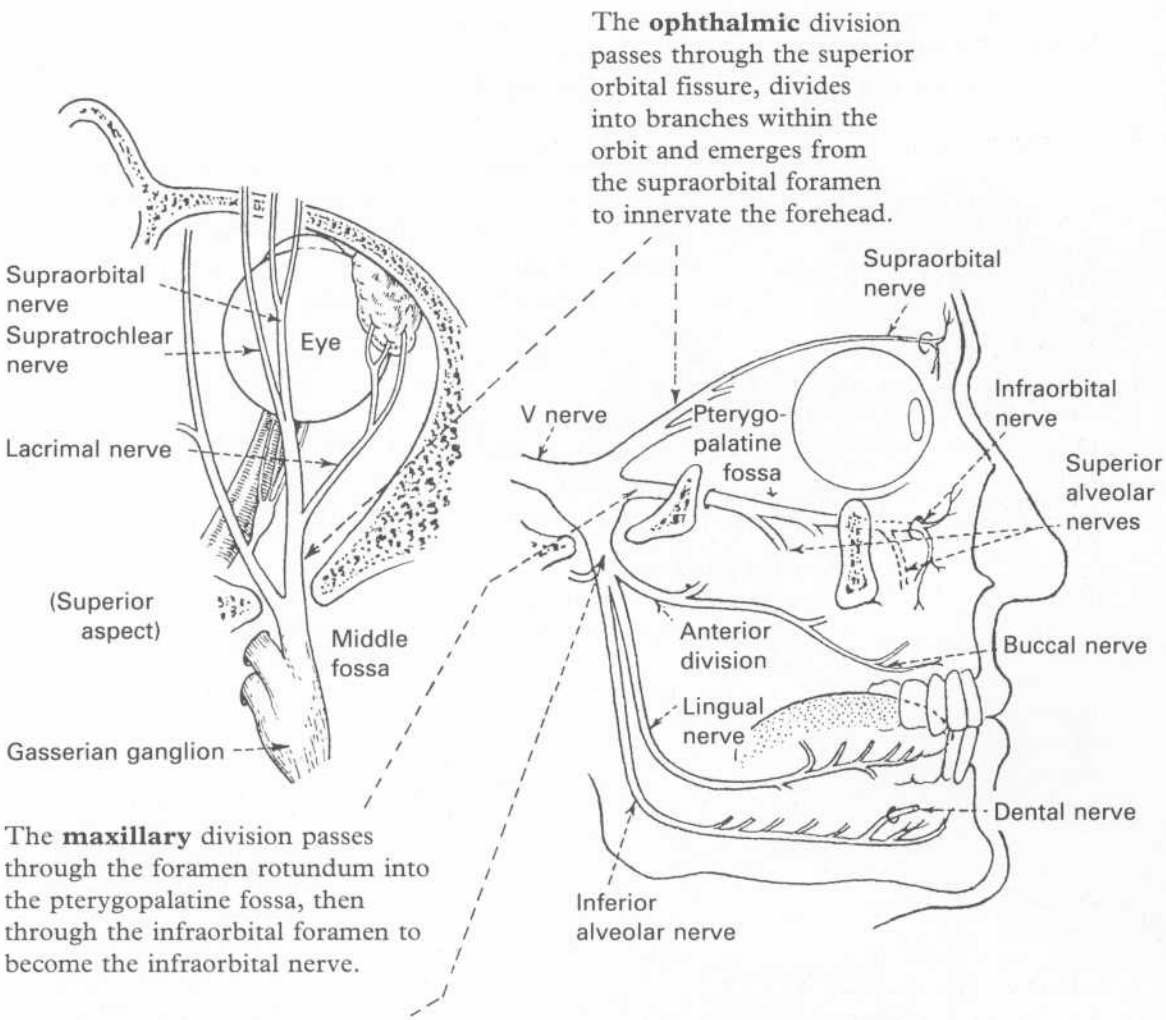
Note the topographical arrangement of the descending nucleus. Low pontine, medullary and cervical lesions produce a characteristic 'onion skin' distribution of pinprick and temperature loss. An ascending lesion spares the muzzle area until last.



FACIAL PAIN AND SENSORY LOSS

The peripheral course of the V nerve

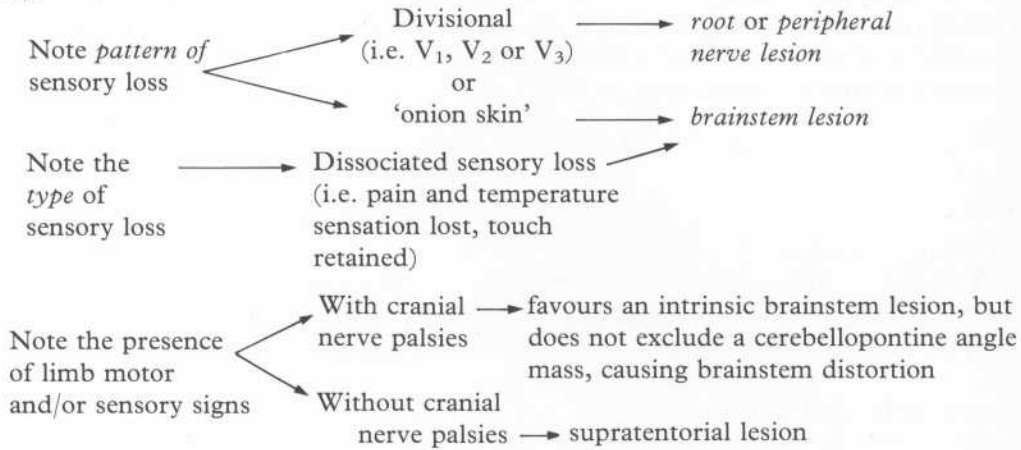
The motor and sensory nerve roots emerge separately from the lateral aspect of the brain stem at the midpontine level. The Gasserian ganglion of the sensory root contains bipolar sensory nuclei and lies on the apex of the petrous bone in the middle fossa. Here the three divisions of the trigeminal nerve merge. Each passes through its own foramen and carries sensation from a specific area of the face.



FACIAL PAIN AND SENSORY LOSS

EXAMINATION OF TRIGEMINAL NERVE FUNCTION.

This should include examination of the *corneal reflex* and *masticatory muscle function* (page 14).



CAUSES OF V NERVE LESIONS

Pons

When associated with other cranial nerve lesions and long tract signs:

- vascular
- neoplastic
- demyelination
- syringobulbia

(especially dissociated sensory loss)

(Tentorium cerebelli omitted)

Other causes

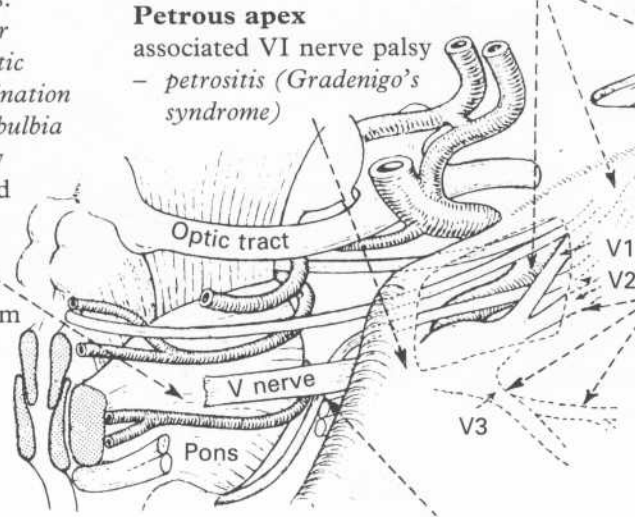
- diabetes
- SLE

Orbital fissure
Orbit
Cavernous sinus

First division of V nerve ± III, IV and VI } (see III nerve lesions, page 149).

Petrous apex

associated VI nerve palsy
- petrositis (Gradenigo's syndrome)



Skull base

One or more V divisions involved:

- nasopharyngeal or metastatic carcinoma
- trauma (e.g. infraorbital nerve - malar fracture)

Cerebello-pontine angle

When associated with other cranial nerve lesions ± long tract signs:

- acoustic neuroma
- trigeminal neuroma
- subacute (chronic) meningitis

FACIAL PAIN AND SENSORY LOSS

Sensory trigeminal neuropathy:

Progressive, painless loss of trigeminal sensation. Normally unilateral and without trigeminal motor weakness, the sensory loss may affect one or all trigeminal divisions. This condition is often associated with established connective tissue disease (scleroderma, Sjögren's syndrome and mixed connective tissue disease (MCTD)). Diagnosis requires exclusion of intracranial granuloma and tumour compressing the trigeminal nerve – meningioma, schwannoma, epidermoid – by contrast enhanced MRI.

Mental neuropathy (numb chin syndrome):

Caused by a lesion of the mandibular nerve or inferior alveolar or mental branches, usually the result of metastatic compression of the nerve within the mandible. Bone scans or an enhanced CT/MRI combined with image-guided aspiration is diagnostic.

Infraorbital neuropathy (numb cheek syndrome) has similar etiology.

Gradenigo's syndrome:

Lesions located at the petrous-temporal bone apex (osteitis or meningitis associated with otitis media) irritate the ophthalmic division of the trigeminal and abducens (VI) nerve. Forehead pain is accompanied by ipsilateral lateral rectus palsy and a Horner's syndrome if sympathetic fibres are also involved. Tumours and trauma can also produce this syndrome.

Neuropathic Keratitis

Corneal anaesthesia from a central or peripheral V nerve lesion may lead to a neuropathic keratitis. The corneal surface becomes hazy, ulcerated and infected and blindness may follow.

Patients with absent corneal sensation should wear a protective shield, attached to the side of spectacles, when out of doors.

FACIAL PAIN—DIAGNOSTIC APPROACH

Pain in the face may result from many different disorders and often presents as a diagnostic problem to the neurologist or neurosurgeon.

Consider:

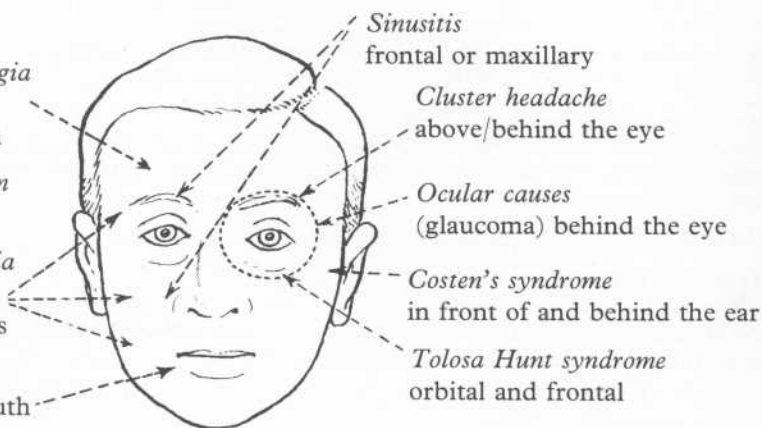
1. Site of pain

Postherpetic neuralgia
usually 1st
trigeminal division

Atypical facial pain
diffuse

Trigeminal neuralgia
1st, 2nd, 3rd
trigeminal divisions

Dental around mouth



2. Quality of pain

Trigeminal neuralgia	– sharp, stabbing, shooting, paroxysmal
Atypical facial pain	– dull, persisting
Postherpetic neuralgia	– dull, burning, persisting, occasional paroxysm
Dental	– dull
Sinusitis	– sharp, boring, worse in the morning
Ocular	– dull, throbbing
Costen's syndrome	– severe aching, aggravated by chewing
Cluster headache	– sharp, intermittent

3. Associated symptoms/signs

Trigeminal neuralgia	– often no neurological deficit, but occasional blunting of pinprick over involved region
Atypical facial pain	– accompanying features of depressive illness
Postherpetic neuralgia	– evidence of scarring associated with sensory loss
Dental	– swelling of lips/face
Sinusitis	– puffy appearance around eyes, tenderness to percussion over involved sinus
Ocular	– glaucoma: associated visual symptoms – blurring/haloes/loss
Costen's syndrome	– tenderness over temporomandibular joint
Cluster headache	– associated lacrimation/rhinorrhoea

Investigations

– guided by clinical suspicion

Blood tests: ESR, FBC, biochemistry.

Imaging: CT/MRI, dental X-rays, isotope bone scan.

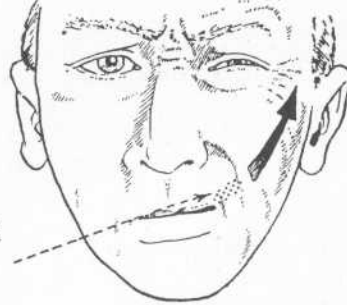FACIAL PAIN – TRIGEMINAL NEURALGIA

TRIGEMINAL NEURALGIA (tic douloureux)

Trigeminal neuralgia is characterised by paroxysmal attacks of severe, short, sharp, stabbing pain affecting one or more divisions of the trigeminal nerve. The pain involves the second or third divisions more often than the first; it rarely occurs bilaterally, and never simultaneously on each side, occasionally more than one division is involved. Paroxysmal attacks last for several days or weeks; they are often superimposed on a more constant ache. When the attacks settle, the patient may remain pain free for many months.

Chewing, speaking, washing the face, tooth-brushing, cold winds, or touching a specific 'trigger spot', e.g. upper lip or gum, may all precipitate an attack of pain.

Trigeminal neuralgia more commonly affects females and patients over 50 years of age.



Aetiology

In many patients the cause remains unexplained, as do the long periods of remission. Trigeminal pain may be symptomatic of disorders which affect the nerve root or its entry zone.

Root or root entry zone compression – tumours of the cerebellopontine angle lying against the V nerve roots, e.g. meningioma, epidermoid cyst, frequently present with trigeminal pain.

– *arterial vessels* often abut and sometimes clearly indent the trigeminal nerve root at the entry-zone into the pons.

Demyelination – such a lesion in the pons should be considered in a 'young' person with trigeminal neuralgia. Trigger spots are rare. Remission occurs infrequently and the response to drug treatment is poor.

Investigation

CT or preferably MR scan to exclude a cerebello-pontine angle lesion.

Management

Drug therapy

CARBAMAZEPINE proves effective in most patients (and helps confirm the diagnosis). Provided toxicity does not become troublesome, i.e. drowsiness, ataxia, the dosage is increased until pain relief occurs (600–1600 mg/day). When remission is established, drug treatment can be discontinued.

If pain control is limited, other drugs – BACLOFEN, LAMOTRIGINE, PIMOZIDE (dopamine receptor antagonist), PHENYTOIN – may benefit.

Persistence of pain on full drug dosage or an intolerance of the drugs, indicates the need for more radical measures.

FACIAL PAIN – TRIGEMINAL NEURALGIA

MANAGEMENT (contd)

Operative therapy

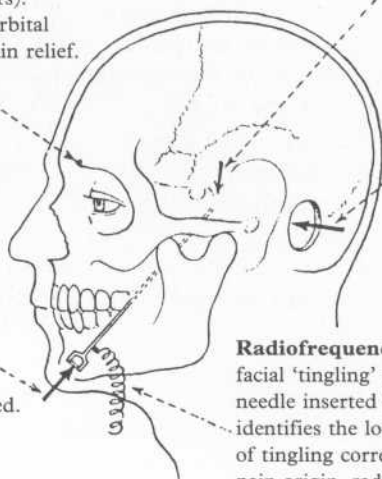
Peripheral nerve techniques: Nerve block with alcohol or phenol provides temporary relief (up to two years).

Avulsion of the supra- or infraorbital nerves gives more prolonged pain relief.

Trigeminal ganglion/root injection:

Alcohol or phenol injection into the trigeminal ganglion effectively produces pain relief, but area control is limited and the risk of corneal anaesthesia, ulceration and scarring is high. Now rarely used.

Glycerol injection into Meckel's cave usually produces good pain relief with less sensory damage.



Trigeminal root section: Through either a subtemporal (extra- or intradural) or posterior fossa approach, the appropriate trigeminal root is identified and divided.

Microvascular decompression:

Exploration of the cerebellopontine angle reveals blood vessels in contact with the trigeminal nerve root or root entry zone in the majority of patients. Separation of these structures and insertion of a non absorbable sponge produces pain relief in most patients, without the associated problems of nerve destruction.

Radiofrequency thermocoagulation: The site of facial 'tingling' produced by electrical stimulation of a needle inserted into the trigeminal ganglion, accurately identifies the location of the needle tip. When the site of tingling corresponds to the trigger spot or site of pain origin, radiofrequency thermocoagulation under general anaesthetic, produces a permanent lesion – usually resulting in analgesia of the appropriate area with retention of light touch.

Results and complications

Pain relief – accurate comparison of the wide variety of techniques used for trigeminal neuralgia is difficult; all but peripheral nerve avulsion appear to produce similar results. Approximately 80–85% of patients remain pain free for a 5-year period. Results of peripheral nerve avulsion are less satisfactory with pain recurring in 50% within 2 years.

Dysaesthesia/Anaesthesia dolorosa – this troublesome sensory disturbance follows any destructive technique to nerve or root in 5–30% of patients. Microvascular decompression avoids this problem and the risk of a severe deficit is low with glycerol injection.

Corneal anaesthesia – this occurs most frequently following phenol or alcohol injection into the trigeminal ganglion, but is also a problem when root section or thermocoagulation involves the first division.

Mortality – microvascular decompression and open root section carry a very low mortality (about 1%), but this must not be ignored when comparing results with safer methods.

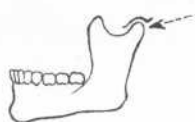Treatment selection: This largely depends on the surgeon's personal preference and experience.

In many centres, the absence of sensory complications make microvascular decompression the procedure of first choice, particularly for 1st division pain and for the younger patient.

Frail and elderly patients may tolerate glycerol injection and thermocoagulation more easily than other procedures.

FACIAL PAIN – OTHER CAUSES

Temporomandibular joint dysfunction (Costen's syndrome)

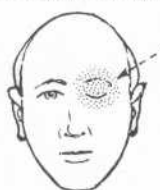


Aching pain occurring around the ear, aggravated by chewing; due to malalignment of one temporomandibular joint as a consequence of dental loss with altered 'bite' or involvement of the joint in rheumatoid arthritis. This condition requires dental treatment with realignment.

Raeder's syndrome (the paratrigeminal syndrome)

Pain and sensory loss in 1st and 2nd trigeminal divisions, maximal around the eye and associated with a sympathetic paresis (ptosis and small pupil). Sweating in the lower face is preserved. This may be associated with involvement of the other cranial nerves (IV & VI). The syndrome occurs with lesions of the middle fossa, e.g. nasopharyngeal carcinoma, granulomas and infection.

Tolosa Hunt syndrome



A condition in which an inflammatory process involving the cavernous sinus or superior orbital fissure presents with pain, loss of ocular movement and ophthalmic division sensory loss. The diagnosis is based on exclusion of tumour and response to steroids. Pathological examination confirms non-specific granulomatous change.

Atypical facial pain

The patient, often a young or middle-aged woman, experiences a dull, persistent pain, spreading diffusely over one or both sides of the face. These symptoms often result from an underlying depression and may respond well to antidepressant therapy.

Herpes zoster

Frequently affects the trigeminal territory, especially the ophthalmic division producing a painful 'herpetic rash' and often involving the cornea. The acute symptoms may resolve but lead to a chronic postherpetic neuralgia which slowly improves. Surgical procedures such as trigeminal root section do not help. The incidence of postherpetic neuralgia is not influenced by treatment with antiviral agents (acyclovir) in the acute phase.

Carotidynia

A form of migraine characterised by intermittent facial pain associated with vasomotor rhinitis and tenderness of the carotid artery. It may be precipitated by alcohol.

Carotid artery dissection

This presents as acute retro-orbital pain with a Horner's syndrome (page 141).

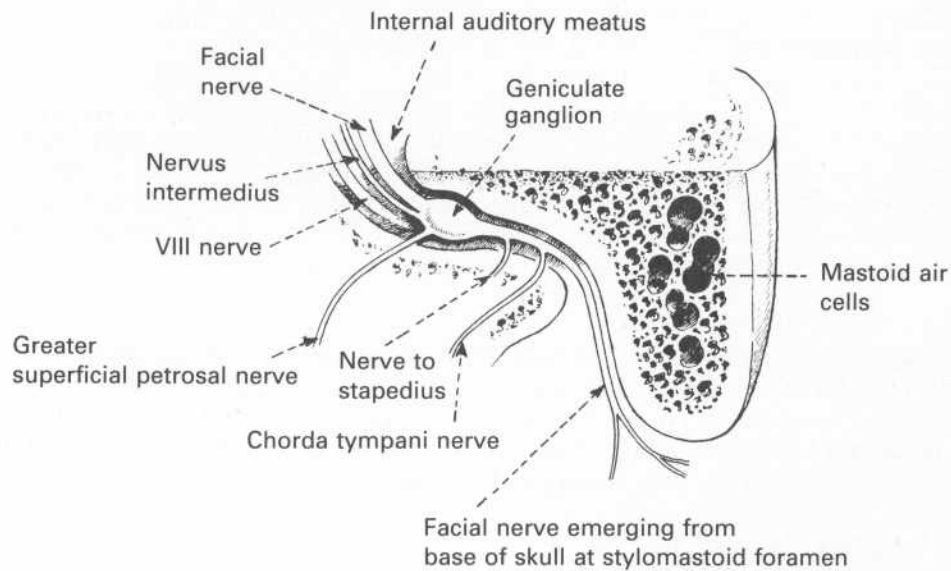
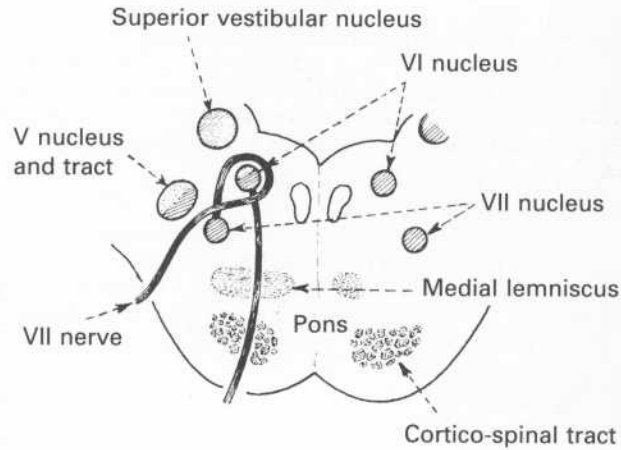
'Cluster' headaches – see page 68.

FACIAL WEAKNESS

Related anatomy

The facial (VII) nerve contains mainly motor fibres supplying the muscles of facial expression, but also visceral efferent (parasympathetic) and visceral afferent (taste) fibres.

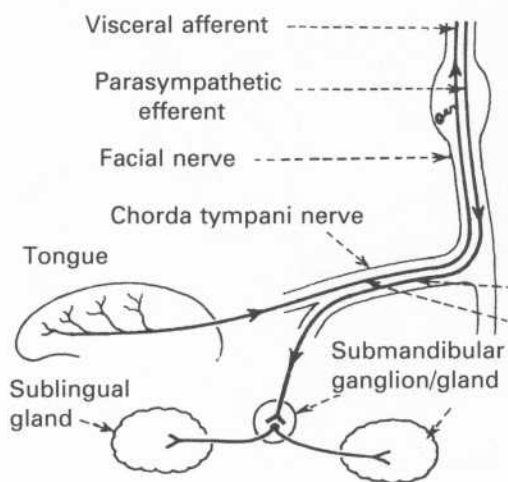
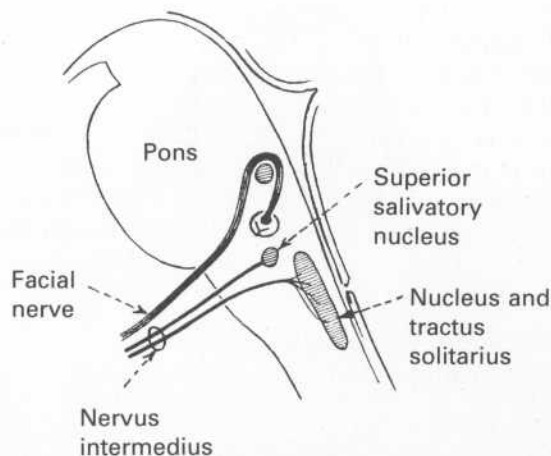
The motor nucleus lies in the lower pons medial to the descending nucleus and tract of the Vth cranial nerve. Axons from the motor nucleus wind around the nucleus of the VIth cranial nerve. The facial nerve and its visceral root (*nervus intermedius*) exit from the lateral aspect of the brain stem and cross the cerebellopontine angle immediately adjacent to the VIII cranial nerve. They enter the internal auditory meatus and, passing through the facial canal of the temporal bone, lie in close proximity to the inner ear and tympanic membrane. The facial nerve gives off several branches before exiting from the skull through the stylomastoid foramen.



FACIAL WEAKNESS

Visceral efferent and visceral afferent fibres arise and terminate in the superior salivary nucleus and nucleus/tractus solitarius respectively.

They run together as the nervus intermedius and accompany the facial nerve to the internal auditory meatus. The parasympathetic fibres (visceral efferent) pass in the greater petrosal nerve to the sphenopalatine ganglion and thence to the lacrimal gland to produce tears and in the chorda tympani nerve to the submandibular ganglion.



The chorda tympani nerve contains both parasympathetic efferent and visceral afferent fibres.

Parasympathetic fibres are responsible for salivation.

Visceral afferent fibres convey sensations of taste from the anterior two-thirds of the tongue. The geniculate ganglion contains the bipolar cell bodies of these afferent fibres.

Supranuclear control of facial muscles

The muscles in the lower face are controlled by the contralateral hemisphere, whereas those in the upper face receive control from both hemispheres (bilateral representation). Hence a lower motor neuron lesion paralyses all facial muscles on that side, but an upper motor neuron (supranuclear) lesion paralyses only the muscles in the lower half of the face on the opposite side.

Clinical examination of the facial nerve (see page 15)

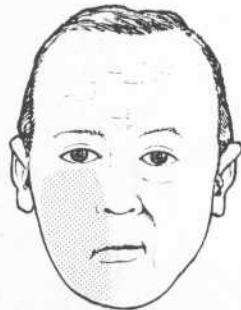In addition to examining for facial weakness and taste impairment, also note whether the patient comments on reduced lacrimation or salivation on one side, or hyperacusis (exaggeration of sounds due to loss of the stapedius reflex).

FACIAL WEAKNESS

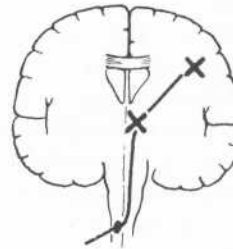
LESION, LOCALISATION AND CAUSE

Note the *distribution*:

Unilateral
involvement
of the *lower*
face, with
near normal
eye closure



indicates
a **CONTRALATERAL**
SUPRANUCLEAR
lesion

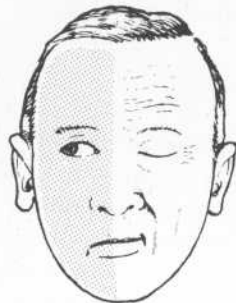

CAUSES

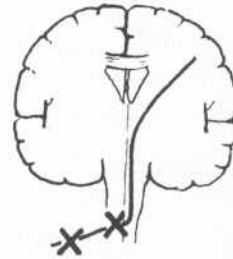
- vascular
- tumour
- demyelination
- infection

(Spontaneous emotional expression
may be unaffected with subcortical lesions)

Unilateral
involvement of
the *upper* and
lower face
with defective
eye closure



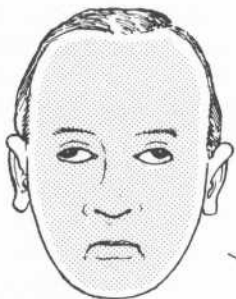indicates an
IPSILATERAL
NUCLEAR OR
INFRANUCLEAR
lesion



(see
opposite)

(Spontaneous emotional expression affected).

Bilateral
involvement of
the *upper* and
lower face



BILATERAL
NUCLEAR
lesions
(associated with
other features of
pseudobulbar palsy:
(see page 534)

- Pontine lesions
- infarction
 - haemorrhage
 - demyelination
 - tumour
 - infection
 - syringobulbia
 - motor neuron disease
 - Moebius' syndrome *

BILATERAL
INFRANUCLEAR
lesions

-
- Guillain Barré syndrome
 - Lyme disease
 - Infectious mononucleosis
 - Sarcoidosis

MUSCLE DISEASE →

- myasthenia gravis
- muscular dystrophy

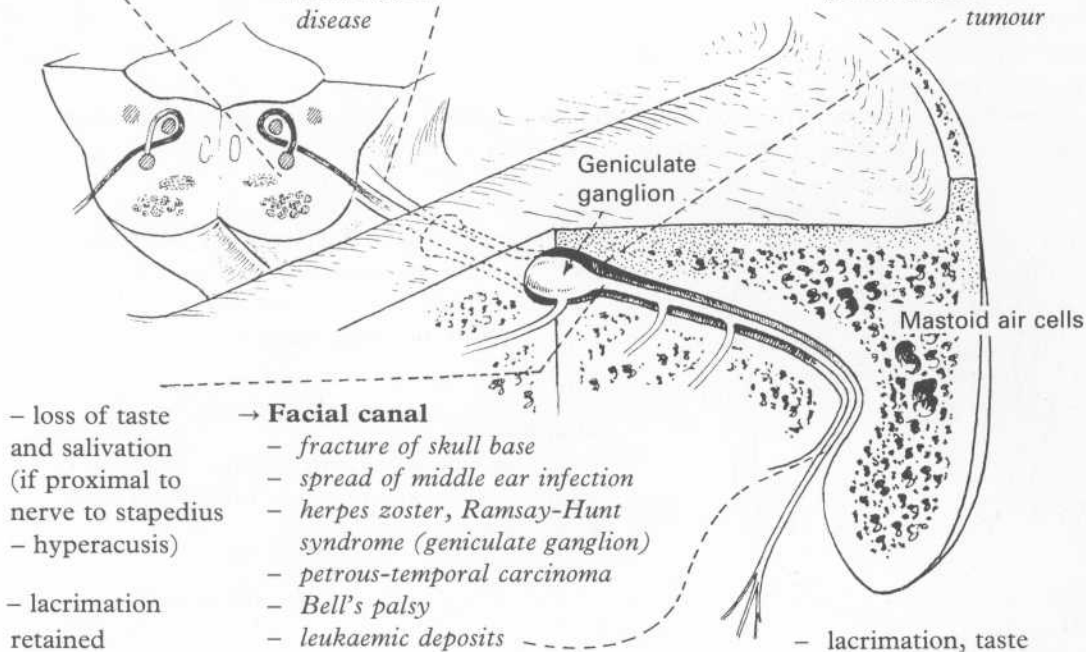
Eyes move outwards
and upwards on
attempted closure –
Bell's phenomenon

FACIAL WEAKNESS

NUCLEAR/INFRANUCLEAR LESIONS

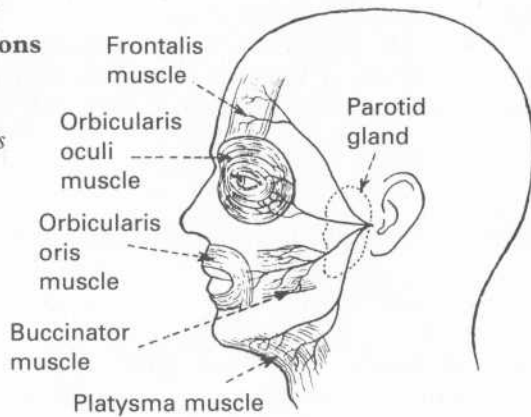
The following features (if present) help in lesion location:

- | | | | |
|-----------------------------------------------------------------------------------------------------------|---------------------------------------------------------------------------------------------------------------------------------------------------------------------------------------------------------------|--------------------------------------------------------------------------------------------------------------------------------------------------------------------------------|-----------------------------------------------------------------------------------------------------------------------------------------------------------------------------------------------------------------------|
| <ul style="list-style-type: none"> - VI nerve palsy - contralateral limb weakness | <p>→ Pons</p> <ul style="list-style-type: none"> - vascular - demyelination - tumour - encephalitis - syringobulbia - motor neuron disease | <ul style="list-style-type: none"> - V, VIII, (IX, X, XI) → nerve palsies - loss of taste, salivation, and lacrimation - hyperacusis | <p>→ Cerebellopontine angle or internal auditory meatus</p> <ul style="list-style-type: none"> - acoustic tumours - meningioma - epidermoid - glomus jugulare tumour |
|-----------------------------------------------------------------------------------------------------------|---------------------------------------------------------------------------------------------------------------------------------------------------------------------------------------------------------------|--------------------------------------------------------------------------------------------------------------------------------------------------------------------------------|-----------------------------------------------------------------------------------------------------------------------------------------------------------------------------------------------------------------------|



Other causes of facial nerve lesions

- diabetes
- infectious mononucleosis



Peripheral nerve

- parotid gland lesion, e.g. uveoparotid fever of sarcoidosis
- parotid operations
- facial trauma

BELL'S PALSY

Bell's palsy is characterised by an acute paralysis of the face related to 'inflammation' and swelling of the facial nerve within the facial canal or at the stylomastoid foramen. It is usually unilateral, rarely bilateral, and may occur repetitively. In some, a family history of the condition is evident.

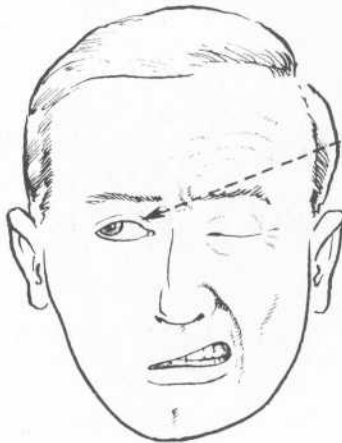Aetiology

Uncertain, but may be associated with viral infections, e.g. herpes simplex and varicella-zoster; epidemics of Bell's palsy occur sporadically. Bells palsy may be part of the syndrome of polyneuritis cranialis.

Symptoms

Pain of variable intensity over the ipsilateral mastoid precedes weakness, which develops over a 48-hour period.

Impairment of taste, hyperacusis and salivation depend on the extent of inflammation and will be lost in more severe cases. Lacrimination is seldom affected.



On attempting to close the eyes and show the teeth, the one eye does not close and the eyeball rotates upwards and outwards – Bell's phenomenon (normal eyeball movement on eye closure).

Diagnosis

Based on typical presentation and exclusion of middle ear disease, diabetes, sarcoidosis and Lyme disease.

Treatment

During the acute stage protect the exposed eye during sleep.

Prednisolone given in high dosage in the acute stage (40–60 mg per day for 5 days) may reduce inflammation, but there is no conclusive evidence of benefit. Antiviral therapy – acyclovir is currently under evaluation. Eye care (shielding) is important in preventing corneal abrasion.

Prognosis

Most patients (80%) recover in 4–8 weeks without treatment. In the remainder, residual facial asymmetry may require corrective surgery. Incomplete paralysis indicates a good prognosis. In patients with complete paralysis, electrical absence of denervation on electromyography is an optimistic sign.

Occasionally aberrant reinnervation occurs – movement of the angle of the mouth on closing the eyes (Jaw winking) or lacrimation when facial muscles contract (crocodile tears).

OTHER FACIAL NERVE DISORDERS

RAMSAY HUNT SYNDROME

Herpes zoster infection of the geniculate (facial) ganglion causes sudden severe facial weakness with a typical zoster vesicular eruption within the external auditory meatus. Pain is a major feature and may precede the facial weakness. Serosanguinous fluid may discharge from the ear.

Deafness may result from VIII involvement. Occasionally, other cranial nerves from V–XII are affected.

Treatment

Antiviral agents (acyclovir) may help.

HEMIFACIAL SPASM

This condition is characterised by unilateral clonic spasms beginning in the orbicularis oculi and spreading to involve other facial muscles. The stapedius muscle can be affected producing a subjective ipsilateral clicking sound.

Contractions are irregular, intermittent and worsened by emotional stress and fatigue.

Onset usually occurs in middle to old age and women are preferentially affected.

The aetiology remains unknown but 'irritation' from an adjacent blood vessel (or from a tumour) may cause demyelination and 'short-circuiting' within the nerve. Occasionally hemifacial spasm follows a Bell's palsy or traumatic facial injury.

The clinician must distinguish hemifacial spasm from milder habit spasms or tics which tend to be familial, and also from 'focal' seizures selectively affecting the face.

Investigations

CT/MR scan of the posterior fossa excludes the presence of a cerebellar pontine angle lesion and may show an ectatic basilar artery.

Treatment

Drugs – Anxiolytics and carbamazepine may produce some benefit but are of no lasting value. When spasm is confined to orbicularis oculi, local infiltration with botulinum toxin is helpful.

Surgery – Posterior fossa exploration and microvascular decompression i.e. dissecting blood vessels off the facial nerve roots and root entry zone, gives excellent results (cure rate 80%), but carries the risk of producing deafness and rarely brainstem damage. Alternative, less successful treatments include phenol injection or partial section of the facial nerve; these methods inevitably cause some facial weakness.

TONIC FACIAL SPASM

Less common than hemifacial spasm. Occurs with cerebellar pontine angle lesions. It produces tonic elevation of the corner of the mouth with narrowing of the eye. The diagnosis is confirmed by CT/MR scanning and treatment is surgical.

FACIAL MYOKYMIA

A rare condition seen most often in multiple sclerosis. Flickering of facial muscles results from spontaneous discharge in the facial motor nucleus. Other brainstem signs are present. The facial movements respond to carbamazepine.

MYOCLONUS

Rhythmic facial movement associated with similar palatal movements and characteristic of dentate or olivary nucleus disease.

BLEPHAROSPASM

Spasmodic closing or screwing up of eyes (see page 357).

DEAFNESS, TINNITUS AND VERTIGO

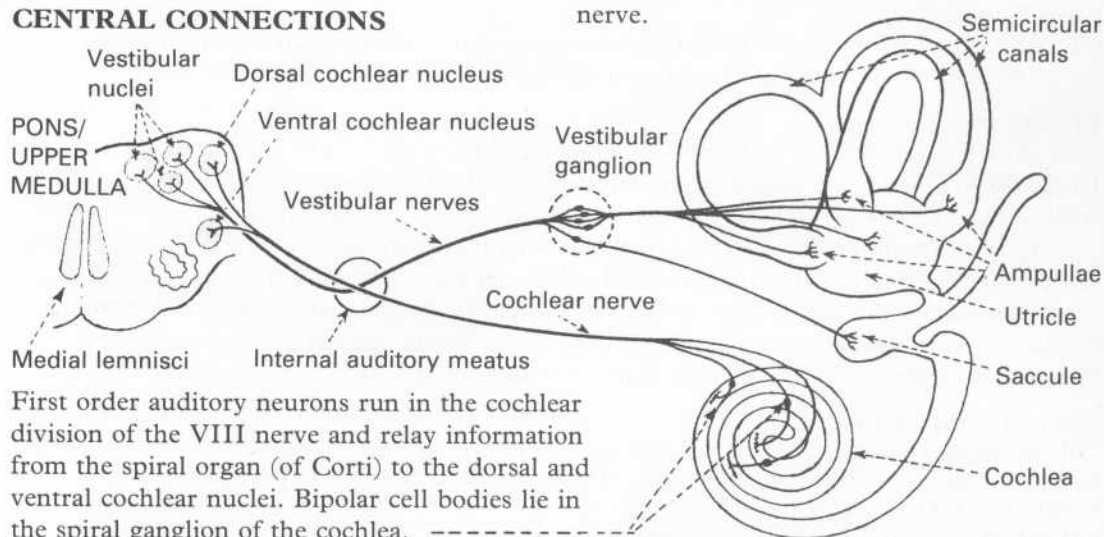
Deafness, tinnitus and vertigo result from disorders affecting the auditory and vestibular apparatus or their central connections transmitted through the VIII cranial nerve.

MECHANISMS OF AUDITORY AND VESTIBULAR FUNCTION

Auditory function: the cochlea converts sound waves into action potentials in cochlear neurons. Sound waves are transmitted by the tympanic membrane and the ossicles to the oval window, setting up waves in the perilymph of the cochlea. The action of the waves on the spiral organ (of Corti) generates action potentials in the cochlear division of the VIII cranial nerve.

Vestibular function: the vestibular system responds to rotational and linear acceleration (including gravity) and along with a visual and proprioceptive input maintains equilibrium and body orientation in space. Relative inertia of the endolymph within the semicircular canals during angular acceleration displaces hair cells imbedded in the cupula, activates the hair cells and transmits action potentials to the vestibular division of the VIII cranial nerve. Linear acceleration results in displacement of the otoliths within the utricle or saccule. This distorts the hair cells and increases or decreases the frequency of action potentials in the vestibular division of the VIII cranial nerve.

CENTRAL CONNECTIONS



First order auditory neurons run in the cochlear division of the VIII nerve and relay information from the spiral organ (of Corti) to the dorsal and ventral cochlear nuclei. Bipolar cell bodies lie in the spiral ganglion of the cochlea.

First order vestibular neurons lie in the vestibular division of the VIII nerve and relay information from the utricle, saccule and semicircular canals to the vestibular nuclei (superior, inferior, medial and lateral). Bipolar cell bodies lie in the vestibular ganglion.

The cochlear (acoustic) and vestibular divisions travel together through the petrous bone to the internal auditory meatus where they emerge to pass through the subarachnoid space in the cerebellopontine angle, each entering the brain stem separately at the pontomedullary junction.

DEAFNESS, TINNITUS AND VERTIGO

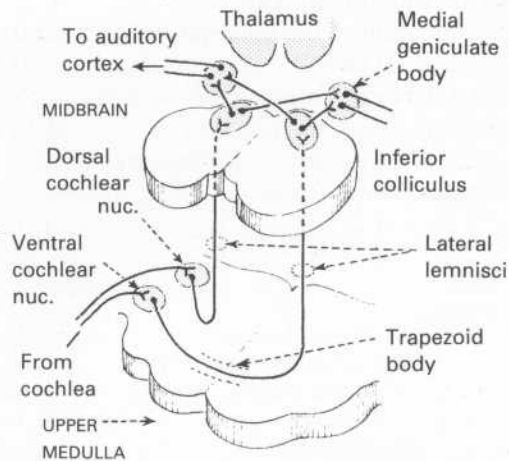
CENTRAL CONNECTIONS (contd)

Auditory: From the cochlear nucleus, second order neurons either pass upwards in the lateral lemniscus to the ipsilateral inferior colliculus or decussate in the trapezoid body and pass up in the lateral lemniscus to the contralateral inferior colliculus.

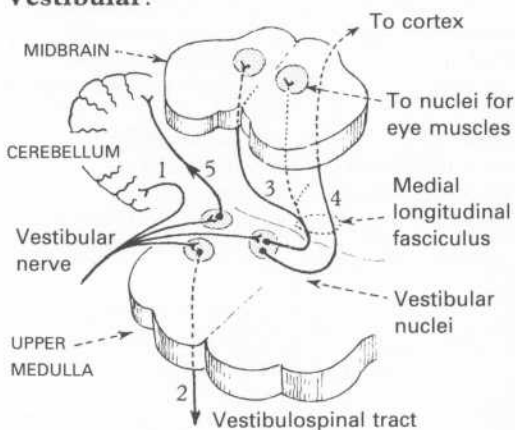
Third order neurons from the inferior colliculus on each side run to the medial geniculate body on both sides.

Fourth order neurons pass through the internal capsule and auditory radiation to the auditory cortex.

The bilateral nature of the connections ensures that a unilateral central lesion will not result in lateralised hearing loss.



Vestibular:



1. Directly to cerebellum.
2. Second order neurons arise in the vestibular nucleus and descend in the ipsilateral vestibulospinal tract.
3. Second order neurons project to the oculomotor nuclei (III, IV, VI) through the medial longitudinal fasciculus.
4. Second order neurons project to the cortex (temporal lobe). The pathway is unclear.
5. Second order neurons project to the cerebellum.

(There is a bilateral feedback loop to the vestibular nuclei from the cerebellum through the fastigial nucleus.)

DEAFNESS: Three types of hearing loss are recognised:

1. *Conductive deafness:* failure of sound conduction to the cochlea.
2. *Sensorineural deafness:* failure of action potential production or transmission due to disease of the cochlea, cochlear nerve or cochlear central connections. Further subdivision into cochlear and retrocochlear deafness helps establish the causative lesion.
3. *Pure word or cortical deafness:* a bilateral or dominant posterior temporal lobe (auditory cortex) lesion produces a failure to understand spoken language despite preserved hearing.

TINNITUS: a sensation of noise of ringing, buzzing, pulsing, hissing or singing quality.

Tinnitus may be (i) continuous or intermittent, (ii) unilateral or bilateral, (iii) high or low pitch.

As a rule, when hearing loss is accompanied by tinnitus, conductive deafness is associated with low pitch tinnitus – sensorineural deafness is associated with high pitch tinnitus, except Meniere's disease where tinnitus is low pitch. Pulsing tinnitus has a vascular cause.

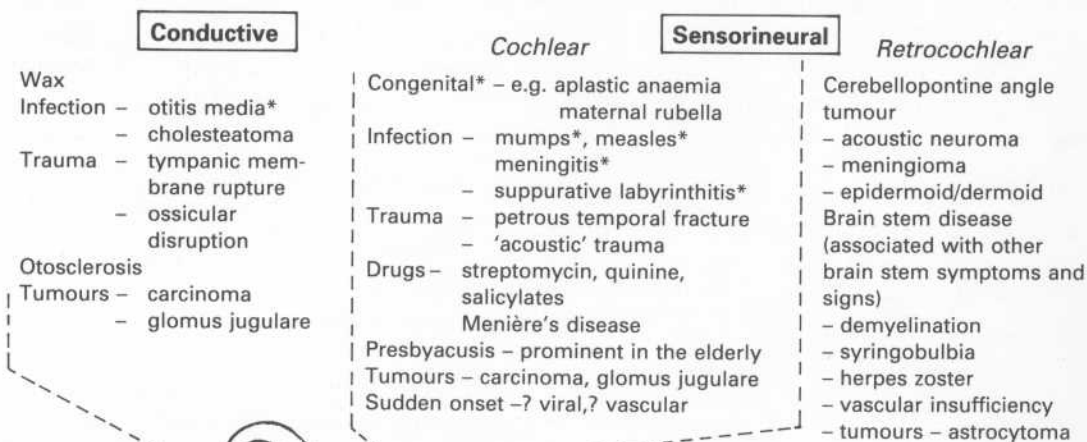
VERTIGO: an illusion of rotatory movement due to disturbed orientation of the body in space. The sufferer may sense that the environment is moving. Vertigo may result from disease of the labyrinth, vestibular nerve or their central connections.

DEAFNESS, TINNITUS AND VERTIGO

Clinical examination

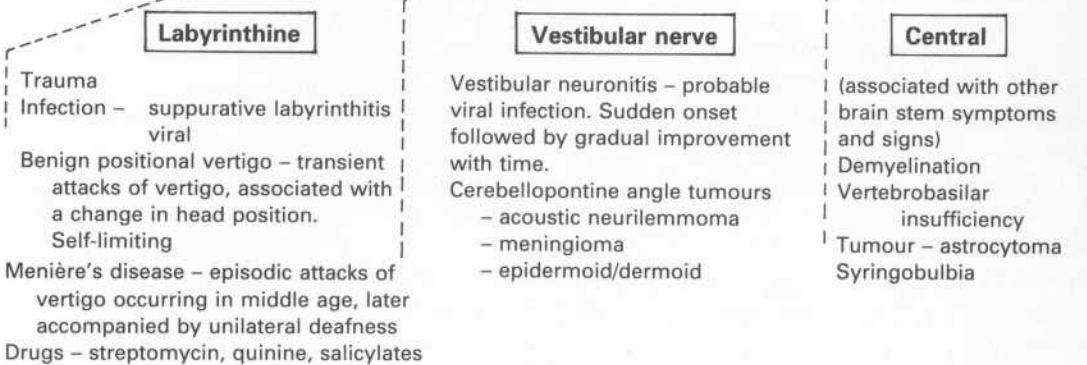
Examination of the external auditory meatus, tympanic membrane and eye movements (for nystagmus) and Weber's and Rinne's tests (page 16) provide valuable information, but more detailed neuro-otological tests (pages 60, 61) are usually required to determine the exact nature of the auditory or vestibular dysfunction and to locate the lesion site. The results of these tests may indicate the need for further investigation (e.g. CT/MR scan)

Causes of deafness



*Prominent in childhood

Causes of Vertigo:



Causes of tinnitus

Any lesion causing deafness may also cause tinnitus. Occasionally patients perceive a vibratory noise inside the head, transmitted from an arteriovenous malformation or carotid stenosis.

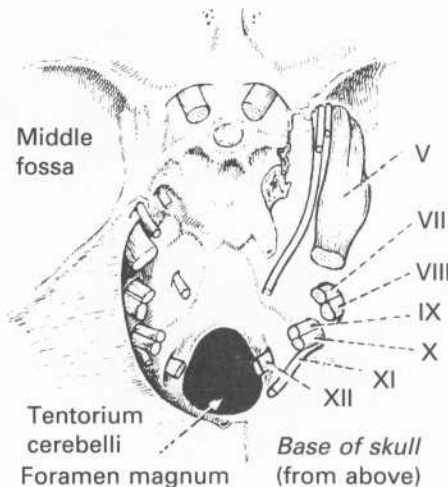
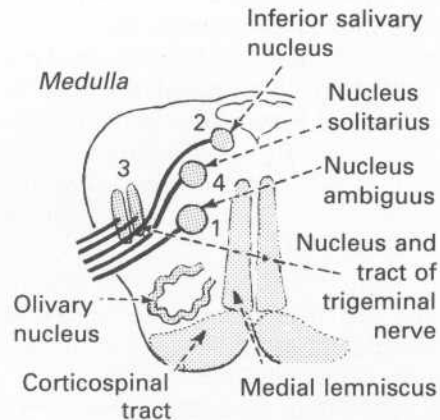
In addition, patients with non-specific disease, e.g. anaemia, fever, hypertension, occasionally complain of tinnitus.

DISORDERS OF THE LOWER CRANIAL NERVES

NINTH (GLOSSOPHARYNGEAL) CRANIAL NERVE

This is a mixed nerve with motor, sensory and parasympathetic functions.

1. Motor fibres to stylopharyngeus muscle arise in the nucleus ambiguus.
2. Preganglionic parasympathetic fibres arise in the inferior salivatory nucleus and pass to the otic ganglion. From there postganglionic fibres innervate the parotid gland.
3. General somatic sensory fibres innervate the area of skin behind the ear, pass to the superior ganglion and end in the nucleus and tract of the trigeminal nerve.
4. Sensory fibres innervate the posterior third of the tongue (taste), pharynx, eustachian tube and carotid body/sinus and terminate centrally in the nucleus solitarius. The cell bodies lie in the inferior ganglion.



The IX nerve emerges as 5 or 6 rootlets from the medulla, dorsal to the olivary nucleus and passes with the vagus and accessory nerves through the jugular foramen in the neck.

Within the neck the nerve lies in close proximity to the internal carotid artery and internal jugular vein.

The superior and inferior ganglia lie in the jugular foramen, the otic ganglion in the neck below the foramen ovale.

Clinical examination (see page 17)

Disorders of the glossopharyngeal nerve

Glossopharyngeal palsy from either medullary or nerve root lesions does not occur in isolation. When associated with X and XI cranial nerve lesions, this constitutes the *jugular foramen syndrome*. Lesions producing this syndrome are listed on page 175.

GLOSSOPHARYNGEAL NEURALGIA

Short, sharp, lancinating attacks of pain, identical to trigeminal neuralgia in nature but affecting the posterior part of the pharynx or tonsillar area. The pain often radiates towards the ear and is triggered by swallowing. Reflex bradycardia and syncope occur due to stimulation of vagal nuclei by discharges from glossopharyngeal. As with trigeminal neuralgia, carbamazepine often provides effective relief – if not microvascular decompression or section of the IX nerve roots or nerve give good results.

DISORDERS OF THE LOWER CRANIAL NERVES

TENTH (VAGUS) CRANIAL NERVE

This is a mixed nerve with motor, sensory and parasympathetic functions.

The central connections are complex though similar to those of the glossopharyngeal nerve.

1. Motor fibres supplying the pharynx, soft palate and larynx arise in the nucleus ambiguus.

2. Preganglionic parasympathetic fibres arise in the dorsal motor nucleus. Postganglionic fibres supply the thoracic and abdominal viscera.

3. Afferent fibres from the pharynx, larynx and external auditory meatus have cell bodies in the jugular ganglion and end in the nucleus and tract of the trigeminal nerve.

4. Afferent fibres from abdominal and thoracic viscera have cell bodies in the nodose ganglion and end in the nucleus solitarius. Taste perception in the pharynx ends similarly.

The nerve emerges from the brain stem as a series of converging rootlets. It exits from the cranial cavity by the jugular foramen where both ganglia lie.

Extracranial branches:

- Motor and sensory supply to the pharynx
- Superior laryngeal branch to the laryngeal muscles
- Recurrent laryngeal branch
- Supply to thoracic and abdominal viscera

Disorders of the vagus nerve cause:

Palatal weakness

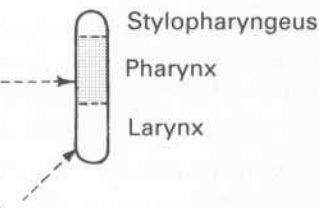
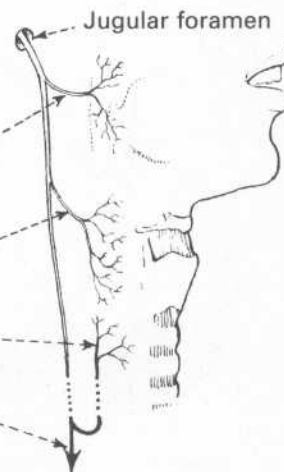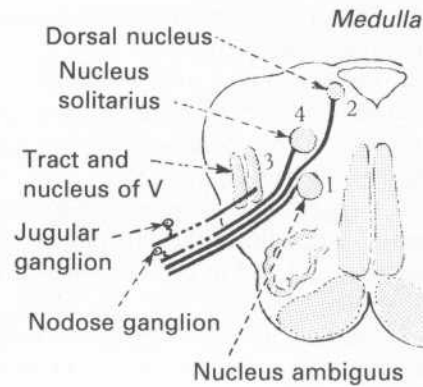
- Unilateral – minimal symptoms.
- Bilateral – nasal regurgitation of fluid, nasal quality of speech.

Pharyngeal weakness

- Pharyngeal muscles are represented by the middle part of the nucleus ambiguus.
- Unilateral – pharyngeal wall droops on the affected side.
- Bilateral – marked dysphagia.

Laryngeal weakness

- Motor fibres arise in the lowest part of the nucleus ambiguus.
- Fibres to *tensors of the vocal cords* pass in *superior laryngeal nerves*.
- Fibres to *adductors and abductors of the vocal cords* are supplied by the *recurrent laryngeal nerves*.

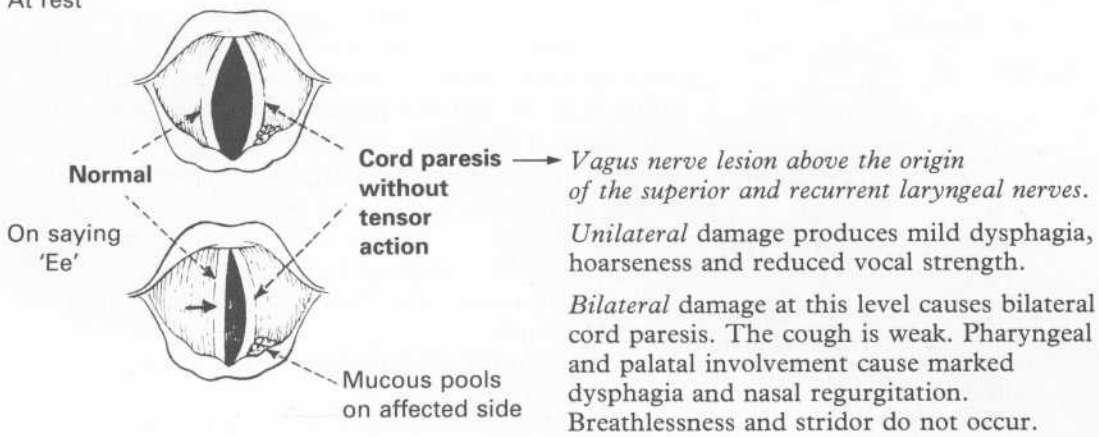


DISORDERS OF THE LOWER CRANIAL NERVES

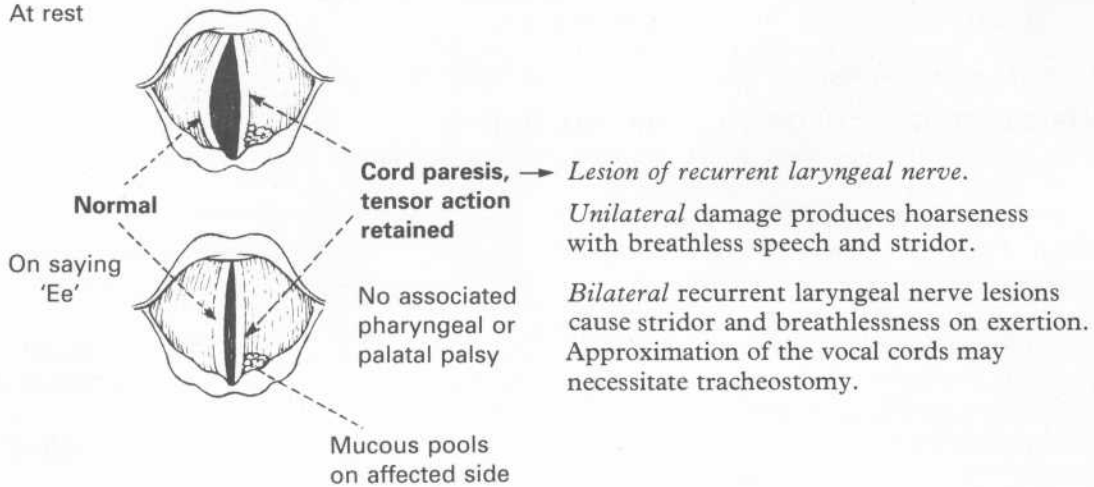
Clinical examination (see page 17)

Direct examination of the vocal cords helps identification of the lesion site.

At rest



At rest

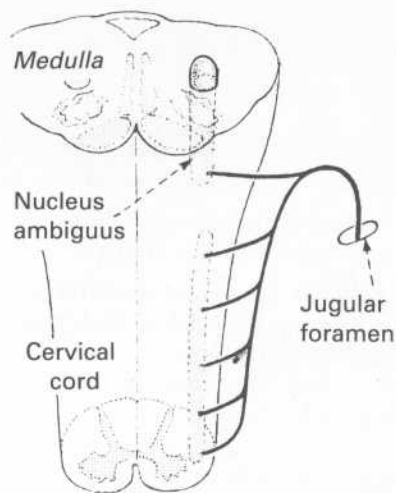


Causes (See page 175)

DISORDERS OF THE LOWER CRANIAL NERVES

ELEVENTH (ACCESSORY) CRANIAL NERVE

This is a purely motor nerve supplying the sternomastoid and trapezius muscles.



The cranial portion of the accessory nerve arises from the lowest part of the nucleus ambiguus in the medulla.

The spinal part arises in the ventral grey matter of the upper five cervical segments, ascends alongside the spinal cord and passes through the foramen magnum. After joining with the cranial portion it exits as the accessory nerve through the jugular foramen.

The *supranuclear connections* act on the ipsilateral sternomastoid (turning the head to the contralateral side) and on the contralateral trapezius. This results in:

- head turning away from the relevant hemisphere during a seizure
- head turning towards the relevant hemisphere with cerebral infarction.

Unilateral lower motor neurone weakness produces a lower shoulder on the affected side (trapezius) and weakness in turning the head to the opposite side (sternomastoid).

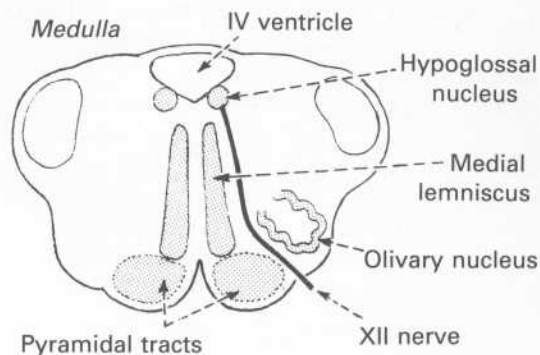
Clinical examination (see page 17) *Causes* (see page 175)

TWELFTH (HYPOGLOSSAL) CRANIAL NERVE

This is a purely motor nerve which supplies the intrinsic muscles of the tongue.

The nucleus lies in the floor of the IV ventricle and fibres pass ventrally to leave the brain stem lateral to the pyramidal tract.

Since each nucleus is bilaterally innervated, a unilateral supranuclear lesion will not produce signs or symptoms. A bilateral supranuclear lesion results in a thin pointed (spastic) tongue which cannot be protruded.



A lesion of the hypoglossal nerve results in atrophy and deviation of the tongue to the weak side

Clinical examination (see page 18) *Causes* (see page 175)

CAUSES OF LOWER CRANIAL NERVE PALSIES

Lower cranial nerve palsies seldom occur in isolation. Investigations include CT or MR imaging of the skull base. If negative, specific tests for systemic causes and EMG (for nerve and muscle disease) may be required.

Skull base/intracranial

- Basal skull tumours –
 - meningioma, neurofibroma, metastasis, epidermoid, nasopharyngeal carcinoma
- Bone lesions –
 - osteomyelitis (in diabetics, consider pseudomonas), chordoma
- Basal meningitis (especially tuberculous)
- Carcinomatous meningitis
- Glomous jugulare tumour (chemodectoma)

Brain stem

- Infarction
- Demyelination
- Motor neuron disease
- Syringobulbia
- Poliomyelitis
- Intrinsic tumours, e.g. astrocytoma

Neck

- Penetrating injury
- Neck operations
- Tumours

Lower cranial nerve syndromes

Jugular foramen syndrome:

lesion involving the IX, X, and XI cranial nerves.

Collet-Sicard syndrome:

lesion (usually extracranial) involving the IX, X, XI and XII cranial nerves.

Villaret's syndrome:

lesion of the retropharyngeal space involving the IX, X, XI and XII cranial nerves and the cervical sympathetic (Horner's syndrome).

Recurrent laryngeal nerve lesions

- Mediastinal disease
- Operative damage
- Aortic aneurysm

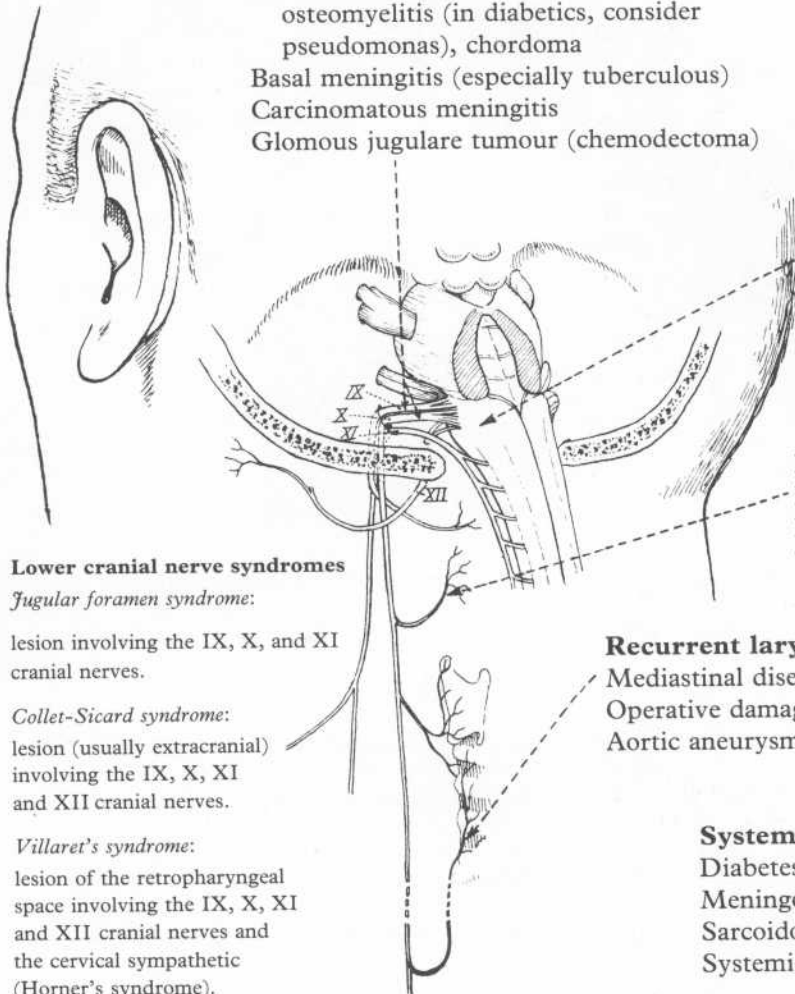
Systemic causes

- Diabetes
- Meningovascular syphilis
- Sarcoidosis
- Systemic lupus erythematosus

Polyneuritis cranialis

Multiple cranial nerve palsies of unknown aetiology which spontaneously remit. The diagnosis is dependent upon exclusion of other possible causes. Occasionally it occurs in association with or as a variant of postinfectious polyneuropathy.

Myasthenia gravis may present with a weakness of the bulbar musculature (see page 464).

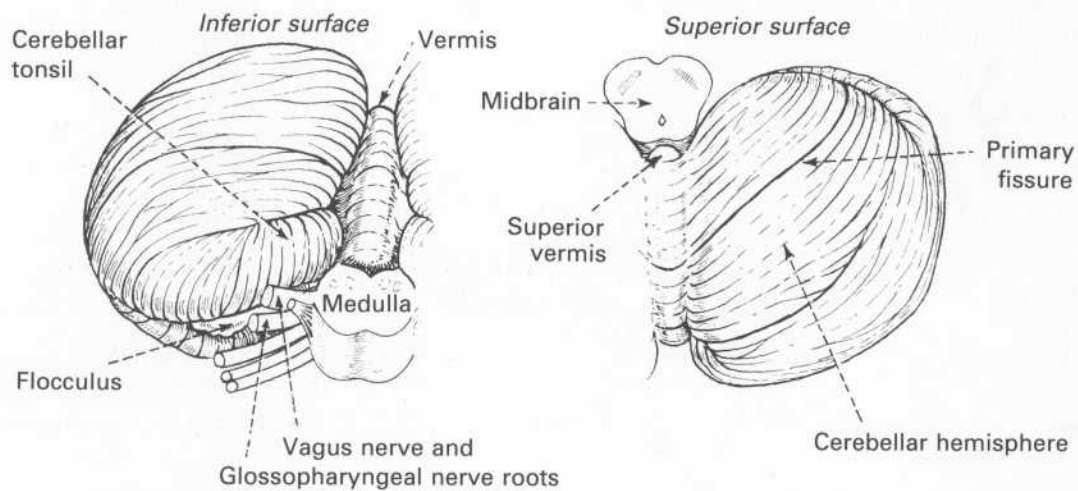
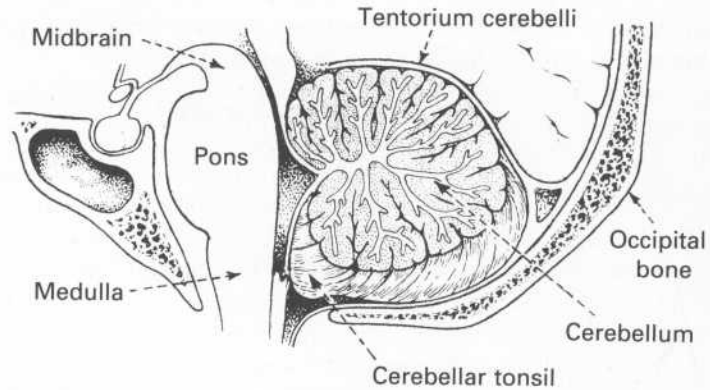


CEREBELLAR DYSFUNCTION

Anatomy

The cerebellum lies in the posterior fossa, posterior to the brain stem, separated from the cerebrum above by the tentorium cerebelli.

The cerebellum consists of two laterally placed hemispheres and the midline structure – the vermis.



Three major phylogenetic subdivisions of the cerebellum are recognised.

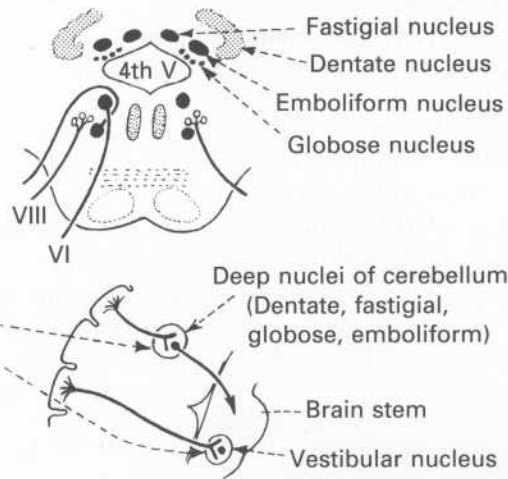
- | | | |
|-------------------------------------------------------|--|--------------------------------------------------------------------------------------------------------------------------------------------------------------------------------------------------------------------|
| <p>1. The anterior lobe (paleocerebellum)</p> | | <p>Receives afferent fibres from (spinocerebellar pathways) in the spinal cord
<i>Function:</i> maintenance of gait.</p> |
| <p>2. The posterior lobe (neocerebellum)</p> | | <p>Receives afferent fibres and projects efferent fibres from and to motor cortex/vestibular nuclei, basal ganglia and pons.
<i>Function:</i> maintenance of postural tone and modulation of motor skills.</p> |
| <p>3. The flocculonodular lobe; (archicerebellum)</p> | | <p>Receives afferent fibres from vestibular system.
<i>Function:</i> maintenance of balance.</p> |

CEREBELLAR DYSFUNCTION

The cerebellar cortex is made up of three cell layers. The middle or Purkinje layer contains Purkinje cells. These are the only neurons capable of transmitting efferent impulses. Deep within the cerebellar hemispheres in the roof of the 4th ventricle, lie four paired nuclei separated by white matter from the cortex.

The efferent system

The Purkinje cells give rise to all efferent axons. These pass either to the deep nuclei of the cerebellum and thence to the brain stem, or to the vestibular nuclei of the brain stem. From there fibres relay back to the cerebral cortex and thalamus, or project into the spinal cord, influencing motor control.



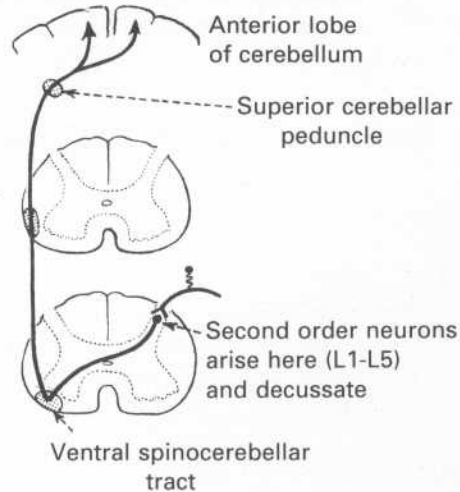
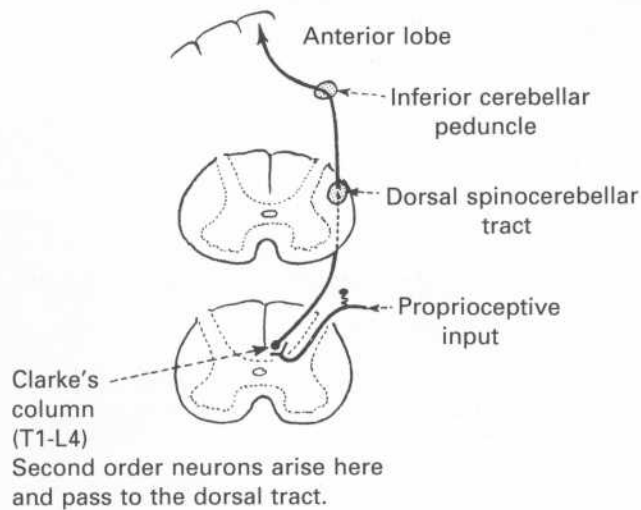
The afferent system

Connections between the vestibular system and the cerebellum are described on page 169.

The spinocerebellar pathways form a major afferent input. These transmit 'subconscious' proprioception from muscles, joints and skin – especially of the lower limbs.

THE DORSAL SPINOCEREBELLAR TRACT

THE VENTRAL SPINOCEREBELLAR TRACT



The cerebellar peduncles: Three peduncles connect the cerebellum to the brain stem:

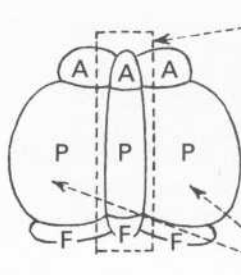
Superior peduncle – afferent and efferent fibres.

Middle peduncle – afferent fibres only.

Inferior peduncle – afferent and efferent fibres.

SYMPTOMS AND SIGNS OF CEREBELLAR DYSFUNCTION

The close relationship of structures within the posterior fossa makes the identification of exclusively cerebellar symptoms and signs difficult. Disease of the brain stem and its connections may produce identical results.



Damage to midline structures

- vermis (and flocculonodular lobe)

Results in: disturbance of equilibrium with unsteadiness on standing, walking and even sitting (truncal ataxia). The patient's gait is broad based and reeling. Eye closure does not affect balance (see Romberg's test). Tests of vestibular function, e.g. calorics, may be impaired.

Damage to hemisphere structures

- always produces signs *ipsilateral to the side of the lesion.*

Results in: a loss of the normal capacity to modulate fine voluntary movements. Errors or inaccuracies cannot be corrected. The patient complains of impaired limb co-ordination and certain signs are recognised:

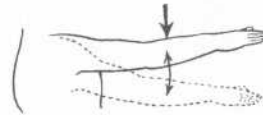
Ataxia of extremities with unsteadiness of gait towards the side of the lesion.

Dysmetria: a breakdown of movement with the patient 'overshooting' the target when performing a specific motor task, e.g. finger-to-nose test.

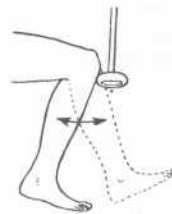
Dysdiadochokinesia: a failure to perform a rapid alternating movement.

Intention tremor: a tremor which increases as the limb approaches its target.

Rebound phenomenon: the outstretched arm swings excessively when displaced.



'Pendular' reflexes: the leg swings backwards and forwards when the knee jerk is elicited.



Eye movements

Nystagmus results from disease affecting cerebellar connections to the vestibular nuclei.

In unilateral disease, amplitude and rate increase when looking towards the diseased side.

Other ocular signs may occur, e.g. ocular dysmetria – an 'overshoot' when the eyes voluntarily fixate.

SYMPTOMS AND SIGNS OF CEREBELLAR DYSFUNCTION

Disturbance of speech

Scanning dysarthria may occur with speech occasionally delivered with sudden unexpected force – *explosive speech*. Whether dysarthria results from hemisphere or midline vermis disease remains debatable.

Dysarthria, like nystagmus, is an inconsistent finding in cerebellar disease.

Titubation

Titubation is a rhythmic 'nodding' tremor of the head from side to side or to and fro, usually associated with distal limb tremor. It appears to be of little localising value.

Head tilt

Abnormal head tilt suggests a lesion of the anterior vermis. Note that a IV (trochlear) cranial nerve palsy and tonsillar herniation also produce this abnormal posture.

Involuntary movements

Myoclonic jerks and choreiform involuntary movements occur with extensive cerebellar disease involving the deep nuclei.

ASSOCIATED NON-CEREBELLAR SIGNS AND SYMPTOMS: These arise from:

- obstructive hydrocephalus
- cranial nerve involvement
- brain stem involvement.

(Extensor spasms from brain stem damage may be wrongly described as 'cerebellar fits'.)

CLASSIFICATION OF CEREBELLAR DYSFUNCTION

The following disorders are dealt with in their specific sections.

Developmental

- agenesis
- Dandy-Walker malformation
- Arnold-Chiari malformations
- Von Hippel Lindau disease.

Demyelinative

- multiple sclerosis.
- acute disseminated encephalomyelitis (ADEM)

Degenerative

- cerebellar degeneration
- multi-system atrophy (MSA)
- olivopontocerebellar atrophy

Neoplastic

- astrocytoma, medulloblastoma, haemangioblastoma, metastasis

Paraneoplastic

- subacute cerebellar degeneration

Infectious

- abscess formation
- acute cerebellitis (viral)
- Creutzfeldt-Jacob disease

Metabolic

- myxoedema
- hypoxia, hypoglycaemia.
- alcohol (vitamin B₁ deficiency)
- inborn disorders of metabolism. (lipid or amino acid metabolism)

Vascular

- cerebellar haemorrhage
- cerebellar infarction.

Drugs/toxins

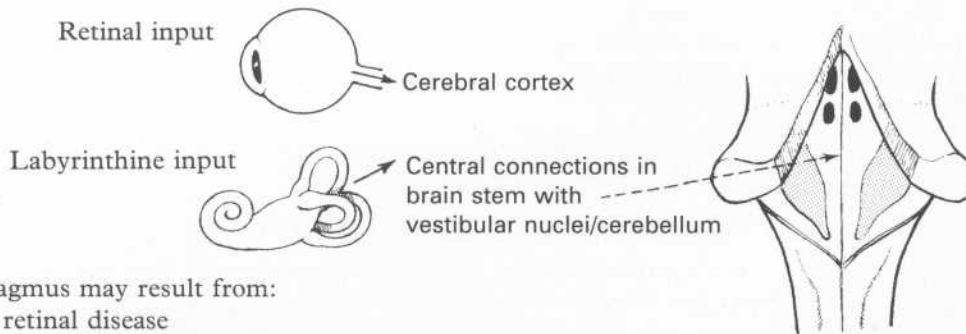
- alcohol
- phenytoin.

NYSTAGMUS

Nystagmus is defined as an involuntary 'to and fro' movement of the eyes in a horizontal, vertical, rotatory or mixed direction. The presence and characteristics of such movements help localise to the site of neurological disease.

Nystagmus may be *pendular* – equal velocity and amplitude in all directions,
 or *jerk* – with a fast phase (specifying the direction) and a slow phase.

The normal maintenance of ocular posture and alignment of the eyes with the environment depends upon:



Nystagmus may result from:

- retinal disease
- labyrinthine disease, or
- disorders affecting the cerebellum or a substantial portion of the brain stem.

Examination for nystagmus

'Nystagmoid' movements of the eyes are present in many people at extremes of gaze. Nystagmus present with the eyes deviated less than 30° from the midline is abnormal.

When nystagmus is present only with the eyes deviated to one side – *1st degree nystagmus*.
 With eyes deviated to one side and in the midline position also – *2nd degree nystagmus*.
 When present in all directions of gaze – *3rd degree nystagmus*.

If nystagmus is detected, note the type (jerk or pendular), direction (of fast phase) and degree.

Nystagmus suppressed by visual fixation may appear in darkness, but this requires specialised techniques (electronystagmography – see page 62) to demonstrate.

RETINAL OR OCULAR nystagmus

Physiological: following moving objects beyond the limits of gaze – opticokinetic nystagmus.

Pathological: occurs when vision is defective. Fixation is impaired and the eyes vainly search.

Nystagmus is:

- Rapid
- Pendular (lacks slow and fast phase)
- Increased when looking to sides
- Persistent throughout lifetime

NYSTAGMUS

VESTIBULAR nystagmus

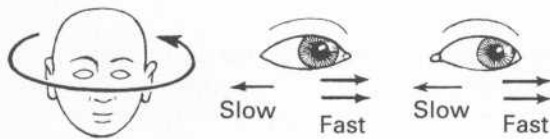
Nystagmus arises from:

- natural stimulation of the vestibular apparatus – rotational or linear acceleration.
- artificially removing or increasing the stimulus from one labyrinth (e.g. caloric testing).
- damage to vestibular apparatus or the vestibular nerve.

Creates an imbalance between each side resulting in a slow drift of the eyes towards the damaged side (or side with the reduction in stimulus) followed by a fast compensatory movement to the opposite side.

Physiological

- (i) Rotational acceleration produces nystagmus in the plane of rotation.

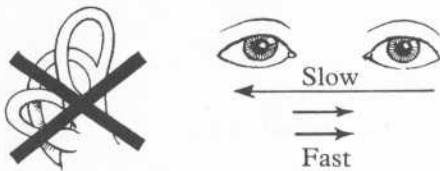


Slow phase in a direction tending to maintain the visual image.
Fast phase in the opposite direction.

- (ii) Caloric testing sets up convection currents in the lateral semicircular canal producing a horizontal nystagmus (see page 62).

Pathological

Damage to labyrinth or vestibular nerve.

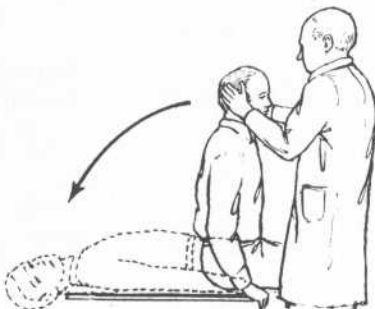


Often associated with tinnitus and hearing loss. Vertigo and nystagmus settle simultaneously.

Occurs in acute labyrinthine disease – *Menière's disease*, *vestibular neuronitis*, *vascular disease*.

Slow phase to side of lesion.
Quick or fast phase to normal side.
Rotatory component often present.
Turning eyes away from the side of the lesion increases amplitude but does not change direction of nystagmus.
In severe cases, the nystagmus is 3rd degree and gradually settles to 1st degree with recovery.
Enhanced by loss of ocular fixation.
Vertigo accompanies nystagmus.

POSITIONAL nystagmus: this may occur in labyrinthine disease in association with vertigo when the patient assumes a certain posture.



To elicit, suddenly reposition the patient:

After a delay of several seconds, nystagmus develops often with a rotatory component. With repeated testing, the nystagmus fatigues.

NYSTAGMUS

CENTRAL NERVOUS SYSTEM nystagmus

Central nystagmus arises from damage to the central vestibular connections in the vestibular nuclei and brain stem. The nystagmus may be horizontal, vertical, rotatory or dissociated (present in one eye only).

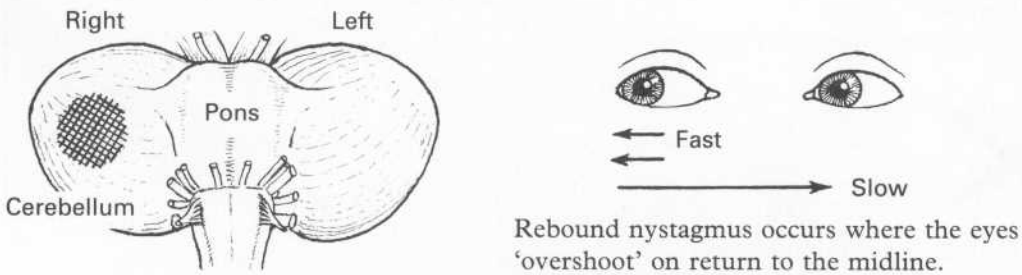
The direction (fast phase) is determined by direction of gaze (multidirectional).
Vertigo is seldom present.
Signs of other nuclear or tract involvement in brain stem should be evident.

Central nystagmus occurs in *vascular disease, demyelination, neoplasms, nutritional disease (Wernicke's encephalopathy), alcohol intoxication and drug toxicity, e.g. phenytoin.*

Posterior fossa lesions may produce *positional nystagmus*. This may be distinguished from labyrinthine disease by:

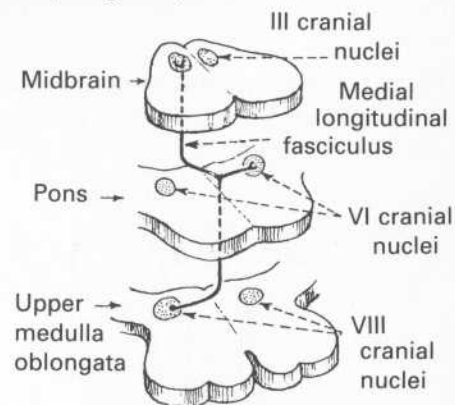
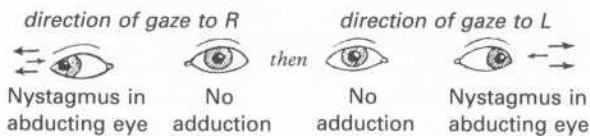
Absence of delay before onset, lack of fatiguing with repetitive testing, and a tendency to occur with any rather than one specific head movement.

Although nystagmus often occurs in cerebellar disease, the role of the cerebellum in its production remains unclear. *The fast phase tends to occur to the side of the cerebellar damage (i.e. the opposite of labyrinthine disease).*



INTERNUCLEAR OPHTHALMOPLEGIA (Ataxic nystagmus)

The median longitudinal fasciculus links, among other structures, the innervation of the lateral rectus with the contralateral medial rectus muscle in order to coordinate horizontal gaze. A lesion of this fasciculus will cause *dissociate nystagmus*.



Eyes no longer move as one and nystagmus is present in one eye but not the other.

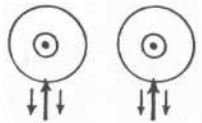
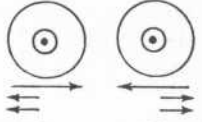

NYSTAGMUS

In unilateral medial longitudinal fasciculus lesions the eye fails to adduct towards the affected side.

N.B. Internuclear ophthalmoplegia differs from a bilateral III nerve or nuclear lesion in that the pupil is not affected and when testing eye movements individually, some adduction occurs.

The disorder characteristically occurs in multiple sclerosis but also in brainstem infarction, haemorrhage, trauma, syringobulbia and drug toxicity (phenytoin).

OTHER VARIETIES OF CENTRAL NERVOUS SYSTEM NYSTAGMUS

1. **Downbeat nystagmus**  Occurs with lesions around the aqueduct of Sylvius or cervicomedullary junction. Fast phase is downwards (downbeating nystagmus).
2. **Convergence nystagmus**  Occurs with lesions in upper midbrain region.
3. **See-saw nystagmus**  One eye intorts and moves up while the other extorts and moves down. Occurs with sellar or parasellar mass lesion.

A group of confusing terms are used to describe abnormal, involuntary eye movements seen in cerebellar/brain stem disease:

Ocular bobbing – fast drift downwards, slow drift upwards; seen with large pontine lesions. (Horizontal eye movements are absent.)

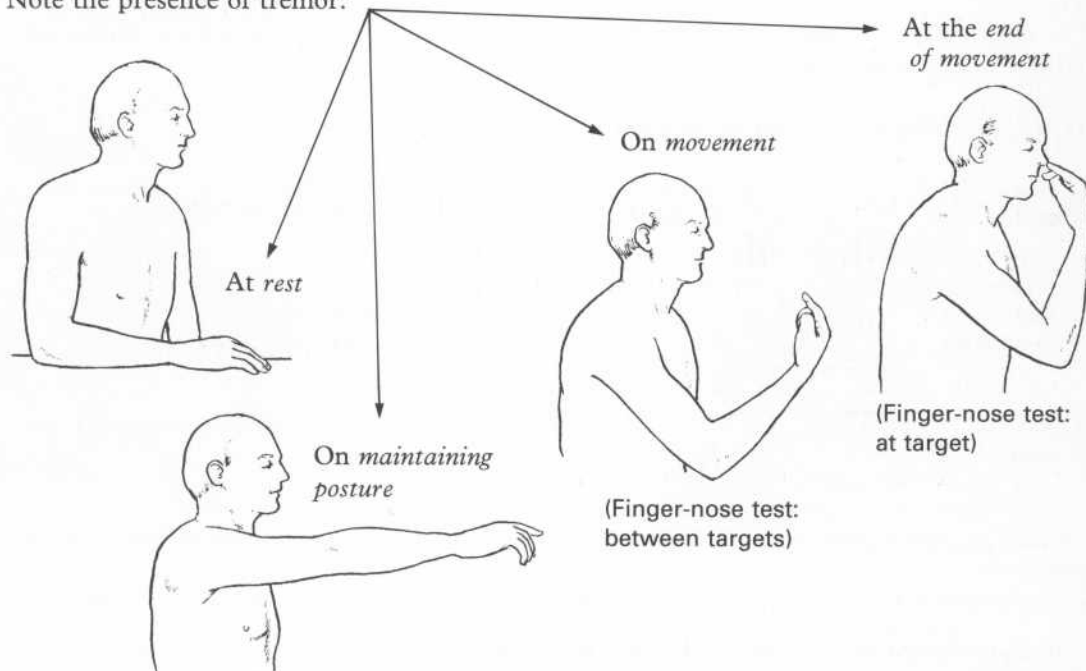
Opsoclonus – rapid conjugate jerks of eyes; made worse by head movement. The eye movements are random.

Oscillopsia is a term used to describe the patient's awareness of jumping of the environment as a consequence of rapid jerking eye movements.

TREMOR

Tremor is a rhythmic involuntary movement normally affecting the limbs. Diagnosis depends on examination of the character of the tremor as well as the presence of other specific features.

Note the presence of tremor:



Observe:

- the *rate* (slow, 4–6 Hz), (rapid, 6–12 Hz)
- the *amplitude* (fine or coarse)
- the *distribution*: head, trunk or limbs (distal or proximal)
- *associated features* e.g disorder of gait or balance

Most tremors disappear during sleep.

Physiological tremor is evident on maintaining a fixed posture, fast in rate (8–12 Hz), fine in character, distal in distribution and non-disabling. It is enhanced by fatigue, anxiety and drugs e.g. caffeine, steroids.

Pathological tremor occurs at rest or with movement, slow in rate, coarse in character, proximal or distal and often asymmetrical in distribution. This tremor is socially and physically disabling.

TREMOR

CHARACTERISTICS OF PATHOLOGICAL TREMOR

Tremor at rest

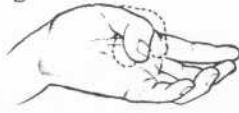'Pill-rolling' tremor, decreasing with movement.

Rate: 3-7 per second.

Amplitude: coarse.

Distribution: distal limbs.

Usually associated with bradykinesia and rigidity.



PARKINSON'S DISEASE
OR DRUG INDUCED
PARKINSONISM

Tremor on maintaining posture and throughout range of movement

Tremor absent at rest, when the limb is relaxed, but present on maintaining a fixed posture and during movement.

Rate: 6-12 Hz

amplitude: fine

Slow insidious onset

Distribution:

Upper limbs involved, lower limbs rarely.

Titubation (tremor of the head on the trunk) often present.

POSTURAL TREMOR.

Specific types of postural tremor are recognised

FAMILIAL TREMOR – often Mendelian dominant.

ESSENTIAL TREMOR – no family history.

SENILE TREMOR – develops in old age.

The tremor may progress until handwriting becomes impossible and feeding difficult. Alcohol may temporarily abort the tremor; beta blockers may produce an improvement.

Tremor during and maximal at the end of movement

Tremor absent at rest; present during movement and maximal on approaching target, e.g. finger-nose test.

Rate: 4-6 per second.

Amplitude: coarse.

Distribution: Proximal and distal.

Titubation may occur.

Usually associated with other cerebellar signs

CEREBELLAR TREMOR
(‘intention tremor’)

Extremely severe tremor – sufficient to interrupt movement and throw patient off balance.



MIDBRAIN TREMOR
due to disease involving the
cerebellar/red nucleus connections,
e.g. *multiple sclerosis*.

MYOCLONUS

Myoclonus is a shock-like contraction of muscles which occur irregularly and asymmetrically. Such jerks occur repetitively in the same muscle groups and range from a flicker in a single muscle to contraction in a group of muscles sufficient to displace the affected limb.

Pathophysiology

The precise nature of myoclonus remains unclear. Several forms exist, some clearly related to epilepsy; others may be associated with damage to inhibitory mechanisms in the brainstem reticular formation. Myoclonus may result from pathological changes affecting a variety of different sites including the motor cortex, cerebellum and spinal cord.

Clinical features

Myoclonic movements when repetitive vary in frequency between 5–60/minute. The muscles of the face, oral cavity and limbs are preferentially affected. The movements may be accentuated or precipitated by visual, auditory or tactile stimulation. Repetitive stimulation may result in a crescendo of myoclonus which resembles a seizure.

Physiological myoclonus occurs in sleep (hypnic jerks), with anxiety and in infants when feeding.

Causes

Myoclonus occurs in many rare conditions of the nervous system. Four groups of disorder are recognised:

<i>Progressive myoclonus</i>	<i>Metabolic disease associated</i>	<i>Miscellaneous disorders</i>
Familial disorders:	<i>with transient myoclonus</i>	– Cerebral anoxia
– Lafora body disease	– Hyponatraemia	– Vasculitides
– Tay Sach's disease	– Hypocalcaemia	– Sarcoidosis
– Gaucher's disease	– Renal, hypoxic, hepatic	– Paraneoplastic disease
– Ramsay Hunt syndrome	encephalopathy	– Mitochondrial disease
– Benign polymyoclonus	– Non ketotic hyperglycaemia	– HIV encephalopathy
	– Hypoglycaemia	– Whipple's disease
<i>Degenerative disease:</i>	<i>Epileptic disorders in which myoclonus occurs</i>	
– Subacute sclerosing	Generalised seizures: – associated with petit mal	
panencephalitis	– during prodrome of grand mal	
– Alzheimer's disease	– photosensitive myoclonus	
– Pick's disease	Juvenile myoclonic epilepsy	
– Diffuse Lewy body disease	Lennox Gastaut syndrome (atypical petit mal, drop attacks	
– Huntington's disease	and mental retardation)	
– Prion disease	West's syndrome	
– Creutzfeldt-Jacob disease		

Palatal myoclonus – an unusual myoclonic disorder with rapid regular movements of the soft palate and occasionally of the pharyngeal and facial musculature. Palatal movements occur at a rate of 120–140/minute. This disorder is associated with degenerative changes in the olivary and dentate nuclei.

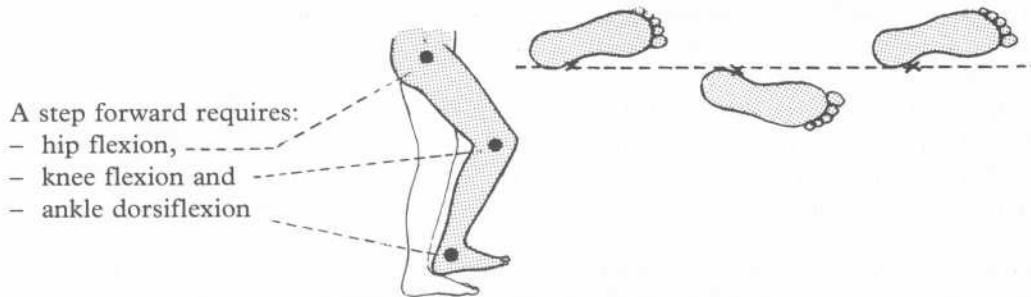
Treatment

Benzodiazepine drugs such as clomazepam may suppress myoclonic movements. Piracetam (G.A.B.A. analogue) and levodopa or dopamine agonists are also used.

An exaggerated startle response can be confused with myoclonus. This is often physiological but can be disabling – *hypereplexia* (Startle disease).

DISORDERS OF STANCE AND GAIT

The normal gait is characterised by an erect posture, moderately sized steps and the medial malleoli of the tibia 'tracing' a straight line.



- A step forward requires:
- hip flexion,
 - knee flexion and
 - ankle dorsiflexion

Co-ordination ensures fluidity of movement.

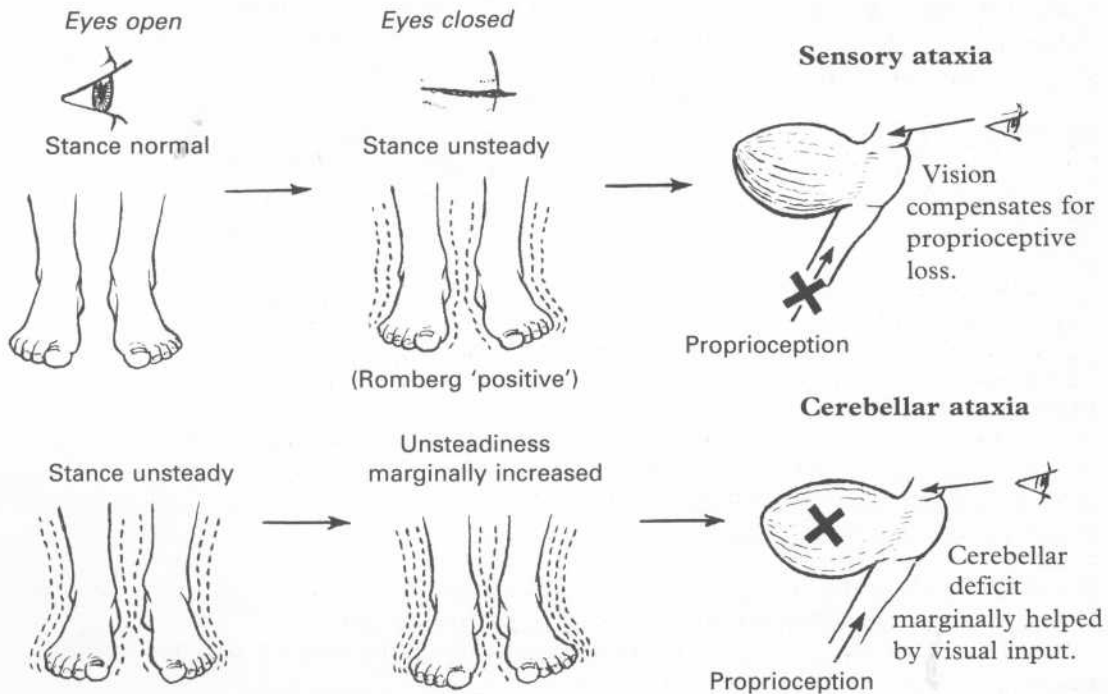
Antigravity reflexes maintain the erect posture. They depend upon spinal cord and brain stem connections to produce extension.

ASSESSMENT OF STANCE AND GAIT

In a patient complaining of disturbance of walking, careful assessment indicates the likely site of the causative lesion.

Watch the patient:

- walking
- performing *tandem gait* - heel to toe walking,
- standing with heels together with (a) eyes open, (b) eyes closed - this (Romberg's test) distinguishes cerebellar from sensory ataxia.

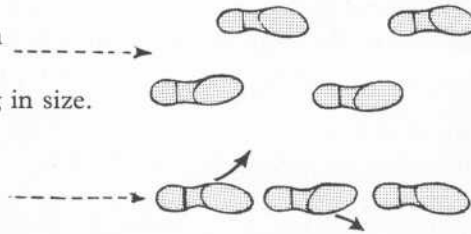


SPECIFIC DISORDERS OF STANCE AND GAIT

ATAXIC GAIT

- 1. Cerebellar** The feet are separated widely when standing or walking. Steps are jerky and unsure, varying in size. The trunk sways forwards.

In mild cases: Tandem gait (heel-toe walking) is impaired; the patient falling to one or both sides.



2. Sensory

Disturbed conscious or unconscious proprioception due to interruption of afferents in peripheral nerves or spinal cord (posterior columns, spinocerebellar tracts).

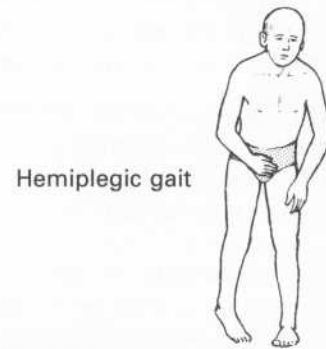The gait appears normal when the eyes are open although the feet usually 'stamp' on the ground. Examination reveals a positive Romberg's test and impaired joint position sensation.

HEMIPLEGIC GAIT

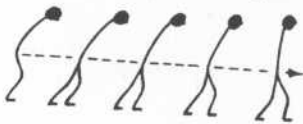
The leg is extended and the toes forced downwards. When walking, abduction and circumduction at the hip prevent the toes from catching on the ground.

In paraplegia, strong adduction at the hips can produce a scissor-like posture of the lower limbs.

In mild weakness, the gait may appear normal, but excessive wear occurs at the outer front aspect of the patient's shoe sole.



PARKINSONIAN (festinating) GAIT

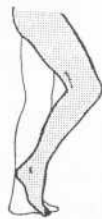

The patient adopts a flexed, stooping posture. To initiate walking, he leans forwards and then hurries (festinates) to 'catch up' on himself. The steps are short and shuffling.

STEPPAGE GAIT

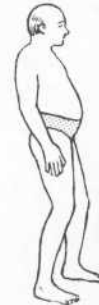Lower motor neuron weakness of pretibial and peroneal muscles produces this gait disorder. The patient lifts the affected leg high so that the toes clear the ground.

When bilateral, it resembles a high-stepping horse.



MYOPATHIC (waddling) GAIT

Characteristic of muscle disease. Trunk and pelvic muscle weakness result in a sway-back, pot-bellied appearance with difficulty in pelvic 'fixation' when walking.



FRONTAL LOBE GAIT

Disturbance of connections between frontal cortex, basal ganglia and cerebellum produces this characteristic disturbance. The gait is wide based (feet wide apart). Initiation is difficult, the feet often seem 'stuck' to the floor. There is a tendency to fall backwards. Power and sensation are normal.

HYSTERICAL GAIT

Characterised by its bizarre nature.

Numerous variations are seen. The hallmark is inconsistency supported by the lack of neurological signs. Close observation is essential.

LIMB WEAKNESS

Limb weakness results from damage to the **motor system** at any level from the motor cortex to muscle.

UPPER MOTOR NEURON WEAKNESS

MUSCLE TONE

Hypertonicity develops after a period (a few days or weeks) of 'neural shock'. Passive movements produce a 'clasp knife' quality, i.e. sudden 'give' towards the end of movement.

Clonus – present.

MUSCLE FASCICULATION

Absent.

MUSCLE WASTING

Absent – but, in the long term, disuse atrophy results.

REFLEXES

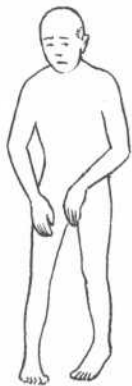- **Tendon** – exaggerated.
- **Superficial** – depressed or absent (abdominal, cremasteric).
- **Plantar response** – extensor.

DISTRIBUTION

In general, whole limb or limbs are involved, e.g. monoplegia, hemiplegia, paraplegia.

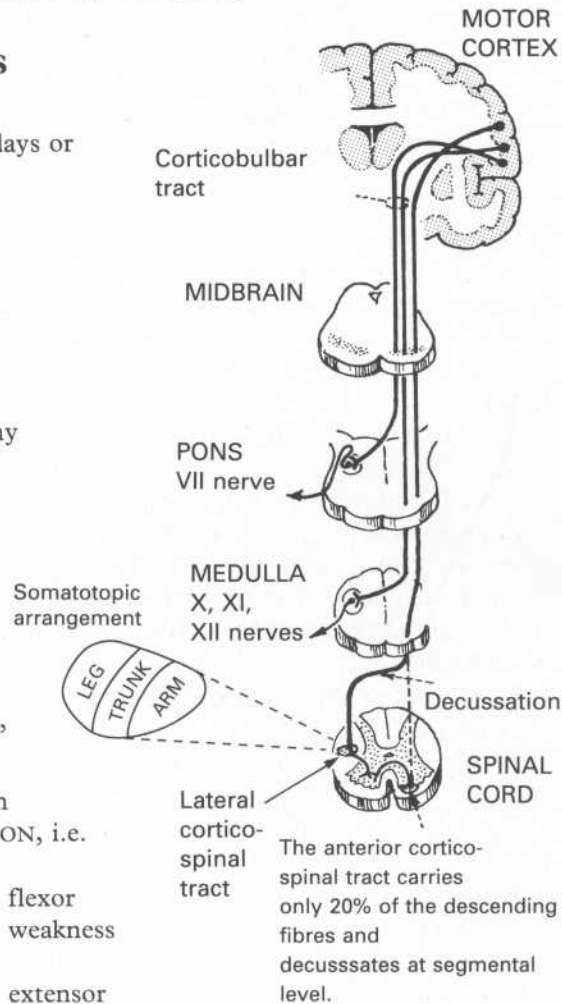
Weakness shows a **PREDILECTION** for certain muscle groups in a **PYRAMIDAL DISTRIBUTION**, i.e.

upper limbs –	extensor weakness	>	flexor weakness
lower limbs –	flexor weakness	>	extensor weakness

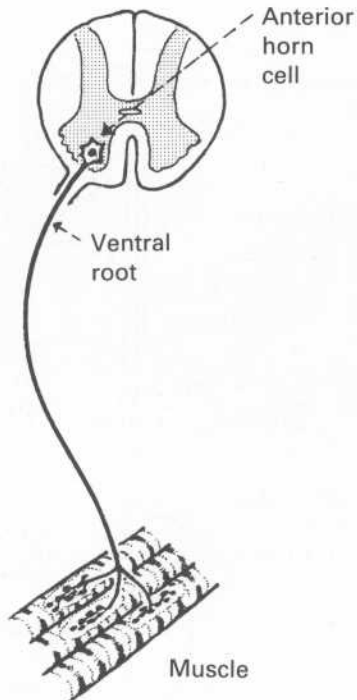


This results in the '*spastic*' posture with the arm and the wrist flexed and the leg extended. In upper motor neuron lesions, **SKILLED** movements, e.g. fastening buttons, are always more affected than unskilled movements.

N.B. *Dual innervation* from each hemisphere results in sparing of the upper face, muscles of mastication, the palate and tongue with a unilateral upper motor neuron lesion.



LIMB WEAKNESS



LOWER MOTOR NEURON WEAKNESS

MUSCLE TONE

Hypotonicity with diminished resistance to passive stretch.
Clonus – absent.

MUSCLE FASCICULATION

Present – irregular, non-rhythmical contractions of groups of motor units. More prevalent in anterior horn cell disease than in nerve root damage.

MUSCLE WASTING

Wasting becomes evident in the paretic muscle within 2–3 weeks of the onset.

REFLEXES

- **Tendon** – depressed or absent.
- **Superficial** – rarely affected (abdominal, cremasteric).
- **Plantar response** – flexor.

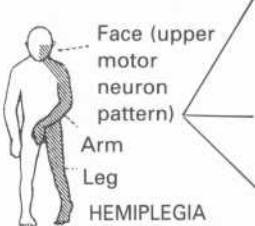
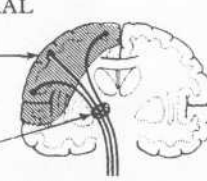
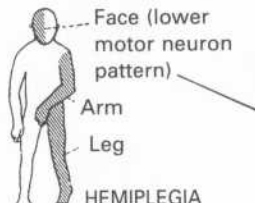

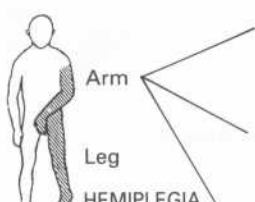

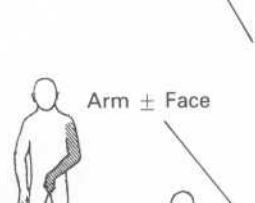

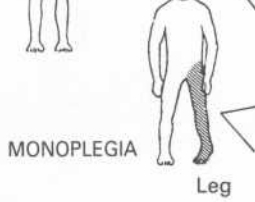
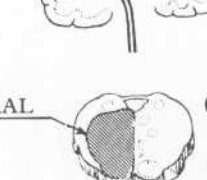





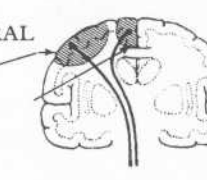

DISTRIBUTION

Either – muscle groups involved in distribution of a spinal segment/root, plexus or peripheral nerve,
or – generalised limb involvement affecting proximal or distal muscles or following a specific distribution, e.g. facioscapulohumeral dystrophy.

LIMB WEAKNESS

LESION LOCALISATION

The foregoing clinical features readily distinguish weakness of an upper motor neuron, lower motor neuron or mixed pattern. Combining these findings with other neurological signs enables localisation of the lesion site.

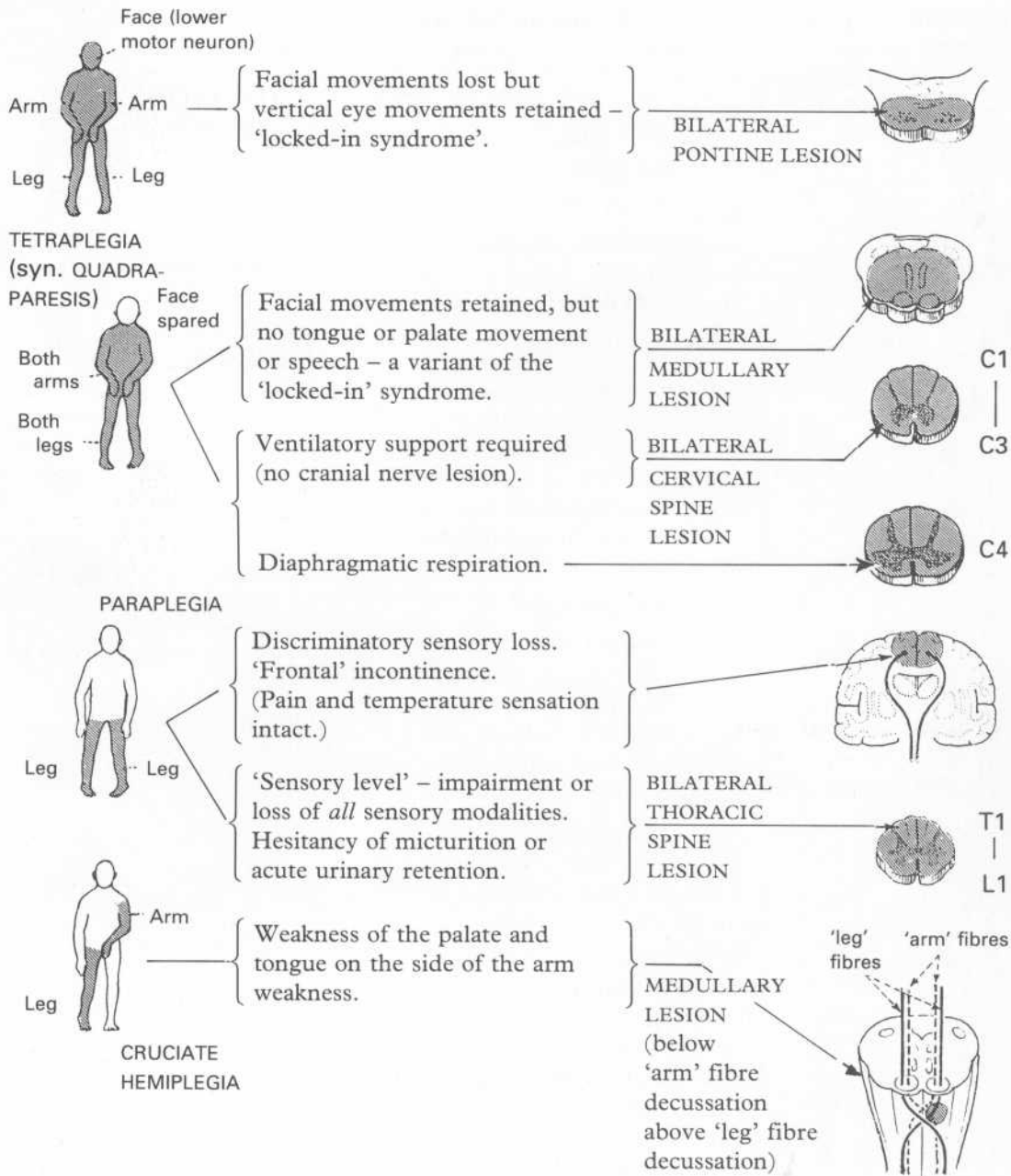
UPPER MOTOR NEURON LIMB WEAKNESS - UNILATERAL	Useful localising features (not always present)	Lesion site
	<ul style="list-style-type: none"> Impairment of conscious level. Visual field deficit. Dysphasia (if dominant hemisphere). 	<ul style="list-style-type: none"> CONTRALATERAL HEMISPHERE LESION 
	<ul style="list-style-type: none"> Alert. No dysphasia (if dominant hemisphere). Visual field deficit rare. 	<ul style="list-style-type: none"> CONTRA-LATERAL INTERNAL CAPSULE LESION 
	<ul style="list-style-type: none"> Contralateral III nerve palsy. 	<ul style="list-style-type: none"> CONTRALATERAL MIDBRAIN LESION 
	<ul style="list-style-type: none"> Conjugate gaze deviation towards the weak limbs (impaired movement towards the 'normal' limb). Lower motor neuron facial weakness on side opposite the weak limbs. 	<ul style="list-style-type: none"> CONTRALATERAL PONTINE LESION 
	<ul style="list-style-type: none"> Visual field deficit. Discriminatory sensory deficit. 	<ul style="list-style-type: none"> CONTRA-LATERAL CORTEX LESION 
	<ul style="list-style-type: none"> Pain and temperature loss on the same side as the weakness and a Horner's syndrome and weak palate and tongue on the opposite side. 	<ul style="list-style-type: none"> CONTRALATERAL MEDULLARY LESION 
	<ul style="list-style-type: none"> Pain and temperature loss on the opposite side to the limb weakness and a Horner's syndrome and proprioception loss on the same side. 	<ul style="list-style-type: none"> IPSILATERAL SPINAL LESION 
	<ul style="list-style-type: none"> Visual field deficit. Dysphasia (if dominant hemisphere). Discriminatory sensory deficit. Discriminatory sensory deficit. Pain and temperature loss in the opposite leg, proprioception loss on the same side. 	<ul style="list-style-type: none"> CONTRALATERAL CORTEX LESION 
		<ul style="list-style-type: none"> IPSILATERAL SPINAL LESION 

LIMB WEAKNESS

UPPER MOTOR NEURON LIMB WEAKNESS - BILATERAL

Useful localising features (not always present)

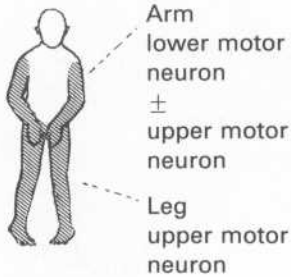
Lesion site



LIMB WEAKNESS

MIXED UPPER AND LOWER MOTOR NEURON WEAKNESS - UNILATERAL OR BILATERAL

Useful localising features
(not always present)

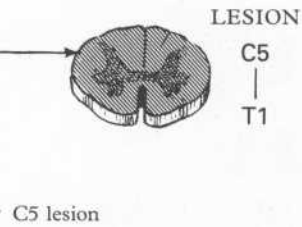


Arm
lower motor neuron
±
upper motor neuron

Leg
upper motor neuron

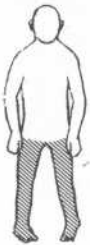{ Lower motor neuron lesion identifies the level of segmental cord damage,
e.g. weak arm abductors, weak elbow flexors, reduced biceps jerk, } C5 lower motor neuron lesion

weak elbow extension, increased triceps jerk, } C7 level upper motor neuron lesion



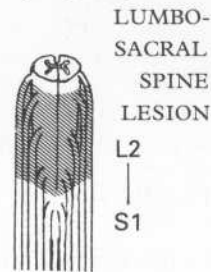
C5 lesion

but note that wasting of the small hand muscles (T1) may accompany cervical lesions at any level.



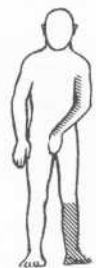Leg
lower motor neuron
+
upper motor neuron

{ Upper motor neuron signs are important in detecting level of cord damage (since lower motor neuron signs may result from either segmental damage or root damage from a higher level). }



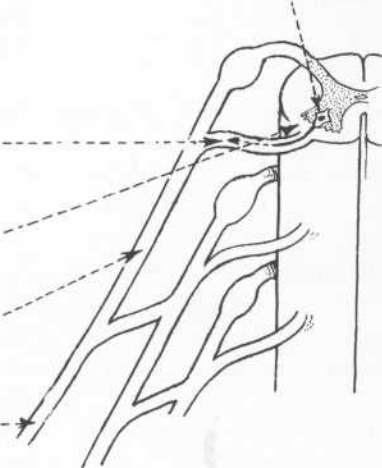
N.B. Dual lesions, e.g. cervical + lumbar spondylosis may cause mixed (umn and lmn) signs in both arm and leg.

LOWER MOTOR NEURON LIMB WEAKNESS - UNILATERAL OR BILATERAL



Note the muscle groups involved and the area of sensory impairment (if present).
Does this fit the distribution of
- one or more NERVE ROOTS (pages 20-25)
root distribution without sensory deficit
- the BRACHIAL PLEXUS (page 430)
- the LUMBOSACRAL PLEXUS (page 438)
- a PERIPHERAL NERVE (page 433-436, 438-440).

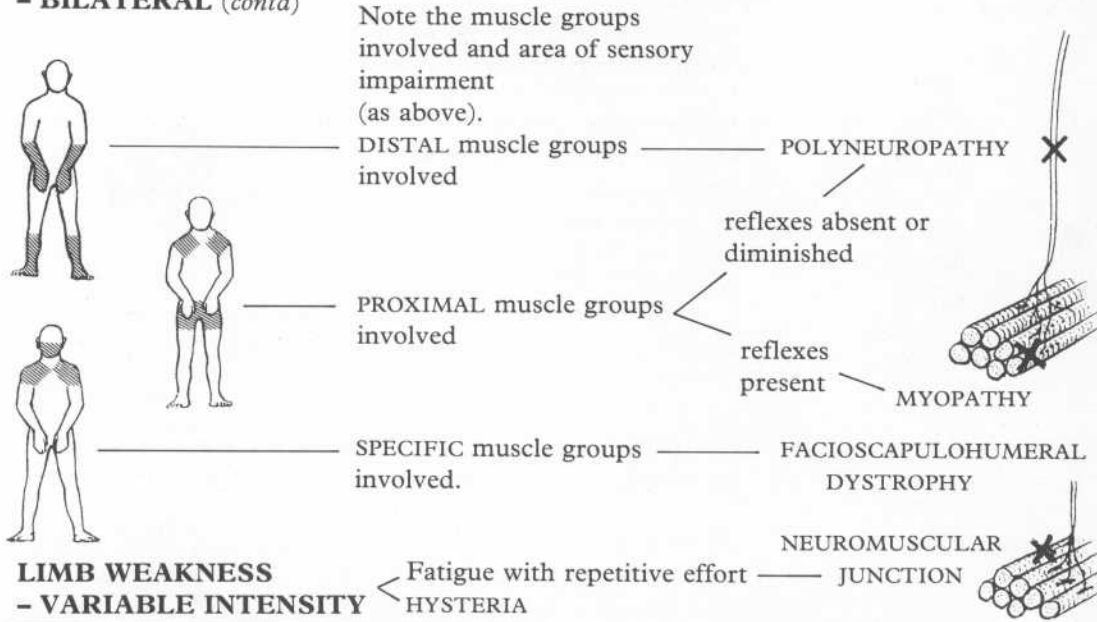
Anterior horn cell



LIMB WEAKNESS

LOWER MOTOR NEURON LIMB WEAKNESS

- BILATERAL (contd)



LIMB WEAKNESS - VARIABLE INTENSITY

LESION SITE

DIFFERENTIAL DIAGNOSIS

PRELIMINARY INVESTIGATIONS

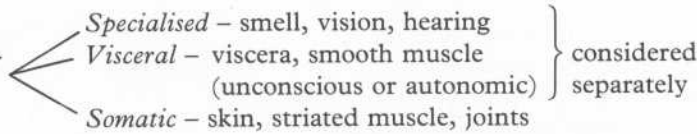
Cerebral hemispheres, midbrain, pons, medulla	<ul style="list-style-type: none"> Vascular Tumour Infection 	CT scan/MRI
Spinal cord	<ul style="list-style-type: none"> Demyelination Spondylosis/disc disease Tumour Infection Vascular 	<ul style="list-style-type: none"> MRI Visual evoked potentials CSF oligoclonal bands Straight X-ray CT myelography MRI
Anterior horn cell (± spinal cord)	Motor neuron disease (progressive muscular atrophy)	Electromyography (EMG)
Nerve roots	<ul style="list-style-type: none"> Spondylosis/disc disease Tumour 	CT Scan/MRI (myelography – cervical roots, radiculography – lumbar roots)
Plexus/peripheral nerves	<ul style="list-style-type: none"> Peripheral neuropathy Trauma Tumour infiltration 	EMG, Nerve conduction studies
Neuromuscular junction	<ul style="list-style-type: none"> Myasthenia gravis Myasthenic syndrome 	EMG, Tensilon test
Muscle	<ul style="list-style-type: none"> Myopathy Dystrophy 	EMG, Muscle biopsy

SENSORY IMPAIRMENT

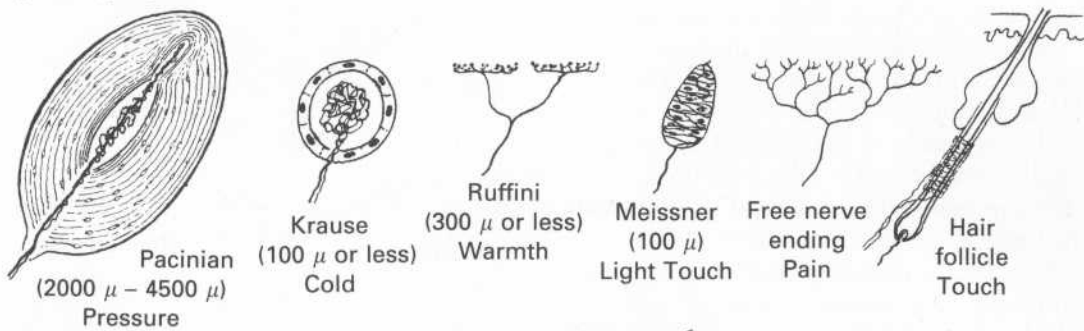
ANATOMY AND PHYSIOLOGY

The sensory system relays information from both the external and the internal environment.

Receptors convert this information into electrical action potentials.




Cutaneous receptors are of several types and, while overlap does occur, each has some specific purpose.



Muscle and tendon receptors

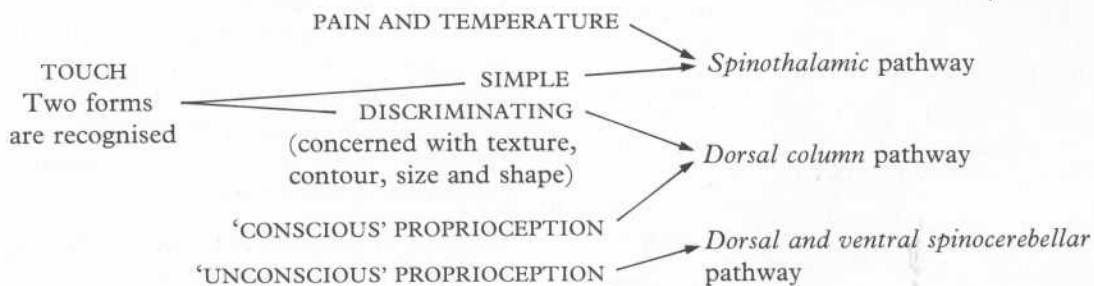
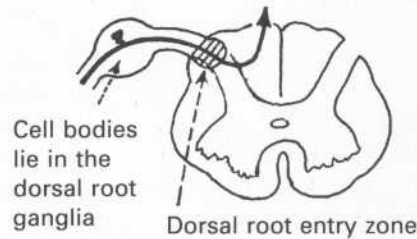
These receptors along with those of pressure and touch provide information on body and limb position - proprioception.



Continual stimulation of most receptors results in a reduction in the action potential frequency - ADAPTATION

CENTRAL CONNECTIONS

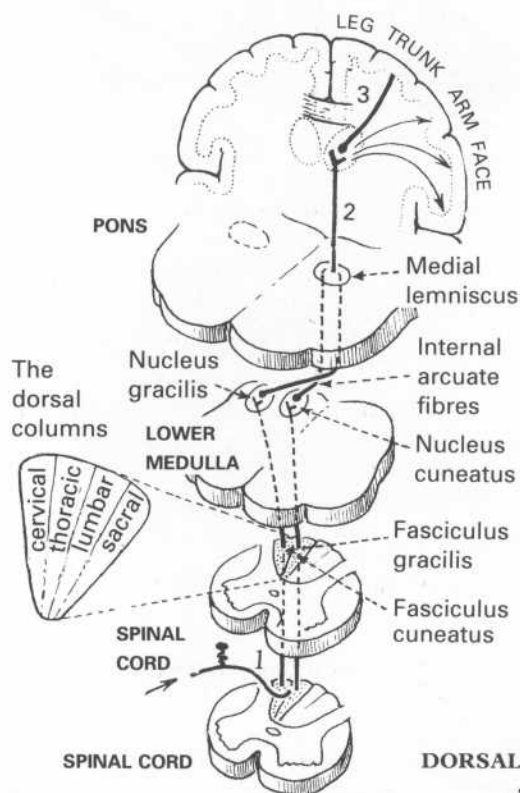
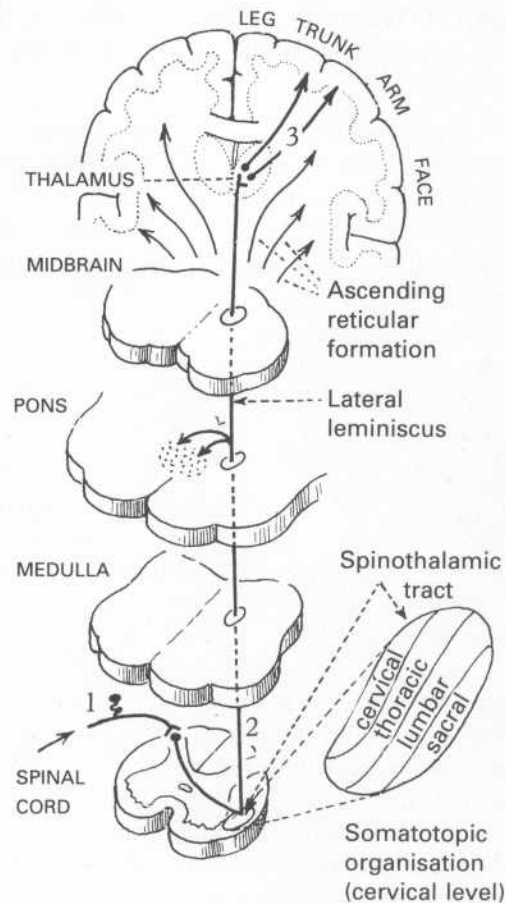
Sensory neurons (bipolar cells) relay information to the spinal cord via the dorsal root to the dorsal root entry zone. The anatomical and physical characteristics of the neurons vary depending on the information they carry, as do the central pathways:



SENSORY IMPAIRMENT

SPINOTHALAMIC PATHWAY

1. Fibres enter the root entry zone and pass up or down for several segments in *Lissauer's tract* before terminating in the dorsal aspect of the dorsal horn.
2. *Second order neurons* synapse locally, cross the midline and run up the *spinothalamic tract* and *lateral lemniscus* to terminate in the posterolateral nucleus of the *thalamus*. Throughout its course, the fibres lie in a *somatotopic arrangement* with sacral fibres outermost. In the brain stem the lateral lemniscus gives off collateral branches to the *reticular formation*, which projects widely to the cerebral cortex and limbic system and is joined by fibres from the contralateral nucleus and tract of the trigeminal nerve.
3. From the thalamus, *third order neurons* project to the *parietal cortex*.



DORSAL COLUMN PATHWAY

1. Fibres enter in the root entry zone and run upwards in the *dorsal columns* to the *lower medulla* where they terminate in the *nucleus gracilis* and *nucleus cuneatus*.
2. *Second order neurons* decussate as the *internal arcuate fibres* and pass upwards in the *medial lemniscus*. Maintaining a *somatotopic arrangement*, they terminate in the ventral posterolateral thalamus.
3. *Third order neurons* arise in the thalamus and project to the *parietal cortex*.

DORSAL AND VENTRAL SPINOCEREBELLAR PATHWAYS:
see Cerebellar dysfunction, page 176.

SENSORY IMPAIRMENT

EXAMINATION OF THE SENSORY SYSTEM: see page 21

CLINICAL FEATURES

Sensory disturbance may result in:

- NEGATIVE symptoms: 'a loss of feeling'
'a deadness'.
POSITIVE symptoms: 'a pins and needles sensation'
'a burning feeling'.

Lesions of the PERIPHERAL NERVES or NERVE ROOTS may produce 'negative' or 'positive' symptoms.

SPINOTHALAMIC TRACT lesions – seldom produce pain but usually a *lack of awareness of pain and temperature*.

This may result in:

- trophic changes: cold
blue extremities
hair loss
brittle nails
- painless burns
- joint deformation (Charcot's joints).

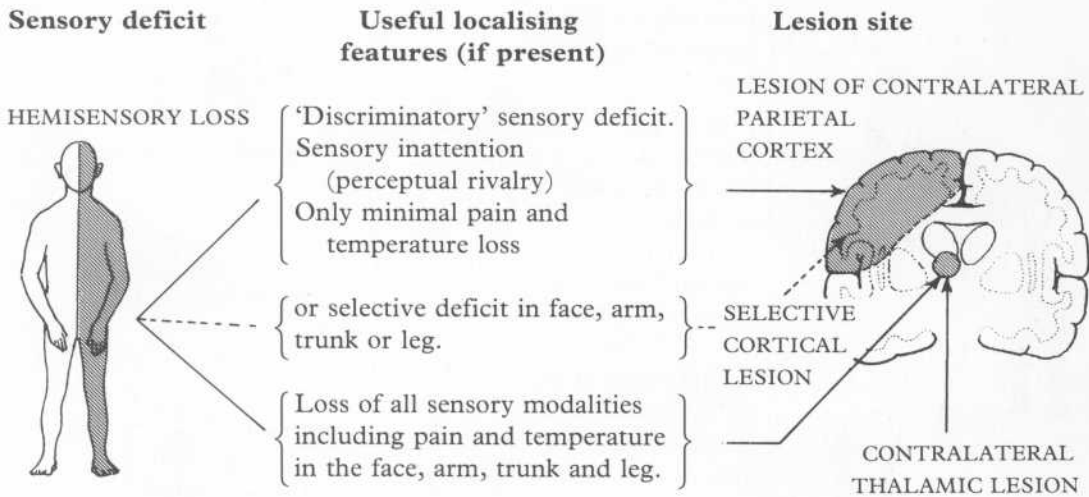
DORSAL COLUMN lesions – produce a *discriminatory type of sensory loss*.

- impaired two point discrimination
- astereognosis (failure to discriminate objects held in the hand).
- sensory ataxia (disturbed proprioception).

Lesions of the PARIETAL CORTEX also produce a *discriminatory type of sensory loss*. Minor lesions produce *sensory inattention* (perceptual rivalry) – with bilateral simultaneous limb stimulation, the stimulus is only perceived on the unaffected side.

LESION LOCALISATION

The pattern of the sensory deficit aids lesion localisation.



SENSORY IMPAIRMENT

LESION LOCALISATION (contd)

Sensory deficit

Useful localising features (if present)

Lesion site

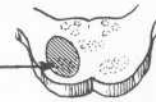
FACIAL
SENSORY
LOSS



HEMISENSORY
LOSS

Loss of all modalities in the limbs (depending on the extent of the lesion).
Loss of pain and temperature on the opposite side of the face with or without 'muzzle' area sparing and a lateral gaze palsy towards that side.

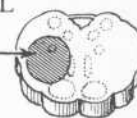
CONTRALATERAL
PONTINE
LESION



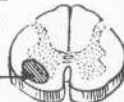(Ipsilateral to the facial sensory loss)

As above – but lateral gaze normal.
Weakness of palate and tongue on side opposite to the limb sensory deficit.

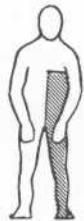CONTRALATERAL
MEDULLARY
LESION



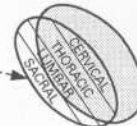
CONTRALATERAL
SPINOTHALAMIC
TRACT LESION



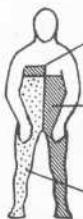
(Partial spinothalamic tract lesion)



Loss of pain, temperature and light touch below a specific dermatome level (may spare sacral sensation).



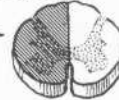
Loss of all modalities at one or several dermatome levels.



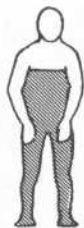Loss of pain and temperature below a specific dermatome level.

Loss of proprioception and 'discriminatory' touch up to similar level and limb weakness.

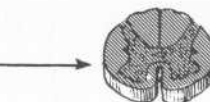
BROWN-SEQUARD
SYNDROME



(Partial cord lesion)

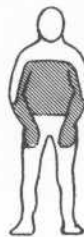

Bilateral loss of all modalities.
Bilateral leg weakness.

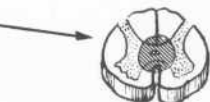


COMPLETE CORD LESION

'SUSPENDED'
SENSORY
LOSS



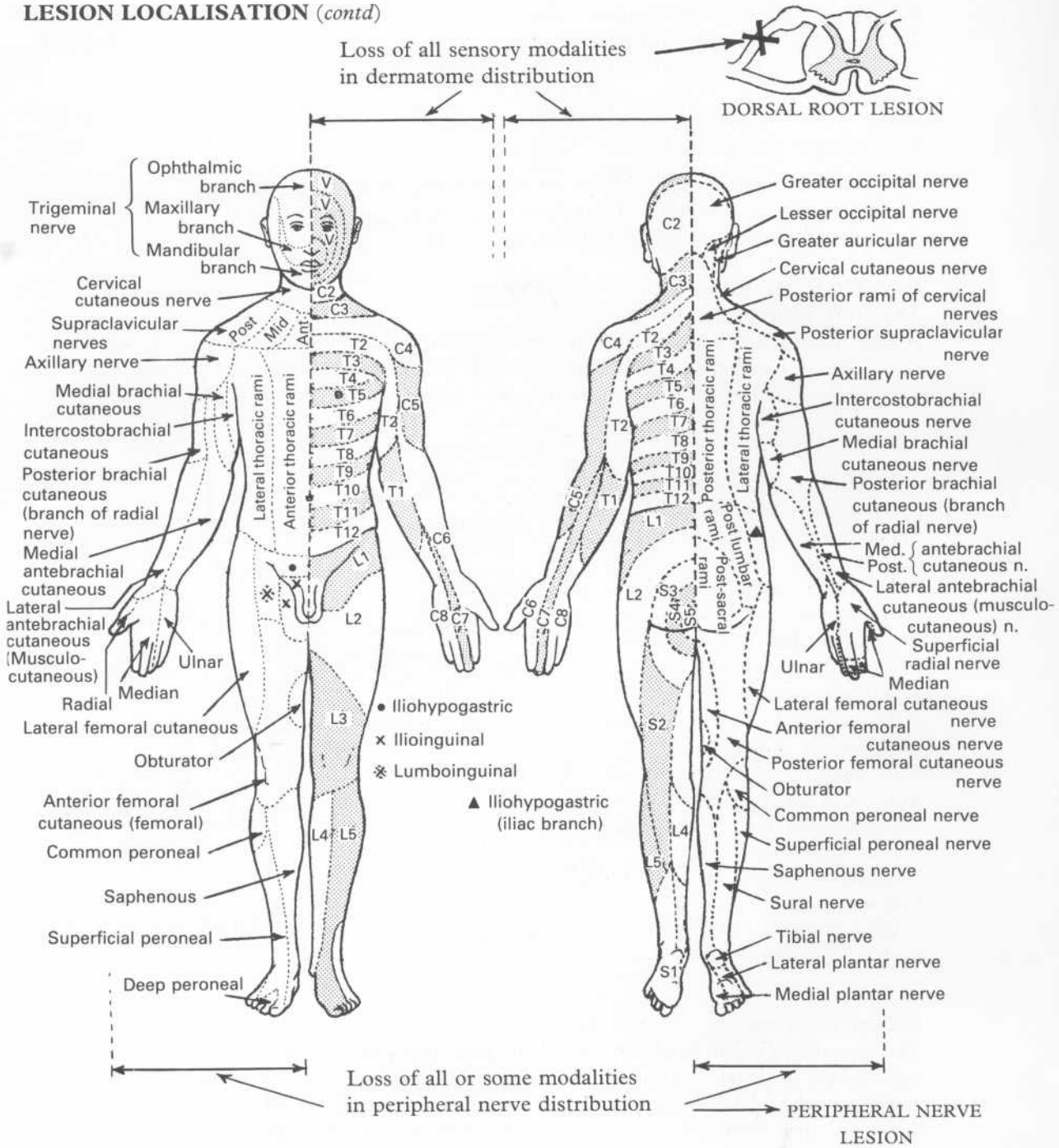
Bilateral loss of pain and temperature.
Preservation of proprioception and 'discriminatory' sensation.



CENTRAL CORD LESION

SENSORY IMPAIRMENT

LESION LOCALISATION (contd)



PAIN

Peripheral receptors of pain – free nerve endings lying in skin or other organs – are the distal axons of sensory neurons. Such unmyelinated or only thinly myelinated axons are of small diameter. The termination and central connections of these axons are described on page 196.

The type of stimulus required to activate free endings varies, e.g. in muscle – ischaemia, in abdominal viscera – distension.

Certain substances – bradykinins, prostaglandins, histamine – may stimulate free nerve endings.

These substances are released in damaged tissue.



CONTROL OF SENSORY (PAIN) INPUT

The Gate control theory

A relay system in the posterior horn of the spinal cord modifies pain input. This involves interneuronal connections within the substantia gelatinosa (a layer of the posterior horn which extends throughout the whole length of the spinal cord on each side).

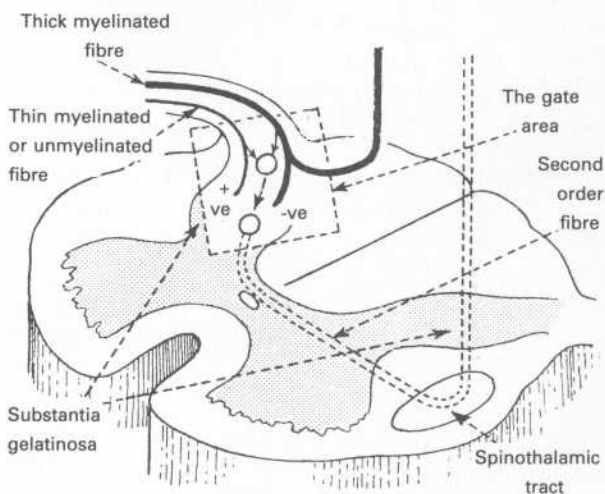
An afferent impulse arriving at the posterior horn in *thick myelinated fibres* has an inhibitory effect in the region of the substantia gelatinosa.

An afferent impulse arriving in *thin myelinated or unmyelinated fibres* (i.e. transmitting pain) has an excitatory effect in the region of the substantia gelatinosa.

The overall interaction of these inhibitory or excitatory effects determines the activity of second order neurons of the spinothalamic pathway.

A reduction in activity of large sensory fibres ‘opens’ the gate. Stimulation of large sensory fibres theoretically ‘closes’ the gate.

In addition to these segmental influences, higher centres also control the gate region and form part of a feed-back loop.



Cross section of the spinal cord: the gate area connections

Pain perception

The awareness of pain is brought about by projection from the thalamus to cerebral cortex. Personality, mood and neuroticism all influence the intensity of pain perception. Diffuse projections through Lissauer’s tract and the reticular core of the spinal cord white matter to the reticular formation and limbic system probably contribute to the unpleasant, emotionally disturbing aspects of pain.

NEUROTRANSMITTER SUBSTANCES

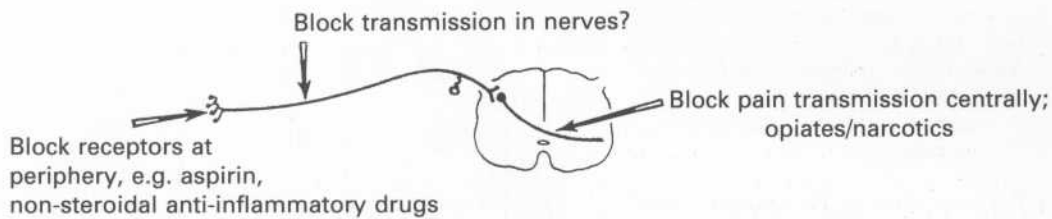
Evidence based on both human and animal studies has shown that an endogenous system, lying within the central nervous system can induce a degree of analgesia. Electrical stimulation of certain sites, such as the periaqueductal grey matter, can inhibit pain perception.

Receptor sites for endogenous opiates have been found in the posterior horns and thalamus as well as at several other sites. The endogenous substances which bind to these sites are called *encephalins* or *endorphins*.

Substance P, a polypeptide, found predominantly around free nerve ending receptors and in the spinal cord posterior horns, is the likely primary transmitter of pain.

DRUG TREATMENT

Sites of potential drug action:



Drug selection in pain treatment depends on the severity, cause and the expected duration of the pain, i.e. *acute pain* – less than 2 weeks duration, e.g. postoperative, post-traumatic, renal colic.

chronic pain – *benign* origin, e.g. postherpetic neuralgia, phantom limb pain, chronic back pain.
– *malignant* origin.

1. In acute pain, drug therapy ranges from *mild analgesics* – aspirin, paracetamol – to *narcotic agents* – morphine, heroin. *Tranquillisers* may also help.
2. In chronic pain of benign origin, narcotics and sedatives must be avoided. In these patients, depression usually plays a rôle and the clinician must not underestimate the value of *antidepressants*.
Anticonvulsants – carbamazepine appears to benefit many patients, probably due to its membrane stabilizing effect.
Topical treatment – capsaicin blocks substance P and inhibits pain transmission in the skin. Used for postherpetic neuralgia.
3. In chronic pain from terminal malignancy, patients often require *strong narcotics* – morphine, heroin. Frequent administration of small doses provides the greatest effect.

PAIN – TREATMENT

PERIPHERAL TECHNIQUES

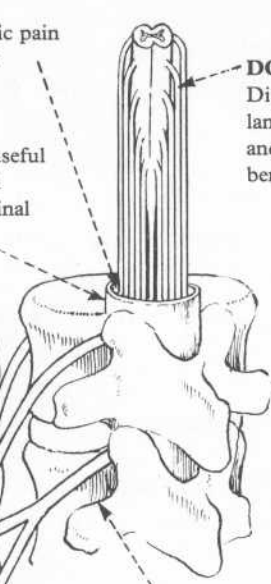
Generally used for more benign conditions and before resorting to central techniques.

NERVE BLOCKS: Injections of agents into peripheral nerves or roots abolishes pain in the appropriate dermatome; motor and sympathetic function are also lost. Local anaesthetics produce a temporary effect; neurolytic agents, e.g. phenol, alcohol, give permanent results.

- *Intraspinal* phenol or hypertonic saline for chronic pain usually used in patients with terminal malignancy.
- *Epidural* local anaesthetic produces temporary analgesia. Narcotic infusion appears useful for controlling postoperative pain and intractable pain in patients with terminal malignancy.
- *Sympathetic Ganglion or Trunk*
 - anaesthetics or neurolytic agent often helps causalgic pain. (see page 204).
- *Paravertebral or Peripheral Nerve*
 - local anaesthetics may benefit temporary pain states, e.g. fractured rib, but neurolytic agents often cause a painful neuritis.

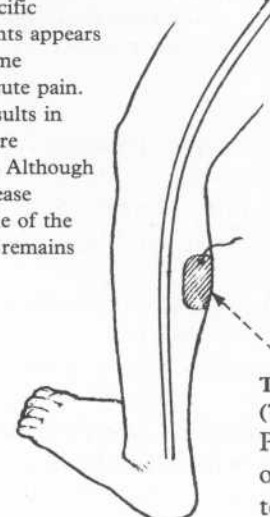
DORSAL RHIZOTOMY:

Division of the dorsal roots via a laminectomy has a high failure rate and provides only short lasting benefit. Now seldom performed.



ACUPUNCTURE:

Insertion and rotation of needles in specific cutaneous points appears to produce some analgesia in acute pain. Long-term results in chronic pain are disappointing. Although endorphin release occurs, the rôle of the placebo effect remains unclear.



FACET JOINT INJECTION:

Depomedrone combined with marcaine, injected into the facet joints, helps some patients with backpain from osteoarthritic degeneration and can be repeated as required. Alternatively a percutaneous radiofrequency heat lesion applied to the posterior ramus of the spinal nerves exiting from the intervertebral foramen, denervates the facet joints. This technique relieves facet joint pains in the majority of patients, but as the nerve regenerates, pain returns unless preventative measures are adopted.

TRANSCUTANEOUS ELECTRICAL NERVE STIMULATION (TENS):

Prolonged electrical stimulation over the affected site often alleviates pain of peripheral origin. This technique acts either by stimulating large diameter fibres, closing the 'gate' at the dorsal root entry zone or via higher centres.

PAIN – TREATMENT

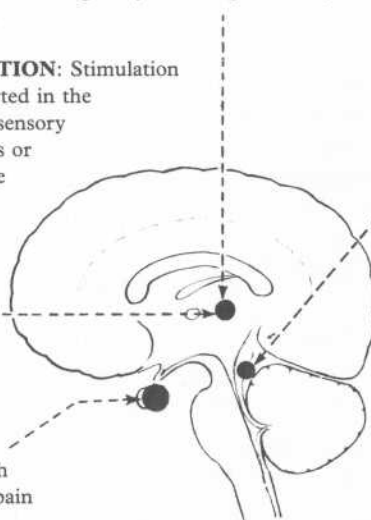
CENTRAL TECHNIQUES

Used primarily in patients with intractable pain from malignancy

STEREOTACTIC THALAMOTOMY: The spinoreticular system appears largely responsible for the unpleasant aspects of pain sensation. Stereotactic obliteration of the spinoreticular relay nuclei in the thalamus (page 370) may help patients with intractable pain from malignancy involving the head, neck or brachial plexus, sites where other methods of pain control are limited.

DEEP BRAIN STIMULATION: Stimulation of implanted electrodes inserted in the periventricular grey matter, sensory relay nucleus of the thalamus or internal capsule may produce pain relief in patients with head or neck malignancy. If successful, a radiocontrolled stimulator is implanted subcutaneously.

MESENCEPHALOTOMY: A radiofrequency heat lesion in a stereotactically implanted electrode inserted into the midbrain reticular formation may help patients with head and neck malignancy.



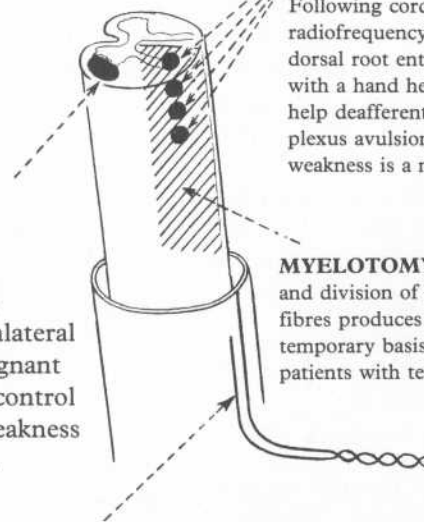
HYPOPHYSECTOMY: By transphenoidal excision or with radioactive yttrium may help pain from metastatic deposits. The mechanism of relief remains uncertain; this is not merely due to tumour regression.

DORSAL ROOT ENTRY ZONE LESIONS

Following cord exposure, multiple radiofrequency heat lesions of the dorsal root entry zone are produced with a hand held electrode. This may help deafferentation pain, i.e. brachial plexus avulsion, but ipsilateral leg weakness is a major complication.

PERCUTANEOUS ANTEROLATERAL CORDOTOMY: A percutaneous radiofrequency heat lesion of the spinothalamic tract now replaces open cordotomy. This produces pain relief in 90% of patients in the contralateral limbs. It is usually applicable in malignant states where simple methods of pain control have failed. Risks (ipsilateral limb weakness and respiratory difficulties) are small.

MYELOTOMY: Exposure of the cord and division of the decussating pain fibres produces pain relief on a temporary basis, restricting use to patients with terminal malignancy.



DORSAL COLUMN STIMULATION: Stimulation of electrodes inserted percutaneously into the epidural space may benefit patients with chronic pain, unresponsive to non-invasive techniques. A trial with exteriorised electrodes permits evaluation, prior to implanting a radiocontrolled stimulator.

PAIN SYNDROMES

Pain is not primarily a pathological phenomenon, but serves a protective function. Conditions with loss of pain perception exemplify this, resulting in frequent injuries, burns and subsequent mutilations, e.g. syringomyelia, hereditary sensory neuropathy, congenital insensitivity to pain.


Pathological conditions do, however, cause pain – as a symptom of cancer, injury or other disease.

The following conditions produce characteristic pain syndromes.

CAUSALGIA

Causalgia is an intense, continuous, burning pain produced by an incomplete peripheral nerve injury. Touching the limb aggravates the pain, and the patient resents any interference or attempt at limb mobilisation. The skin becomes red, warm and swollen.

Theoretical mechanism



Causalgia only occurs with damage to peripheral nerves containing a large number of sympathetic fibres and responds in part to sympathetic blockade (pharmacological or surgical).

POSTHERPETIC NEURALGIA

Following activation of a latent infection with varicella zoster virus lying dormant in the dorsal root or gasserian ganglion, the patient develops a burning, constant pain with severe, sharp paroxysmal twinges over the area supplied by the affected sensory neurons. Touch exacerbates the pain. Thick myelinated fibres are preferentially damaged, possibly opening the 'gate'.

Treatment of postherpetic neuralgia is particularly difficult. Carbamazepine and/or antidepressants may help. Ethylchloride spray over the affected area provides temporary relief. Topical capsaicin is a promising new treatment.

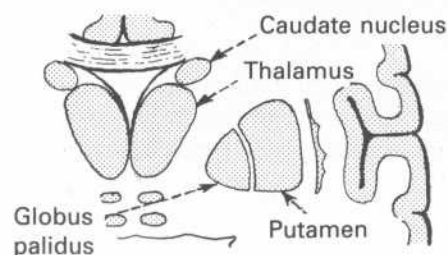
THALAMIC PAIN

Thalamic stimulation may produce or abolish pain depending upon the electrode site. A vascular accident which involves the inhibitory portion of the thalamus may result in pain – the thalamic syndrome.

Clinical features: Hemianaesthesia at onset contralateral to the lesion precedes the development of pain. This is burning and diffuse, and exacerbated by the touch of clothing.

Treatment: Drug treatment gives poor results. A stereotactic procedure although increasing the sensory deficit may help.

Paradoxically the thalamic syndrome may occur following a thalamic stereotactic procedure for movement disorders.

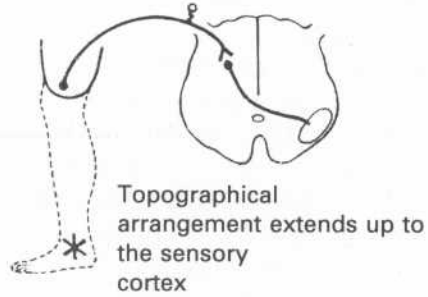


PAIN SYNDROMES

PHANTOM LIMB PAIN

Following amputation of a limb, 10% of patients develop pain with a continuous persistent burning quality, caused by neuroma formation in the stump. The patient 'feels' the pain arising from some point on the missing limb (the pain input projects through pathways which retain the topographical image of the absent limb).

Treatment: no specific treatment.



VISCERAL AND REFERRED PAIN

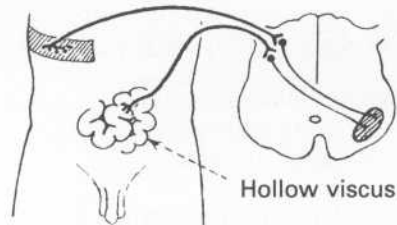
Deep visceral pain is dull and boring; it is the consequence of distension or traction on free nerve endings.

Referred pain of a dull quality relates to a specific area of the body surface – often hypersensitive to touch.

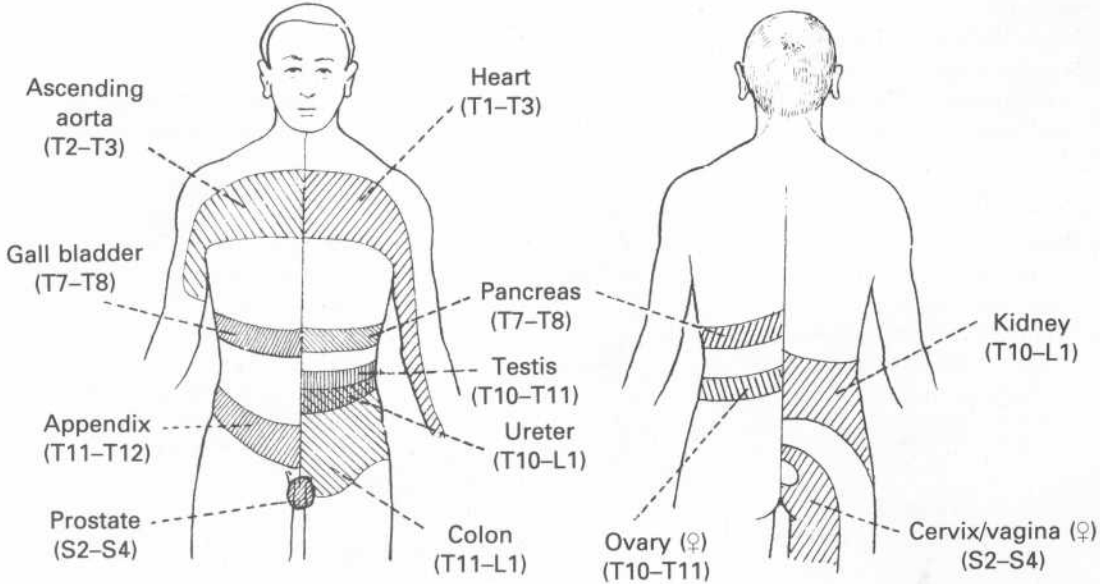
The basis of referred pain

The visceral afferents converge upon the same cells in the posterior horns as the somatic efferents. The patient 'projects' pain from the viscera to the area supplied by corresponding somatic afferent fibres.

A knowledge of the source of referred pain is important in diagnosis and treatment.



SITES OF REFERRED PAIN FROM SPECIFIC ORGANS

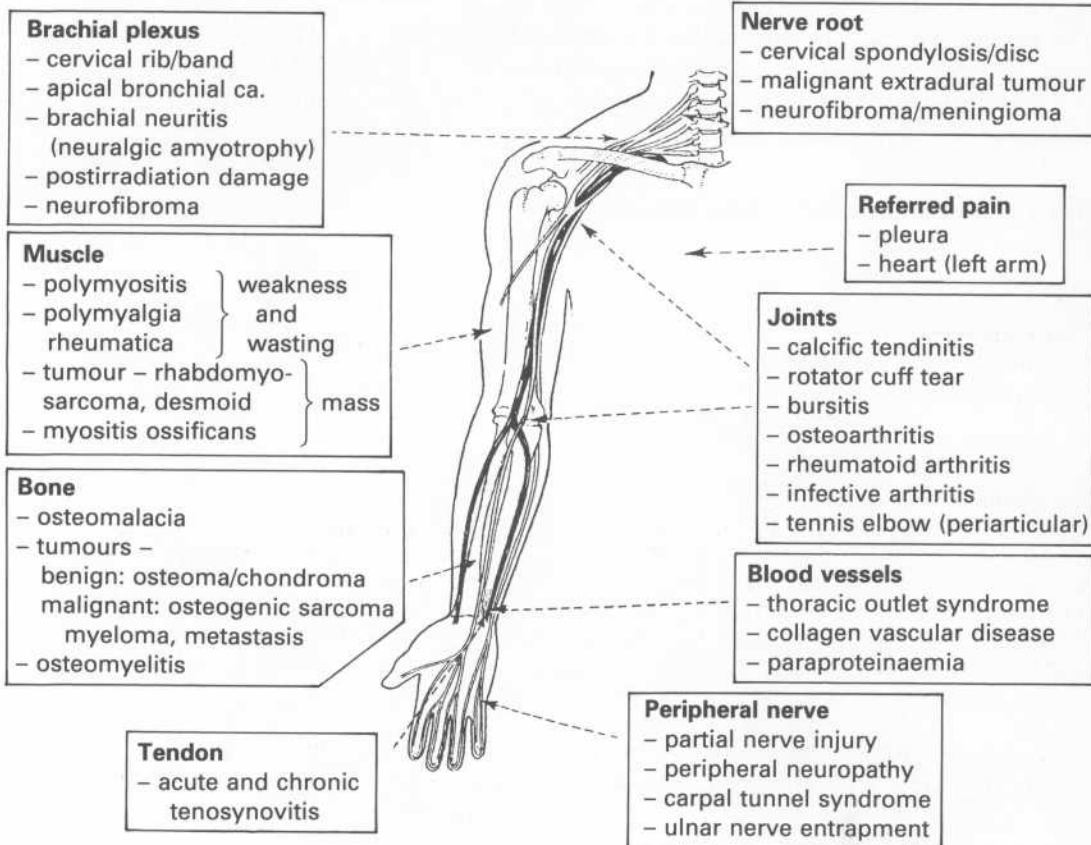


LIMB PAIN

Pain may arise from any anatomical structure within the limb. Each produces characteristic features:

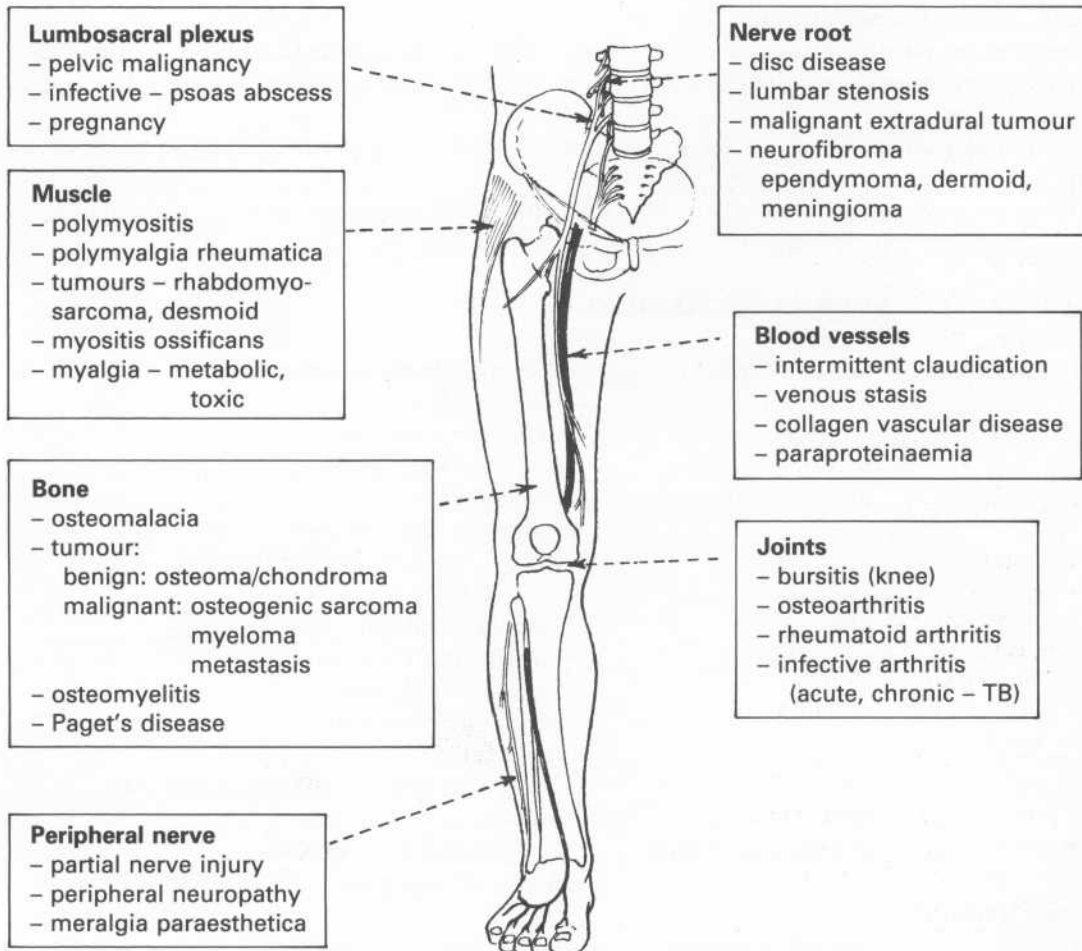
- | | |
|----------------------------------------------------------------------------------------------------------------------------------------------------------------------------------|-----------------------------------------------------------------------------------------------------------------------------------------------------------------------------------------------------------------------------|
| <p>BONE – diffuse, aching pain
± palpable mass.</p> | <p>BLOOD VESSELS – pain brought on by exertion (claudication), relieved by rest.
– pain at rest in pale, pulseless limb (occlusion).
– pain associated with paraesthesia and digital pallor (Raynaud's).</p> |
| <p>JOINTS – pain localised to affected joint.
– tenderness on palpation.
– movements restricted and painful.
– wasting of surrounding muscles may follow.</p> | <p>NERVE ROOT – pain increased by coughing or by movement
± associated neurological deficit</p> |
| <p>MUSCLES – pain localised to specific muscle
± wasting and weakness
± palpable mass.</p> | <p>PLEXUS OR PERIPHERAL NERVE – burning pain
± sweating, cyanosis and oedema of extremity,
± associated neurological deficit.</p> |
| <p>TENDONS – pain localised to swollen, tender tendon sheath.</p> | |

CAUSES OF UPPER LIMB PAIN



LIMB PAIN

CAUSES OF LOWER LIMB PAIN



Meralgia paraesthetica: burning, tingling pain over the outer aspect of the thigh, increased when standing or by walking, due to a localised neuritis of the lateral cutaneous nerve of the thigh. A patch of sensory impairment may be evident over the outer aspect of the thigh.

Ekbom's syndrome: (syn. restless legs syndrome): intolerable tingling, burning sensation or pain in both legs, occurring only when sitting or lying down and relieved by walking; no associated neurological abnormality.

Investigation of limb pain depends on the suspected cause and may include straight X-rays, CTscan, MRI, nerve conduction studies and EMG.

MUSCLE PAIN (MYALGIA)

Muscle pain is a common medical complaint. There are many causes and clinical evaluation and appropriate investigation is often difficult. The physiological mechanisms producing such a symptom are limited.

Mechanical pain results from excessive muscle tension or contraction and is 'cramp like'

Inflammatory pain results from disruption of muscle fibres, inflammatory exudate and fibre swelling

Ischaemic pain results from metabolic change, usually in response to exercise and is deep and aching.

Muscle pain may be physiological – as a consequence of extreme exercise or pathological – as a consequence of muscle, soft tissue or systemic illness.

DIAGNOSTIC APPROACH TO MUSCLE PAIN

History

Is muscle pain – present at rest?	– Polymyalgia rheumatica – Fibromyalgia – Parkinson's disease – Collagen vascular disease
present with exercise?	– Physiological – Metabolic myopathies – Benign myalgic encephalomyelitis (ME)
localised?	– Muscle haematoma, abscess, tumour or fibromyalgia
generalised?	– Polymyalgia rheumatica – Parkinson's disease – Metabolic myopathies – Inflammatory myopathies – Benign myalgic encephalomyelitis (ME)
family history?	– Metabolic myopathies
exposure to toxins?	– Drug induced myopathies – Alcoholic myopathy

Examination

Is there – wasting/weakness?	– Inflammatory myopathies – Metabolic myopathies – Drug induced myopathies – Alcoholic myopathy
skin rash?	– Inflammatory myopathy (dermatomyositis) – Collagen vascular disease
stiffness or spasms?	– Tetanus – Tetany – Spasticity – Neuroleptic malignant syndrome – Malignant hyperthermia
muscle swelling?	– Muscle abscess, tumour – Metabolic myopathy

MUSCLE PAIN (MYALGIA)

DIAGNOSTIC APPROACH TO MUSCLE PAIN (*continued*)

Investigations

Serum creatine kinase (muscle enzyme)

- elevated in muscle necrosis, high levels result in myoglobinuria

Imaging (occasionally used)

Ultrasound, MR or CT in suspected muscle haematoma, abscess or tumour.

Radionuclide (Gallium or in suspected muscle abscess, Technitium)

Electromyography (EMG)

Will confirm presence of myopathy (rarely more specific)

Muscle biopsy (needle or open)

Essential in diagnosis of

- inflammatory myopathies
- metabolic myopathies

Helpful in collagen vascular disease

Ischaemic lactate test

Measurement of post exercise

changes in serum lactate

Reduced response in - metabolic myopathies (disorders of glycolytic pathway)

Following extensive investigation, in a significant number of cases no cause of myalgia is found.

Most disorders are covered in relevant sections. Those that are not are briefly described.

Fibromyalgia

A common condition of uncertain pathology in which generalised muscle pain with localised tender areas occurs without objective clinical or laboratory abnormalities. Psychiatric symptoms commonly co-exist.

Malignant hyperpyrexia

Characterised by a sudden rise in body temperature whilst undergoing general anaesthesia, usually with halothane or succinylcholine. Certain hereditary myopathic disorders, e.g. myotonic dystrophy, central core disease - are unduly prone to this condition.

Muscle abscess

Commonly Staphylococcal due to local trauma or blood-borne in debilitated persons.

Polymyalgia Rheumatica

Proximal muscle pain encountered in the elderly and often associated with giant cell arteritis. The ESR is elevated and the EMG is normal. Muscle biopsy shows type 2 fibre loss. Steroids are effective.

Muscle tumours

These are rare. Mixed pathologically and of varying degrees of malignancy

Benign myalgic encephalomyelitis (ME)

Characterised by exercise induced muscle pain. A puzzling disorder often occurring after viral illness, associated with fatigue, without clear diagnostic criteria and merging with depressive symptoms.

OUTCOME AFTER BRAIN DAMAGE

Outcome after brain damage has major social and financial implications for both patients and their families. In a welfare state, society may carry most, if not all of the financial burden, particularly with more severe disability. The greater the disability, the greater the support required. Conditions causing brain damage do not respect age; survivors may need long-term care.

A variety of methods have been devised to categorise outcome. Such classifications provide end-points for audit and research, and a means of assessing therapeutic intervention. They permit predictions based on clinical and investigative findings early in the course of the disease. Most outcome scales have been developed with a particular disease in mind (e.g. Bartel/Rankin – stroke, Karnofsky – tumour). In 1975 Jennett and Bond developed the Glasgow Outcome Scale (GOS) for the assessment of head injured patients, and this is now widely applied in the assessment of patients with other causes of brain damage.

The Glasgow Outcome Scale Five categories exist –

1. **Death**
2. **Persistent Vegetative State** – see below.
3. **Severe Disability** – *dependent* for some support in every 24 hour period.
4. **Moderate Disability** – *independent* but disabled. May or may not be capable of return to work.
5. **Good recovery** – *good*, but not necessarily complete recovery. e.g. cranial nerve deficit. Could (although may not) return to work.

The Vegetative State

Severe bilateral hemisphere damage may result in a state in which the patient has no awareness of themselves or of their environment. Although periods of eye opening and closure may occur suggesting sleep/wake cycles, along with spontaneous movements of the face, trunk and limbs, the patient does not communicate or interact with others in any way.

The vegetative state becomes 'permanent' when irreversibility can be established with a high degree of certainty, i.e. > 6 months after non-traumatic coma and > 12 months after traumatic coma. At one month after *trauma*, about 1/3 of patients in the vegetative state will show some improvement over the subsequent year. After *non-traumatic coma*, outcome is much worse; only about 7% show some improvement and have severe disability.

Outcome Prediction

Outcome from **non-traumatic** coma depends on a variety of factors including the patient's *age*, the *duration* and *depth* of the coma, and the *cause* of the damage provided this is not drug induced.

		Poor outcome (GOS 1-3)	Favourable outcome (GOS 4-5)
Cause	Infective metabolic	65%	35%
	Hypoxic – ischaemic	90%	10%
	Cerebrovascular	95%	5%
Duration	>6 hours	85%	15%
Depth	Absent pupillary response at 24 hours	100%	0%
	Speaking, eye movements and reactive pupils at 2 hours	0%	100%

210 Outcome from **traumatic coma** see page 85.

BRAIN DEATH

The advent of improved intensive care facilities and more aggressive resuscitation techniques has led to an increase in numbers of patients with irreversible brain damage in which tissue oxygenation is maintained by a persistent heart beat and artificial ventilation.

A government working party has published guidelines for the diagnosis of brain death which, when fulfilled, indicate that recovery is impossible. In these patients, organs may be removed for transplantation before discontinuing ventilation.

The tests are designed to detect failure of *brain stem* function, but certain *preconditions* must first be met.

Preconditions

Depressant drugs must not contribute towards the patient's clinical state – if in doubt allow an adequate time interval to elapse to eliminate any possible persistent effect.

Hypothermia must not be a primary cause – ensure that temperature is not less than 35 °C.

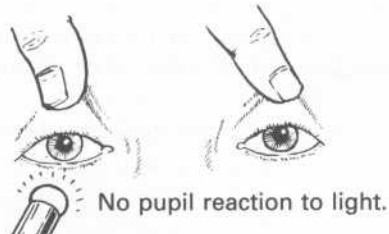
Severe *metabolic* or *endocrine* disturbance must be excluded as a possible cause of the patient's condition.

The patient must be on a ventilator as a result of inadequate spontaneous respiration or respiratory arrest – if a neuromuscular blocking drug has been used, exclude a prolonged effect by observing a muscle twitch on nerve stimulation, e.g. electrical stimulation of the median nerve should cause a thumb twitch.

The cause of the patient's condition must be established and this must be compatible with irreversible brain damage, e.g. severe head injury, spontaneous intracerebral haematoma. *If in doubt, delay brain death testing.*

BRAIN DEATH TESTS

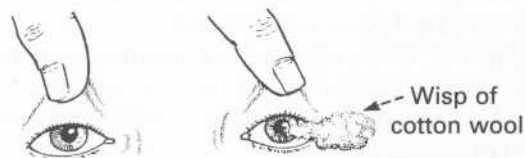PUPIL RESPONSE



No pupil reaction to light.

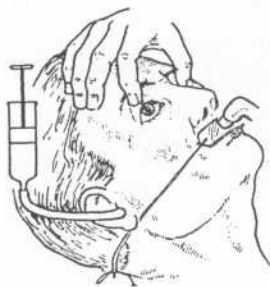
N.B. Ensure light intensity is adequate.

CORNEAL REFLEX



No orbicularis oculi contraction in response to corneal stimulation.

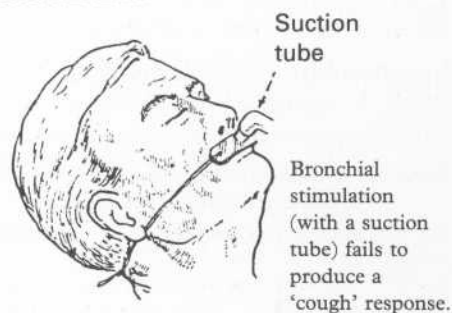
VESTIBULO-OCULAR REFLEX



No eye movements occur when 50 ml of iced water are slowly injected into the external meatus. (Ensure that the external meatus is not occluded with wax or blood.) In coma with preserved brain stem function, the eyes tonically deviate towards the tested ear after a delay of 20 seconds.

Maximal response is obtained with the head raised 30° from the horizontal.

GAG REFLEX



Suction tube

Bronchial stimulation (with a suction tube) fails to produce a 'cough' response.

BRAIN DEATH

MOTOR RESPONSE

No motor response in the face or in the muscles supplied by cranial nerves in response to a painful stimulus, e.g. supraorbital pain.



N.B. Limb responses are of no value in testing brain stem integrity.

Movements can occur in response to limb or trunk stimulation (especially in the legs), and tendon reflexes may persist in a patient with brain stem death but intact cord function.

Conversely, limb movements and reflexes may be absent in a patient with an intact brain stem and spinal cord damage.

RESPIRATORY MOVEMENTS

No respiratory movements are observed when the patient is disconnected from the ventilator. During this test, anoxia is prevented by passing 6 litres O₂ per minute down the endotracheal tube. This should maintain adequate PO₂ levels for up to 10 minutes.

N.B. Ensure that apnoea is not a result of a low PCO₂. This should be greater than 6.65 kPa (50 mmHg).

Clinician's status

The British recommendations state that these tests should be carried out by two doctors, both with expertise in the field; one of consultant status, the other of consultant or senior specialist registrar status. The doctors may carry out the tests individually or together.

Test repetition and timing

The test should be repeated but the interval should be left to the discretion of the clinician. The initial test may be performed within a few hours of the causal event, but in most instances is delayed for 12-24 hours, or longer if there is any doubt about the preconditions.

Timing of death

Certification of death occurs when brain death is established, i.e. at the time of the second test. Old concepts of death occurring at the time the heart ceases to beat are no longer applicable.

Supplementary investigations

Electroencephalography (EEG) is of no value in diagnosing brain death. Some patients with the potential to recover show a 'flat' trace; in others with irreversible brain stem damage, electrical activity can occasionally be recorded from the scalp electrodes.

Similarly, angiography or cerebral blood flow measurement are of no additional value to the clinical tests described above, provided the preconditions are fulfilled.

**LOCALISED NEUROLOGICAL DISEASE
AND ITS MANAGEMENT
A. INTRACRANIAL**

HEAD INJURY

INTRODUCTION

Many patients attend accident and emergency departments with head injury. Approximately 300 per 100 000 of the population per year require hospital admission; of these 9 per 100 000 die, i.e. 5000 patients per year in Britain. Some of these deaths are inevitable, some are potentially preventable.

The principal causes of head injury include road traffic accidents, falls, assaults and injuries occurring at work, in the home and during sports. The relative frequency of each cause varies between different age groups and from place to place throughout the country.

Head injuries from road traffic accidents are most common in young males; alcohol is frequently involved. Road traffic accidents, although only constituting about 25% of all patients with head injury, are the cause of more serious injuries. This cause contributes to 60% of the deaths from head injury; of these, half die before reaching hospital.

In many countries preventative and punitive measures controlling alcohol levels and the use of seat belts, air bags and crash helmets have reduced the incidence. Once a head injury has occurred, nothing can alter the impact damage. The aim of head injury management is to minimise damage arising from secondary complications.

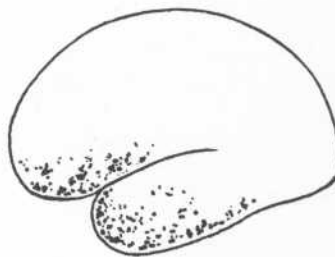
PATHOLOGY

Brain damage occurs both at impact and as a result of the development of secondary complications.

IMPACT DAMAGE is of two types, which *may coexist*:

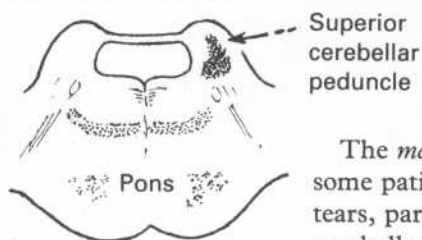
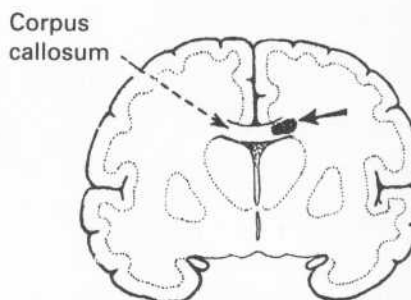
1. Cortical contusions and lacerations

These may occur under or opposite (*contre-coup*) the site of impact, but most commonly involve the frontal and temporal lobes. Contusions are usually multiple and may occur bilaterally. Multiple contusions do not in themselves contribute to depression of conscious level, but this may arise when bleeding into the contusions produces a space-occupying haematoma.



2. Diffuse axonal injury

This type of brain damage occurs as a result of mechanical shearing following deceleration, causing disruption and tearing of axons. Depending on the severity of injury its immediate effects range from mild confusion to coma and even death. Recent studies show that the full extent of the axonal damage takes some time to evolve.

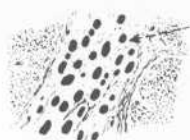

The *macroscopic* appearance may appear entirely normal but in some patients pathological sections reveal small haemorrhagic tears, particularly in the corpus callosum or in the superior cerebellar peduncle.

HEAD INJURY

Diffuse axonal injury (contd)

Microscopic evidence of neuronal damage depends on the duration of survival and on the severity of the injury. After a few days, retraction balls and microglial clusters are seen in the white matter.



Retraction balls reflect axonal damage. Note only axons in one plane are involved, indicating the direction of the 'shear'



Microglial clusters (hyper-trophied microglia) are found diffusely throughout the white matter

If the patient survives 5 weeks or more after injury then appropriate staining demonstrates Wallerian degeneration of the long tracts and white matter of the cerebral hemispheres. Even a minor injury causing a transient loss of consciousness produces some neuronal damage. Since neuronal regeneration is limited, the effects of repeated minor injury are cumulative.

SECONDARY BRAIN DAMAGE: may occur at any time after the initial impact. Impact damage is unavoidable, but secondary brain damage caused by haematoma, brain swelling, brain shift, ischaemia and infection may be preventable and this must be the aim of head injury management.

1. Intracranial haematoma

Intracranial bleeding may occur either outside (extradural) or within the dura (intradural).

Intradural lesions usually consist of a mixture of both subdural and intracerebral haematomas although pure subdurals occur in a proportion. Brain damage is caused directly or indirectly as a result of tentorial or tonsillar herniation.

Incidence of haematoma:

Extradural - 27%

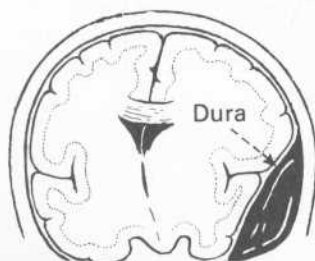
Intradural:

Pure subdural - 26%

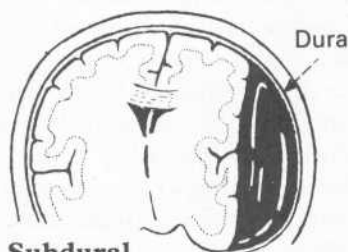
intracerebral.

± subdural - 38%

Extra- + Intradural - 8%

**Extradural**

A skull fracture tearing the middle meningeal vessels bleeds into the extradural space. This usually occurs in the temporal or temporoparietal region. Occasionally extradural haematomas are caused by a ruptured sagittal or transverse sinus.

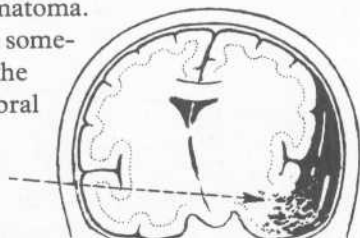
**Subdural**

In some patients impact may rupture bridging veins from the cortical surface to the venous sinuses producing a pure subdural haematoma with no evidence of underlying cortical contusion or laceration.

Intracerebral ± subdural (burst lobe)

Contusions in the frontal and temporal lobes often lead to bleeding into the brain substance, usually associated with an overlying subdural haematoma.

'Burst lobe' is a term sometimes used to describe the appearance of intracerebral haematoma mixed with necrotic brain tissue, rupturing out into the subdural space.

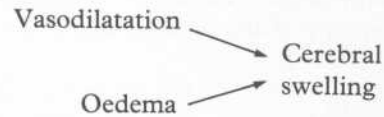


HEAD INJURY

SECONDARY BRAIN DAMAGE (contd)

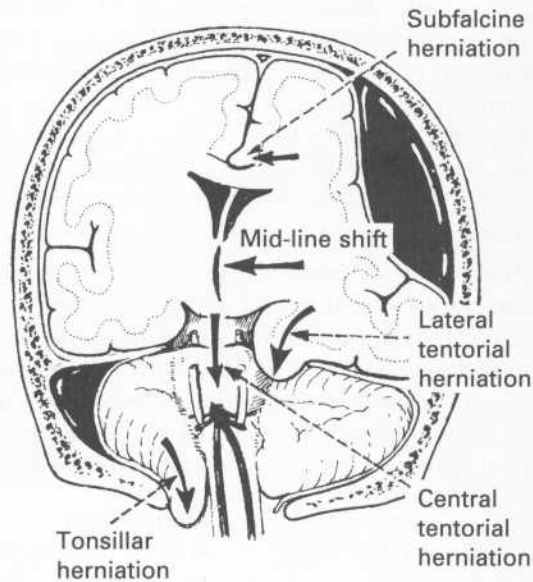
2. Cerebral swelling

This may occur with or without intracranial haematoma. It results from either vascular engorgement or an increase in extra- or intracellular fluid, the exact causative mechanisms in different injuries remaining unknown.



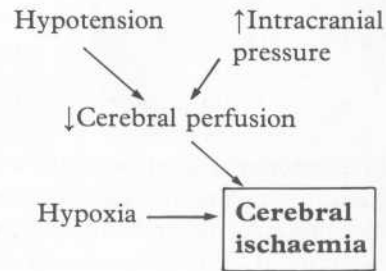
3. Tentorial/tonsillar herniation (syn. 'cone')

It is unlikely that high intracranial pressure alone directly damages neuronal tissue, but brain damage occurs as a result of tonsillar or tentorial herniation (see page 77). A progressive increase in intracranial pressure due to a supratentorial haematoma initially produces midline shift. Herniation of the medial temporal lobe through the tentorial hiatus follows (*lateral tentorial herniation*), causing midbrain compression and damage. Uncontrolled lateral tentorial herniation or diffuse bilateral hemispheric swelling will result in *central tentorial herniation*. Herniation of the cerebellar tonsils through the foramen magnum (*tonsillar herniation*) and consequent lower brainstem compression may follow central tentorial herniation or may result from the infrequently occurring traumatic posterior fossa haematoma.

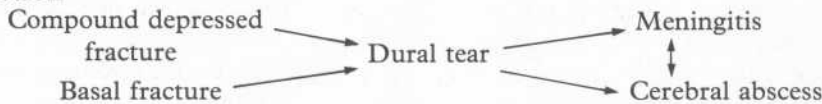


4. Cerebral ischaemia

Cerebral ischaemia commonly occurs after severe head injury and is caused by either hypoxia or impaired cerebral perfusion. In the normal subject, a fall in blood pressure does not produce a drop in cerebral perfusion since 'auto-regulation' results in cerebral vasodilatation. After head injury, however, autoregulation is often defective and hypotension may have more drastic effects. Glutamate excess and free radical accumulation may also contribute to neuronal damage (see page 241).



5. Infection

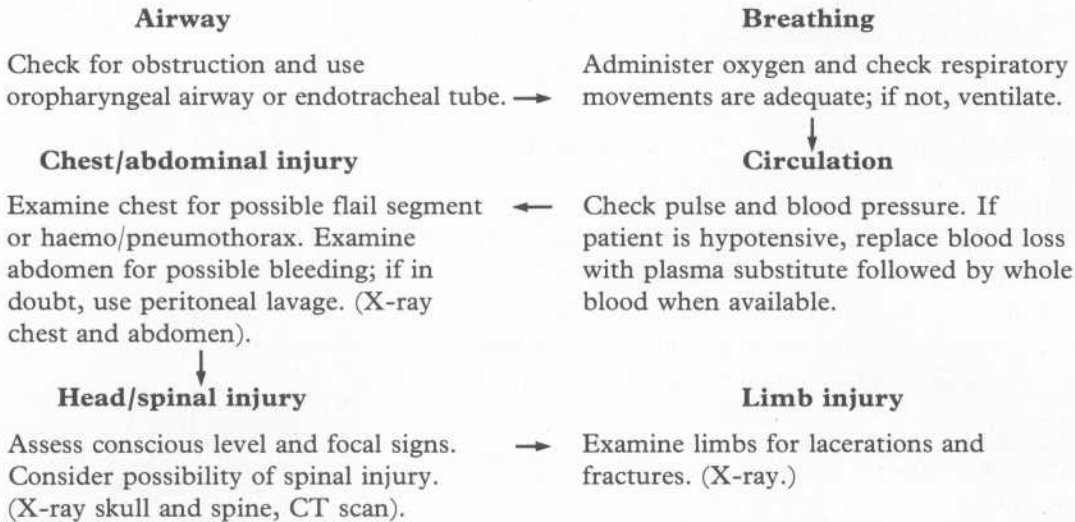


The presence of a dural tear provides a potential route for infection. This seldom occurs within 48 hours of injury. Meningitis may develop after several months or years.

HEAD INJURY – CLINICAL ASSESSMENT

MULTIPLE INJURY – PRIORITIES OF ASSESSMENT

Patients admitted in coma with multiple injuries require urgent care and the clinician must be aware of the priorities of assessment and management.



When intracranial haematoma is suspected, a CT scan is essential, especially before clinical signs are masked by a general anaesthetic required for the management of limb or abdominal injuries. However, if difficulty occurs in maintaining blood pressure, then urgent laparotomy or thoracotomy would take precedence over further investigation of a possible intracranial haematoma.

HEAD INJURY – ASSESSMENT

Some patients may describe the events leading to and following head injury, but often the doctor depends on descriptions from witnesses.

Points to determine:

Period of loss of consciousness: Relates to severity of diffuse brain damage and may range from a few seconds to several weeks.

Period of post-traumatic amnesia: This is the period of permanent amnesia occurring after head injury. It also reflects the severity of damage and in severe injuries may last several weeks. (Period of retrograde amnesia, i.e. amnesia for events before the injury is of less value since it bears no relation to the severity of injury and may improve with time).

Cause and circumstances of the injury: The patient may collapse, or crash his vehicle as a result of some preceding intracranial event, e.g. subarachnoid haemorrhage or epileptic seizure. The more 'violent' the injury, the greater the risk of associated extracranial injuries.

Presence of headache and vomiting: These are common symptoms after head injury. If they persist, the possibility of intracranial haematoma must be considered.

HEAD INJURY – CLINICAL ASSESSMENT

EXAMINATION

1 Evidence of injury:
LACERATIONS
GRAZING/BRUISING

3 CONSCIOUS LEVEL

- Eye opening
- Verbal response
- Motor response

4 PUPIL RESPONSE

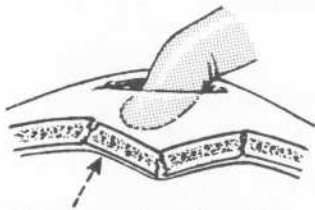
2 BASAL FRACTURE SIGNS

5 LIMB WEAKNESS

6 EYE MOVEMENTS

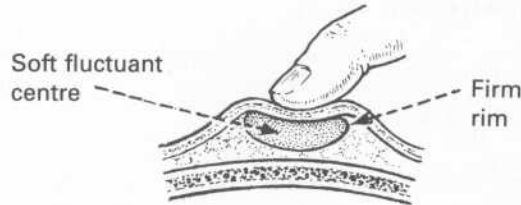
1. Lacerations and bruising

The presence of these features confirms the occurrence of a head injury, but traumatic intracranial haematoma can occur in patients with no external evidence of injury.



Always explore deep lacerations with a gloved finger for evidence of a depressed fracture.

Beware of falling into the trap of diagnosing a depressed fracture when only scalp haematoma is present.



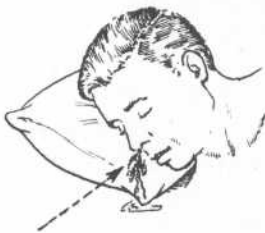Consider the possibility of a hyperextension injury to the cervical spine if frontal laceration or bruising is present.

2. Basal skull fracture

Clinical features indicate the presence of a basal skull fracture which may not be evident on routine skull X-ray or even on specific views of the skull base. If present, a potential route of infection exists with the concomitant risk of meningitis.

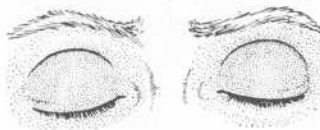ANTERIOR FOSSA FRACTURE

CSF rhinorrhoea



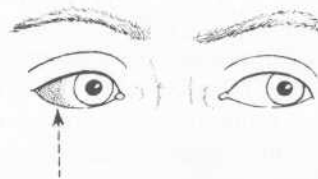If the nasal discharge contains glucose, then the fluid is CSF rather than mucin.

Bilateral periorbital haematoma



Bruising limited to the orbital margins indicates blood tracking from behind.

Subconjunctival haemorrhage



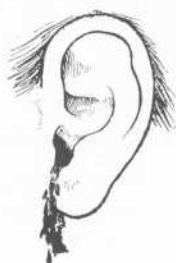Bruising under conjunctiva extending to posterior limits of the sclera indicates blood tracking from orbital cavity.

HEAD INJURY – CLINICAL ASSESSMENT

Basal skull fracture (contd)

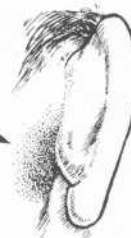PETROUS FRACTURE

Bleeding from the external auditory meatus or CSF otorrhoea:



Blood or CSF leaking through a torn tympanic membrane must be differentiated from a laceration of the external meatus.

Battle's sign:
Bruising over the mastoid may take 24–48 hours to develop.



3. Conscious level

Assess patient's conscious level in terms of *eye opening, verbal and motor response* on admission (see page 5) and record at regular intervals thereafter. An observation chart incorporating these features is essential and clearly shows the trend in the patient's condition. Deterioration in conscious level indicates the need for immediate investigation and action where appropriate.

INSTITUTE OF NEUROLOGICAL SCIENCES, GLASGOW

8GH 172

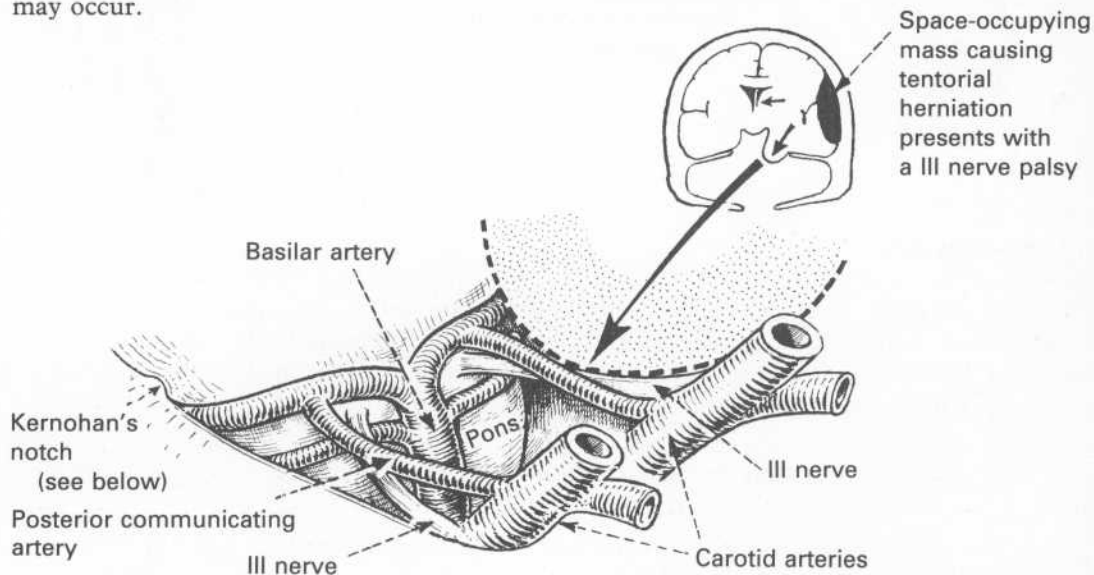
NAME		OBSERVATION CHART																		DATE									
RECORD No.		23/10/83					24/10/83					25/10/83								TIME									
		10	11	12	1	15	14	4	4	5	6	7	8	10	12	2	4	5	8	10	12	2	4	6	8	10	12		
C O M A	Eyes open																												
	Best verbal response																												
	Best motor response																												

Reproduced by permission of the Nursing Times

HEAD INJURY – CLINICAL ASSESSMENT

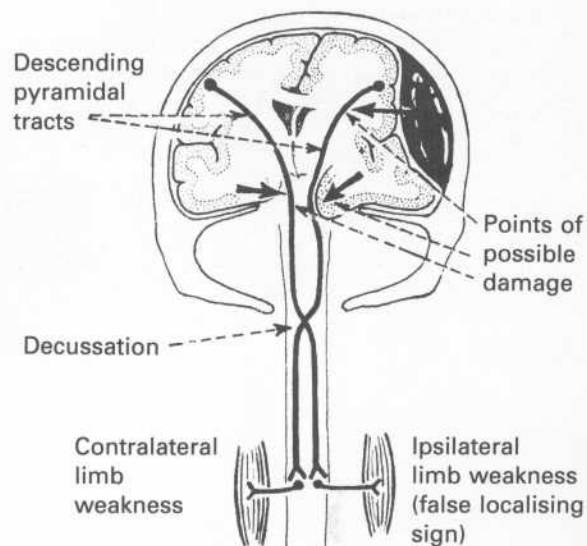
4. Pupil response

The light reflex (page 138) tests optic (II) and oculomotor (III) nerve function. Although II nerve dysfunction after head injury is important to record and may result in permanent visual impairment, it is the III nerve function which is the most useful indicator of an expanding intracranial lesion. Herniation of the medial temporal lobe through the tentorial hiatus directly damages the III nerve resulting in pupil dilatation with impaired or absent reaction to light. The *pupil dilates on the side of the expanding lesion* and is an important localising sign. With a further increase in intracranial pressure, bilateral III nerve palsies may occur.



5. Limb weakness

Determine limb weakness by comparing the response in each limb to painful stimuli (page 30). Hemiparesis or hemiplegia usually occurs in the limbs contralateral to the side of the lesion but may also occur in the ipsilateral limbs. This is due to indentation of the contralateral cerebral peduncle by the edge of the tentorium cerebelli (Kernohan's notch). Limb deficits are therefore of limited value in localising the site of the lesion.

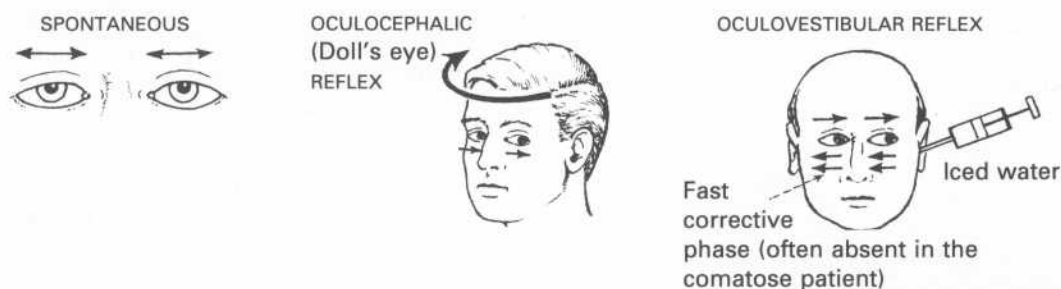


HEAD INJURY – CLINICAL ASSESSMENT

6. Eye movements

Evaluation of eye movements does not help in immediate management, but provides a useful prognostic guide.

Eye movements may occur spontaneously, or can be elicited reflexly (page 30) by head rotation (oculocephalic reflex) or by caloric stimulation (oculovestibular reflex).



Abnormal eye movements may result from: brainstem dysfunction, damage to the nerves supplying the extraocular muscles or damage to the vestibular apparatus. Absent eye movements relate to low levels of responsiveness and indicate a gloomy prognosis.

Vital signs

At the beginning of the century, the eminent neurosurgeon Harvey Cushing noted that a rise in intracranial pressure led to a rise in blood pressure and a fall in pulse rate and produced abnormal respiratory patterns. In the past, much emphasis has been placed on close observation of these vital signs in patients with head injury. These changes, however, may not occur and when present are usually preceded by deterioration in conscious level. This last observation is therefore more relevant.

Cranial nerve lesions

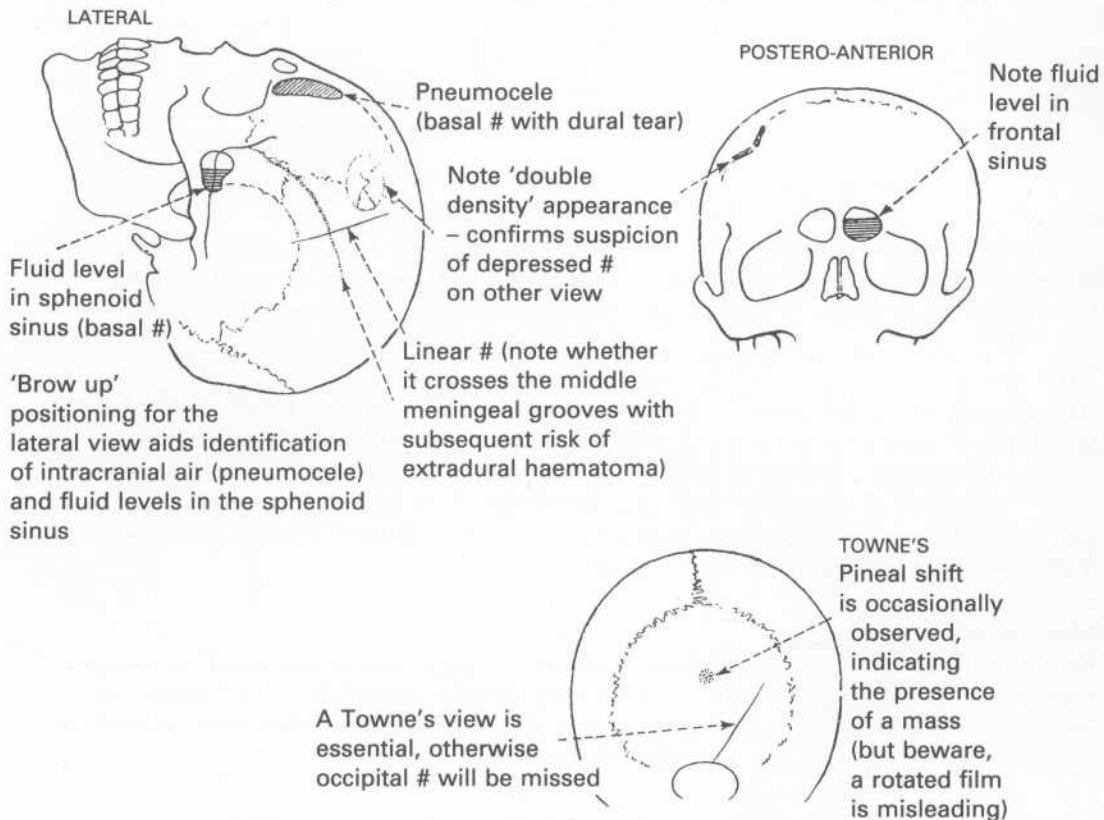
Basal skull fracture or extracranial injury can result in damage to the cranial nerves. Evidence of this damage must be recorded but, with the exception of a III nerve lesion, does not usually help immediate management. Full cranial nerve examination is difficult in the comatose patient and this can await patient co-operation.

Clinical assessment cannot reliably distinguish the type or even the site of intracranial haematoma, but is invaluable in indicating the need for further investigation and in providing a baseline against which any change can be compared.

HEAD INJURY – INVESTIGATION AND ADMISSION CRITERIA

IN THE ACCIDENT AND EMERGENCY DEPARTMENT

- X-ray the skull if:**
- conscious level is impaired at the time of examination or if the patient has lost consciousness at any time since the injury
 - neurological symptoms or signs are present
 - CSF leak from the nose (rhinorrhoea) or ear (otorrhoea)
 - penetrating injury is suspect
 - significant scalp bruising or swelling
 - patient assessment is difficult (e.g. alcohol intoxication).

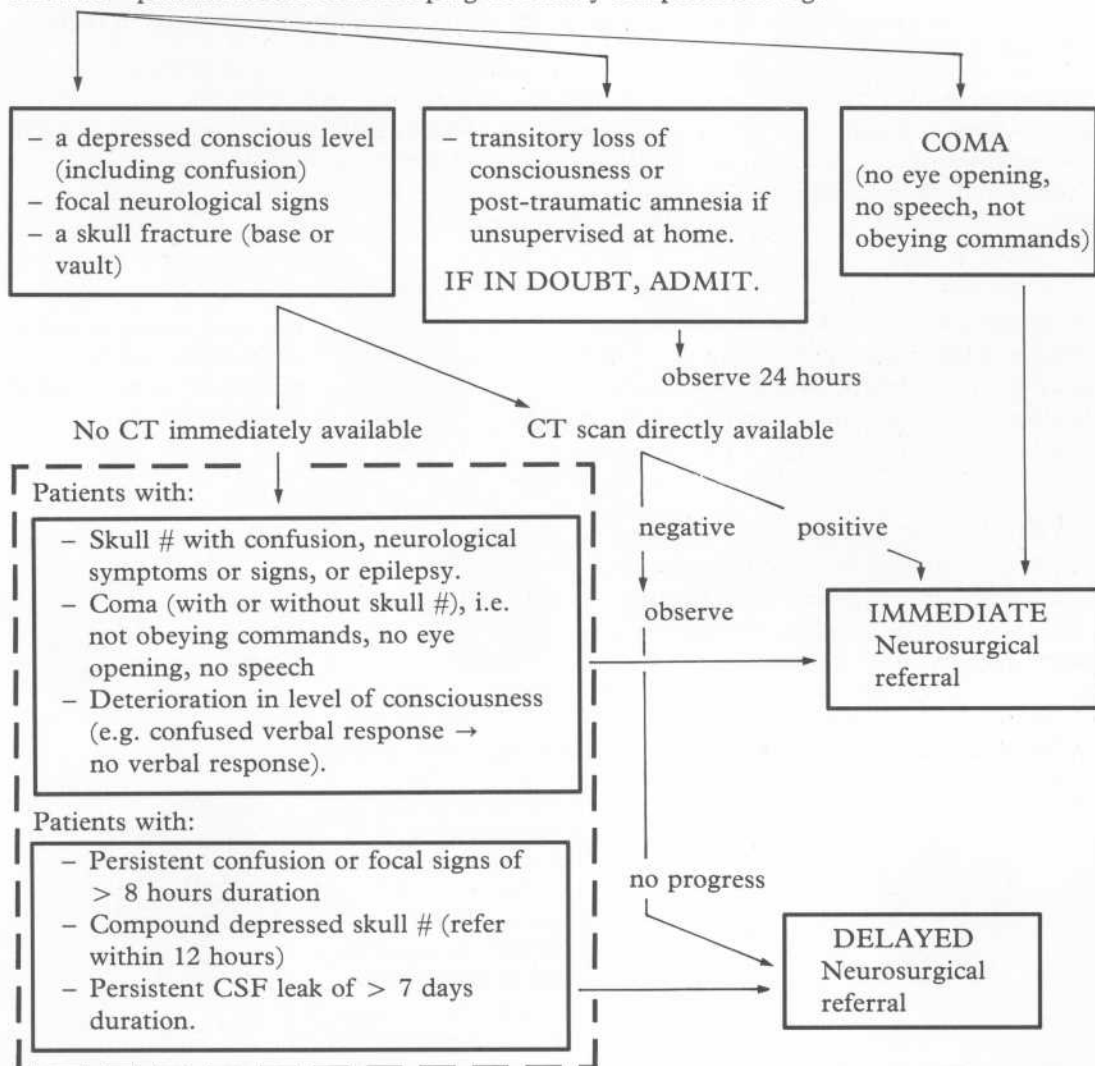


Risk of intracranial haematoma (requiring removal) in adults attending A & E departments after head injury.		
No skull #	– orientated	1 in 6000
No skull #	– not orientated	1 in 120
Skull #	– orientated	1 in 32
Skull #	– not orientated	1 in 4

Adapted with permission Mendelow et al 1983 ii: 1173–1176
British Medical Journal

HEAD INJURY – INVESTIGATION AND ADMISSION CRITERIA

ADMIT patients at risk of developing secondary complications e.g.



Transfer to the neurosurgical unit

Prior to the transfer, ensure that resuscitation is complete, and that more immediate problems have been dealt with (see page 217). Insert an oropharyngeal airway. Intubate and ventilate if the patient is in coma or if the blood gases are inadequate ($PO_2 < 13 \text{ kPa}$ on air, 13 kPa on O_2 or $CO_2 > 6 \text{ kPa}$). If the patient's conscious level is deteriorating, an intravenous bolus infusion of 100 ml of 20% mannitol should 'buy time' by temporarily reducing the intracranial pressure.

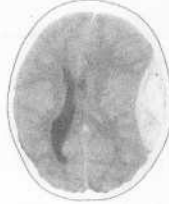NOTE: for comatose patients with an unstable systemic state from multiple injuries, a negative CT scan in the local hospital may avoid a dangerous transfer to the neurosurgical unit.

HEAD INJURY – INVESTIGATION

CT scan in head injury

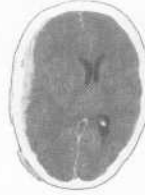Scans must extend from the posterior fossa to the vertex, otherwise haematomas in these sites will be missed.

EXTRADURAL haematoma – area of increased density, convex inwards. Spread limited by dural adhesion to skull



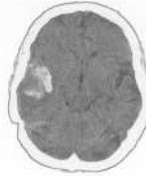Midline shift with compression of ipsilateral ventricle

SUBDURAL haematoma – area of increased density spreading around surface of cerebral hemisphere. Subdural haematomas become isodense with brain 10–20 days following injury and hypodense thereafter.

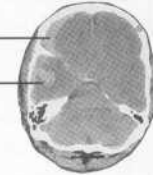

The contralateral ventricle often dilates due to obstruction at the foramen of Munro

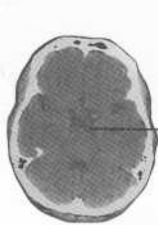INTRACEREBRAL haematoma – ‘BURST LOBE’ (± subdural haematoma) – appears as an irregular area of increased density (blood clot) surrounded by area of low density (oedematous brain).



overlying subdural haematoma
‘Burst’ temporal lobe



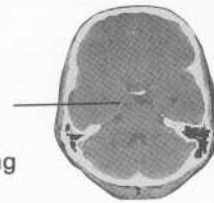
Whether a haematoma is present or not, look at the *basal cisterns*.



NORMAL

Chiasmatic cistern

Obliteration of one or both cisterns indicates raised intracranial pressure with brain shift from an expanding mass or hemispheric swelling



With *diffuse shearing injuries*, small haematomas may be seen on CT scan scattered throughout the white matter, particularly in the corpus callosum or in the superior cerebellar peduncle.

If *hydrocephalus* is present on the upper scan cuts, look carefully for a haematoma (extradural, subdural or intracerebral) in the posterior fossa, compressing and obstructing the 4th ventricle.

In the absence of CT scanning, ANGIOGRAPHY shows displacement of vessels and gives a useful guide to the haematoma site. Failing this, bilateral burr holes are placed in frontal, temporal and parietal sites; even in experienced hands, however, this exploratory approach will miss 30% of intracranial haematomas.

Further investigation may be required to exclude other coincidental or contributory causes of the head injury, e.g. drugs, alcohol, postictal state, encephalitis (Cause of coma, see page 82).

HEAD INJURY – MANAGEMENT

Management aims at preventing the development of secondary brain damage from intracranial haematoma, ischaemia, raised intracranial pressure with tentorial or tonsillar herniation and infection.

- Ensure the *airway is patent* and that *blood oxygenation is adequate*. *Intubation* is advisable in patients 'flexing to pain' or worse. *Ventilation* may be required if respiratory movements are depressed or lung function is impaired, e.g. 'flail' segment, aspiration pneumonia, pulmonary contusion or fat emboli. Hypoxia can cause direct cerebral damage, but in addition causes vasodilatation resulting in an increase in cerebral blood volume with subsequent rise in ICP.
- A *space-occupying haematoma requires urgent evacuation* (see over). If the patient's conscious level is deteriorating, give an initial or repeat i.v. bolus of mannitol (100 ml of 20%). Coagulation should be checked and any deficits corrected.
- Scalp *lacerations* require cleaning, inspection to exclude an underlying depressed fracture and suturing.
- *Correct hypovolaemia* following blood loss – but avoid fluid overload as this may aggravate cerebral oedema. In adults, 2 litres/day of fluid is sufficient. Commence nasogastric fluids or oral fluids when feasible.
- *Anticonvulsants* (e.g. phenytoin) must be given intravenously if seizures occur; further seizures and in particular status epilepticus significantly increase the risk of cerebral anoxia.
- *Monitor intracranial pressure (ICP), blood pressure and cerebral perfusion pressure (CPP)* in selected patients with diffuse swelling or after evacuation of an intracranial haematoma. Maintain CPP either by raising blood pressure or by treating raised intracranial pressure (see below).
- *Brain protective agents* include free radical scavengers, calcium channel blockers and glutamate antagonists. Experimental evidence in animal studies has revealed encouraging results and the evolution of axonal damage after a diffuse shearing injury may provide a window of opportunity for treatment. Studies in head injured patients await completion. (*Steroids*; it is now well established that steroids, even in megadosage, are of no benefit in the management of the head injured patient).
- *Operative repair of a dural defect* is required if the CSF leak persists for more than 7 days. (Many still use *prophylactic antibiotics* in patients with a CSF leak, but there is no conclusive evidence of their efficacy and they may do more harm than good by encouraging the growth of resistant organisms.) The development of meningitis requires prompt treatment with an empirical antibiotic.

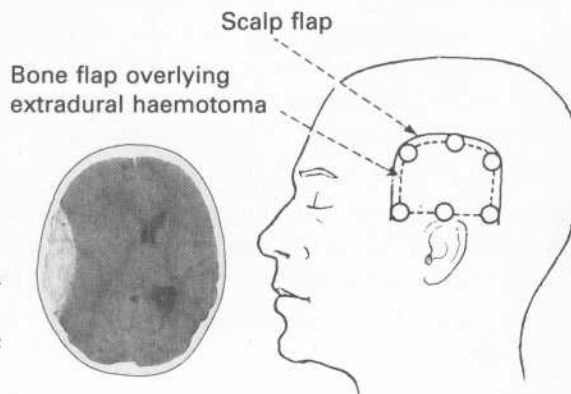
HEAD INJURY – MANAGEMENT

INTRACRANIAL HAEMATOMA

Most intracranial haematomas require urgent evacuation – evident from the patient's clinical state combined with the CT scan appearance of a space-occupying mass.

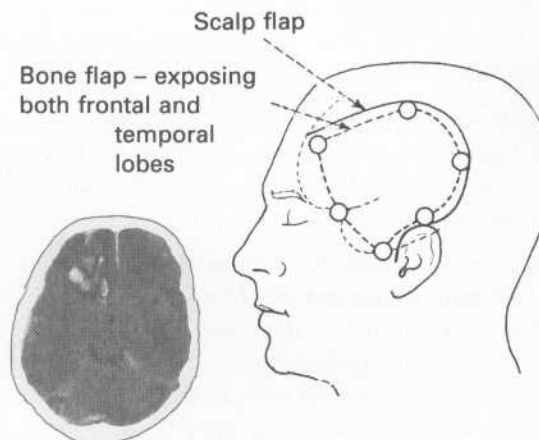
Extradural haematoma

Using the CT scan the position of the extradural haematoma is accurately delineated and a 'horse shoe' craniotomy flap is turned over this area, allowing complete evacuation of the haematoma. For low temporal extradural haematomas, a 'question mark' flap may be more suitable. If patient deterioration is rapid, a burr hole and craniectomy positioned centrally over the haematoma may provide temporary relief, but this seldom provides adequate decompression.



Subdural/intracerebral haematoma ('burst lobe')

Subdural and intracerebral haematomas usually arise from lacerations on the under-surface of the frontal and/or temporal lobes. Again the CT scan is useful in demonstrating the exact site. A 'question mark' flap permits good access to both frontal and temporal 'burst' lobes. The subdural collection is evacuated and any underlying intracerebral haematoma is removed along with necrotic brain. N.B. Burr holes are insufficient to evacuate an acute subdural haematoma or to deal with any underlying cortical damage.



Conservative management of traumatic intracranial haematomas

Not all patients with traumatic intracranial haematomas deteriorate. In some, the haematomas are small and clearly do not require evacuation. In others, however, the decision to operate or not proves difficult, e.g. the CT scan may reveal a moderate-sized haematoma with minimal or no mass effect in a conscious but confused patient.

If conservative management is adopted, careful observation in a neurosurgical unit is essential. Any deterioration indicates the need for immediate operation. In this group of patients, intracranial pressure monitoring may serve as a useful guide. An intracranial pressure of 30 mmHg or more suggests that haematoma evacuation is required as the likelihood of subsequent deterioration with continued conservative management would be high.

HEAD INJURY – MANAGEMENT

THE MAINTENANCE OF CEREBRAL PERFUSION PRESSURE (CPP)

Until recently, too much emphasis was placed on the treatment of raised intracranial pressure (ICP) rather than on the maintenance of the cerebral perfusion pressure (CPP = mean BP - ICP). Raised ICP in the absence of any easily treatable condition (e.g. intracranial haematoma or raised PCO_2) requires careful management. The various techniques used to lower ICP have already been described (pages 79–80) but these must not be applied indiscriminately.

Studies have failed to confirm that active treatment of raised ICP following head injury improves outcome. Failure to show benefit from ICP treatment in the past may have resulted from a 'blind' use of hyperventilation. The vasoconstriction produced by lowering the PCO_2 reduces ICP by reducing intracranial blood volume. But vasoconstriction may reduce cerebral blood flow to ischaemic levels. Only prior measurement of the amount of O_2 taken up by the brain (arteriovenous oxygen difference (AVDO₂)) indicates whether or not neurones can withstand a further reduction in O_2 supply (caused by the vasoconstriction). Provided arterial O_2 saturation remains constant, then the *jugular bulb O_2 saturation* (i.e. O_2 saturation of the venous outflow of the brain (SJvO₂)) can provide this guide. Low SJvO₂ is a contraindication to hyperventilation (see page 80).

Recent studies show that the number of 'insults' (high ICP, low BP or CPP), sustained by patients in the first few days after head injury, adversely affect outcome and *suggest that the CPP is the most important factor*; this should be maintained at more than 70 mmHg.

Patient selection for ICP monitoring: Monitoring ICP and CPP is most relevant in patients with a flexion response or worse to painful stimuli (a response of 'localising to pain' signifies a milder degree of injury and spontaneous recovery is likely). Such patients may have already undergone removal of an intracranial haematoma or may have had no mass lesion on CT scan (i.e. diffuse injury or contusional damage). Each neurosurgical unit is likely to have its own policy for ICP monitoring but the following outline may serve as a guide.

- | | |
|------------------|------------------------------------------------------------------------------------------------------------------------------------------------------------------------------------------------------------------------------------------------------------------------------------------------------------------------------------------------------------------------------------------------------------------|
| CPP low – | <p>ICP high (e.g. > 30 mm Hg)
 & BP low (e.g. mean < 100 mm Hg) → measure central venous pressure (CVP) or insert Swan Ganz catheter.</p> <ul style="list-style-type: none"> – if CVP low → give plasma volume expanders e.g. haemacel (do not use mannitol) – if CVP normal → give inotropic agents (e.g. dobutamine) |
| CPP low – | <p>ICP high,
& BP normal → insert jugular bulb monitor and measure SJvO₂</p> <ul style="list-style-type: none"> – if SJvO₂ normal (60–75%) → give mannitol – if SJvO₂ high (> 75%) → hyperventilate – if SJvO₂ low (< 60%) → give hypnotics e.g. Propofol, Etomidate. (see page 80)
Do not hyperventilate. |

HEAD INJURY – MANAGEMENT

DIFFUSE BRAIN DAMAGE/NEGATIVE CT SCAN

A proportion of patients have no intracranial haematoma on CT scan or have only a small haematoma or contusion causing no mass effect.

In these patients, coma or impairment of conscious level may be due to:

– *diffuse axonal injury* – suspect if no improvement in conscious level from impact.

– *cerebral ischaemic damage*

– *cerebral swelling*

– *fat emboli*

– *meningitis*

} suspect if deterioration is delayed – a patient who talks after impact does not have a significant shearing injury.

Several of these factors may coexist and contribute to brain damage in patients with intracranial haematoma.

The management principles outlined above apply; in particular it is essential to ensure that respiratory function is adequate and that cerebral perfusion pressure is maintained.

Fat emboli usually occur a few days after injury and may be related to fracture manipulation; deterioration of respiratory function usually accompanies cerebral damage and most patients require ventilation.

Meningitis may occur several days after injury in the presence of basal fractures.

Cerebral swelling may occur at any time after injury and cause a rise in intracranial pressure.

REPEAT CT SCANNING

Indications:

Delayed deterioration in clinical state

Maintained rise in ICP

or

Failure to improve after 48 hours

} in patients with diffuse injury or following evacuation of an intracranial haematoma

Occasionally, small areas of 'insignificant' contusion on an initial CT scan may develop into a space-occupying haematoma requiring evacuation. Following haematoma evacuation, recollection may occur in 5–10% of cases.

DEPRESSED SKULL FRACTURE

This injury is caused by a blow from a sharp object. Since diffuse 'deceleration' damage is minimal, patients seldom lose consciousness.

SIMPLE DEPRESSED FRACTURE (closed injury)

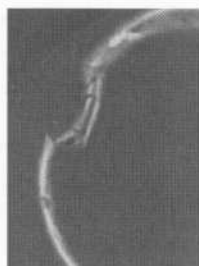There is no overlying laceration and no risk of infection. Operation is not required except for cosmetic reasons. Removal of any bone spicules imbedded in brain tissue does not reverse neuronal damage.

COMPOUND DEPRESSED FRACTURE (open injury)

A scalp laceration is related to (but does not necessarily overlie) the depressed bone segments. Failure to detect a compound depressed fracture with an associated dural tear is likely to result in meningitis or cerebral abscess.

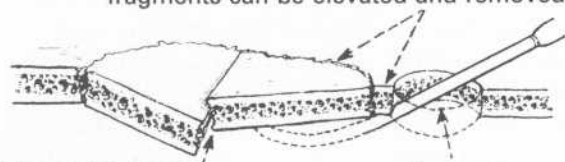
Investigation

Double density appearance on *skull X-ray* suggests depression but tangential views may be required to establish the diagnosis. Impairment of conscious level or the presence of focal signs indicate the need for a *CT scan* to exclude underlying extradural haematoma or severe cortical contusion. Selecting bone window levels on CT scan will clearly demonstrate any depressed fragments.



'Bony' window levels on CT scan clearly demonstrate the depressed fragments

Management Bone edges nibbled away until fragments can be elevated and removed.



Underlying dural tears may be stitched or patched with pericranium

Burr hole at edge of depression

Treatment aims to minimise the risk of infection. The wound is debrided and the fragments elevated within 24 hours from injury. Bone fragments are either removed or replaced after washing with antiseptic. Antibiotics are not essential unless the wound is excessively dirty.

If the venous sinuses are involved in the depressed fracture, then operative risks from excessive bleeding may outweigh the risk of infection and antibiotic treatment alone is given.

Complications

Most patients make a rapid and full recovery, but a few develop complications:

Infection occurs when treatment is delayed, or debridement inadequate, and may lead to meningitis or abscess formation.

Epilepsy: Early epilepsy (in the first week) occurs in 10% of patients with depressed fracture. Late epilepsy develops in 15% overall, but is especially common when the dura is torn, when focal signs are present, when post-traumatic amnesia exceeds 24 hours or when early epilepsy has occurred (the risk ranges from 3 to over 60%, depending on the number of the above factors involved). Elevation of the bone fragments does not alter the incidence of epilepsy.

DELAYED EFFECTS OF HEAD INJURY

POST-TRAUMATIC EPILEPSY

Early epilepsy (occurring within the first week from injury)

Early epilepsy occurs in 5% of patients admitted to hospital with non-missile (i.e. deceleration) injuries. It is particularly frequent in the first 24 hours after injury. Focal seizures are as common as generalised seizures. Status epilepticus occurs in 10%.

The risk of early epilepsy is high in

- children under 5 years.
- patients with prolonged post-traumatic amnesia
- patients with an intracranial haematoma
- patients with a compound depressed fracture.

Late epilepsy (occurring after the first week from injury)

Late epilepsy also occurs in about 5% of all patients admitted to hospital after head injury. It usually presents in the first year, but in some the first attack occurs as long as 10 years from the injury. Usually seizures are generalised, but temporal lobe epilepsy (complex partial seizures) occurs in 20%. Late epilepsy is prevalent in patients with

- early epilepsy (25%)
- intracranial haematoma (35%)
- compound depressed fracture (17%).

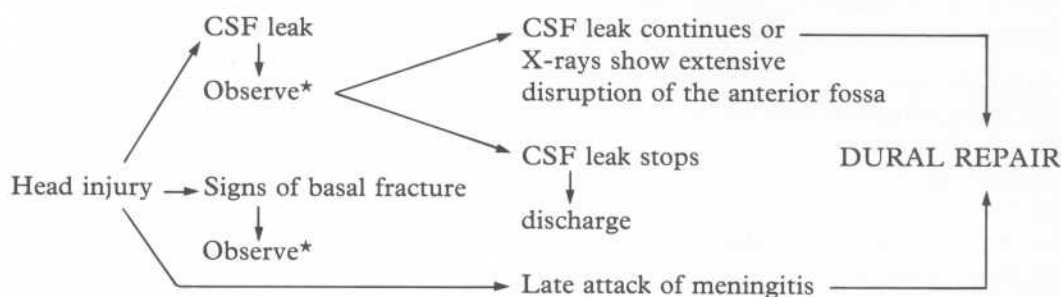
Prophylactic anticonvulsants appear to be of little benefit in preventing the development of an epileptogenic focus. Management is discussed on page 98.

CEREBROSPINAL FLUID (CSF) LEAK

After head injury a basal fracture may cause a fistulous communication between the CSF space and the paranasal sinuses or the middle ear. Profuse CSF leaks (rhinorrhoea or otorrhoea) are readily detectable, but brain may partially plug the defect and the leak may be minimal or absent. Patients risk developing meningitis particularly in the first week, but in some this occurs after several years. When this is associated with anterior fossa fractures, it is usually pneumococcal; when associated with fractures through the petrous bone, a variety of organisms may be involved.

Clinical signs of a basal fracture have previously been described (page 218). The patient may comment on a 'salty taste' in the mouth. Anosmia suggests avulsion of the olfactory bulb from the cribriform plate.

Management



* A recent Working Party concluded that evidence does not support the use of prophylactic antibiotics (Lancet (1994) 344:1547-1551). Prophylactic antibiotics only encourage resistance and late attacks of meningitis may still occur despite their use.

DELAYED EFFECTS OF HEAD INJURY

CSF LEAK (*contd*)

Preoperative investigations

Coronal high definition CT scanning should identify the fracture site.

CT cisternography – CT scanning after running contrast injected into the lumbar theca, up to the basal cisterns may identify the exact site of the leak.

CSF isotope infusion studies combined with pledget insertion into the nasal recesses may also be of value, but results can be misleading.

Operation

As fractures of the anterior fossa often extend across the midline, a bifrontal exploration is required. The dural tear is repaired with fascia lata, pericranium or synthetic dural substitute. A CSF leak through the middle ear requires a subtemporal approach.

Failure to repair a CSF fistula may result from impaired CSF absorption with an intermittent or persistent elevation of ICP. In these patients a CSF shunt may be required.

POSTCONCUSSIONAL SYMPTOMS

Even after relatively minor head injury, patients may have persistent symptoms of:

- headache, dizziness and increased irritability
- difficulty in concentration and in coping with work
- fatigue and depression.

This condition was once thought to have a purely psychological basis, but it is now recognised that in an injury of sufficient severity to cause loss of consciousness, or a period of post-traumatic amnesia, some neuronal damage occurs; studies show a distinct delay in information processing in these patients, requiring several weeks to resolve. Vestibular 'concussion' (end-organ damage) may contribute to the symptomatology ('dizziness' and vertigo).

CUMULATIVE BRAIN DAMAGE

The effects of repeated neuronal damage are cumulative; when this exceeds the capacity for compensation, permanent evidence of brain damage ensues. The 'punch-drunk' state is well recognised in boxers; dementia may also occur from repeated head injury in jockeys.

DELAYED EFFECTS OF HEAD INJURY

CRANIAL NERVE DAMAGE

Cranial nerve damage occurs in about one-third of patients with severe head injury, but treatment is seldom of benefit. These lesions may contribute towards the patient's residual disability.

Nerve	Cause of damage	Clinical problem	Management	Prognosis
I	Usually associated with anterior fossa fracture and CSF rhinorrhoea	Anosmia	Nil	Recovery often occurs in a few months
II	Optic nerve usually damaged in the optic foramen Chiasmatal damage occasionally occurs. [N.B. Visual loss may also occur from damage to the globe, occipital cortex or optic radiations]	Visual loss or field defect in one eye Bitemporal hemianopia.	Nil Local eye/orbital damage may need treatment	Recovery seldom occurs
III IV VI	III nerve damage usually results from tentorial herniation but can also occur in fractures involving the superior orbital fissure or cavernous sinus IV nerve damage is uncommon VI nerve damage is usually associated with fractures of the petrous or sphenoid bones	Pupil inequality, ptosis and disturbance of ocular movements	Nil [other than removing cause of tentorial herniation]	Recovery usually occurs
V	Occasionally follows petrous or sphenoid fractures	Facial numbness	Nil	Usually permanent
VII	Associated with petrous fracture	Immediate or delayed facial palsy	Otologists occasionally recommend decompression. Early steroid therapy may benefit	Immediate lesions have a poor prognosis; delayed lesions usually recover
VIII	Petrous fracture may damage: - nerve - cochlea - ossicles Haemotympanum may result	Vertigo, 'dizziness', hearing loss, tinnitus	Ossicular damage may benefit from operation	Vestibular symptoms usually improve after several weeks. Nerve deafness is usually permanent. Conductive deafness from haemotympanum should gradually improve
IX, X XI, XII	Associated with very severe basal fractures or extracranial injury	Patient seldom survives primary damage		

DELAYED EFFECTS OF HEAD INJURY

OUTCOME AFTER SEVERE HEAD INJURY

Head injury remains a major cause of disability and death, especially in the young. Of those patients who survive the initial impact and remain in coma for at least 6 hours, approximately 40% die within 6 months. The extent of recovery in the remainder depends on the severity of the injury. Residual disabilities include both mental (impaired intellect, memory and behavioural problems) and physical defects (hemiparesis and dysphasia). Most recovery occurs within the first 6 months after injury, but improvement may continue for years. *Physiotherapy* and *occupational therapy* play an important role not only in minimising contractures and improving limb power and function but also in stimulating patient motivation.

Outcome is best categorised with the *Glasgow Outcome Scale* (GOS – see page 210) which uses *dependence* to differentiate between intermediate grades. After severe injury, about 40% regain an independent existence and may return to premorbid social and occupational activities. Inevitably some remain severely disabled requiring long term care, but few (<2%) are left in a vegetative state with no awareness or ability to communicate with their environment (see page 210). Prognosis in this group is marginally better than for non-traumatic coma – with about 1/3 of those vegetative at *one month* regaining consciousness within one year; of those who regain consciousness, over 2/3 either subsequently die or remain severely disabled. Of those vegetative at *3 months* after the injury, none regain an independent existence.

Prognostic features following traumatic coma

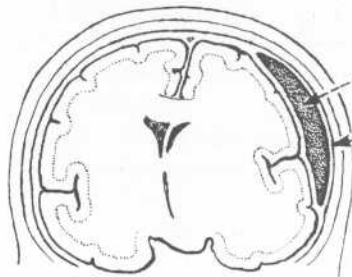
The duration of coma relates closely to the severity of injury and to the final outcome, but in the early stages after injury the clinician must rely on other features – age, eye opening, verbal and motor responses, pupil response and eye movements.

	Poor outcome (GOS 1-3)	Favourable outcome (GOS 4-5)
Patients in coma for > 6 hours	61%	39%
Best <i>Glasgow Coma Score</i> > 11	18%	82%
Best <i>Glasgow Coma Score</i> 8-10	32%	68%
Best <i>Glasgow Coma Score</i> < 8	73%	27%
<i>Pupillary response</i> – reacting	50%	50%
<i>Pupillary response</i> – non-reacting	96%	4%
<i>Age</i> < 20 years	41%	59%
<i>Age</i> > 60 years	94%	6%

(from Jennett.B, Teasdale.G, Braakman.R et al. (1979) *Neurosurgery* 4:283-289)

CHRONIC SUBDURAL HAEMATOMA

Subdivision of subdural haematomas into acute and subacute forms serves no practical purpose. Chronic subdural haematoma however is best considered as a separate entity, differing both in presentation and management.



Chronic subdural haematoma – fluid may range from a faint yellow to a dark brown colour

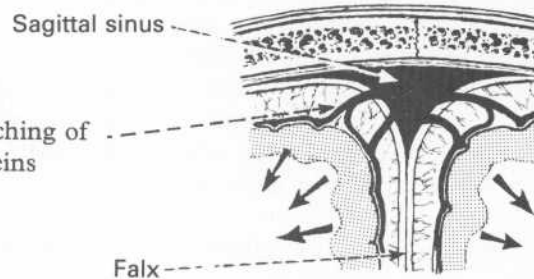
A membrane grows out from the dura to envelop the haematoma

Chronic subdural haematomas occur predominantly in *infancy* and in the *elderly*. Trauma is the likely cause, although a history of this is not always obtained.

Predisposing factors

- Cerebral atrophy
- Low CSF pressure (after a shunt or fistula)
- Alcoholism
- Coagulation disorder

} cause stretching of bridging veins



Breakdown of protein within the haematoma and a subsequent rise in osmotic pressure was originally believed to account for the gradual enlargement of the untreated subdural haematoma. Studies showing equality of osmotic pressures in blood and haematoma fluid cast doubt on this theory and recurrent bleeding into the cavity is now known to play an important role.

Clinical features tend to be non-specific.

- Dementia.
- Deterioration in conscious level, occasionally with fluctuating course.
- Symptoms and signs of raised ICP.
- Focal signs occasionally occur, especially limb weakness. This may be ipsilateral to the side of the lesion, i.e. a false localising sign (see page 220).

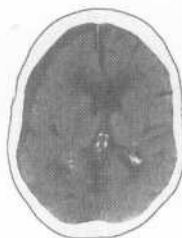CHRONIC SUBDURAL HAEMATOMA

Diagnosis

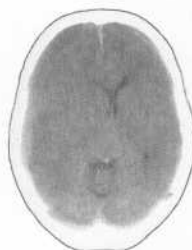CT Scan appearances depend on the time between the injury and the scan.

With injuries 1–3 weeks old, the subdural haematoma may be isodense with brain tissue. In this instance, i.v contrast enhancement may delineate the cortical margin.

Beyond 3 weeks subdural haematomas appear as a low density lesion.



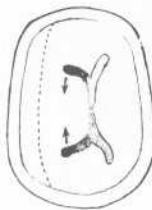
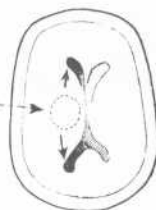
Injury > 3 weeks old: low density lesion seen over hemisphere convexity.



Isodense lesion causing midline shift. Note the shape of the ventricles.

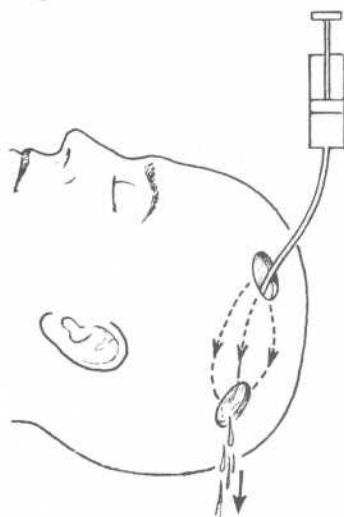
If CT scan shows midline shift without any obvious extra- or intracerebral lesion, look at the shape of the ventricles.

Separation of the frontal and occipital horns suggests an intrinsic lesion, e.g. encephalitis rather than a surface collection



Extracerebral collection, i.e. chronic subdural haematoma, causes approximation of frontal and occipital horns

Management



Adult

The haematoma is evacuated through two or three burr holes and the cavity is irrigated with saline. Drains may be left in the subdural space and nursing in the head-down position may help prevent recollection.

Craniotomy with excision of the membrane is seldom required.

In patients who have no depressed conscious level, conservative treatment with steroids over several weeks may result in resolution.

Infants

The haematoma is evacuated by repeated needle aspiration through the anterior fontanelle. Persistent subdural collections require a subdural peritoneal shunt. As in adults, craniotomy is seldom necessary.

CEREBROVASCULAR DISEASES

Vascular diseases of the nervous system are amongst the most frequent causes of admission to hospital. The annual incidence in the UK varies regionally between 150–200/100 000, with a prevalence of 600/100 000 of which $\frac{1}{3}$ are severely disabled.

Better control of hypertension, reduced incidence of heart disease and a greater awareness of all risk factors have combined to reduce mortality from stroke. Despite this, stroke still ranks third behind heart disease and cancer as a cause of death in affluent societies.

RISK FACTORS

Prevention of cerebrovascular disease is more likely to reduce death and disability than any medical or surgical advance in management. Prevention depends upon the identification of risk factors and their correction.

Hypertension

Hypertension is a major factor in the development of thrombotic cerebral infarction and intracranial haemorrhage.

There is no critical blood pressure level; the risk is related to the height of blood pressure and increases throughout the whole range from normal to hypertensive. A 6 mm Hg fall in diastolic blood pressure is associated in relative terms with a 40% fall in the fatal and non-fatal stroke rate.

Systolic hypertension (frequent in the elderly) is also a significant factor and not as harmless as previously thought.

Cardiac disease

Cardiac enlargement, failure and arrhythmias, as well as rheumatic heart disease, mitral valve prolapse and, rarely, cardiac myxoma are all associated with an increased risk of stroke.

Diabetes

The risk of cerebral infarction is increased twofold in diabetes. More effective treatment of diabetes has not reduced the frequency of atherosclerotic sequelae.

Heredity

Close relatives are at only slightly greater risk than non-genetically related family members of a stroke patient. Diabetes and hypertension show familial propensity thus clouding the significance of pure hereditary factors.

Blood lipids, cholesterol, smoking, diet/obesity, soft water

These factors are much less significant than in the genesis of coronary artery disease.

Race

Alterations in life style, diet and environment probably explain the geographical variations more than racial tendencies.

Haematocrit

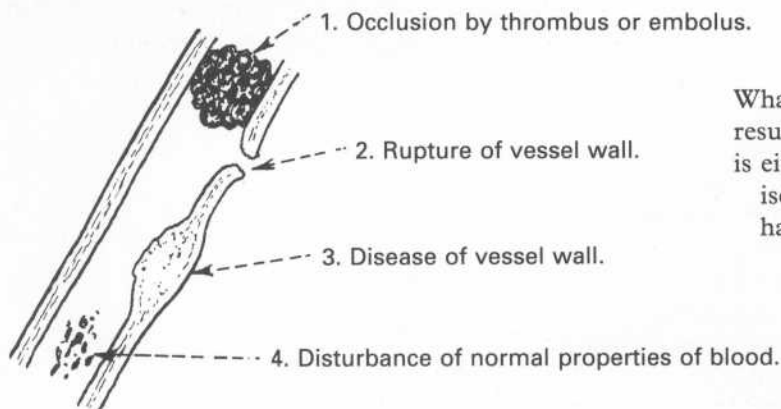
A high blood haemoglobin concentration (or haematocrit level) is associated with an increased incidence of cerebral infarction. Other haematological factors, such as decreased fibrinolysis, are important also.

Oral contraceptives

The evidence of pill-related stroke is inconclusive. A recent prospective study has suggested an increased risk of subarachnoid haemorrhage rather than thromboembolic stroke.

CEREBROVASCULAR DISEASE – MECHANISMS

'Stroke' is a generic term, lacking pathological meaning. Cerebrovascular diseases can be defined as those in which brain disease occurs secondary to a pathological disorder of blood vessels (usually arteries) or blood supply.



Whatever the mechanism, the resultant effect on the brain is either:

ischaemia/infarction, or
haemorrhagic disruption.

Of all strokes: – 85% are due to INFARCTION
– 15% are due to HAEMORRHAGE

CEREBROVASCULAR DISEASE – NATURAL HISTORY

Approximately one-third of all 'strokes' are fatal. The age of the patient, the anatomical size of the lesion, the degree of deficit and the underlying cause all influence the outcome.

Immediate outcome

In cerebral haemorrhage, mortality approaches 70%.

Cerebral infarction fares better, with an immediate mortality of less than 25%, fatal lesions being large with associated oedema and brain shift.

Embolic infarction carries a better outcome than thrombotic infarction.

Fatal cases of infarction die either at onset or else, more commonly, after the first week from cardiovascular or respiratory complications.

The level of consciousness on admission to hospital gives a good indication to immediate outcome. The deeper the conscious level the graver the prognosis.

Long-term outcome

The prognosis following infarction due to thrombosis or embolisation from diseased neck vessels or heart is dependent on the progression of the underlying atherosclerotic disease. Recurrent cerebral infarction rates vary between 5%–15% per year. Symptoms of coronary artery disease and/or peripheral vascular disease may also ensue. Five year mortality is 44% for males and 36% for females.


The long-term prognosis following survival from haemorrhage depends upon the cause and the treatment.

CEREBROVASCULAR DISEASE – CAUSES

OCCLUSION (50%)

Atheromatous/thrombotic

1. Large vessel occlusion or stenosis (e.g. carotid artery)



2. Branch vessel occlusion or stenosis (e.g. middle cerebral artery)

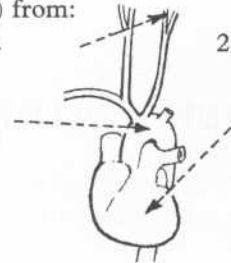
3. Perforating vessel occlusion (lacunar infarction)

Non-atheromatous diseases of the vessel wall

1. Collagen disease e.g. rheumatoid arthritis
systemic lupus erythematosus (SLE)
2. Vasculitis e.g. polyarteritis nodosa
temporal arteritis
3. Granulomatous vasculitis e.g. Wegener's granulomatosis
4. Miscellaneous e.g. syphilitic vasculitis
fibromuscular dysplasia
sarcoidosis
trauma

EMBOLISATION (25%) from:

1. Atheromatous plaque in the intracranial or extracranial arteries or from the aortic arch.



2. The heart:

- valvular heart disease
- arrhythmias
- ischaemic heart disease
- bacterial and non-bacterial endocarditis
- atrial myxoma
- prosthetic valves
- patent foramen ovale
- cardiomyopathy

3. Miscellaneous:

- fat emboli
- air emboli
- tumour emboli.

DISEASES OF BLOOD

e.g. Coagulopathies
Haemoglobinopathies

VENOUS THROMBOSIS

Venous thrombosis may occur with infection and dehydration or in association with arterial occlusion when related to oestrogen excess.

DECREASED CEREBRAL PERFUSION

Infarction between arterial territories may result from impaired perfusion from e.g. cardiac dysrhythmia
G I blood loss

HAEMORRHAGE (20%)

Into the brain substance – parenchymal (15%)
and/or subarachnoid space (5%)

Hypertension

Amyloid vasculopathy

Aneurysm

Arteriovenous malformation

Neoplasm

Coagulation disorder e.g. haemophilia

Anticoagulant therapy

Vasculitis

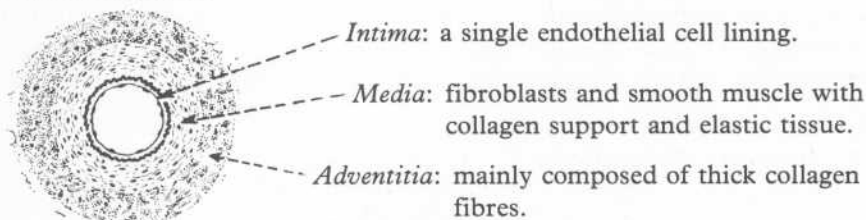
Drug abuse e.g. cocaine

Trauma

OCCLUSIVE AND STENOTIC CEREBROVASCULAR DISEASE

PATHOLOGY

The normal vessel wall comprises:



Within brain and spinal cord tissue the adventitia is usually very thin and the elastic lamina between media and adventitia less apparent.

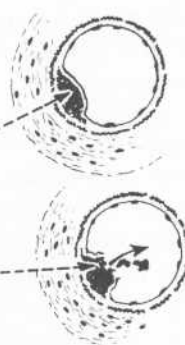The intima is an important barrier to leakage of blood and constituents into the vessel wall. In the development of the atherosclerotic plaque, damage to the endothelium of the intima is the primary event.

The atherosclerotic plaque

Following intimal damage:

- Intimal cells
- Smooth muscle cells laden with cholesterol, lipids, phospholipids
- Collagen and elastic fibres

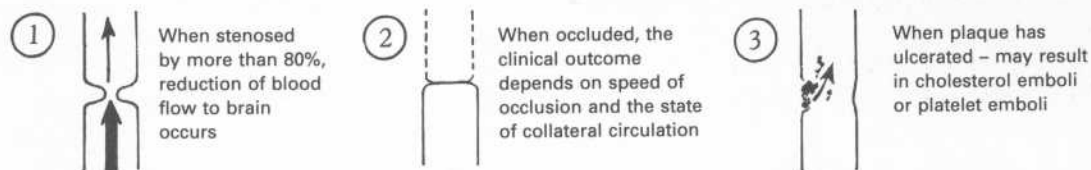
build up subintimally.



Haemorrhage may occur within the plaque or the plaque may ulcerate into the lumen of the vessel forming an intraluminal mural thrombus. Either way, the lumen of the involved vessel is narrowed (stenosed) or blocked (occluded).

The plaque itself may give rise to emboli. Cholesterol is present partly in crystal form and fragments following plaque rupture may be sufficiently large to occlude the lumen of distal vessels. The cholesterol esters, lipids and phospholipids each play a role in the aggregation of such emboli.

The carotid bifurcation in the neck is a frequent site at which the atheromatous plaque causes stenosis or occlusion.



Platelet emboli arise from thrombus developed over the damaged endothelium. This thrombus is produced partly by platelets coming into contact with exposed collagen fibres. Endothelial cells synthesise PROSTACYCLIN which is a potent vasodilator and inhibitor of platelet aggregation. THROMBOXANE A₂, synthesised by platelets, has opposite effects. In thrombus formation these two PROSTAGLANDINS actively compete with each other.

CEREBROVASCULAR DISEASE – PATHOPHYSIOLOGY

Standard techniques of cerebral blood flow (CBF) measurement provide information on both global and regional flow in patients with cerebral ischaemia or infarction. Recent availability of positron emission tomography (PET), recording oxygen and glucose metabolism, as well as blood flow and blood volume, gives a more detailed and accurate understanding of pathophysiological changes after stroke.

Changes in cerebral infarction

NON-ISCHAEMIC HEMISPHERE

Mild reduction in global CBF – perhaps due to transneuronal depression of metabolism in the unaffected hemisphere – diaschisis.

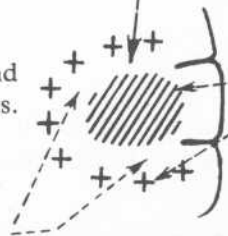
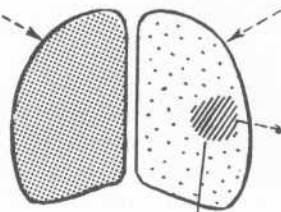
In the normal brain, cerebral blood flow to a particular part varies depending on the metabolic requirements, i.e. the supply of O₂ and glucose is 'coupled' to the tissue needs. After infarction, between areas of reduced flow and areas of luxury perfusion, lie areas of *relative luxury perfusion* where reduced flow exceeds the tissue requirements, i.e. 'uncoupling' of flow and metabolism has occurred.

Studies with SPECT imaging suggest that 40% of infarcts are reperfused with blood within 48 hrs.

ISCHAEMIC HEMISPHERE

Reduction in global CBF

In the infarcted area and its surroundings, more subtle changes of regional cerebral blood flow (rCBF) are detected.



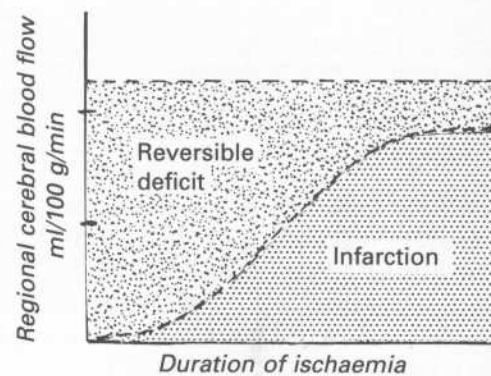
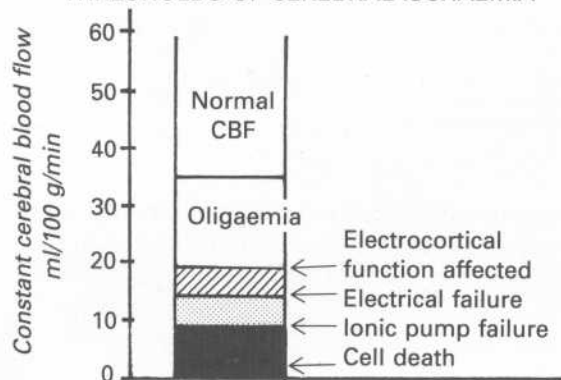
Areas of *reduced flow* are bordered by areas of increased flow – *luxury perfusion* – due to vasodilatation of arteriolar bed in response to lactic acidosis.

These changes in rCBF are transient and revert to normal within days of the onset. The degree of disturbance of rCBF correlates with outcome. Flow of < 28 ml/min/100g results in the development of the morphological changes of infarction.

Pathophysiology of ischaemia

Progression from *reversible ischaemia* to infarction depends upon the *degree* and *duration* of the reduced blood flow.

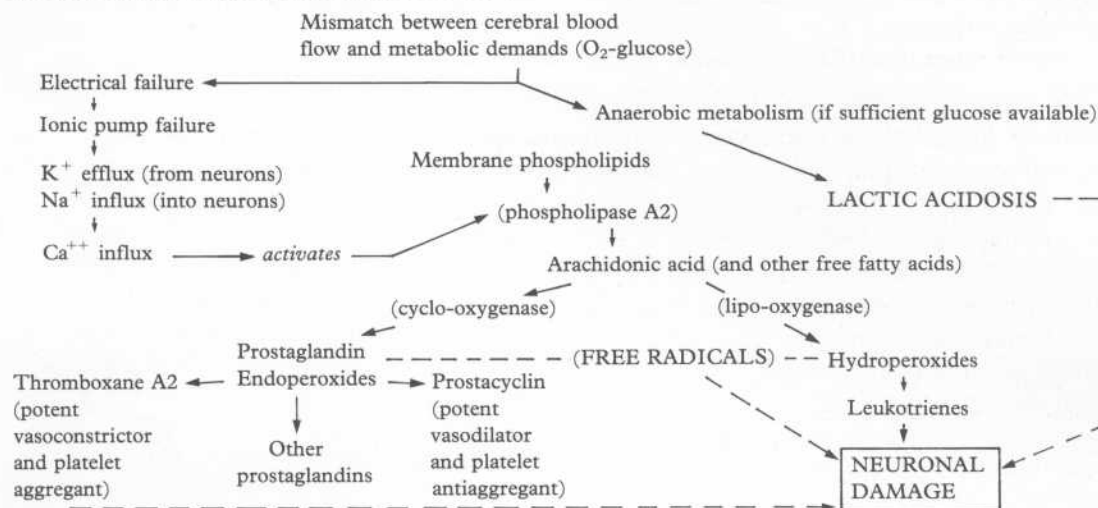
THRESHOLDS OF CEREBRAL ISCHAEMIA



CEREBROVASCULAR DISEASE – PATHOPHYSIOLOGY

Ischaemic cascade

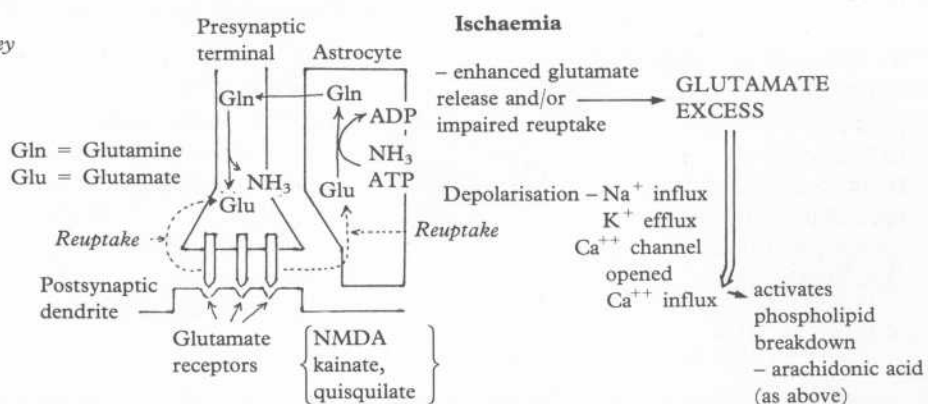
A significant fall in cerebral blood flow produces a cascade of events which, if unchecked, lead to the production and accumulation of toxic compounds and cell death.



Role of neurotransmitters

Recent research has shown that one of the amino acid excitatory neurotransmitters, Glutamate, in *excess* is a powerful neurotoxin, playing an important role in ischaemic brain damage.

(Adapted from Rothman & Olney 1986 *Annals of Neurology* 19:105-111)



Therapeutic implications

Identification of harmful neurotransmitters and of the pathways involved in the ischaemic cascade has led to a surge of interest in *brain protective agents* –

Ca⁺⁺ antagonists: studies of Nimodipine in patients with SAH have shown a significant reduction in ischaemic complications. This drug acts by opening up the collateral circulation and by blocking Ca⁺⁺ influx. There is limited evidence of efficacy in acute infarction

Glutamate antagonists (e.g. NMDA antagonist – ‘MK801’, CGS 1975S): significantly reduces ischaemia in animal studies. Toxicity may limit clinical trials.

Barbiturates: these reduce cerebral metabolism, thereby reducing neuronal requirements. They also block free radical production. The dosage required to lower metabolism produces significant hypotension and benefits remain unproven.

Free radical scavengers: Early studies suggest that these agents may produce some benefit in reducing ischaemia.

TRANSIENT ISCHAEMIC ATTACKS (TIA'S)

Transient ischaemic attacks are episodes of focal neurological symptoms due to inadequate blood supply to the brain. Attacks are sudden in onset, resolve within 24 hours or less and leave no residual deficit. These attacks are important as warning episodes or precursors of cerebral infarction.

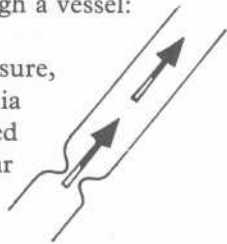
Before diagnosing TIA's, consider other causes of transient neurological dysfunction – migraine, partial seizures, hypoglycaemia, syncope and hyperventilation.

The pathogenesis of transient ischaemic attacks

A reduction of cerebral blood flow below 20–30 ml 100 g/min produces neurological symptoms. The development of infarction is a consequence of the *degree* of reduced flow and the *duration* of such a reduction. If flow is restored to an area of brain within the critical period, ischaemic symptoms will reverse themselves. TIAs may be due to:

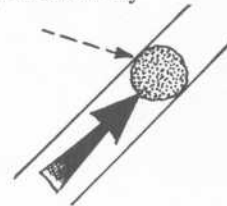
1. Reduced flow through a vessel:

a fall in perfusion pressure, e.g. cardiac dysrhythmia associated with localised stenotic cerebrovascular disease



2. Blockage of the passage of flow by embolism:

arising from plaques in aortic arch/extracranial vessels or from the heart



– the *haemodynamic* explanation.

– the *embolic* explanation.

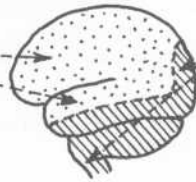
Both mechanisms occur. Emboli are accepted as the cause of the majority of TIAs.

The symptomatology of TIAs

Anterior (90%)

Carotid territory

hemiparesis,
hemisensory disturbance,
dysphasia,
monocular blindness
(amaurosis fugax)



Posterior (7%)

Vertebrobasilar territory

loss of consciousness
bilateral limb motor/sensory
dysfunction
binocular blindness
vertigo, tinnitus,
diplopia, dysarthria

} not singly, but in
combination
with each other

A small number of transient ischaemic attacks are difficult to fit convincingly into either anterior or posterior circulation, e.g. dysarthria with hemiparesis.

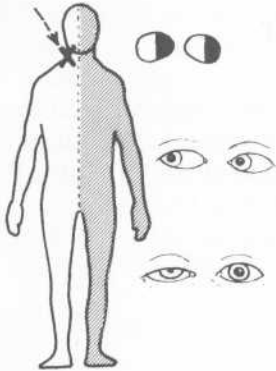
The natural history of TIAs

Following a TIA, between 5–10% of patients will develop infarction in each year of follow-up, irrespective of the territory involved. The risk of infarction is probably at its greatest in the first 3–6 months after the initial TIA. Not all patients who develop cerebral infarction have had a warning TIA.

CLINICAL SYNDROMES – LARGE VESSEL OCCLUSION

OCCLUSION OF THE INTERNAL CAROTID ARTERY – may present in a ‘stuttering’ manner due to progressive narrowing of the lumen or recurrent emboli.

The degree of deficit varies – occlusion may be asymptomatic and identified only at autopsy, or a catastrophic infarction may result.



In the most extreme cases there may be:

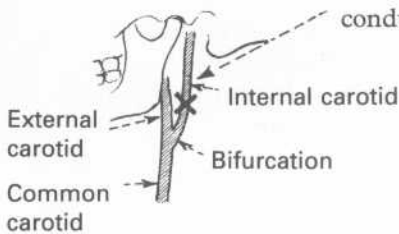
- Deterioration of conscious level
- Homonymous hemianopia of the contralateral side
- Contralateral hemiplegia
- Contralateral hemisensory disturbance
- Gaze palsy to the opposite side – eyes deviated to the side of the lesion

A partial Horner’s syndrome may develop on the side of the occlusion (involvement of sympathetic fibres on the internal carotid wall).

Occlusion of the dominant hemisphere side will result in a global aphasia.

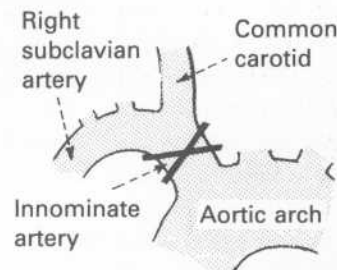
Examination of the neck will reveal:

Absent carotid pulsation at the angle of the jaw with poorly conducted heart sounds along the internal carotid artery.

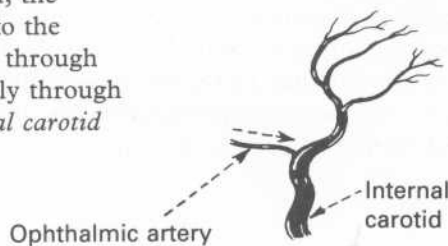


Prodromal symptoms prior to occlusion may take the form of monocular blindness – AMAUROSIS FUGAX and transient hemisensory or hemimotor disturbance (see page 253).

The origins of the vessels from the aortic arch are such that an *innominate artery occlusion* will result not only in the clinical picture of carotid occlusion but will produce diminished blood flow and hence blood pressure in the right arm.



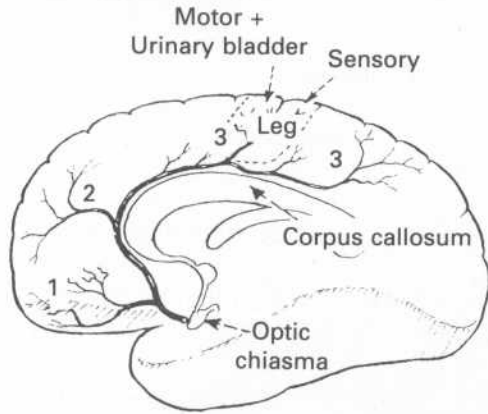
The outcome of carotid occlusion depends on the collateral blood supply primarily from the circle of Willis, but, in addition, the external carotid may provide flow to the *anterior and middle cerebral arteries* through meningeal branches and retrogradely through the ophthalmic artery to the *internal carotid artery*.



CLINICAL SYNDROMES – LARGE VESSEL OCCLUSION

ANTERIOR CEREBRAL ARTERY

Anatomy



Medial surface of right cerebral hemisphere

The anterior cerebral artery is a branch of the internal carotid and runs above the optic nerve to follow the curve of the corpus callosum. Soon after its origin the vessel is joined by the anterior communicating artery. Deep branches pass to the anterior part of the internal capsule and basal nuclei.

Cortical branches supply the medial surface of the hemisphere:

1. Orbital
2. Frontal
3. Parietal

Clinical features

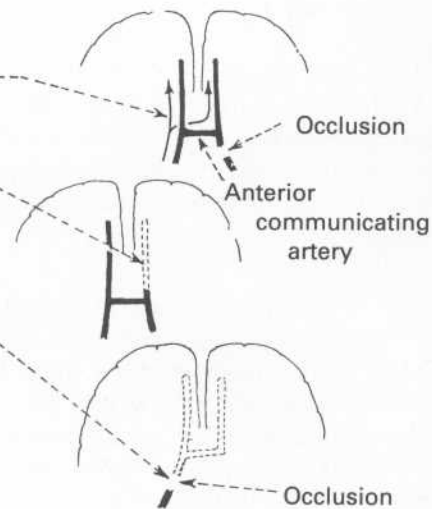
The anterior cerebral artery may be occluded by embolus or thrombus. The clinical picture depends on the site of occlusion (especially in relation to the anterior communicating artery) and anatomical variation, e.g. both anterior cerebral arteries may arise from one side by enlargement of the anterior communicating artery.

Occlusion proximal to the anterior communicating artery is normally well tolerated because of the cross flow.

Distal occlusion results in weakness and cortical sensory loss in the contralateral lower limb with associated incontinence. Occasionally a contralateral grasp reflex is present.

Proximal occlusion when both anterior cerebral vessels arise from the same side results in 'cerebral' paraplegia with lower limb weakness, sensory loss, incontinence and presence of grasp, snout and palmomentar reflexes.

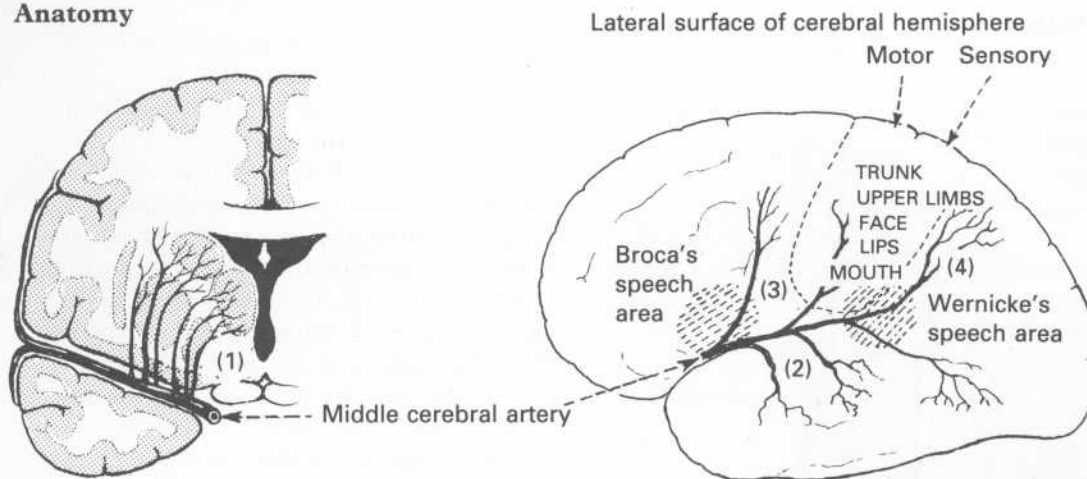
Bilateral frontal lobe infarction may result in *akinetic mutism* (page 107) or deterioration in conscious level.



CLINICAL SYNDROMES – LARGE VESSEL OCCLUSION

MIDDLE CEREBRAL ARTERY

Anatomy



The middle cerebral artery is the largest branch of the internal carotid artery. It gives off (1) deep branches (perforating vessels – lenticulostriate) which supply the anterior limb of the internal capsule and part of the basal nuclei. It then passes out to the lateral surface of the cerebral hemisphere at the insula of the lateral sulcus. Here it gives off cortical branches (2) temporal, (3) frontal, (4) parietal.

Clinical features

The middle cerebral artery may be occluded by embolus or thrombus. The clinical picture depends upon the site of occlusion and whether dominant or non-dominant hemisphere is affected.

Occlusion at the insula

	Contralateral hemiplegia (leg relatively spared)
	Contralateral hemianaesthesia and hemianopia
All cortical branches are involved –	Aphasia (dominant)
	Neglect of contralateral limbs
	Dressing difficulty
	} (non-dominant)

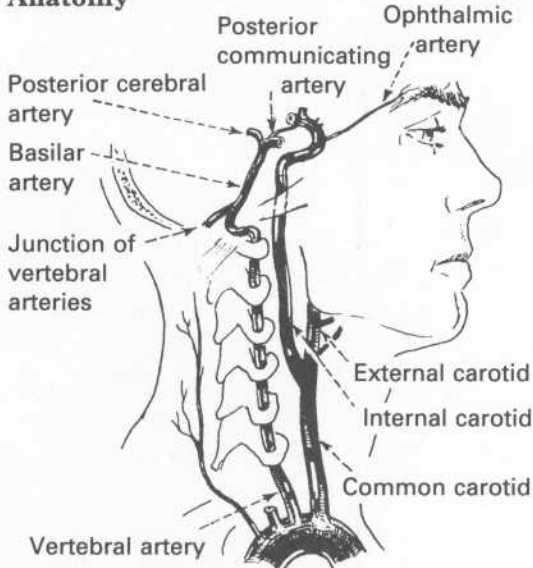
When cortical branches are affected individually, the clinical picture is less severe, e.g. involvement of parietal branches alone may produce Wernicke's dysphasia with no limb weakness or sensory loss.

The deep branches (perforating vessels) of the middle cerebral artery may be a source of haemorrhage or small infarcts (lacunes – see later).

CLINICAL SYNDROMES – LARGE VESSEL OCCLUSION

VERTEBRAL ARTERY OCCLUSION

Anatomy



The vertebral artery arises from the subclavian artery on each side. Underdevelopment of one vessel occurs in 10%.

The vertebral artery runs from its origin through the foramen of the transverse processes of the mid-cervical vertebrae. It then passes laterally through the transverse process of the axis, then upwards to the atlas accompanied by a venous plexus and across the suboccipital triangle to the vertebral canal. After piercing the dura and arachnoid mater, it enters the cranial cavity through the foramen magnum. At the lower border of the pons, it unites with its fellow to form the basilar artery.

The vertebral artery and its branches supply the medulla and the inferior surface of the cerebellum before forming the basilar artery.

Clinical features

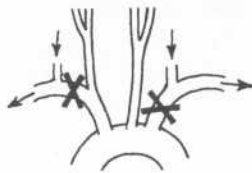
Occlusion of the vertebral artery, when low in the neck, is compensated by anastomotic channels.

When one vertebral artery is hypoplastic, occlusion of the other is equivalent to basilar artery occlusion.

Only the posterior inferior cerebellar artery (PICA) depends solely on flow through the vertebral artery. Vertebral artery occlusion may therefore present as a PICA syndrome (page 250).

The close relationship of the vertebral artery to the cervical spine is important. Rarely, damage at intervertebral foramina or the atlanto-axial joints following subluxation may result in intimal damage, thrombus formation and embolisation.

Vertebral artery compression during neck extension may cause symptoms of intermittent vertebrobasilar insufficiency.

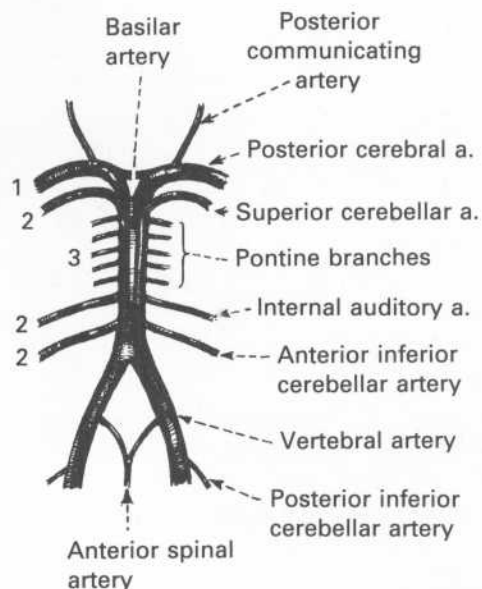


✗ Stenosis of the proximal left or right subclavian artery may result in retrograde flow down the vertebral artery on exercising the arm. This is commonly asymptomatic and demonstrated incidentally by Doppler techniques or angiography. Occasionally symptoms of vertebrobasilar insufficiency arise – *subclavian 'steal' syndrome*. Surgical reconstruction or bypass of the subclavian artery may be indicated.

CLINICAL SYNDROMES – LARGE VESSEL OCCLUSION

BASILAR ARTERY OCCLUSION

Anatomy



The basilar artery supplies the brain stem from medulla upwards and divides eventually into posterior cerebral arteries as well as posterior communicating arteries which run forward to join the anterior circulation (circle of Willis).

Branches can be classified into:

1. Posterior cerebral arteries
2. Long circumflex branches
3. Paramedian branches.

Clinical features

Prodromal symptoms are common and may take the form of diplopia, visual field loss, intermittent memory disturbance and a whole constellation of other brain stem symptoms:

- vertigo
- ataxia
- paresis
- paraesthesia

The *complete basilar syndrome* following occlusion consists of:

- impairment of consciousness → coma
- bilateral motor and sensory dysfunction
- cerebellar signs
- cranial nerve signs indicative of the level of occlusion.

The clinical picture is variable. Occasionally basilar thrombosis is an incidental finding at autopsy.

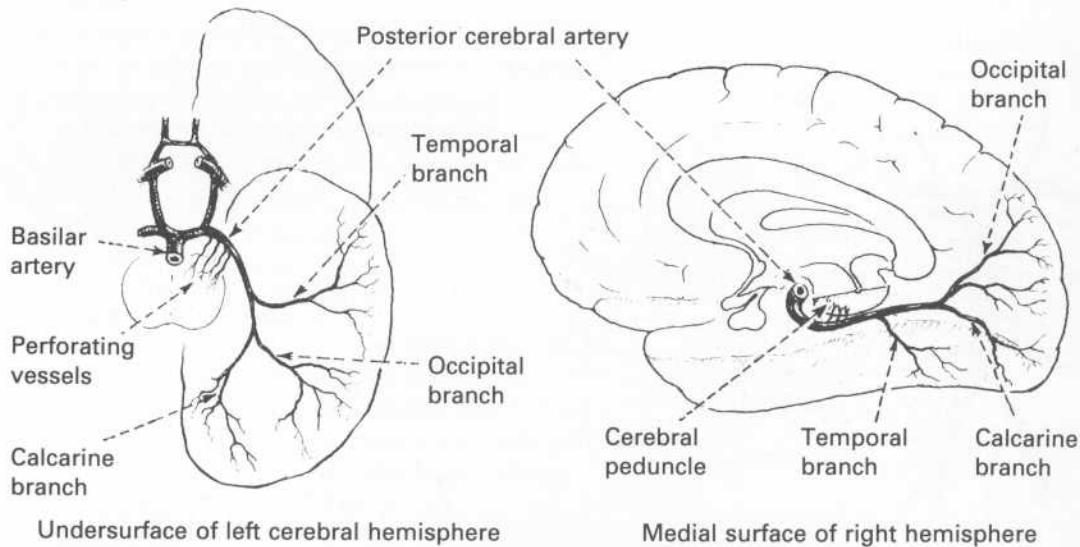
'Top of basilar' occlusion: This results in lateral midbrain, thalamic, occipital and medial temporal lobe infarction. Abnormal movements (hemiballismus) are associated with visual loss, pupillary abnormalities, gaze palsies, impaired conscious level and disturbances of behaviour.

Paramedian perforating vessel occlusion gives rise to the **'LOCKED-IN' SYNDROME** (page 251) and **LACUNAR** infarction (page 252).

CLINICAL SYNDROMES – LARGE VESSEL OCCLUSION

POSTERIOR CEREBRAL ARTERY

Anatomy



The posterior cerebral arteries are the terminal branches of the basilar artery. Small perforating branches supply midbrain structures, choroid plexus and posterior thalamus. Cortical branches supply the undersurface of the temporal lobe – temporal branch; and occipital and visual cortex – occipital and calcarine branches.

Clinical features

Proximal occlusion by thrombus or embolism will involve perforating branches and structures supplied:

- Midbrain syndrome* – III nerve palsy with contralateral hemiplegia – **WEBER'S SYNDROME.**
- Thalamic syndromes* – chorea or hemiballismus with hemisensory disturbance.

Occlusion of cortical vessels will produce a different picture with visual field loss (homonymous hemianopia) and sparing of macular vision (the posterior tip of the occipital lobe, i.e. the macular area, is also supplied by the middle cerebral artery).

Posterior cortical infarction in the dominant hemisphere may produce problems in naming colours and objects.

CLINICAL SYNDROMES – BRANCH OCCLUSION

BASILAR ARTERY – LONG CIRCUMFLEX BRANCH OCCLUSION

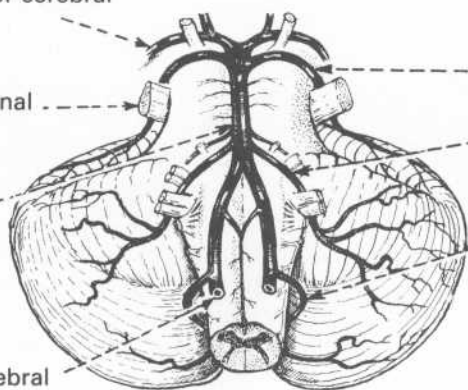
Anatomy

Posterior cerebral artery

Trigeminal nerve

Basilar artery

Vertebral artery

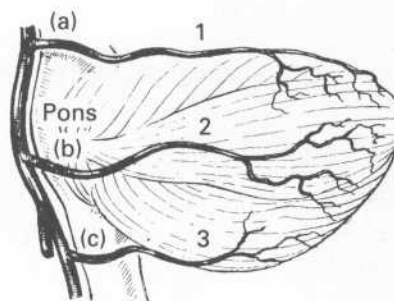


The cerebellum is supplied by three paired blood vessels:

1. Superior cerebellar artery
 2. Anterior inferior cerebellar artery
 3. Posterior inferior cerebellar artery (PICA) which arises from the vertebral artery.
- } arise from basilar artery

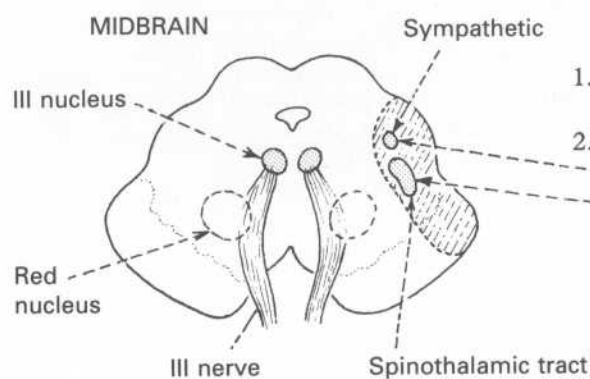
It can be seen that a vascular lesion in the territory of these vessels will produce, not only cerebellar, but also brain stem symptoms and signs localising to:

- (a) superior pontine,
- (b) inferior pontine and
- (c) medullary levels.



Clinical features

Superior cerebellar artery syndrome results in:

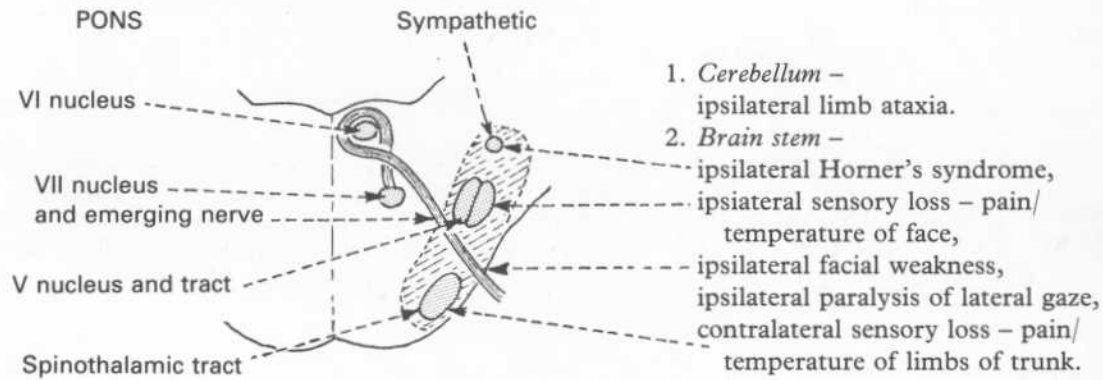


1. *Cerebellum* – disturbed gait, limb ataxia.
2. *Brain stem* – ipsilateral Horner's syndrome, contralateral sensory loss – pain/temperature (including face).

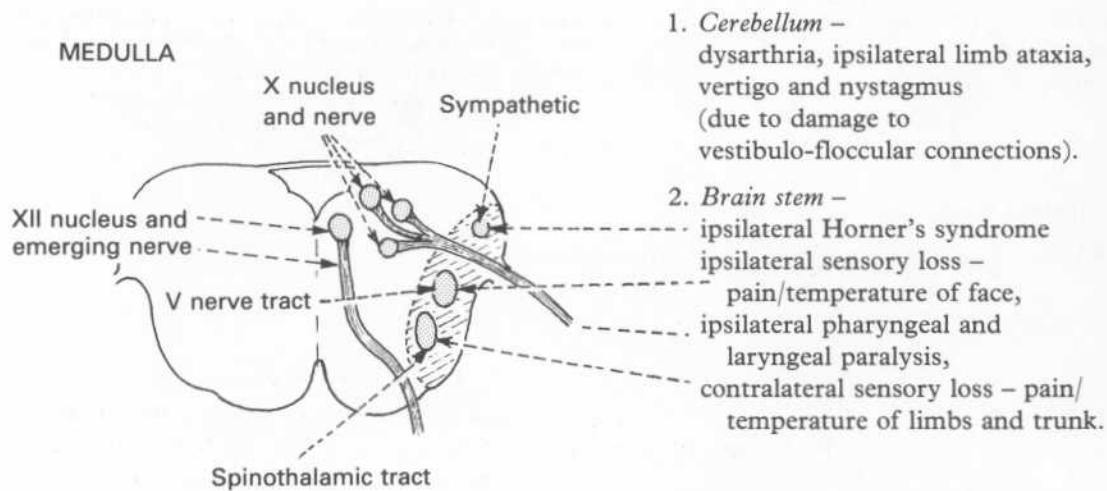
CLINICAL SYNDROMES – BRANCH OCCLUSION

Clinical features (contd)

Anterior inferior cerebellar artery syndrome results in:



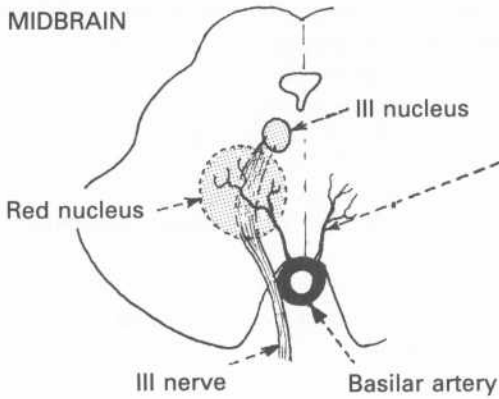
Posterior inferior cerebellar artery syndrome (lateral medullary syndrome) results in:



CLINICAL SYNDROMES – BRANCH OCCLUSION

BASILAR ARTERY – PARAMEDIAN BRANCH OCCLUSION

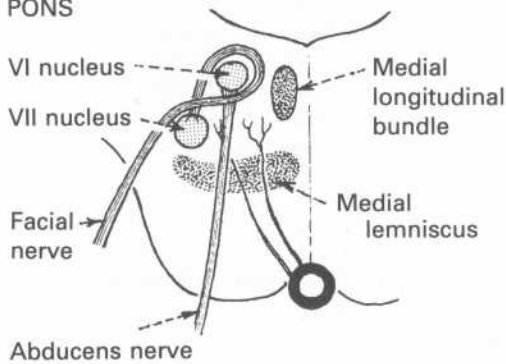
MIDBRAIN



Paramedian branch occlusion is produced by occlusion of the penetrating midline branches of the basilar artery.

At the midbrain level damage to the nucleus or the fasciculus of the oculomotor nerve (III) will result in a complete or partial III nerve palsy; damage to the red nucleus (outflow from opposite cerebellar hemisphere) will also produce contralateral tremor – referred to as **BENEDIKT'S SYNDROME**.

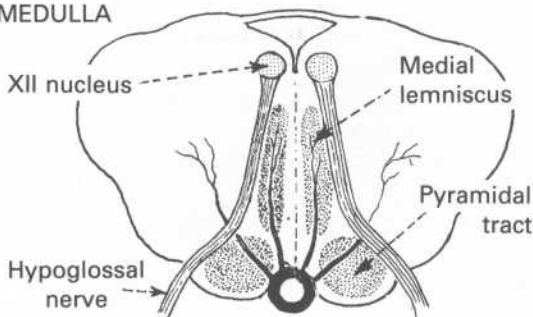
PONS



At the pontine level an abducens nerve (VI) palsy will occur with ipsilateral facial (VII) weakness and contralateral sensory loss – light touch, proprioception (medial lemniscus damage) when the lesion is more basal.

Abducens and facial palsy may be accompanied by contralateral hemiplegia – **MILLARD-GUBLER SYNDROME**.

MEDULLA



At the medullary level, bilateral damage usually occurs and results in the '**LOCKED-IN**' SYNDROME. The patient is paralysed and unable to talk, although some facial and eye movements are preserved.

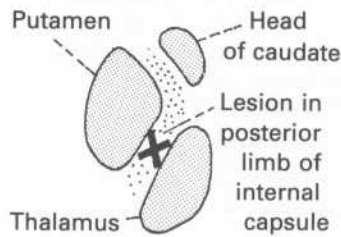
Spinothalamic sensation is retained, but involvement of the medial lemniscus produces loss of 'discriminatory' sensation in the limbs. The syndrome usually follows basilar artery occlusion and carries a grave prognosis.

CLINICAL SYNDROMES – LACUNAR STROKE (LACI)

Occlusion of deep penetrating arteries produces subcortical infarction characterised by *preservation* of cortical function – language, other cognitive and visual functions.

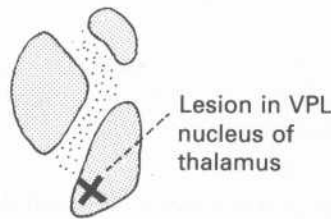
Clinical syndromes are distinctive and normally result from long-standing hypertension. In 80%, infarcts occur in periventricular white matter and basal ganglia, the rest in cerebellum and brain stem. Areas of infarction are 0.5–1.5 cms in diameter and occluded vessels demonstrate lipohyalinosis, microaneurysm and microatheromatous changes. Lacunar or subcortical infarction accounts for 17% of all thromboembolic strokes and knowledge of commoner syndromes is essential.

1. Pure motor hemiplegia



Clinical: Equal weakness of contralateral face, arm and leg with dysarthria
Vessel(s): Lenticulostriate A.

2. Pure sensory stroke



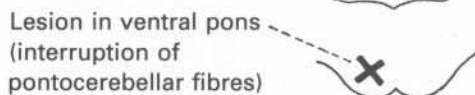
Clinical: Numbness and tingling of contralateral face and limbs. Sensory examination may be normal
Vessel(s): Thalamogeniculate A.

3. Dysarthria/clumsy hand



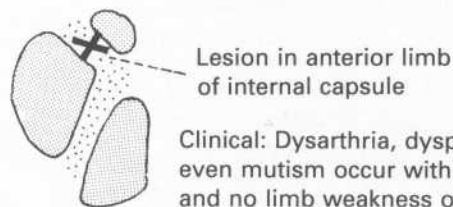
Clinical: Dysarthria due to weakness of ipsilateral face and tongue associated with clumsy but strong contralateral arm.
Vessel(s): Perforating branch of Basilar A.

4. Ataxic hemiparesis



Clinical: Mild hemiparesis with more marked ipsilateral limb ataxia
Vessel(s): Perforating branch of Basilar A. (This syndrome can also be produced by anterior capsular lesions)

5. Severe dysarthria with facial weakness



Clinical: Dysarthria, dysphagia and even mutism occur with mild facial and no limb weakness or clumsiness.
Vessel(s): Lenticulostriate A.

Sensorimotor syndromes are common although anatomical basis is obscure. A recent Stroke Data Bank survey showed the commonest presentations to be: -

- Pure motor hemiplegia 57%
- Sensorimotor 20%
- Ataxic hemiparesis 10%
- Pure sensory 7%
- Dysarthria/Clumsy hand 6%

Investigations MRI is superior to CT in demonstrating lacunae, although either may occasionally misdiagnose a small resolving haematoma. Confirmation of lacunar stroke may save patients from unnecessary investigations for carotid and cardiac embolic source.

Prognosis For all syndromes this is encouraging. Careful control of blood pressure and the use of aspirin usually prevents recurrence. Multiple lacunar infarctions – ‘etat lacunaire’ – results in shuffling gait, pseudobulbar palsy and subcortical dementia.

CLASSIFICATION OF SUBTYPES OF CEREBRAL INFARCTION

A recently devised classification of infarction has proved simple and of practical value in establishing *diagnosis* and in *predicting outcome* –

	Clinical features	Outcome
Total Anterior Circulation Infarction (TACI)	motor and sensory deficit, hemianopia and disturbance of higher cerebral function	Poor
Partial Anterior Circulation Infarction (PACI)	any two of above or isolated disturbance of cerebral function	Variable
Posterior Circulation Infarction (POCI)	signs of brainstem dysfunction or isolated hemianopia	Variable
Lacunar Infarction (LACI)	pure motor stroke or pure sensory stroke or pure sensorimotor stroke or ataxic hemiparesis	Good

EMBOLISATION

Emboli consist of friable atheromatous material, platelet-fibrin clumps or well formed thrombus.

The **diagnosis** of embolic infarction depends on:

- The identification of an embolic *source*, e.g. cardiac disease.
- The clinical picture of *sudden onset*.
- Infarction in the territory of a major vessel or large branch.

Clinical picture – depends on the vessel involved. Emboli commonly produce *transient ischaemic attacks (TIA)* as well as *infarction*.

Symptoms are referable to the eye (retinal artery) and to the anterior and middle cerebral arteries, and take the form of:

Visual loss – transient, i.e. *amaurosis fugax* or permanent.

Hemisensory and hemimotor disturbance.

Disturbance of higher function, e.g. dysphasia.

Focal or generalised seizures – may persist for some time after the ischaemic episode.

Depression of conscious level if major vessel occlusion occurs.

Emboli less frequently affect the posterior circulation.

EMBOLI FROM THE INTERNAL CAROTID ARTERY AND AORTA

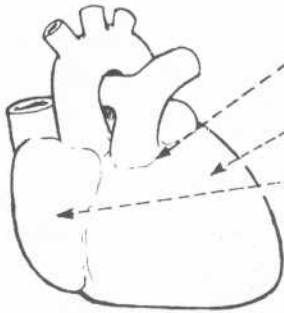
Emboli from these sources are commonest outwith the heart. The majority of all cerebral emboli arise from ulcerative plaques in the carotid arteries (see page 239).

Emboli arising from the aorta (atheromatous plaque or aortic aneurysm) often involve both hemispheres and systemic embolisation (e.g. affecting limbs) may coexist.



EMBOLISATION

EMBOLI OF CARDIAC ORIGIN



The heart represents a major source of cerebral emboli.

Valvular heart disease: rheumatic heart disease e.g. mitral stenosis with atrial fibrillation or mitral valve prolapse.

Ischaemic heart disease: myocardial infarction with mural thrombus formation.

Arrhythmias: Non-rheumatic (non-valvular) atrial fibrillation is the most common cause of cardioembolic stroke

Bacterial endocarditis may give rise to septic cerebral embolisation with ischaemia → infection → abscess formation.

Neurological signs will occur in 30% of all cases of bacterial endocarditis, *S. aureus* and *streptococci* being the offending organisms in the majority.

Non-bacterial endocarditis (marantic endocarditis): associated with malignant disease due to fibrin and platelet deposition on heart valves.

Atrial myxoma is a rare cause of recurrent cerebral embolisation. Bihemisphere episodes with a persistently elevated ESR should arouse suspicion which may be confirmed by cardiac ultrasound.

Patent foramen ovale may result in paradoxical embolisation; suspect in patient with deep venous thrombosis who develops cerebral infarction.

New cardiac imaging techniques especially Transoesophageal Echocardiography (TOE) allow a more accurate detection of potential embolic source. Transcranial Doppler (TCD) may characterise emboli by analysing their signals and help quantify risk of recurrence.

EMBOLI FROM OTHER SOURCES

Fat emboli: following fracture, especially of long bones and pelvis, fat appears in the bloodstream and may pass into the cerebral circulation, usually 3–6 days after trauma. Emboli are usually multiple and signs are diffuse.

Air emboli follow injury to neck/chest, or follow surgery. Rarely, air emboli complicate therapeutic abortion. Again the picture is diffuse neurologically. Onset is acute; if the patient survives the first 30 minutes, prognosis is excellent.

Nitrogen embolisation or decompression sickness (the 'bends') produces a similar picture, but if the patient survives, neurological disability may be profound.

Tumour emboli result in metastatic lesions; the onset is usually slow and progressive. Acute stroke-like presentation may occur, followed weeks or months later by the mass effects.

Lung Melanoma Testicular tumours Lymphoblastic leukaemia Prostate Breast Renal	}	commonly metastasise to brain.
--------------------------------------------------------------------------------------------------	---	--------------------------------

STENOTIC/OCCCLUSIVE DISEASE – INVESTIGATIONS

1. CONFIRM THE DIAGNOSIS

Computerised tomography (CT scan)

Ideally, all patients should have a CT scan.

In practice, a CT scan is performed if:

- there is doubt about the diagnosis
- symptoms progress
- conscious level is depressed
- if thrombolytic or anticoagulant treatment is considered or aspirin commenced or continued
- neck stiffness is present

or prior to any invasive investigation.

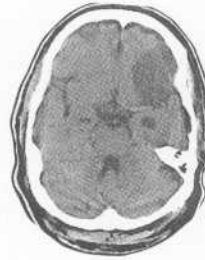?haemorrhage or tumour

?cerebral haemorrhage (see page 259)

Infarction is evident as a low-density lesion which conforms to a vascular territory, i.e. usually wedge shaped. It is not immediately visible on CT but in most patients becomes apparent in 4–7 days.

CT scan also identifies:

- the site and size of the infarct, providing a prognostic guide
- the presence of haemorrhagic infarction where bleeding occurs into the infarcted area
- intracerebral haemorrhage or tumour.



(note hyperdense thrombosed middle cerebral artery)

Magnetic resonance imaging (MRI)

T1 prolongation (i.e. hypointensity in relation to white and grey matter) occurs within a few hours of onset of ischaemic symptoms. Intracranial vessel occlusions show an absence of a 'signal void'. Posterior circulation strokes (lacunes) are more readily identified than with CT.

2. DEMONSTRATE THE SITE OF PRIMARY LESION

(a) **Non-invasive investigation**

Ultrasound – Doppler/Duplex scanning: assesses extra- and intracranial vessels (page 42). A normal study precludes the need for angiography.

Cardiac ultrasound (transthoracic or transoesophageal): this often reveals a cardiac embolic source in young people with stroke, e.g. prolapsed mitral valve, patent foramen ovale.

Magnetic resonance angiography (MRA)

Using 'time of flight' techniques, a non-invasive image of extra and intracranial vasculature is obtained. MRA overestimates the degree of stenosis and is insensitive to ulcerative plaque detection.

(b) **Invasive investigation**

The combination of the above techniques has decreased the need for invasive investigation but often *cerebral angiography* is still required to make a definitive diagnosis. The role and safety of angiography *immediately* following infarction is uncertain. In the elderly or poor-risk patient, investigations to demonstrate the site of the primary lesion may be inappropriate.

STENOTIC/OCCCLUSIVE DISEASE – INVESTIGATIONS

Indication for angiography

1. With suspected *extracranial* vascular disease
 - a recovered stroke patient } if ultrasound
 - at further risk } positive.
 - following TIAs
2. With suspected *intracranial* vascular disease.



Carotid stenosis and ulceration

Angiography identifies the site and nature of the disease in intra- and extracranial vessels, and indicates the degree of collateral circulation.

Suspected carotid disease: demonstrate both carotids, intracranial vessels, the aortic arch and origins of the vertebrals. Approximately two-thirds of patients with carotid territory attacks will have angiographic abnormality.

Suspected vertebrobasilar disease: note the intracranial vessels and the course of the vertebral artery through the cervical foramina where osteophytic encroachment may occur. Note that proximal subclavian occlusion may result in retrograde flow down the vertebral arteries into the subclavian arteries, and cause TIAs aggravated by arm exercise – *subclavian steal* (page 246).

3. IDENTIFY FACTORS WHICH MAY INFLUENCE TREATMENT AND OUTCOME

General investigations identify conditions which may predispose towards premature cerebrovascular disease. These are essential in all patients.

Chest X-ray – cardiac enlargement – hypertension/valvular heart disease

ECG – ventricular enlargement and/or arrhythmias – hypertension/embolic disease
 recent myocardial infarct – embolic disease
 sinoatrial conduction defect – embolic disease/output failure

Blood glucose – diabetes mellitus

Serum lipids and cholesterol – hyperlipidaemia

ESR – } vasculitis/collagen vascular disease

Auto-antibodies – }

Urine analysis – polyarteritis, thrombocytopenia

Full blood count – polycythaemia, thrombocytopenia

VDRL-TPHA – neurosyphilis

Prothrombin time – circulating auto-anticoagulants

Note drug history – oral contraceptives, amphetamines, opiates

Cervical spine X-ray – atlanto-axial subluxation

Following the interpretation of these preliminary investigations, more detailed studies may be required, e.g.

- cardiac ultrasound — cardiac embolic source
- blood cultures — subacute bacterial endocarditis
- HIV screen — AIDS
- sickle cell screen
- plasma electrophoresis } haematological disorder
- viscosity studies }
- anticardiolipin antibodies – antiphospholipid syndrome
- muscle biopsy – mitochondrial disease

} See inflammatory vasculitis and blood diseases (pages 261, 264)

CEREBRAL INFARCTION – MANAGEMENT

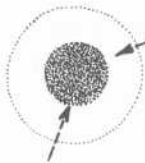
THE ACUTE STROKE

Clinical history, examination and investigation will separate infarction and haemorrhage. Once the nature of the 'stroke' has been confidently defined, treatment should be instigated.

Treatment aims

- Prevent progression of present event
- Prevent immediate complication
- Prevent the development of subsequent events
- To rehabilitate the patient.

General measures



Infarction

Around the edge of an infarct, ischaemic tissue is at risk, but is potentially recoverable. This compromised but viable tissue must be protected by ensuring a good supply of glucose and oxygen. Factors which might adversely affect this must be maintained – hydration, oxygenation, blood pressure. To this end, treat chest infections and cardiac failure/dysrhythmias.

Specific measures

The following are generally ineffective, or are as yet inadequately evaluated.

Anticoagulant therapy

The role of antithrombotic therapy (heparin) in patients with acute infarction is uncertain and currently under evaluation (IST – International Stroke Trial).

In patients with a known cardiac source of emboli, the risk of recurrent embolic infarction is high and anticoagulant therapy should be commenced once CT scan has ruled out haemorrhagic infarction. In chronic valvular disease, treatment is long term; following myocardial infarction (with mural thrombus) – 6 months. With mitral valve prolapse, antiplatelet drugs will suffice. In atrial fibrillation the overall annual risk of stroke is 5%. Several recent trials show highly significant benefit from long term oral anticoagulation with warfarin (target INR 1.2-2.0)

Heparin is often used in the management of 'stroke in evolution'. The neurological deficit fluctuates but gradually worsens over some hours. The gradual progression is considered due to increasing thrombus formation with progressive 'silting' of collateral vessels. Studies of anticoagulant therapy produce conflicting results probably because of other potential mechanisms, e.g. collateral perfusion failure.

Thrombolytic agents

Recent experience with thrombolytic agents, especially recombinant tissue plasminogen activator (rTPA) suggests a sustained, significant neurological improvement when initiated within a few hours of infarction. Such agents are associated with rapid recanalisation of occluded vessels. Randomised clinical trials of rTPA and other thrombolytics are currently underway. Experience with streptokinase shows unacceptable risk of intracranial haemorrhage and studies have been suspended.

CEREBRAL INFARCTION – MANAGEMENT

Specific measures (*contd.*)

Decreasing blood viscosity

Improving hydration and venesection lower the haematocrit and reduce blood viscosity, thereby increasing cerebral blood flow (to a greater extent than the oxygen carrying capacity is reduced). Preliminary studies of venesection have produced encouraging results. Plasma expanders, low molecular weight dextran and drugs that effect red blood cell deformity (pentoxifylline) lower blood viscosity but seem of less value.

Neuronal rescue

Experimental work indicates a pathological role for intracellular calcium influx in neuronal injury. Excitatory amino acids – glutamate and glycine – promote calcium influx by acting on receptor-mediated membrane channels. (N-methyl-D-aspartate-NMDA channels.) The NMDA channel has at least 6 sites which may be pharmacologically blocked. Agents such as MK801, Mg^{++} , CGS-19755 and d-Methorphan have been evaluated in animal models and some await evaluation in human clinical trials. Voltage dependent calcium channel antagonists (Nimodipine, Diltiazem, Nifedipine and Verapamil) have been assessed, with, to date, disappointing results, in large multicentre studies of acute infarction.

Treatment of oedema

The degree of concomitant oedema relates to the magnitude of infarction. Oedema develops early and may cause ventricular displacement and transtentorial herniation with secondary brain stem damage. Controversy exists as to whether oedema is vasogenic or cytotoxic (as associated with metabolic encephalopathies), or a mixture of the two. Its effective treatment should lower morbidity and mortality but steroids and hyperosmolar agents (e.g. mannitol) have been used with little effect on outcome. The poor response probably reflects the 'mixed' nature of the oedema.

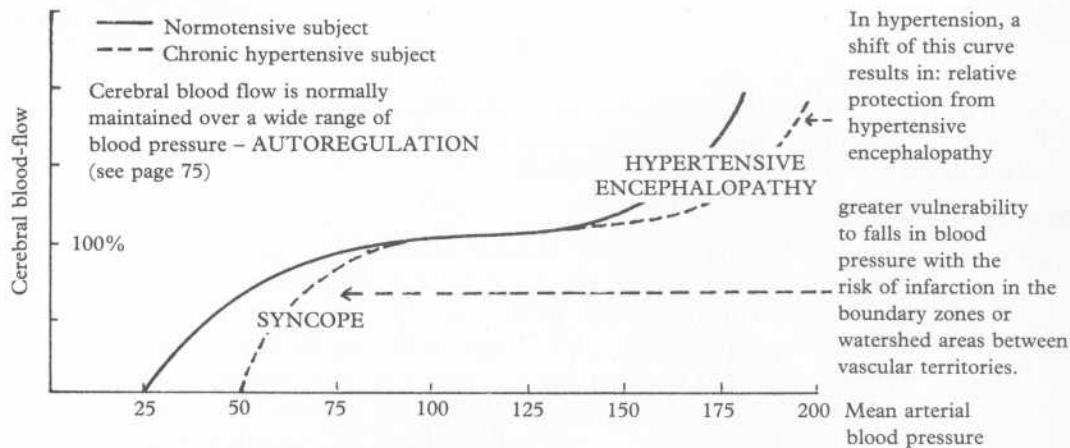
Prevention of further stroke

The recognition of risk factors and their correction to minimise the risk of further events forms a necessary and important step in long-term treatment.

- Control hypertension
- Emphasise the need to stop cigarette smoking
- Correct lipid abnormality
- Give platelet antiaggregation drugs (aspirin or in selected cases ticlopidine) to reduce the rate of reinfarction
- Remove or treat embolic source (long term anticoagulation in atrial fibrillation)
- Treat inflammatory or vascular inflammatory diseases
- Stop thrombogenic drugs, e.g. oral contraceptives.

HYPERTENSION AND CEREBROVASCULAR DISEASE

Next to age, the most important factor predisposing to cerebral infarction or haemorrhage is hypertension. The risk is equal in males and females and is proportional to the height of blood pressure (diastolic and systolic).



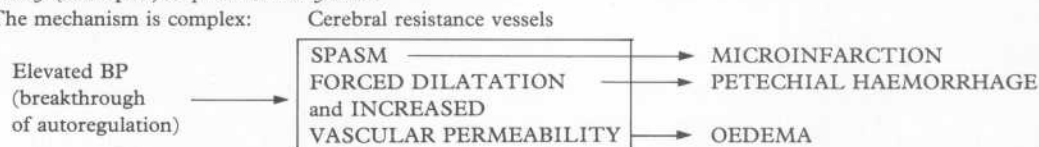
The pathological effects of sustained hypertension are:

- Charcot Bouchard microaneurysms → INTRACEREBRAL HAEMORRHAGE (from perforating vessels)
- Accelerated atheroma and thrombus formation → INFARCTION (large vessels)
- Hyalinosis and fibrin deposition → INFARCTION (lacunes - small vessels)

HYPERTENSIVE ENCEPHALOPATHY

An acute, usually transient, cerebral syndrome precipitated by sudden severe hypertension. The excessive blood pressure may be due to *malignant hypertension* from any cause, or uncontrolled hypertension in *glomerulonephritis*, *pregnancy (eclampsia)* or *phaeochromocytoma*.

The mechanism is complex:



Clinical features: Headache and confusion precede convulsions and coma. Papilloedema with haemorrhages and exudates are invariably found. Proteinuria and signs of renal and cardiac failure are common.

Diagnosis: CT scanning shows widespread white matter low attenuation and excludes other pathology. MRI confirms increased brain water content and SPECT shows hyperperfusion adjacent to these changes.

Treatment: a precipitous fall in blood pressure can result in retinal damage and watershed infarction. Gradually reduce blood pressure with i.v. nitroprusside or hydralazine. Reserve peritoneal dialysis for resistant cases.

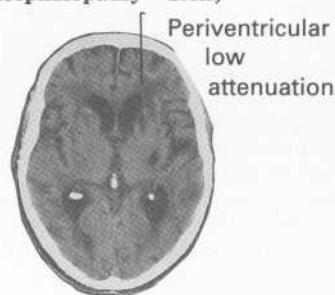
N.B. *With treatment full recovery is usual. Without treatment death occurs.*

BINSWANGER'S ENCEPHALOPATHY (Subcortical arteriosclerotic encephalopathy - SAE)

A rare disorder in which progressive dementia and pseudobulbar palsy are associated with diffuse hemisphere demyelination. The CT scan shows areas of periventricular low attenuation, often also involving the external capsule. The pathological changes were previously attributed to chronic diffuse oedema, but the recent finding of a high plasma viscosity in these patients suggests that this, in conjunction with hypertensive small vessel disease, could produce chronic ischaemic change in central white matter.

Subclinical forms of this disease may exist as this CT scan appearance is occasionally found in asymptomatic patients.

MRI appears more sensitive in establishing radiological diagnosis.



DISEASES OF THE VESSEL WALL

VASCULITIS AND COLLAGEN VASCULAR DISEASES

These disorders have systemic as well as neurological features. Occasionally only the nervous system is diseased.

Collagen vascular diseases:

- Systemic lupus erythematosus
- Rheumatoid arthritis
- Other connective tissue disorders.

Vasculitis

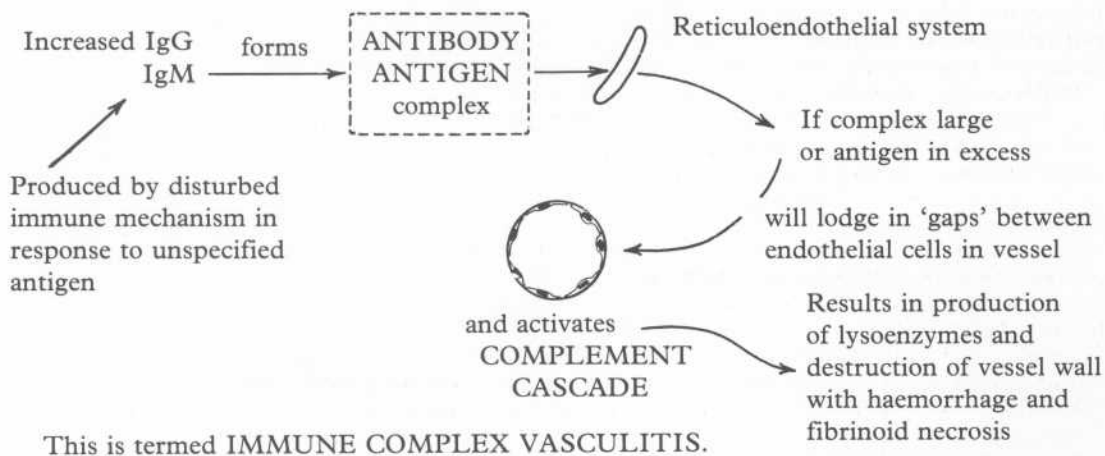
- Vasculitis associated with connective tissue disease.
- Polyarteritis nodosa (PAN).
- Allergic angiitis (hypersensitivity vasculitis).
- Takayasu's arteritis.
- Isolated angiitis of the central nervous system (IAC).
- Giant cell arteritis/Temporal arteritis
- Churg-Strauss angiitis.

All the above conditions can result in infarction or haemorrhage.

Granulomatous vasculitis e.g. Wegener's granulomatosis.

Mechanism

An immune basis for these disorders is likely.



Indirect immunofluorescent microscopy on biopsy material will demonstrate the presence of immune complexes.

In giant cell arteritis and granulomatous vasculitis, cellular immune mechanisms are probably to blame and vessels are directly attacked. A reaction of antigen with sensitised lymphocytes results in lymphokine release - attracted mononuclear cells release lysosomal enzymes with resultant granuloma formation.

DISEASES OF THE VESSEL WALL

VASCULITIS AND COLLAGEN VASCULAR DISEASES (*contd.*)

In all vasculitides affecting predominantly large and medium size vessels, angiography is important in establishing diagnosis. On MRI the presence of bilateral cortical and subcortical infarction is suggestive.

SYSTEMIC LUPUS ERYTHEMATOSUS: in 75% of patients nervous system involvement occurs and may predate systemic manifestation.

- Psychiatric change
- Dementia
- Seizures
- HEMIPLEGIA
- Cranial or peripheral nerve involvement
- SPINAL stroke
- Involuntary movements.

Pathology

The predominant CNS finding is microvascular injury with hyalinisation, perivascular lymphocytosis, endothelial proliferation and thrombosis. Active vasculitis is rare. Cardiogenic embolism and coagulopathy (antiphospholipid antibodies) are alternative mechanisms of stroke.

Treatment

Corticosteroids in moderate dosage. In patients with severe or fulminant disease, immunosuppressants and plasma exchange may help.

POLYARTERITIS NODOSA

Neurological involvement is common (80%): Small and medium size arteries are affected.

- HEMIPLEGIA - microinfarction
- INTRACRANIAL HAEMORRHAGE - aneurysm formation
- SPINAL INFARCTION or HAEMORRHAGE
- Peripheral nerve involvement (mononeuritis multiplex)
- 'Cogan's' syndrome

}	interstitial keratitis	}	progressing to
	deafness		
	vertigo		

 → seizures/stroke/coma

Hypertension and renal involvement are common.

Investigations

Blood

- Elevated ESR and C-reactive protein
- Anaemia
- Leukocytosis
- Eosinophilia
- Antinuclear cytoplasmic antibodies (ANCA)
- Circulating immune complexes
- IgM rheumatoid factor

Other

- Biopsy* - renal or peripheral nerve
- necrotic vessel
- lumen diminished
- leucocytes and eosinophils in necrotic media and adventitia

CT/MRI as in systemic lupus erythmatosus

Angiography. Multiple irregularities and micro-aneurysm formation. These changes can be visible on MRA

Treatment

Steroids and immunosuppressant therapy have dramatically improved outcome (60% 5-year survival). Plasmapheresis is successful in acute cases.

DISEASES OF THE VESSEL WALL

VASCULITIS AND COLLAGEN VASCULAR DISEASES (*contd.*)

ALLERGIC ANGIITIS (Hypersensitivity vasculitis)

Intercurrent illnesses (infection or neoplasia) trigger immune complex deposition on basement membranes of capillaries and venules. Systemic symptoms – rash, fever and arthralgia are associated with multiorgan involvement. Neurological features – neuropathy, stroke-like syndromes – occur in 30% of patients. Investigations suggest systemic upset – elevated ESR, anaemia, leukopaenia. Skin biopsy confirms peri-venular inflammation. Treatment of underlying infection and steroids produce rapid improvement.

TAKAYASU'S (PULSELESS) DISEASE

A giant cell arteritis involving the aorta and its major branches. Predominantly affects Asian females in third or fourth decades.

Symptoms:

- Non-specific – fever, arthralgias and myalgia
- Vascular – myocardial ischaemia, peripheral vascular disease
- Neurological vascular TIAs (including subclavian steal), strokes and dementia.

Diagnosis:

Steroids are useful initially. The role of surgical reconstruction of occluded vessels is uncertain

ISOLATED ANGIITIS OF CENTRAL NERVOUS SYSTEM

Systemic symptoms and laboratory evidence of generalised vasculitis are *absent*.

Presentation with headaches/seizures/encephalopathy and stroke

Diagnosis:

- Condition should be borne in mind in atypical stroke
- CSF shows lymphocytes
- MRI, multiple ischaemic changes
- Angiography, beading (multiple narrow segments) on intracranial arteries
- Meningeal biopsy.

Treatment:

Prognosis often dismal. Steroids and cyclophosphamide may produce remission.

GIANT CELL ARTERITIS (see page 69)

CHURG STRAUSS ANGIITIS

A distinctive syndrome of eosinophilia, pulmonary infiltrates, neuropathy and encephalopathy or stroke. Related to polyarteritis nodosa, steroid responsive. Other immunosuppressants e.g. cyclophosphamide in resistant cases.

GRANULOMATOUS VASCULITIS/WEGENERS GRANULOMATOSIS

A rare disorder, most frequent in males aged 20–50 years.

Upper or lower respiratory tract granuloma is associated with glomerulonephritis
Small arteries and capillaries are affected

Neurological involvement

- direct granulomatous invasion of skull base (cranial nerve palsies, visual failure from chiasmal compression)
- Stroke-like symptoms from vasculitis.

Diagnosis:

- Elevated ESR and C-reactive protein (CRP)
- Elevated immunoglobulins
- Impaired renal function
- Radiological findings: Chest and sinuses: granuloma mass
MRI (cranium): granuloma mass or vasculitis.

Treatment:

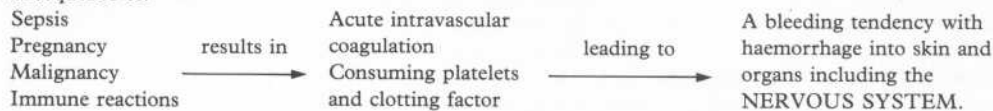
- Immunosuppression: steroids and cyclophosphamide
- Surgical decompression of granulomas occasionally required.

DISEASES OF THE BLOOD

Disorders of the blood may manifest themselves as 'stroke-like' syndromes. Examination of the peripheral blood film is an important investigation in cerebrovascular disease. Where indicated, more extensive haematological investigation is necessary.

DISSEMINATED INTRAVASCULAR COAGULATION (DIC)

A consequence of:



Neurological involvement – a diffuse fluctuating encephalopathy, subarachnoid or subdural haemorrhage.

Diagnosis confirmed by – low platelet count – prolonged prothrombin time, elevated fibrin degradation products and reduced fibrinogen levels.

Treatment

Heparin. Fresh frozen plasma/vitamin K. Treatment of underlying cause.

HAEMOGLOBINOPATHIES

These are genetically determined disorders in which abnormal haemoglobin is present in red blood cells.

Sickle cell disease

This disorder is common in Negro populations and also occurs sporadically throughout the Mediterranean and Middle East region.

The patient is of small stature, usually with chronic leg ulcers, cardiomegaly and hepatosplenomegaly. When arterial oxygen saturation is reduced, 'sickling' will occur, manifested clinically by abdominal pain/bone pain.

Neurological involvement – hemiparesis, optic atrophy, subarachnoid haemorrhage.

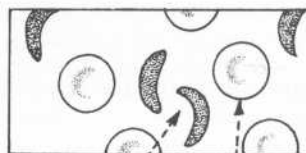Diagnosis is confirmed in vitro by the 'sickling' of cells when O₂ tension is reduced and by haemoglobin electrophoresis.

Treatment

Analgesics for pain

O₂ therapy, or hyperbaric O₂.

exchange transfusion should be carried out for those with a severe or progressive deficit.



Sickle cells rbc

ANTIPHOSPHOLIPID ANTIBODIES

These IgB or IgM antibodies prolong prothrombin time and appear to be associated with thrombotic stroke. There remains uncertainty as to whether they are caused or represent a transient non-specific 'acute phase' reaction to illness. Such antibodies can be found in patients with systemic lupus erythematosus.

ANTITHROMBIN III, PROTEIN C and PROTEIN S DEFICIENCY

Deficiency of any of these circulating antithrombotic fibrinolytic agents can result in deep venous thrombosis, pulmonary embolism or thrombotic stroke.

DISEASES OF THE BLOOD

POLYCYTHAEMIA

Both polycythaemia rubra vera (primary) and secondary polycythaemia may result in *neurological* involvement – increased viscosity results in reduced cerebral blood flow and an increased tendency towards thrombosis.

Headaches, visual blurring and vertigo are common neurological symptoms.

Transient ischaemic attacks and thrombotic cerebral infarction occur.

Diagnosis

Hb and PCV are elevated.

Primary polycythaemia is confirmed by increased red cell count, white blood count and platelets.

Secondary polycythaemia – respiratory, renal or congenital heart disease are causal.

Treatment

Venesection with replacement of volume with low molecular weight dextran.

Antimitotic drugs may also be used when polycythaemia is due to myeloproliferative disease.

HYPERGAMMAGLOBULINAEMIA

An increase in serum gamma globulin may arise as a primary event or secondary to leukaemia, myeloma, amyloid.

Neurological involvement develops in 20% of cases – due to increased viscosity.

Clinical features are similar to those of polycythaemia – peripheral nervous system involvement may also occur.

Diagnosis is confirmed by protein electrophoresis.

Treatment – underlying cause – plasmapheresis.

THROMBOTIC THROMBOCYTOPENIC PURPURA (syn: Moschkowitz's syndrome)

This is a fibrinoid degeneration of the subintimal structures of small blood vessels. Lesions occur in all organs including the brain.

Clinical features – fever with purpura and multiorgan involvement and neurological features of diffuse encephalopathy or massive intracranial haemorrhage.

Haemolytic anaemia, haematuria and thrombocytopenia are the main laboratory features.

Treatment

Heparin, steroids and platelet inhibitors may be of value.

THROMBOCYTOPENIA

Whether idiopathic, drug-induced or due to myeloproliferative disorders, this condition may be associated with intracranial haemorrhage.

THROMBOCYTOSIS

This is an elevation in platelet count above 600 000 per mm³. It may be part of a myeloproliferative disorder, or 'reactive' to chronic infection. Patients present with recurrent thrombotic episodes.

Treatment

Aspirin in mild cases; plasmapheresis and antimitotic drugs if more severe.

HYPERFIBRINOGENAEMIA

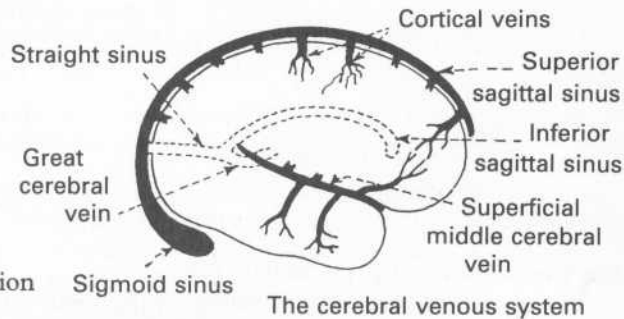
Serum fibrinogen is occasionally elevated in people with cerebrovascular disease. This enhances coagulation and raises blood viscosity. Infection, pregnancy, malignancy and smoking all raise fibrinogen and may explain in part the increased risk of cerebral infarction. Arvin (Malayan viper venom) acutely lowers serum levels.

CEREBROVASCULAR DISEASE – VENOUS THROMBOSIS

The venous sinuses are important in CSF absorption, with arachnoid villi invaginating the sagittal sinus in particular. Thrombotic occlusion of the venous system occurs with

- head trauma
- infection
- dehydration
- pregnancy, puerperium and pill
- coagulation disorders
- malignant meningitis
- miscellaneous disorders
e.g. sarcoid, Beçhets

Improved imaging (MRI) has resulted in increased recognition. Venous infarction accounts for 1% of all 'strokes'.



Superior sagittal and lateral sinus thrombosis (85% of cases)

Impaired CSF drainage results in headache, papilloedema and impaired consciousness. Venous infarction produces seizures and focal deficits (e.g. hemiplegia).

Diagnosis is suggested by venous (nonarterial territory) infarction and 'empty delta' sign (following contrast the wall of the sinus enhances but not the central thrombus on CT) and confirmed by occlusion of filling deficit on MR angiography/venography. Outcome is variable; benign intracranial hypertension may develop (p. 364).

A thorough search for causation – coagulation screen, drug history and underlying systemic illness – essential.

Treatment:

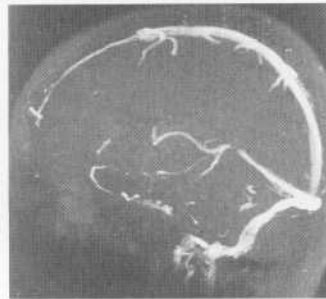
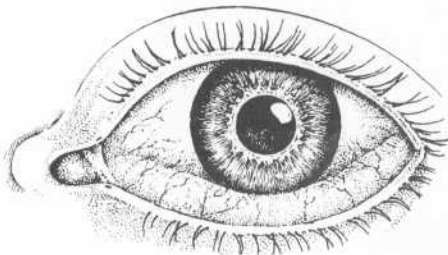
The role of heparin remains uncertain and is currently being evaluated.

Deep cerebral venous thrombosis (10% of cases)

This produces venous infarction of the basal ganglion and other subcortical structures. Presentation with similar features; diagnosis can only be established by imaging (CT/MRI and MRV). The role of heparin is again uncertain.

Cavernous sinus thrombosis (5% of cases)

Commonly results from infection spreading from the jaw through draining veins or paranasal sinuses. Painful ophthalmoplegia, proptosis and chemosis with oedema of periorbital structures are associated with facial numbness and fever. The disorder may be bilateral. Base diagnosis on clinical suspicion supported by venography. Treatment with antibiotics and if indicated, sinus drainage.



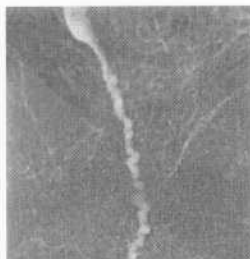MR angiogram showing virtual occlusion of the superior sagittal sinus

CEREBROVASCULAR DISEASE – UNUSUAL FORMS

ABNORMALITIES OF EXTRACRANIAL VESSELS

FIBROMUSCULAR DYSPLASIA

This disease involves intracranial as well as extracranial vessels which appear like a 'string of beads'. The patient presents with infarction as a result of thrombotic occlusion or haemorrhage from an associated saccular aneurysm, of which there is an increased risk. Transluminal angioplasty can be used to dilate a stenotic segment.



Dilated and narrowed segments of vessel. Produced by fibrosis of the lamina media.

SPONTANEOUS ARTERIAL DISSECTION

Extracranial and intracranial dissections are an underdiagnosed cause of stroke in young persons. Spontaneous dissections occur in Marfan's syndrome, fibromuscular dysplasia, migraine and hypertension. Pathological examination often reveals cystic degeneration or necrosis of the media.

TRAUMA TO CAROTID AND VERTEBRAL VESSELS



Internal carotid artery dissection

A direct blow to the neck, a sustained tight grip around the neck or a hyperextension injury may produce an intimal tear of the extracranial vessels. This may lead to dissection and occlusion.

The vertebral arteries are particularly susceptible to trauma in view of their close relationship to the cervical spine at intervertebral foramina, the atlanto-axial joint and the occipito-atlantal joint. Carotid dissection may present with a painful isolated Horner's syndrome.

Angiography will confirm, and exploration and/or anticoagulant therapy may halt thrombus formation.

CERVICAL RIB

Pressure from a cervical rib can result in aneurysmal formation in the subclavian artery with endothelial damage, thrombus formation and embolisation down the arm or retrograde thrombus spread and embolisation to the vertebral and common carotid arteries.

INFLAMMATORY VESSEL OCCLUSION

Infection in structures close to the carotid artery can result in inflammatory change in the vessel wall and secondary thrombosis. In children, infection in the retropharyngeal fossa (tonsillar infection) may cause cerebral infarction. Meningitis (especially pneumococcal) may result in secondary arteritis and occlusion of intracerebral vessels as they cross the subarachnoid space.

MOYAMOYA DISEASE

Bilateral occlusion of the carotid artery at the siphon is followed by the development of a fine network of collateral arteries and arterioles at the base of the brain. This may be a congenital or acquired disorder associated with previous meningitis, oral contraception or granulomatous disease (e.g. sarcoidosis). Children present with alternating hemiplegia, adults with subarachnoid haemorrhage. There is no specific treatment though some use surgical revascularisation procedures.

HOMOCYSTINURIA

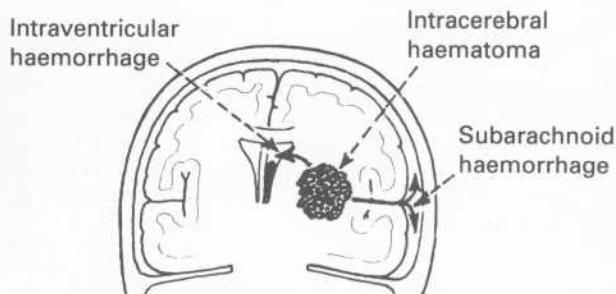
A recessively inherited disorder. Accumulation of homocystine in blood damages endothelium and induces premature occlusive arterial disease. The significance of the heterozygote state is uncertain.

MELAS

See Mitochondrial disorders (page 462)

CEREBROVASCULAR DISEASE – INTRACEREBRAL HAEMORRHAGE

By definition, 'intracerebral haemorrhage' occurs within the brain substance, but rupture through to the cortical surface may produce associated 'subarachnoid' bleeding. When the haemorrhage occurs deep in the hemisphere, rupture into the ventricular system is common.



CAUSES

Hypertension

Amyloid vasculopathy

Aneurysm

Arteriovenous malformation

Neoplasm

Coagulation disorders e.g. haemophilia

Anticoagulants

Vasculitis

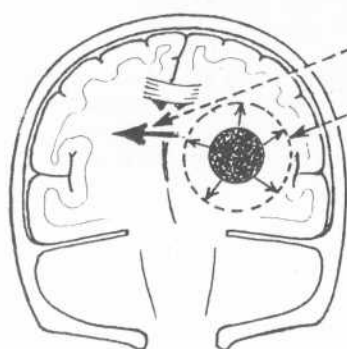
Drug abuse e.g. cocaine

Trauma

Idiopathic

In autopsy series, hypertension accounts for 40–50% of patients dying from non-traumatic haematomas. In hypertensive patients, hyalinisation within the walls of small cerebral vessels results in the formation of 'microaneurysms'. These are small outpouchings or local ectatic dilatations less than 1 mm in size, as initially described by Charcot and Bouchard. They tend to arise on intraparenchymal perforating vessels; rupture therefore occurs within the brain substance. In normotensive patients without any evident underlying pathology the cause remains unknown, but *cryptic arteriovenous malformations* are suspect especially in younger patients (i.e. less than 40 years) and when the haematoma is 'lobar' (i.e. frontal, temporal, parieto-occipital). In these patients, the haematoma may temporarily or permanently obliterate the lesion. Reinvestigation following haematoma resolution occasionally reveals previously undetected malformations. In the normotensive elderly patient, subcortical haematomas are commonly associated with amyloid vasculopathy, a degenerative disorder affecting the walls of arteries.

PATHOLOGICAL EFFECTS



Space-occupying effect – brain shift.

48 hours after the bleed, the haematoma directly affects the adjacent brain substance producing a layer of necrosis surrounded by perivascular bleeding.

Oedema is seldom a prominent feature.

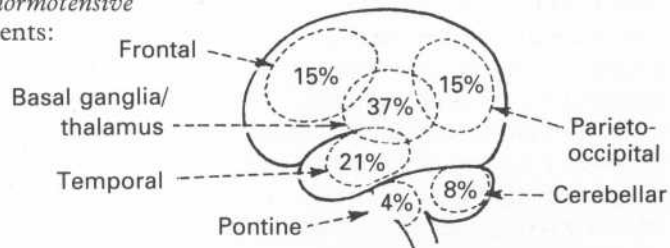
Haematoma resolution occurs in 4–8 weeks, leaving a cystic cavity.

INTRACEREBRAL HAEMORRHAGE

SITES

In *hypertensive* patients, up to 70% occur in the basal ganglia/thalamic region.

In *normotensive* patients:

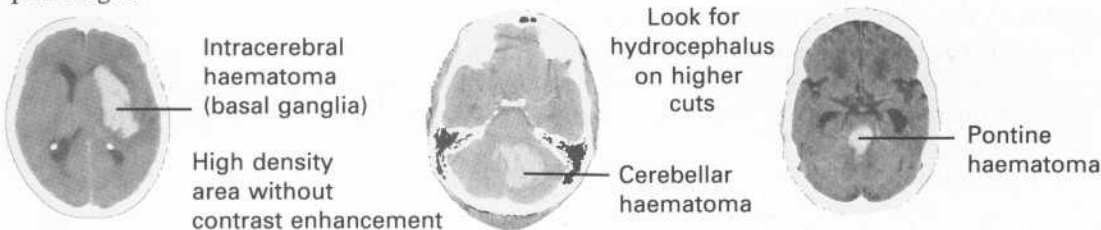


CLINICAL EFFECTS

- | | | |
|-----------------------------|---|----------------------------------------------------------------------------------------------------------------------------------------------------------------------------------------------------------------------------------------------------------------------------------------------------------------------------------------------------------------------------------------------------------------|
| SUPRATENTORIAL
HAEMATOMA | { | <p>Mass effect: Sudden onset of headache followed by either a rapid loss of consciousness or a gradual deterioration in conscious level over 24–48 hours.</p> <p>Focal signs: Hemiparesis, hemisensory loss and homonymous hemianopia are common. The patient may be aware of limb weakness developing prior to losing consciousness. A III nerve palsy indicates transtentorial herniation.</p> |
| CEREBELLAR
HAEMATOMA | – | <p>Sudden onset of headache with subsequent effects developing either acutely or subacutely –</p> <p>Cerebellar and brainstem symptoms and signs, e.g. severe ataxia, dysarthria, nystagmus, vertigo and vomiting</p> <p>CSF obstruction → hydrocephalus with symptoms and signs of ↑ ICP.</p> |
| PONTINE
HAEMATOMA | – | <p>Sudden loss of consciousness</p> <p>Quadraplegia</p> <p>Respiratory irregularities → slowed respiration</p> <p>Pinpoint pupils, pyrexia</p> <p>Skewed/dysconjugate eye movements</p> <p>Death often follows.</p> |

INVESTIGATIONS

A **CT scan** determines the exact site and size of the haematoma and excludes other pathologies.



Angiography

- Performed immediately if clinical state requires urgent operation, to identify a possible arteriovenous malformation or aneurysm.
- Otherwise delayed until condition improves and the haematoma resolves, unless age and medical condition precludes further management.

In patients with negative angiography, a late **MRI** may demonstrate a **CAVERNOUS ANGIOMA** (see page 288).

INTRACEREBRAL HAEMORRHAGE

MANAGEMENT

Supratentorial haematoma

In 1961 a controlled study of conservative versus operative evacuation of intracerebral haematomas (through a craniotomy flap) showed no difference in outcome (McKissock et al) and as a result many surgeons adopted a conservative approach.

More recent studies suggest that in selected patients, operative decompression is worthwhile. In general, haematoma evacuation is indicated in patients who deteriorate gradually from the 'mass' effect, especially when the lesion lies superficially; operation will not benefit moribund patients, i.e. patients extending to painful stimuli with no pupil reaction.

Cerebellar haematoma:

Small haematomas causing minimal effects may be managed conservatively. Otherwise, urgent evacuation through a suboccipital craniectomy is required. Relief of brain stem compression may be life saving and operative morbidity is low.

The overall mortality is approximately 30%.

Pontine haemorrhage

The mortality from pontine haemorrhage is high. A conservative approach is usually adopted although some advocate operative exploration.

INTRAVENTRICULAR HAEMORRHAGE

Haemorrhage into the ventricles causes a sudden loss of consciousness. With a large bleed, death may follow from the pressure transmission from within the ventricular system. Blood in the ventricles does not in itself cause damage and, following clot resolution, complete recovery may occur.

No treatment is required; attempts at flushing out the ventricles usually fail. If the blood 'cast' causes obstructive hydrocephalus, then ventricular drainage (although hampered by the presence of blood) is indicated.

PROGNOSIS

Poor prognostic features

- Large, deep lesions (basal ganglia/thalamic)
- Depth of conscious level (flexion or extension to painful stimuli).

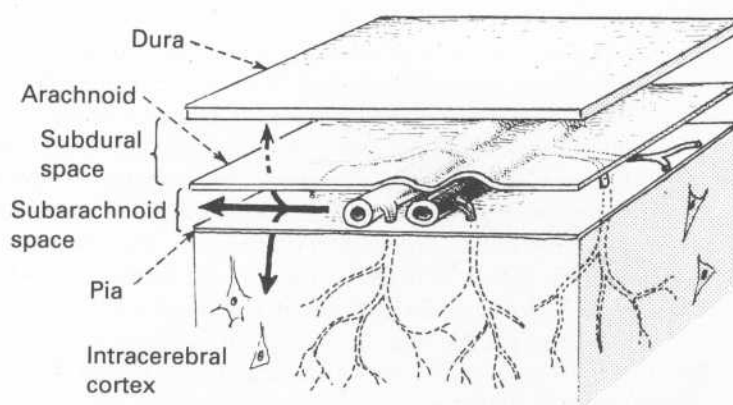
Good prognostic factors

- small superficial lesions (i.e. frontal, temporal or parieto-occipital)
- conscious patients or patients localising to painful stimuli.

The overall mortality ranges from 50–65% (90% if the patient is in coma).

SUBARACHNOID HAEMORRHAGE (SAH)

Intracranial vessels lie in the *subarachnoid* space and give off small perforating branches to the brain tissue. Bleeding from these vessels or from an associated aneurysm occurs primarily into this space. Some intra-cranial aneurysms are imbedded within the brain tissue and their rupture causes intracerebral bleeding with or without sub-arachnoid haemorrhage.



Occasionally the arachnoid layer gives way and a subdural haematoma results.

INCIDENCE

Subarachnoid haemorrhage occurs in approximately 10–15 per 100 000 per year.

CAUSE

Cerebral aneurysms are the most frequent cause of subarachnoid haemorrhage, with arteriovenous malformations accounting for 6%.

In some patients detailed investigation fails to reveal a source of the haemorrhage.

Hypertension may account for some. Cryptic arteriovenous malformations or small thrombosed aneurysms may contribute to the remainder.

CAUSES OF SAH

	Approx. incidence
Aneurysm	70–75%
A-V malformations	5%
Bleeding diathesis	< 5%
Anticoagulants	
Tumours	
Vasculitis	15%
Undefined	

SYMPTOMS AND SIGNS

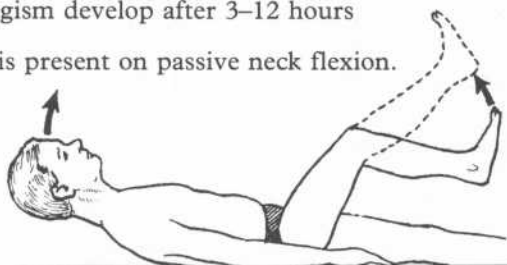
The severity of the symptoms is related to the severity of the bleed.

Usually the *headache* is severe and the onset instantaneous (often described as a 'blow to the head'). A transient or prolonged *loss of consciousness* or *epileptic seizure* may immediately follow. Nausea and *vomiting* commonly occur. Symptoms continue for many days.

Occasionally, the headache is mild (although still instantaneous) and may represent a 'warning leak' of blood before a major bleed.

Signs of meningism develop after 3–12 hours

Neck stiffness is present on passive neck flexion.



Kernig's sign: stretching nerve roots by extending the knee causes pain.

SUBARACHNOID HAEMORRHAGE

SYMPTOMS AND SIGNS (contd)

Coma or depression of conscious level may result from the direct effect of the subarachnoid haemorrhage or from the mass effect of an associated intracerebral haematoma.

Focal damage from a haematoma will produce *focal signs*, e.g. limb weakness, dysphasia. The presence of a III nerve palsy indicates either transtentorial herniation or direct nerve damage from a posterior communicating artery (or rarely from a basilar artery aneurysm).

Epilepsy frequently occurs and may mask other features.

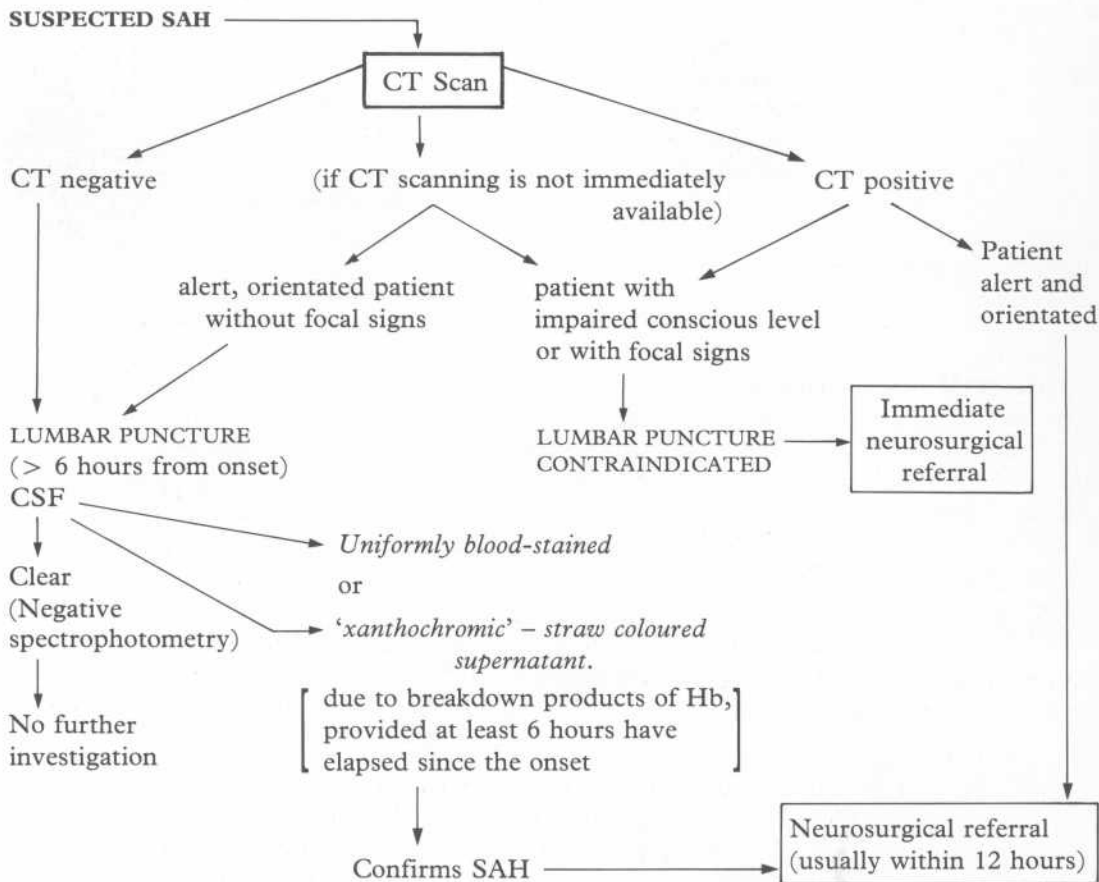
Fundus examination may reveal *papilloedema* or a *subhyaloid* or *vitreous haemorrhage* caused by the sudden rise in intracranial pressure.

A '*reactive hypertension*' commonly develops, i.e. a rise in BP in patients with no evidence of pre-existing hypertension, and takes several days to return to normal levels.

Pyrexia is also a common finding; if severe and fluctuating, it may reflect ischaemic hypothalamic damage.

INVESTIGATIVE APPROACH

Lumbar puncture establishes the diagnosis of subarachnoid haemorrhage, but in patients with a mass lesion, lumbar puncture could precipitate transtentorial herniation.



SUBARACHNOID HAEMORRHAGE

INVESTIGATIVE APPROACH (contd)

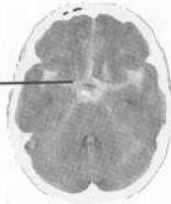Age limit for neurosurgical referral: Although mortality and morbidity increase with age, with modern anaesthetic and operative techniques, many surgeons may even consider patients even over the age of 70 for further investigation with a view to operation, provided their clinical state is satisfactory.

CT Scan

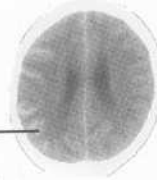
Confirms the diagnosis of SAH in 95% (if within 48 hours of the bleed).

Blood may be *widely distributed*

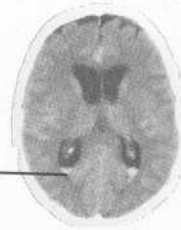- throughout the basal cisterns, Sylvian and interhemispheric fissures



- over the cortical sulci

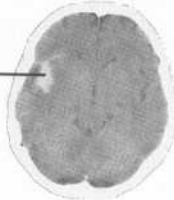


- within the ventricular system

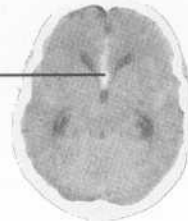

or *more localised* aiding identification of the site of the ruptured aneurysm

- e.g. - within a Sylvian fissure - middle cerebral aneurysm



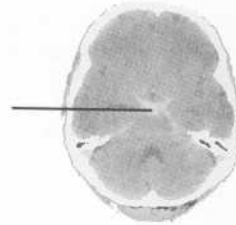
- within the interhemispheric fissure - anterior communicating aneurysm



CT also identifies other associated lesions

- hydrocephalus
- intracerebral haematoma
- tumour
- arteriovenous malformation

Blood restricted to the interpeduncular region and not extending into the lateral Sylvian or interhemispheric fissures (i.e. a '*perimesencephalic*' pattern) is usually associated with a negative angiogram, but angiography is still required to exclude a basilar aneurysm.



MRI scan

Not routinely used, but in patients with multiple aneurysms, MRI performed several days after the bleed may provide greater sensitivity than CT in detecting small areas of subarachnoid clot and help determine the particular lesion responsible.

Angiography

Angiography is usually carried out at the earliest convenience, although in patients in poor clinical condition, the clinician may prefer to delay investigation until improvement has occurred. If a patient deteriorates from the mass effect of an intracranial haematoma, then emergency angiography is required prior to any decompressive operation.

SUBARACHNOID HAEMORRHAGE

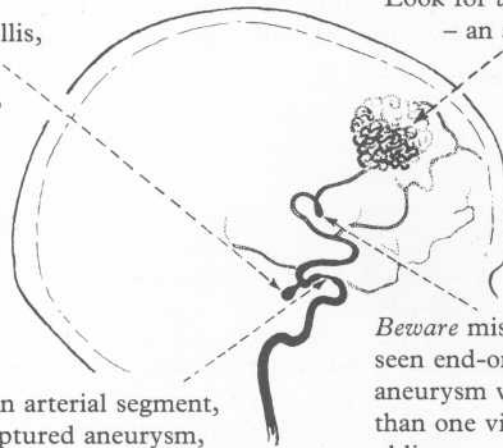
Angiography (contd)

Four-vessel angiography is usually performed in all patients.

Antero-posterior, lateral and oblique views are required for each vessel.

Look for *aneurysms* at vessel bifurcations around the circle of Willis, on the middle cerebral and pericallosal vessels, and on the vertebral artery at the posterior inferior cerebellar artery origin. (Mycotic aneurysms lie more peripherally.)

Carotid angiogram – lateral view



Look for *arteriovenous malformations* – an abnormal tangle of blood vessels demonstrated in the arterial phase. N.B. Small AVMs are difficult to detect and only early filling of a vein may draw attention to their presence.

Note '*spasm*' of an arterial segment, usually near a ruptured aneurysm, although it may be distant or diffuse.

Beware mistaking a vessel loop seen end-on for an aneurysm – an aneurysm will be evident on more than one view, e.g. lateral and oblique.

MAGNETIC RESONANCE ANGIOGRAPHY (MRA) is a useful noninvasive technique for demonstrating intracranial aneurysms (see page 41), but the resolution is still insufficient to ensure that small aneurysms are not missed.

Negative angiography

Angiography fails to reveal a source of the subarachnoid haemorrhage in approximately 20% of patients. In the presence of arterial spasm, reduction in flow may prevent the demonstration of an aneurysm and repeat angiography may be required at a later date.

Prognosis: In patients with a 'perimesencephalic' pattern of haemorrhage on CT scan and with negative angiography, the outlook is excellent; those patients with an 'aneurysmal' pattern with blood lying in the interhemispheric or Sylvian fissure still run a risk of rebleeding.

N.B. Rupture of a spinal angioma also results in SAH – if the patient's pain begins in the back before spreading to the head, or if any features of cord compression are apparent, then myelography should be the preliminary investigation (see page 409).

CEREBRAL ANEURYSMS

INCIDENCE

At autopsy intracranial aneurysms are found in approximately 1% of the population.

Aneurysm rupture occurs in 6–12 per 100 000 per year

Female: male = 3:2
 but this ratio varies with age — < 40 years, male > females
 > 40 years, females > males

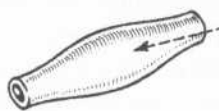
Inheritance: familial occurrence is occasionally seen and is probably associated with procollagen III deficiency, although other factors may be involved.

Age: rupture is most common between 40 and 60 years but can occur in any age group, though rarely in children.

MORPHOLOGY

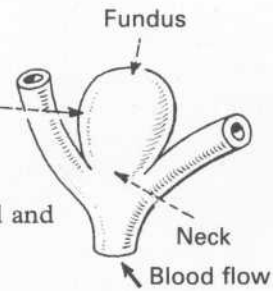
Intracranial aneurysms are usually *saccular*, occurring at vessel bifurcations.

Size varies from a few millimetres to several centimetres. Those over 2.5 cm are termed 'giant' aneurysms.



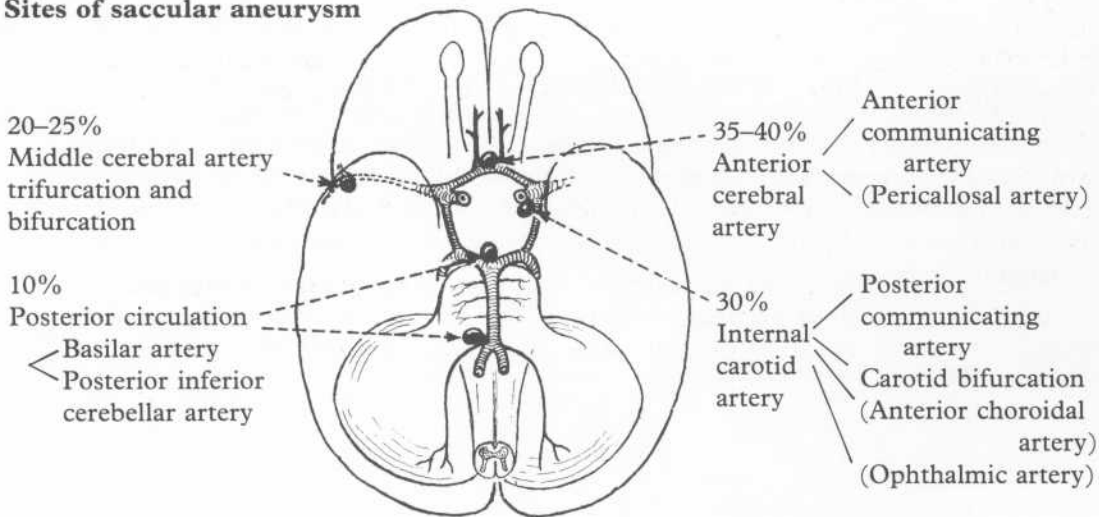
Fusiform dilatation and ectasia of the carotid and the basilar artery may follow atherosclerotic damage. These aneurysms seldom rupture.

Mycotic aneurysms, secondary to vessel wall infection, arise from haematogenous spread, e.g. subacute bacterial endocarditis.



Aneurysm rupture: usually occurs at the fundus of the aneurysm and the risk appears to be related to size; rupture seldom occurs until the aneurysm is over 6 mm in diameter. In some patients, rupture occurs during exertion, straining or coitus, but in many there is no associated relationship. Giant aneurysms surprisingly are less likely to rupture, probably due to multiple layers of thrombus reinforcing the inner wall.

Sites of saccular aneurysm

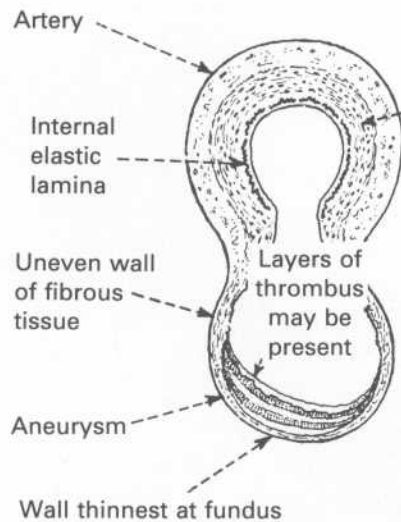


Multiple aneurysms: in approximately 30% of patients with aneurysmal SAH, more than one aneurysm is demonstrated on angiography.

CEREBRAL ANEURYSMS

PATHOGENESIS

The exact cause of aneurysm formation may be multifactorial.



Aneurysms were once thought to be 'congenital' due to the finding of *developmental defects in the tunica media*. These defects occur at the apex of vessel bifurcation as do aneurysms, but they are also found in many extracranial vessels as well as intracranial vessels; saccular aneurysms in contrast are seldom found outwith the skull. Tunica media defects are often evident in children, yet aneurysms are rare in this age group. It now appears that *defects of the internal elastic lamina* are more important in aneurysm formation and these are probably related to arteriosclerotic damage.

Aneurysms often form at sites of *haemodynamic stress* where for example, a congenitally hypoplastic vessel leads to excessive flow in an adjacent artery.

Hypertension may play a role; more than half the patients with ruptured aneurysm have pre-existing evidence of raised blood pressure. (Aneurysm formation is common in patients with hypertension from coarctation of the aorta.)

CLINICAL PRESENTATION

Of those patients with intracranial aneurysms, 90% presenting to neurosurgeons have SAH and 7% have symptoms or signs from compression of adjacent structures. The remainder are found incidentally.

1. Rupture (90%).

The features of SAH have already been described in detail (page 271); they include sudden onset of headache, vomiting, neck stiffness, loss of consciousness, focal signs and epilepsy.

Since the severity of the haemorrhage relates to the patient's clinical state and this in turn relates to outcome, much emphasis has been placed on categorising patients into 5 level grading systems, e.g. Hunt and Hess, Nishioka. Recently a new scale has been formed and approved by the World Federation of Neurosurgeons, incorporating the Glasgow Coma Scale (page 29):

WFNs Grade	Glasgow Coma Score	Motor deficit
I	15	absent
II	14-13	absent
III	14-13	present
IV	12-7	present or absent
V	6-3	present or absent

Glasgow Coma Score		
eye opening	1-4	e.g. no eye opening (1)
verbal response	1-5	no verbal response (1)
motor response	1-6	spastic flexion to pain (3)
	<u>3-15</u>	<u>= 5</u>

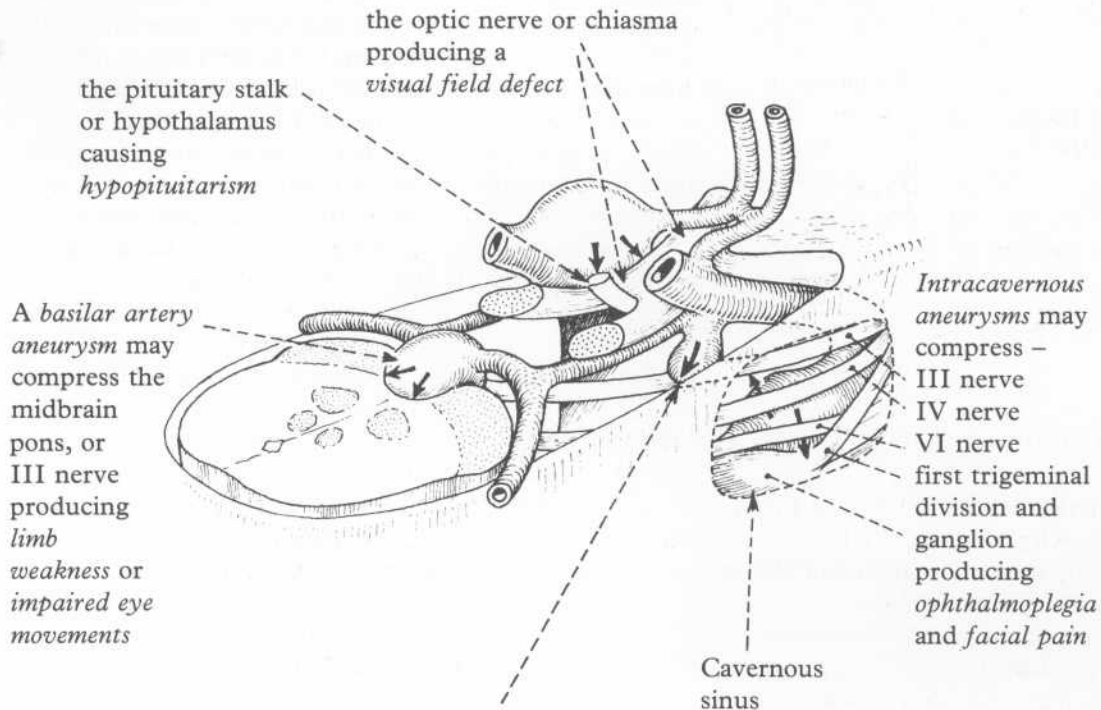
This grading scale correlates well with final outcome and provides a prognostic index for the clinician. In addition, it enables matching of patient groups before comparing the effects of different management techniques.

CEREBRAL ANEURYSMS

CLINICAL PRESENTATION (contd)

2. Compression from aneurysm sac (7%)

A large *internal carotid artery aneurysm* (or *anterior communicating artery aneurysm*) may compress –



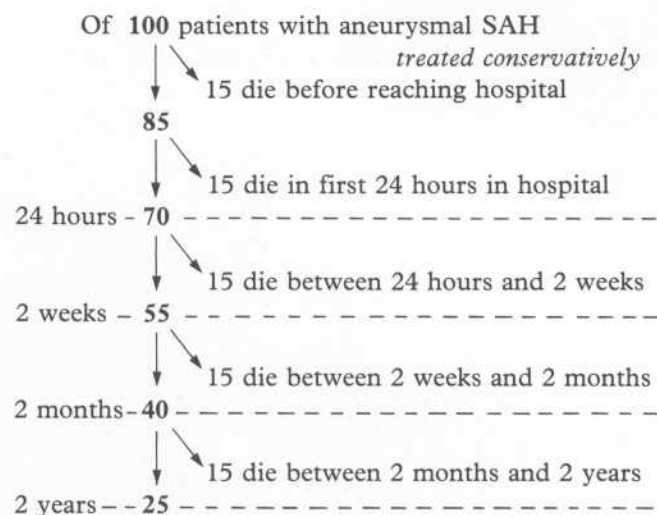
A *posterior communicating artery aneurysm* may produce a *III nerve palsy*. This indicates aneurysm expansion and the need for urgent treatment. Alternatively, it occurs concurrent with SAH.

3. Incidental finding (3%)

Angiography performed for reasons other than SAH, e.g. investigation of ischaemic or neoplastic disease, occasionally reveals previously undetected aneurysms.

CEREBRAL ANEURYSMS

NATURAL HISTORY OF RUPTURED ANEURYSM



SAH from ruptured aneurysm carries a high initial mortality risk which gradually declines with time. Of those who survive the initial bleed, rebleeding and cerebral infarction (see below) are the major causes of death.

These figures are based on studies of conservative treatment carried out in the 1960s, at a time when the risks of operation were greater and benefits uncertain.

COMPLICATIONS OF ANEURYSMAL SAH

INTRACRANIAL

- Rebleeding
- Cerebral ischaemia/infarction
- Hydrocephalus
- 'Expanding' haematoma
- Epilepsy.

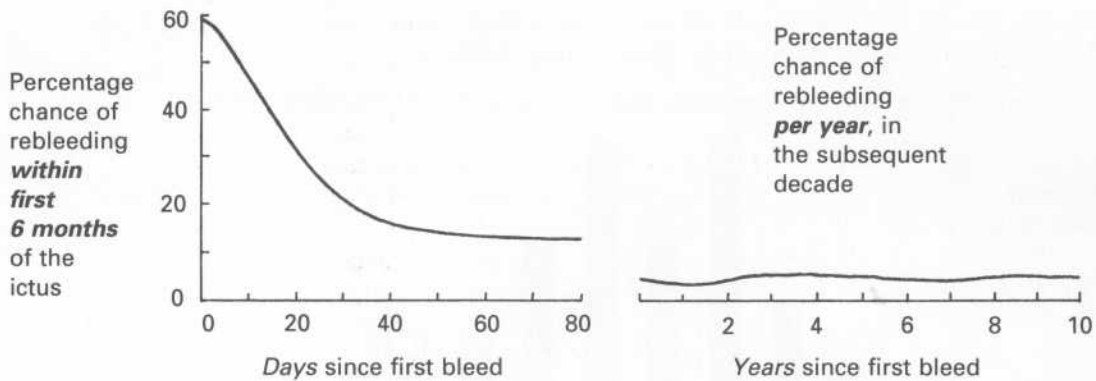
EXTRACRANIAL

- Myocardial infarction
- Cardiac arrhythmias
- Pulmonary oedema
- Gastric haemorrhage (stress ulcer).

CEREBRAL ANEURYSMS – COMPLICATIONS

REBLEEDING

Rebleeding is a major problem following aneurysmal SAH. In the first 28 days (in *untreated* patients), approximately 30% of patients would rebleed; of these 70% die. In the following few months the risk gradually falls off but it never drops below 3.5% per year.



Adapted from Winn, Richardson, June 1977
Annals of Neurology

If, for example, a patient survives the first 30 days after a bleed, there is still a 20% chance of a rebleed occurring in the next 5 months. Even if patients survive the 'high risk' period in the first 6 months, there is still a considerable chance of rebleeding and death in the subsequent years.

The clinical picture of rebleeding is that of SAH, but usually the effects are more severe than the initial bleed. Most patients lose consciousness; the risk of death from a rebleed is more than twice that from the initial bleed.

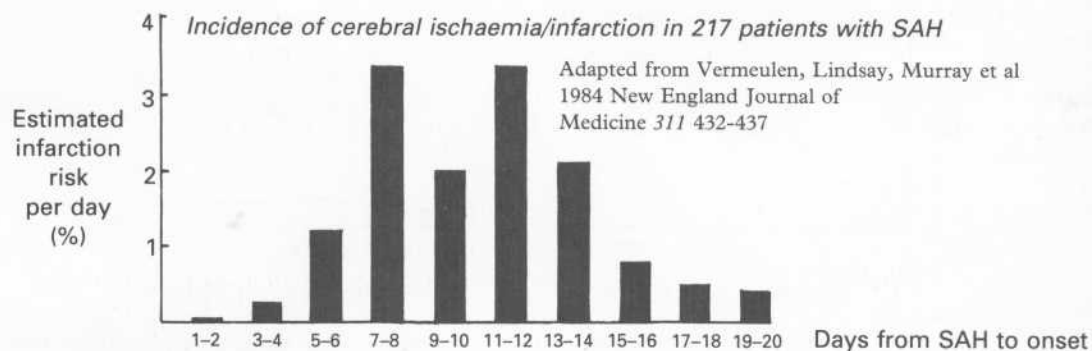
Investigation

All patients deteriorating suddenly require a CT scan. This helps in establishing the diagnosis of rebleeding and excludes a remediable cause of the deterioration, e.g. acute hydrocephalus.

CEREBRAL ANEURYSMS – COMPLICATIONS

CEREBRAL ISCHAEMIA/INFARCTION

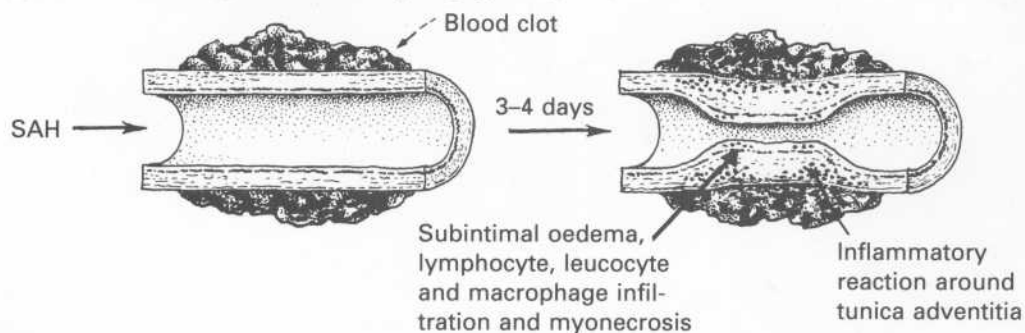
Following subarachnoid haemorrhage, patients are at risk of developing cerebral ischaemia or infarction and this is an important contributory factor to mortality and morbidity. Cerebral ischaemia/infarction may occur as an immediate and direct result of the haemorrhage, but more often develops 4–12 days after the onset, either before or after operation – hence the term ‘delayed cerebral ischaemia’. Approximately 25% of patients develop clinical evidence of delayed ischaemia/infarction; of these 25% die as a result. About 10% of the survivors remain permanently disabled.



Aetiology of cerebral ischaemia/infarction

Several factors probably contribute to the development of cerebral ischaemia or infarction: ‘*Vasospasm*’: arterial narrowing on angiography occurs in up to 60% of patients after SAH and is either focal or diffuse. The development of ‘*vasospasm*’ shows a similar pattern of delay to that of cerebral ischaemia.

The angiogram appearance was initially thought to result from arterial constriction; this may be so, but the pathogenesis of ‘*vasospasm*’ now seems more complex. Many vasoconstrictive substances either released from the vessel wall or from the blood clot appear in the CSF after SAH, e.g. serotonin, prostaglandin, oxyhaemoglobin, but numerous studies with vasoconstrictor antagonists have failed to reverse the angiographic narrowing or to reduce the incidence of ischaemia. This failure may be a result of the *arteriopathic changes* which have been observed in the vessel wall. Only calcium antagonists appear to have a beneficial effect (see page 241).



The greater the amount of blood in the basal cisterns (as shown on CT scan), the higher the incidence of arterial narrowing and associated ischaemic deficits.

CEREBRAL ANEURYSMS – COMPLICATIONS

Hypovolaemia

Hyponatraemia develops after SAH in many patients due to excessive renal secretion of sodium rather than a dilutional effect from inappropriate antidiuretic hormone secretion. Fluid loss and a fall in plasma volume follow.

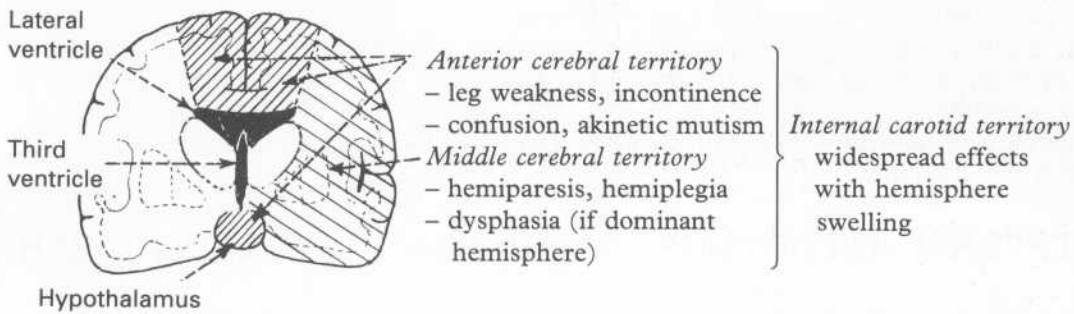
These patients are particularly at risk of developing cerebral ischaemic deficits, probably as a result of increased blood viscosity.

Reduced cerebral perfusion pressure

Following SAH, intracranial haematoma or hydrocephalus may cause a rise in intracranial pressure (ICP). Since cerebral perfusion pressure = mean BP – ICP, a subsequent reduction in cerebral perfusion may occur.

Clinical effects of cerebral ischaemia/infarction

This may affect one particular arterial territory producing characteristic signs:



Commonly the ischaemia occurs in multiple areas, often in both hemispheres. This correlates with the pattern of arterial 'spasm'.

Transcranial Doppler: a significant increase in flow velocity within an intracranial vessel may indicate developing 'vasospasm', even before clinical problems develop, and allow the early introduction of prophylactic measures (see page 255).

HYDROCEPHALUS

Following SAH, cerebrospinal fluid drainage may be impaired by:

- blood clot within the basal cisterns } 'communicating' hydrocephalus
- obstruction of the arachnoid villi } (see page 360)
- blood clot within the ventricular system – 'obstructive' hydrocephalus.

Acute hydrocephalus occurs in about 20% of patients, usually in the first few days after the ictus; occasionally this is a late complication. In only one-third are symptoms of headache, impaired conscious level, dementia, incontinence, or gait ataxia severe enough to warrant treatment.

In a further 10% of patients, hydrocephalus develops late – months or even years after the haemorrhage.

CEREBRAL ANEURYSMS – COMPLICATIONS

'EXPANDING' INTRACEREBRAL HAEMATOMA

Brain swelling around an intracerebral haematoma may aggravate the mass effect of the haematoma; this may cause a progressive deterioration in conscious level or progression of focal signs.

EPILEPSY

Epilepsy may occur at any stage after SAH, especially if a haematoma has caused cortical damage.

Seizures may be generalised or partial (focal).

EXTRACRANIAL COMPLICATIONS

Myocardial infarction/cardiac arrhythmias: electrocardiographic and pathological changes in the myocardium are occasionally evident after SAH, and ventricular fibrillation has been recorded. These problems are likely to occur secondarily to catecholamine release following ischaemic damage to the hypothalamus.

Pulmonary oedema: this occasionally occurs after SAH, probably as a result of massive sympathetic discharge; note the 'pink, frothy' sputum and typical auscultatory and chest X-ray findings.

Gastric haemorrhage: bleeding from gastric erosions occasionally occurs after SAH but rarely threatens life.

CEREBRAL ANEURYSMS – MANAGEMENT FOLLOWING SAH

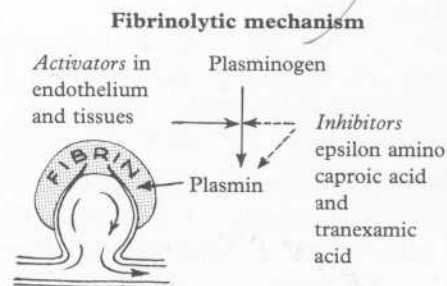
Headache requires *analgesia* → codeine or dihydrocodeine. Stronger analgesics may depress conscious level and mask neurological deterioration. Management is otherwise aimed at preventing complications –

PREVENTION OF REBLEEDING

Bed rest: Usually enforced after SAH, although there is no evidence that this reduces the rebleed risk. Allowing the patient to use the toilet may induce less 'stress' than using a bedpan.

Antifibrinolytic agents: tranexamic acid, epsilon aminocaproic acid.

These agents have been used for many years with the aim of preventing rebleeding by delaying clot dissolution around the aneurysm fundus. Antifibrinolytics do reduce rebleeding (by more than 50%) but at the expense of increasing the incidence of cerebral ischaemia. The overall results showed no improvement in mortality or morbidity.

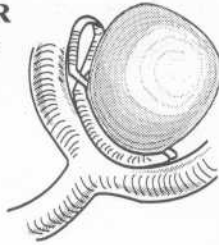


Operation: Clipping of the aneurysm neck is the only certain way of preventing rebleeding, but this technique is not always possible and other methods are sometimes employed. The timing of operation is a controversial topic.

CEREBRAL ANEURYSMS – MANAGEMENT FOLLOWING SAH

METHODS OF ANEURYSM REPAIR

Direct clipping of the aneurysm neck is the optimal method of treatment and prevents further rupture; aneurysm clips rarely slip after application. The operating microscope and improved anaesthetic techniques have considerably lowered mortality and morbidity. Careful dissection of arachnoid tissue around the neck of the aneurysm enables accurate positioning of the clip.



Wrapping: If the width of the aneurysm neck or its involvement with adjacent vessels prevents clipping then muslin gauze may be wrapped around the fundus. This provides some protection but rebleeding can still occur.

Balloon embolisation: Inflating a *balloon* introduced through a special angiographic catheter within the aneurysm sac has had very limited success. The technique carries a risk of causing immediate aneurysm rupture or of allowing balloon fragments to pass into the distal circulation causing an embolic stroke. Results have shown that even apparent successful balloon occlusion does not necessarily prevent rebleeding in the long term. Using a balloon to occlude the neck of an aneurysm *along with the parent vessel* e.g. for a 'giant' ophthalmic 'artery aneurysm', should produce a permanent repair provided the patient can tolerate the occlusion (see below).

Coil embolisation: In recent years, radiologists have succeeded in inserting single or multiple helical platinum coils into the aneurysm sac to induce thrombosis. Although this is still an experimental technique, results are encouraging.

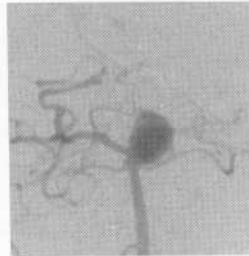A tracker catheter is guided through the aneurysm neck. The coil, attached to the end of a delivery wire, is inserted through the catheter into the aneurysm fundus. After accurate placement, the passage of an electric current causes electrochemical release from the delivery wire.

Complications may still occur during the procedure and unless the fundus is completely obliterated, rebleeding may still follow. The wider the aneurysm neck and the larger the size, the smaller the chance of producing complete obliteration.

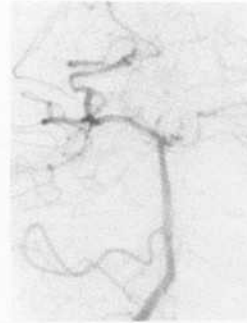
Without this, rebleeding can occur.

Unfortunately early work suggests that aneurysms that surgeons find difficult to clip also pose difficulty to the radiologist. Whether or not coil embolisation will improve the results obtained by direct clipping will take many years to evaluate.

Trapping: clipping of proximal and distal vessels is the only possible treatment for some aneurysms, e.g. 'giant' and intracavernous aneurysms. This prevents rebleeding but carries a high risk of producing an ischaemic deficit. A bypass procedure – superficial temporal to middle cerebral anastomosis, prior to trapping – may help minimise the risk of this complication (see page 287).



Basilar bifurcation aneurysm before coil embolisation

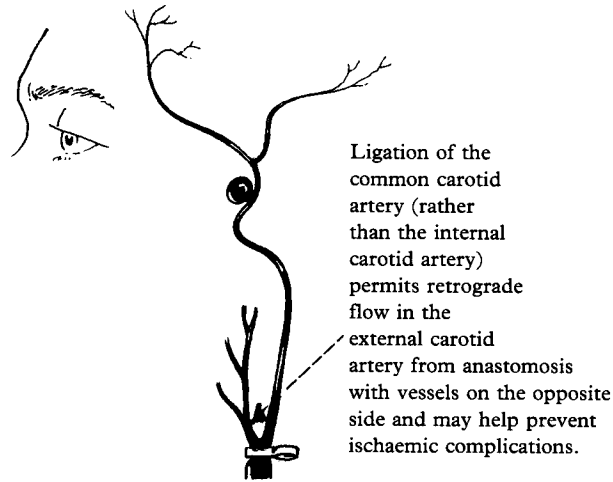


after coil embolisation showing complete obliteration.

CEREBRAL ANEURYSMS – MANAGEMENT FOLLOWING SAH

METHODS OF ANEURYSM REPAIR (*contd*)

Proximal occlusion – common carotid ligation: this technique is used for aneurysms arising directly from the carotid artery where clipping has failed or was not attempted, e.g. an intracavernous aneurysm or 'giant' ophthalmic artery aneurysm. Most patients tolerate common carotid occlusion; collateral circulation through the circle of Willis and perhaps from reverse flow in the external carotid artery usually provides sufficient hemispheric flow to prevent ischaemic complications. Balloon occlusion of the internal carotid artery is an alternative technique.



Cerebral blood flow studies during temporary occlusion, or temporary occlusion under local anaesthesia can predict patients who fail to tolerate this but these methods are not infallible and late ischaemic deficits occasionally occur.

Carotid ligation prevents the patient from rebleeding in the 'high risk' period. Beyond the first 6 months, the rebleed risk reverts to that of an untreated aneurysm, i.e. 3.5% per year.

TIMING OF OPERATION

Pioneers of aneurysm surgery found that operation within a day or two of the haemorrhage carried an unacceptably high risk. Operative mortality rates dramatically fell when operation was delayed for several weeks. The longer the delay, the better the results; but the longer the delay, the greater the possibility of death from rebleeding. The clinical condition or 'grade' of the patient also played a major part; the worse the grade the worse the outcome. As a result, surgeons adopted an optimal delay period of 6–14 days from the haemorrhage, the exact time depending on the patient's clinical condition.

In recent years, with improved operative and anaesthetic techniques, 'early' operation within a few days of the haemorrhage has become feasible. Most surgeons now advocate operation within 3 days if possible for patients in grade I or II. The additional risks appear small and are outweighed by the benefit of preventing rebleeding.

Once the aneurysm is clipped, aggressive methods of treating ischaemia with induced hypertension can be applied. The optimal time for operation in poorer grade patients remains controversial and requires further study.

CEREBRAL ANEURYSMS – MANAGEMENT FOLLOWING SAH

PREVENTION OF CEREBRAL ISCHAEMIA/INFARCTION

Despite considerable clinical and experimental research, cerebral ischaemia is still a major cause of morbidity and mortality after subarachnoid haemorrhage. In recent years some advances have proved beneficial.

Calcium antagonists: several large studies have confirmed that Nimodipine and Nicardipine both reduce the incidence of cerebral infarction by about one third and improve outcome. Whether these act by improving collateral circulation, by reducing the harmful effect of calcium flooding into brain cells or by reducing cerebral 'vasospasm' remains uncertain.

Avoidance of antihypertensive therapy: antihypertensive therapy was once widely used after SAH to reduce 'reactive' hypertension and theoretically to minimise the risk of rebleeding. In the normal subject a drop in BP results in cerebral vasodilatation to maintain cerebral flow (autoregulation, page 75). After SAH, autoregulation is often impaired; a drop in BP causes a reduction in cerebral blood flow with a subsequent risk of cerebral ischaemia. Accumulated evidence shows that patients with SAH on antihypertensive therapy have a significantly higher risk of cerebral infarction.

High fluid intake: maintenance of a high fluid input (3 litres per day) may help prevent a fall in plasma volume from sodium and fluid loss. If hyponatraemia develops do *not* restrict fluids (this significantly increases the risk of cerebral infarction). If sodium levels fall below 130 mmol/l, give fludrocortisone or hypertonic saline.

Plasma volume expansion: expanding the plasma volume with colloid, e.g. plasma proteins, dextran 70, Haemacel, increases blood pressure and improves cerebral blood flow. This should be given either prophylactically in high risk patients (heavy cisternal blood load on CT scan or with high Doppler velocities) or at the first clinical sign of ischaemia. If clinical evidence of ischaemia develops despite this treatment, then combine with:

Hypertensive therapy: treatment with inotropic agents, e.g. dobutamine, increases cardiac output and blood pressure. Since cerebral autoregulation commonly fails after subarachnoid haemorrhage, increasing blood pressure increases cerebral blood flow. Up to 70% of ischaemic neurological deficits developing after aneurysm operations can be reversed by inducing hypertension; often a critical level of blood pressure is evident.

Early recognition and treatment of a developing neurological deficit may prevent progression from ischaemia to infarction. Delayed treatment may merely aggravate vasogenic oedema in an ischaemic area. This technique of induced hypertension is now widely applied, with good results, but requires careful, intensive monitoring. In view of the risk of precipitating aneurysm rupture, it is reserved until after aneurysm clipping.

Brain protective agents: several newly developed neuroprotective drugs (other than the calcium antagonists (see page 241) are currently under study in patients with subarachnoid haemorrhage but as yet their value remains unknown.

CEREBRAL ANEURYSMS – MANAGEMENT FOLLOWING SAH

HYDROCEPHALUS

Hydrocephalus causing acute deterioration in conscious level requires urgent CSF drainage with a ventricular catheter (in 'communicating' hydrocephalus lumbar puncture may provide temporary benefit).

Gradual deterioration or failure to improve in the presence of enlarged ventricles indicates the need for permanent CSF drainage with either a ventriculoperitoneal or lumboperitoneal shunt.

EXPANDING INTRACEREBRAL HAEMATOMA

Intracerebral haematomas from ruptured aneurysms do not require specific treatment unless the 'mass' effect causes a deterioration of conscious level. This necessitates urgent angiography followed by evacuation of the haematoma with or without simultaneous clipping of the aneurysm; under these circumstances, operative mortality is high.

OUTCOME AFTER SUBARACHNOID HAEMORRHAGE

Of patients surviving the initial bleed and admitted within 3 days to the neurosurgical unit, approximately one-quarter die within the following 3 months. Over half make a good recovery and regain former employment, although in a proportion, minor personality change and intellectual deficit persist.

Factors providing a prognostic guide are: age, quantity of subarachnoid blood on CT scan, loss of consciousness at the ictus, clinical condition on admission and the presence of pre-existing hypertension or arterial disease.

Operative mortality (i.e. mortality rate in patients undergoing operation) ranges from 8–45% depending on the patient's clinical condition and the timing of operation.

Management mortality takes into account all patients, including those not undergoing operation due to premature death or poor clinical condition. These figures are of more value when comparing results of different management regimes.

Operative mortality (at 6 months)

No. of patients undergoing operation – 2922

Preoperative state	No.	Mortality(%)	Good recovery(%)
alert	1882	8	78
drowsy	727	19	58
stuporose	202	35	33
comatose	111	45	13
Total	2922	14	68

Management mortality (at 6 months)

No. of patients admitted to the centre within 3 days of the haemorrhage – 3521

State on admission	No.	Mortality(%)	Good recovery(%)
alert	1722	13	74
drowsy	1136	28	54
stuporose	348	44	30
comatose	315	72	11
Total	3512	26	58

Adapted from Kassell, Torner, Haley et al. 1990. *Journal of Neurosurgery* 73:18–36.

This is the largest recent study reviewing the timing of aneurysm surgery, collecting data from 68 neurosurgical centres throughout the world

Comparing different operative or management policies: Comparison of different treatments for ruptured aneurysms is difficult, unless conducted under the confines of a randomised controlled trial. 'Operative mortality' provides limited information unless patient groups are carefully matched for age, clinical condition and timing of operation. 'Management mortality' (e.g. outcome of all admitted patients up to 3 months from the ictus) is of more practical value, but even then, admission policies require careful scrutiny.

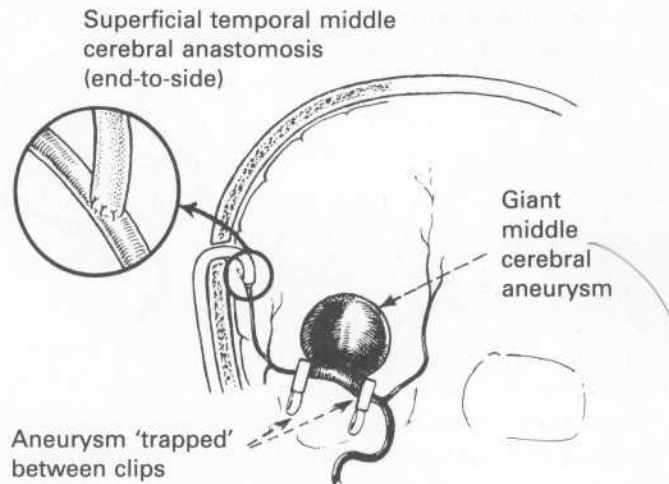
CEREBRAL ANEURYSMS – MANAGEMENT

ANEURYSMS CAUSING COMPRESSIVE SYMPTOMS AND SIGNS

Aneurysms may present as a result of compression of adjacent neurological structures. An oculomotor (III) nerve palsy from a posterior communicating aneurysm often precedes rupture by a few days or weeks and indicates the need for urgent operative treatment.

A giant aneurysm (over 25 mm in diameter), causing compressive problems, seldom ruptures but the symptoms and signs are unlikely to resolve unless spontaneous thrombosis occurs.

Direct clipping and aspiration or excision of the sac provides the best treatment. In some patients the size of the aneurysm neck prevents clipping and either carotid occlusion (if a carotid aneurysm) or 'trapping' provide alternative methods. Prior to 'trapping', superficial temporal middle cerebral anastomosis may help prevent ischaemic complications.



INCIDENTAL ANEURYSMS

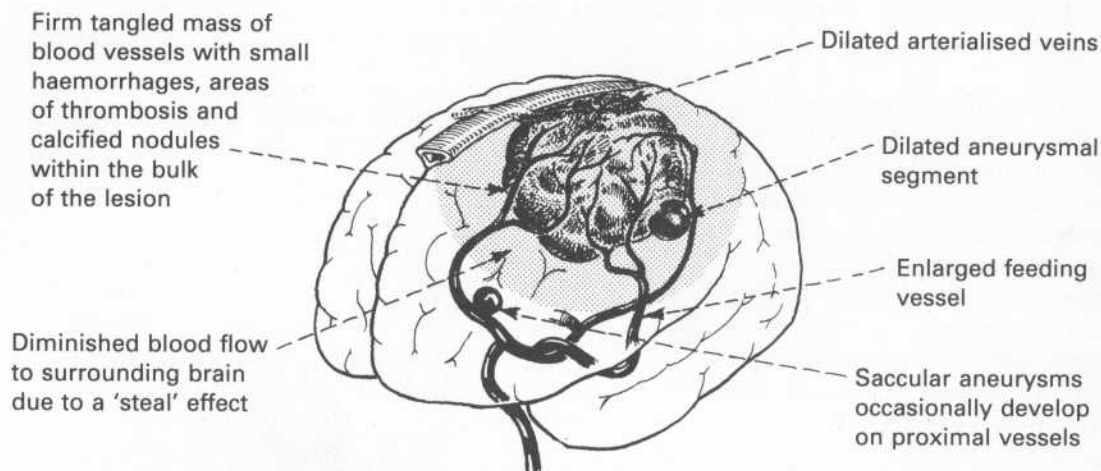
The appearance of high resolution CT and MR scanners and angiographic screening of patients with a strong family history of subarachnoid haemorrhage, has led to the detection of increased numbers of patients with incidental aneurysms (i.e. aneurysms not causing symptoms or signs). Studies suggest that risk of bleeding from a previously unruptured aneurysm approaches 1% per year, with aneurysms over 10 mm in diameter carrying the highest risk.

Operative mortality of aneurysm clipping in the absence of SAH is approximately 2%. Thus, younger patients (e.g. under 45 years) with an otherwise normal life expectancy may well benefit from operation.

When angiography after SAH reveals multiple aneurysms the neurosurgeon must decide whether to operate on the intact as well as the ruptured aneurysm. If accessible through the one craniotomy flap, most clip unruptured aneurysms at the initial operation, although in patients in poor clinical condition, delayed clipping at a second operation several weeks later minimises the risk of ischaemic complications.

ARTERIOVENOUS MALFORMATIONS

Arteriovenous malformations (AVMs) are development anomalies of the intracranial vasculature; they are not neoplastic despite their tendency to expand with time and the descriptive term 'angioma' occasionally applied.



Dilated arteries feed directly into a tangled mass of blood vessels of varying calibre; they bypass the capillary network and shunt oxygenated blood directly into the venous system. As a result of raised intraluminal pressure, veins may adopt an 'aneurysmal' appearance. Arteriovenous malformations may occur at any site but are commonest in the middle cerebral artery territory.

Vascular malformations vary in size and different forms exist:

Capillary telangiectasis: an area of dilated capillaries, like a small petechial patch on the brain surface – especially in the pons. These lesions are often only revealed at autopsy.

Cavernous malformation/angioma: plum coloured sponge-like mass composed of a collection of blood filled spaces, but without enlargement of feeding or draining vessels.

CLINICAL PRESENTATION

Haemorrhage

About 40–60% of patients with an AVM present with haemorrhage – often with an intracerebral or intraventricular component. In comparison with saccular aneurysms, AVMs tend to bleed in younger patients, i.e. 20–40 years, and are less likely to have a fatal outcome. Vasospasm and delayed ischaemic complications rarely develop. Small AVMs are at greater risk of bleeding than larger lesions.

Risk of initial and recurrent bleeding: the risk of haemorrhage over a 5-year period in patients with a previously unruptured AVM is approximately 15% (i.e. 2–3% per year); however, this risk increases to 50% over 5 years for lesions under 3 cm in size.

After a haemorrhage, the chance of a further bleed is slightly increased in the first year but beyond that the risk reverts to that of an unruptured AVM.

Mortality from haemorrhage: in contrast to the high mortality following aneurysm rupture, haemorrhage from an AVM carries the relatively low mortality rate of approximately

ARTERIOVENOUS MALFORMATIONS

CLINICAL PRESENTATION (*contd*)

Epilepsy

Generalised or partial seizures commonly occur in patients with arteriovenous malformation, especially if the lesion involves the cortical surface. Of patients presenting with haemorrhage, 30% have a history of epilepsy.

Neurological deficit

Large AVMs, especially those involving the basal ganglia, may present with a slowly progressive dementia, hemiparesis or visual field defect, probably as a result of a 'steal' effect. The infrequent brain stem AVM may also produce a motor or sensory deficit, with or without cranial nerve involvement.

Headache

Attacks of well localised headache – unilateral and throbbing – occur in a proportion of patients subsequently shown to have a large AVM.

Cranial bruit

Auscultation, especially over the eyeball, occasionally reveals a bruit.

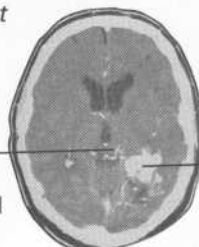
INVESTIGATIONS

CT scan

Most AVMs are evident on CT scan unless masked by the presence of an intracranial haematoma. A double dose of intravenous contrast may aid visualisation, especially with small 'cryptic' lesions.

After i.v. contrast

Streaks of enhancement represent dilated feeding and draining vessels



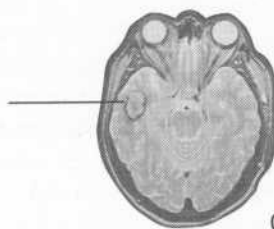
Irregular lesion strongly enhancing with contrast

Calcification may be evident on the plain CT.

MRI

Conventional MRI will clearly demonstrate the AVM as a region of flow voids, with associated signal change within or around the lesion from areas of old haemorrhage or gliosis.

MRI is the investigation of choice in identifying a *cavernous malformation*, often missed on CT scanning and rarely seen on angiography. Most lesions show marked signal change around this lesion due to a rim of haemosiderin deposition.



Cavernous Malformation

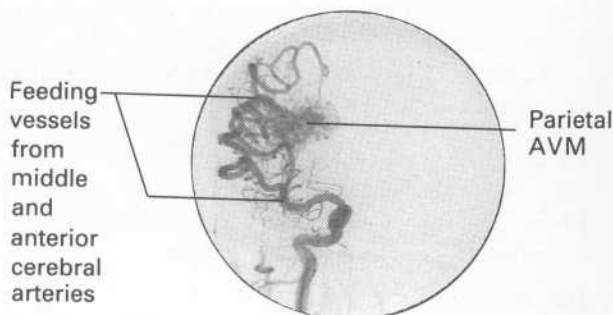
ARTERIOVENOUS MALFORMATIONS

INVESTIGATIONS (contd)

Angiography

Four-vessel angiography confirms the presence of an AVM and delineates the feeding and draining vessels. Occasionally small AVMs are difficult to detect and only *early venous filling* may draw attention to their presence.

N.B. In the presence of a haematoma, angiography should be delayed until the haematoma resolves, otherwise local pressure may mask demonstration of an AVM. If the angiogram is subsequently negative, then MRI is required to exclude the presence of a cavernous malformation.



MANAGEMENT

Various methods of treating arteriovenous malformations are available, but all risk further damage. The urgency of the patient's clinical condition and the risks of treatment must be weighed against the risk of a conservative approach.

Indications for intervention

- 'Expanding' haematoma associated with the AVM
- Risk of haemorrhage, especially – younger patients with many years 'at risk'
 - with AVM in 'non-eloquent' site
 - with AVM < 3 cms diameter.
- Progressive neurological deficit.

Operative removal may not benefit epilepsy control.

Methods of treatment

Operation: *Excision* – complete excision of the AVM (confirmed by per- or postoperative angiography) is the most effective method of treatment. Image guided surgery (see page 372) may aid localisation of small AVMs or cavernous malformations. Some deeply situated lesions in the basal ganglia or brain stem are inoperable in view of the risk of neurological deficit.

Stereotactic

radiotherapy: Standard radiotherapy is of no value in the treatment of AVMs, but focused beams either from multiple cobalt sources or from a linear accelerator, can obliterate up to 80% of lesions under 3 cms in diameter within two years of treatment. Results are far less encouraging for larger lesions, although a combination of embolisation and stereotactic radiotherapy may provide an alternative treatment method for large inoperable AVMs in the future. Although avoiding direct operative damage, stereotactic irradiation destroys tissue locally at the target site. The larger the dose, the greater the chance of AVM obliteration, but the greater the risk of neurological deficit from local tissue destruction. A further disadvantage is the possible delay of up to two years before obliteration occurs. Despite this, stereotactic irradiation may prove ideal for some deeply situated lesions.

ARTERIOVENOUS MALFORMATIONS

Methods of treatment (*contd*)

Embolisation: Skilled catheterisation permits selective embolisation of feeding vessels with isobutyl-cyanoacrylate, although this technique is not without risk. Embolisation alone is unlikely to produce complete obliteration, but used preoperatively, it may significantly aid operative removal.

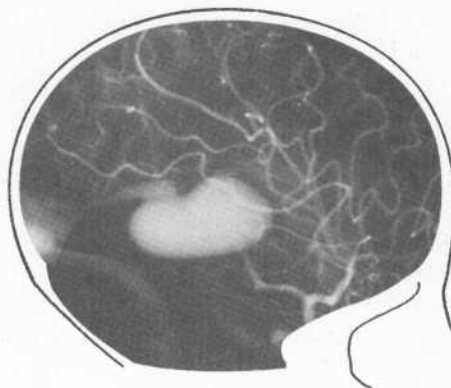Occlusion of feeding vessels: Repeat investigation shows that occlusion of feeding vessels, whether by direct operation or by an endovascular balloon, fails to prevent persistent filling of the AVM due to dilated collaterals.

CAVERNOUS MALFORMATIONS (*syn. cavernous angioma*)

With the appearance of improved imaging, in particular MRI, cavernous malformations are now identified as a source of intracranial haemorrhage in some patients with an otherwise normal CT scan and angiogram. They occur in 0.5% of the population, are occasionally multiple and in a few patients, have a familial basis. A cavernous malformation may present with epilepsy, haemorrhage or with focal neurological signs. Once diagnosed the risk of haemorrhage is 0.7% per year. Lesions in accessible sites are readily excised with little risk; a conservative approach is adopted for those in the basal ganglia, thalamus or brainstem, wherever possible.

ANEURYSM OF THE VEIN OF GALEN

This is a type of arteriovenous malformation in which arteries feed directly into the great vein of Galen causing massive aneurysmal dilatation. Patients present either in the neonatal period with severe high output cardiac failure due to the associated arteriovenous shunt, in infancy with cranial enlargement due to an obstructive hydrocephalus, or in childhood with subarachnoid haemorrhage. A cranial bruit is always evident. Cardiac failure usually develops in the neonatal period and is usually fatal. In the other groups the treatment of choice is now endovascular obliteration of the feeding vessels combined with ventricular drainage if required. As a result, the high mortality and morbidity experienced with direct operative repair has considerably reduced.



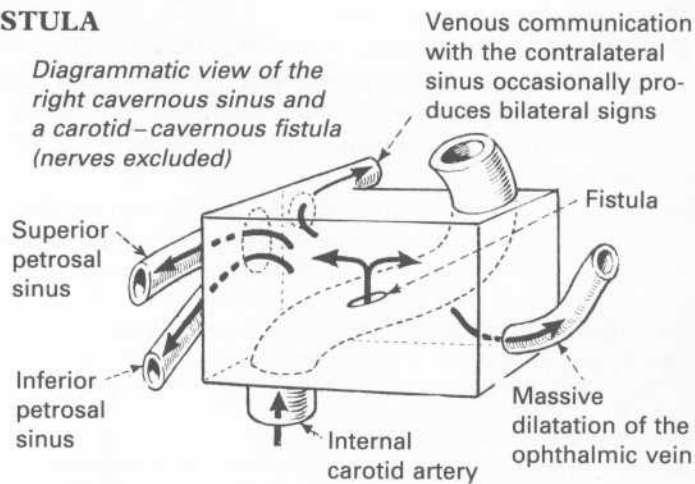
STURGE-WEBER SYNDROME

Angiomatosis affecting the facial skin, eyes and leptomeninges produces the characteristic features of the Sturge-Weber syndrome – a capillary naevus over the forehead and eye, epilepsy and intracranial calcification. (See page 542.)

ARTERIOVENOUS MALFORMATIONS

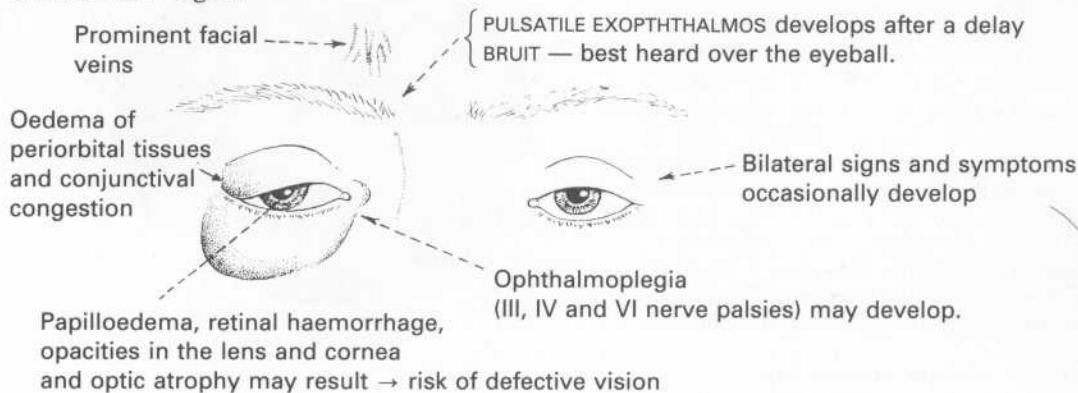
CAROTID - CAVERNOUS FISTULA

A fistulous communication between the internal carotid artery and the cavernous sinus may follow skull base trauma either immediately or after a delay of several days or weeks. Less often carotid-cavernous fistulae occur spontaneously from rupture of a small intracavernous meningeal artery or a saccular carotid aneurysm.



Clinical features

Symptoms develop *suddenly* (cf. cavernous sinus thrombosis) – the patient becomes aware of pulsating tinnitus a ‘noise’ inside the head. Pain may follow. Examination reveals characteristic signs:



Methods of fistula repair

Spontaneous closure occurs in up to 60%. Provided symptoms do not progress, for the first few months, treatment should be conservative.

Trapping: ligation of the supraclinoid carotid and ophthalmic arteries intracranially, followed by ligation of the internal carotid artery in the neck.

Direct operative repair: repair of the fistula within the cavernous sinus with the aid of cardiopulmonary bypass.

Embolisation: – with muscle emboli or plastic beads introduced into the internal carotid artery
– with detachable balloon catheterisation, either transvenous or intra-arterial.

The multiplicity of methods of fistula repair reflect the difficulties and limitations of each technique. None are without risk. In expert hands, transvenous or intra-arterial embolisation may prove to be the most satisfactory method.

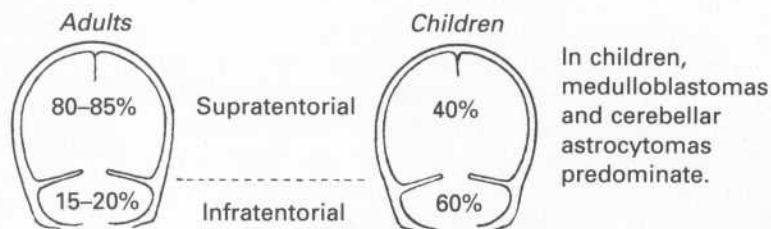
INTRACRANIAL TUMOURS

INCIDENCE

Primary brain tumours occur in approximately 6 persons per 100 000 per year. Fewer patients with metastatic tumours reach a neurosurgical centre, although the actual incidence must equal, if not exceed that of primary tumours. About 1 in 12 primary brain tumours occur in children under 15 years.

SITE

In adults, the commonest tumours are gliomas, metastases and meningiomas; most lie in the supratentorial compartment.



PATHOLOGY

Intracranial tumours are often described as 'benign' or 'malignant', but these terms cannot be directly compared with their extracranial counterparts:

A *benign* intracranial tumour may have devastating effects if allowed to expand within the rigid confines of the skull cavity. A benign astrocytoma may infiltrate widely throughout brain tissue preventing complete removal, or may occupy a functionally critical site preventing even partial removal.

A *malignant* intracranial tumour implies rapid growth, poor differentiation, increased cellularity, mitosis, necrosis and vascular proliferation, but metastases to extracranial sites rarely occur.

Pathological classification

In 1979, the World Health Organisation drew up an internationally agreed classification of intracranial tumours based on the tissue of origin. This system avoids the term 'glioma' – previously encompassing astrocytoma, oligodendroglioma, ependymoma and glioblastoma multiforme. Since the cell origin of the highly malignant glioblastoma is unrecognisable, this is classified along with tumours of embryonic origin.

INTRACRANIAL TUMOURS – PATHOLOGICAL CLASSIFICATION

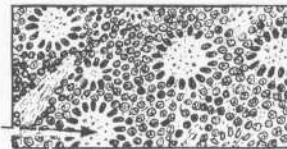
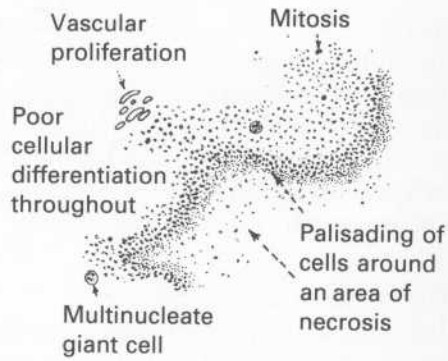
NEUROEPITHELIAL

- Astrocytes → **Astrocytoma:** The most common primary brain tumour. Histological features permit separation into four grades depending on the degree of malignancy. Grading is of limited accuracy and only reflects the features of the biopsy specimen and not necessarily those of the whole tumour. The most malignant type – anaplastic astrocytoma (grade IV) – occurs most frequently and widely infiltrates surrounding tissue. The less common low-grade astrocytomas include the pilocytic (juvenile) type, fibrillary, protoplasmic and gemistocytic types.
- Oligodendrocytes → **Oligodendroglioma:** Usually a slowly growing, sharply defined tumour. Variants include an anaplastic (malignant) form and a ‘mixed’ astrocytoma oligodendroglioma.
- Ependymal cells and choroid plexus → **Ependymoma:** Occurs anywhere throughout the ventricular system or spinal canal, but is particularly common in the 4th ventricle and cauda equina. It infiltrates surrounding tissue and may spread throughout the CSF pathways. Variants include an anaplastic type and a subependymoma arising from subependymal astrocytes.


→ **Choroid plexus papilloma:** Rare tumours and an uncommon cause of hydrocephalus due to excessive CSF production. They are usually benign but occasionally occur in a malignant form.
- Neurons → **Ganglioglioma/gangliocytoma/neuroblastoma:** Rare tumours containing ganglion cells and abnormal neurons. Occur in varying degrees of malignancy.
- Pineal cells → **Pineocytoma/pineoblastoma:** Extremely rare tumours. The latter are less well differentiated and show more malignant features.
- Poorly differentiated and embryonic cells → **Glioblastoma multiforme:** A highly malignant tumour with no cell differentiation, preventing identification of its tissue origins.

→ **Medulloblastoma:** A malignant tumour of childhood arising from the cerebellar vermis. Small closely packed cells are often arranged in rosettes surrounding abortive axons. May seed through the CSF pathways.

Composite diagram showing the characteristic features of a malignant astrocytoma.

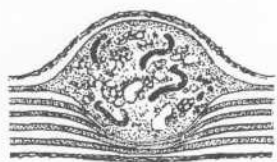

INTRACRANIAL TUMOURS – PATHOLOGICAL CLASSIFICATION

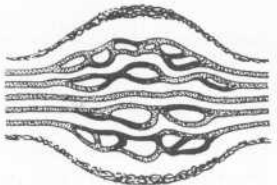
- MENINGES** → **Meningioma:** Arise from the arachnoid granulations, usually closely related to the venous sinuses but also found over the hemispheric convexity. The tumours compress rather than invade adjacent brain. They also occur in the skull base, spinal canal and orbit. Most are benign (despite their tendency to invade adjacent bone) but some undergo sarcomatous change.
- 
- Whorls of fibrous tissue and spindle cells
Calcified psammoma bodies
- Histological types – syncytial, transitional, fibroblastic and angioblastic.
The haemangio-pericytoma variant is poorly differentiated and aggressive in nature.
- **Meningeal sarcoma** and primary **Meningeal melanoma:** Exceedingly rare tumours.

NERVE SHEATH CELLS

- **Neuroma:**
(Syn. neurilemmoma/schwannoma): a non-invasive, slowly growing tumour of the Schwann cells, surrounding the vestibular part of the VIII cranial nerve roots or the peripheral nerves. Different histological types exist:



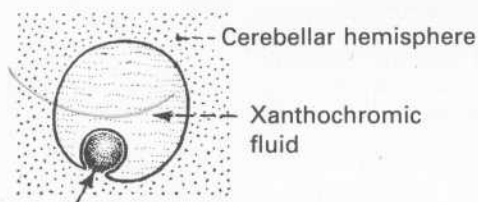
Antoni type A } see page 321
Antoni type B }

- **Neurofibroma:** tumour of Schwann cells and fibroblasts producing a fusiform expansion through which nerve fibres run. It involves the spinal nerve roots or peripheral nerves but rarely affects cranial nerves and has a greater tendency to undergo malignant change than schwannoma. This tumour is the type associated with Von Recklinghausen's disease, although schwannomas and mixed tumours also occur (see page 540).
- 

N.B. Many tumours have mixed characteristics in varying proportions.

BLOOD VESSELS

- Haemangioblastoma:** Occurs within the cerebellar parenchyma or spinal cord. In 1926, Lindau described a syndrome relating cerebellar and/or spinal haemangioblastomas with similar tumours in the retina and cystic lesions in the pancreas and kidney (Von Hippel-Lindau disease).



Reddish brown tumour nodule lying in the wall of the cyst. Histology shows a mass of blood vessels separated by clear, foamy vacuolated cells

INTRACRANIAL TUMOURS – PATHOLOGICAL CLASSIFICATION

GERM CELLS

- **Germinoma:** Primitive spheroidal cell tumour comparable to seminoma of the testis.
 - **Teratoma:** A tumour containing a mixture of well differentiated tissues – dermis, muscle, bone.
- } uncommon tumours of the *pineal region* (not arising from pineal cells)

TUMOURS OF MAL-DEVELOPMENTAL ORIGIN

- **Craniopharyngioma:** Arises from cell rests of buccal epithelium and lies in close relation to the pituitary stalk. Usually a nodular tumour with cystic areas containing greenish fluid and cholesteatomatous material.
- **Epidermoid/dermoid cysts:** Rare cystic tumours arising from cell rests predetermined to form epidermis or dermis.
- **Colloid cyst:** A cystic tumour arising from an embryological remnant in the anterior roof of the 3rd ventricle.

ANTERIOR PITUITARY GLAND

- **Pituitary adenoma:** Benign tumour, usually secreting excessive quantities of prolactin, growth hormone, adrenocorticotrophic hormone, thyrotropin or gonadotropin
- **Adenocarcinoma:** Malignant tumour occasionally arises in the pituitary.

LOCAL EXTENSION FROM ADJACENT TUMOURS

- **Chordoma:** Rare tumour arising from cell rests of the notochord. May occur anywhere from the sphenoid to the coccyx – but commonest in the basi-occipital and the sacrococcygeal region, invading and destroying bone at these sites.
- **Glomus jugulare tumour** (syn. chemodectoma): Vascular tumour arising from 'glomus jugulare' tissue lying either in the bulb of the internal jugular vein or in the mucosa of the middle ear. The tumour invades the petrous bone and may extend into the posterior fossa or neck.
- Other local tumours include **chondroma**, **chondrosarcoma** and **cylindroma**.

Primary malignant lymphoma (syn. microgliomatosis): Forms around periventricular parenchymal blood vessels. May be solitary or multifocal. It generally occurs in immunocompromised patients, e.g. AIDS. Metastatic spread from systemic lymphoma (e.g. non-Hodgkin's lymphoma) is less common, involves the meninges and is rarely intraparenchymal.

Metastatic tumours: May arise from any primary site but most commonly spread from the bronchus or breast. Nervous system metastases occur in 25% of patients with disseminated cancer.

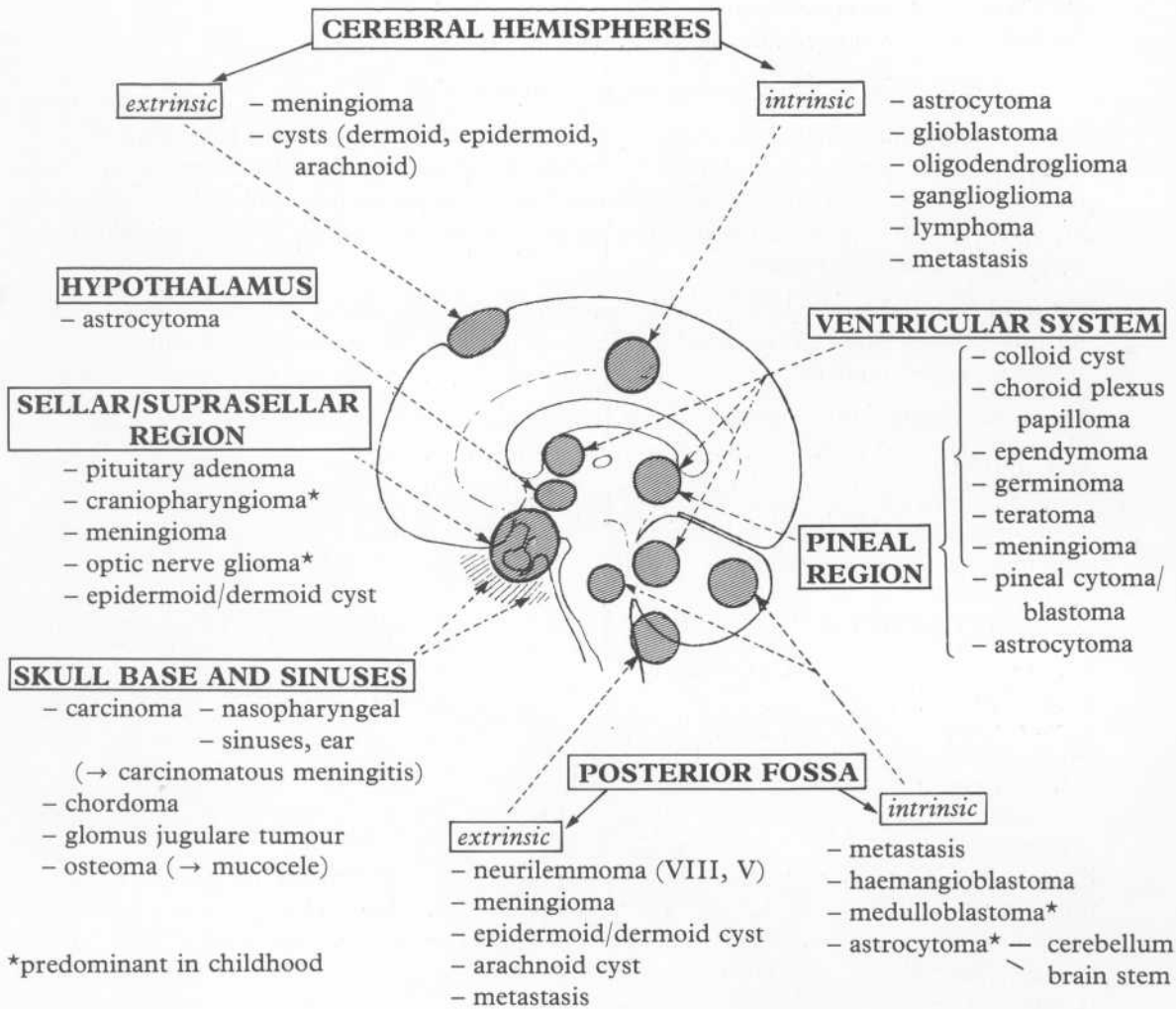
Tumour Markers

Immunohistochemical techniques permit identification of antigens specific for certain cell or tissue characteristics and aid the histological diagnosis of tumours.

- e.g. *Glial fibrillary acidic protein (GFAP)* – for glial tumours
- Cytokeratin*
Epithelial membrane antigen (EMA) } – for metastatic carcinoma

Some markers also indicate the degree of proliferation in various tumours (e.g. *Ki-67*). The identification of growth factors (e.g. *Epidermal growth factor (EGF)*) may help differentiate high-grade from low-grade tumours.

INTRACRANIAL TUMOURS – CLASSIFICATION ACCORDING TO SITE




*predominant in childhood

AETIOLOGY

Genetic factors: Over recent years, the role of genetic factors in tumour development has gained increasing prominence. Transformation of normal cells to malignant growth probably results from a variety of different processes –

(a) Normal cell growth and differentiation controlled by – *proto-oncogenes*



INTRACRANIAL TUMOURS – AETIOLOGY/INCIDENCE

AETIOLOGY (contd)

(b) Inactivation of expression of *tumour suppressor genes*.

(c) Over expression of genes controlling growth factor.

Clearly defined inherited factors play a minor role. Only 5% of patients have a family history of brain tumour and with the exception of **tuberous sclerosis** (related to the formation of subependymal astrocytomas) and **neurofibromatosis** (linked to an increased incidence of optic nerve glioma and meningioma) do not fall into an obvious autosomal recessive or dominant pattern.

Cranial irradiation: long term follow-up of patients undergoing whole head irradiation for tinea capitis shows an increased incidence of both benign and malignant tumours – astrocytoma, meningioma.

Immunosuppression: increased incidence of lymphoreticular tumours.

INCIDENCE

The table below details the incidence of intracranial tumours examined by the Neuropathology Department, Institute of Neurological Sciences, Glasgow (population 2.7 million) over a 5 year period.

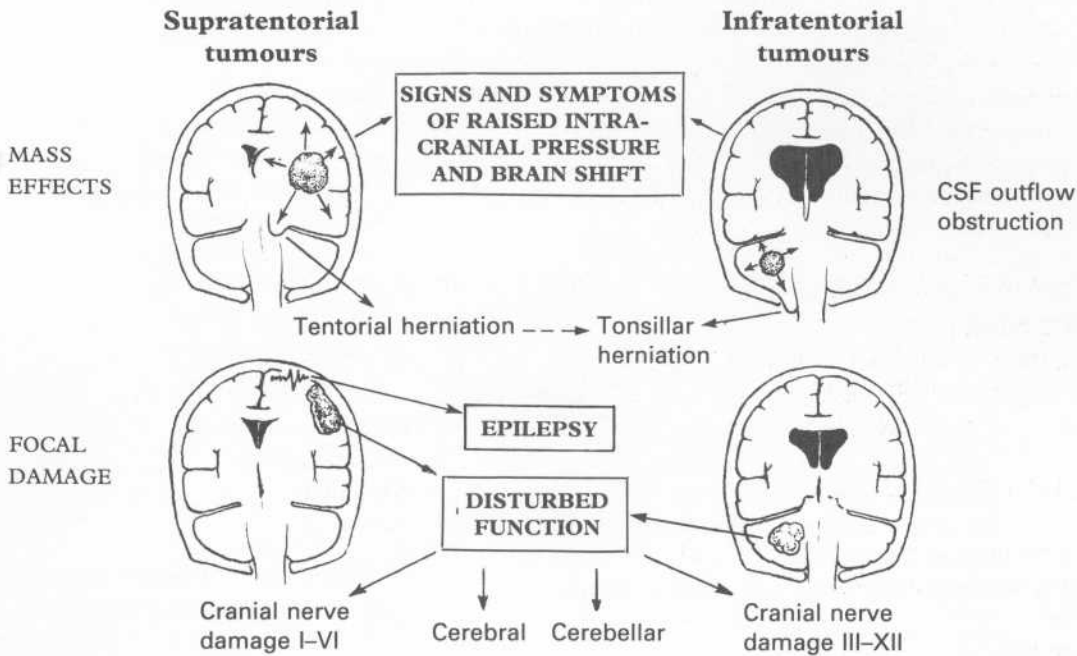
SUPRATENTORIAL	Adults		Children (< 15 years)		
Anaplastic astrocytoma (including glioblastoma)	347	(40%)	5	(7%)	
Meningioma	134	(15%)	–		
Metastasis	105	(12%)	–		
Astrocytoma	73	(8%)	5	(7%)	
Pituitary adenoma	31	(4%)	–		
Craniopharyngioma	13	(1%)	9	(13%)	
Oligodendroglioma	9	(1%)	1	(1%)	
Colloid cyst	4	(<1%)	–		
Lymphoma	2	(<1%)	–		
Others	11	(1%)	6	(9%)	
INFRATENTORIAL					
Neuroma	50	(6%)	–		
Metastasis	39	(4%)	–		
Haemangioblastoma	17	(2%)	–		
Astrocytoma	12	(1%)	19	(27%)	
Meningioma	12	(1%)	–		
Medulloblastoma	6	(<1%)	17	(24%)	
Dermoid/epidermoid	3	(<1%)	1	(1%)	
Ependymoma			4	(6%)	
Others	8	(1%)	3	(4%)	
Total	876		70		

– As a result of AIDS and immunosuppression, the incidence of primary cerebral lymphoma has significantly increased.

(Adapted from Adams, Graham and Doyle, 1981 Brain Biopsy)

INTRACRANIAL TUMOURS – CLINICAL FEATURES

Symptoms tend to develop insidiously, gradually progressing over a few weeks or years, depending on the degree of malignancy (cf. acute onset of a cerebrovascular accident followed by a gradual improvement if the patient survives). Occasionally tumours present acutely due to haemorrhage or the development of hydrocephalus.



CLINICAL EFFECTS

RAISED INTRACRANIAL PRESSURE – headache, papilloedema } (see pages 77-79)
BRAIN SHIFT – vomiting, deterioration of conscious level, pupillary dilatation }

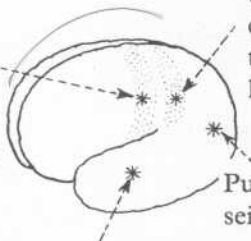
EPILEPSY (see page 88)

- generalised
 - partial (simple or complex)
 - partial progressing to generalised
- (occur in 30% of patients with brain tumours)

Partial seizures help localise the tumour site.

Partial motor seizures arise in the motor cortex – tonic or clonic movements in the contralateral face or limbs.

Partial sensory seizures arise in the sensory cortex and cause numbness and tingling in the contralateral face, limbs.



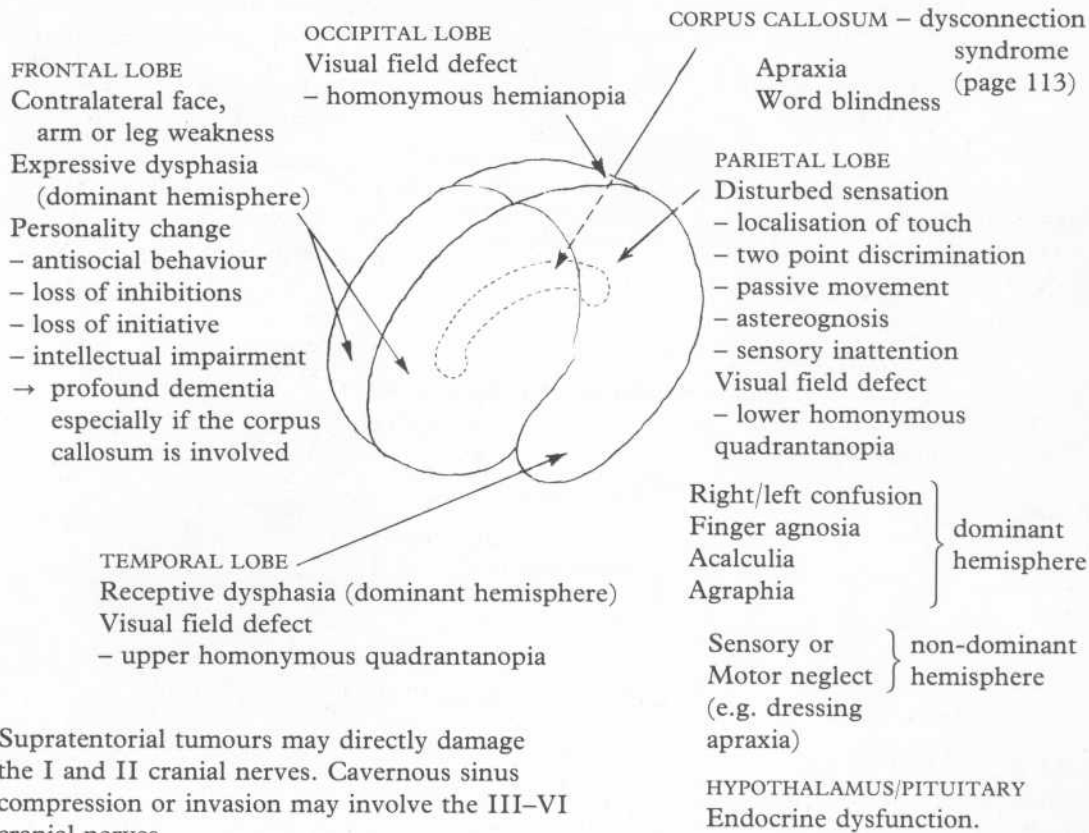
Pure visual (or auditory) seizures are rare.

Complex partial (temporal lobe) seizures arise from the medial temporal lobe – formed visual or auditory hallucinations, awareness of abnormal taste, feelings of fear, déjà vu, unfamiliarity or depersonalisation and automatisms.

INTRACRANIAL TUMOURS – CLINICAL FEATURES

DISTURBED FUNCTION

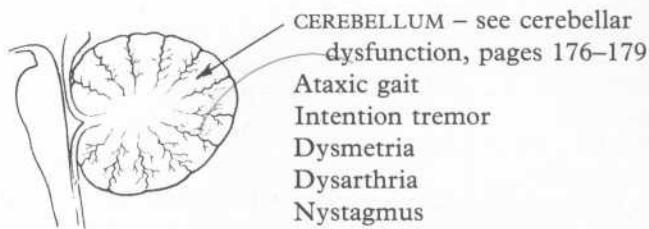
Supratentorial – see higher cortical dysfunction, pages 105–113.



Supratentorial tumours may directly damage the I and II cranial nerves. Cavernous sinus compression or invasion may involve the III–VI cranial nerves.

Infratentorial

MIDBRAIN/BRAIN STEM
 Cranial nerve lesions III–XII
 Long tract signs
 – motor and sensory
 Deterioration of conscious level
 Tremor (red nucleus)
 Impaired eye movements
 Pupillary abnormalities
 Vomiting, hiccough (medulla)



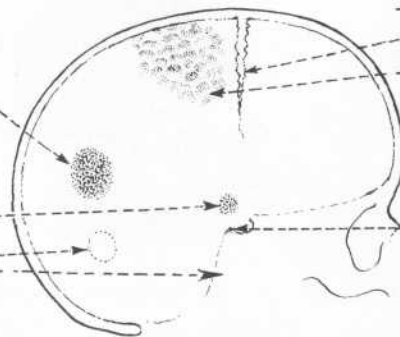
N.B. Intrinsic brain stem tumours in contrast to extrinsic tumours are more likely to produce long tract (motor and sensory) signs early in the course of the disease.

INTRACRANIAL TUMOURS – INVESTIGATION

Chest X-ray } The high incidence of metastatic tumour makes these tests mandatory in
ESR } patients with suspected intracranial tumour.

Skull X-ray Note:
Calcification

- oligodendroglioma
 - meningioma (look for hyperostosis of adjacent bone)
 - craniopharyngioma
- Osteolytic lesion**
- primary or secondary bone tumour
 - dermoid/epidermoid
 - chordoma
 - nasopharyngeal carcinoma
 - myeloma
 - reticulosis

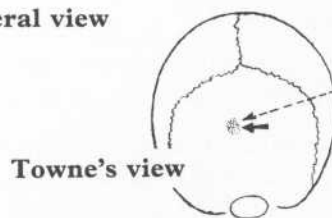


Lateral view

Signs of raised intracranial pressure

- Suture separation (diastasis) in infants
- 'Beaten brass' appearance – of limited value since it may occur normally in children and in some adults.

erosion of the posterior clinoids
 (may also occur from local pressure, e.g. craniopharyngioma).



Towne's view

Pineal shift – if gland is calcified (ensure 'shift' is not due to film rotation).

CT scanning Note:

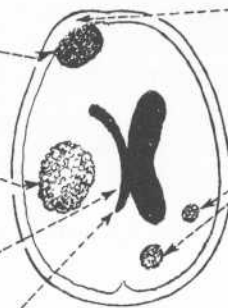
SITE

e.g. frontal, occipital

- *extrinsic*: outwith brain substance, e.g. meningioma
- *intrinsic*: within brain parenchyma, e.g. astrocytoma.

MASS EFFECT

- midline shift.
- ventricular compression.
- hydrocephalus (secondary to 3rd ventricular or posterior fossa lesion).



Effect on adjacent bone i.e. if meningioma → hyperostosis

Single or multiple lesions if multiple → metastasis

Effect of contrast enhancement
 e.g. none – low grade astrocytoma
 irregular – malignant astrocytoma
 homogeneous – meningioma

HIGH DEFINITION SCANS (1.5 mm slice width) – useful in the detection of pituitary, orbital and posterior fossa tumours.

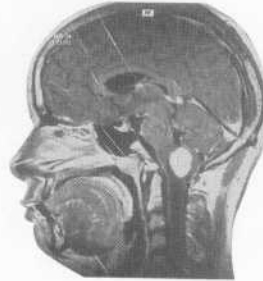CORONAL AND SAGITTAL RECONSTRUCTION
DIRECT CORONAL SCANNING

- useful in demonstrating the vertical extent of a tumour and its relationship with other structures
 - especially when intraventricular or arising from the pituitary fossa or skull base.
- Now replaced by MRI.

INTRACRANIAL TUMOURS – INVESTIGATION

MRI Note: SITE, MASS EFFECT and LESION MULTIPLICITY as for scanning.
Of particular value in demonstrating tumours around the skull base, cranio-cervical junction and the brainstem.

Coronal and sagittal scanning provide additional information, showing the exact anatomical relationship of the tumour to the sulci and gyri, the ventricles, the falx and the tentorium cerebelli.



T1 weighted MRI with gadolinium showing a haemangioblastoma involving the medulla.

Paramagnetic enhancement: intravenous gadolinium increases sensitivity of detection and clarifies the site of origin, i.e. intrinsic or extrinsic, and may delineate the border between tumour and surrounding oedema.

Single or multiple lesions: MRI appears more sensitive than CT scanning in identifying small tumours and improves the detection of multiple lesions, e.g. metastasis.

Angiography/MRA: although angiography may reveal a tumour 'blush' or vessel displacement, it is only occasionally required to supplement other investigations. In some patients, it provides useful preoperative information, e.g. identifies feeding vessels to a vascular tumour or tumour involvement and constriction of major vessels.

CSF examination: lumbar puncture is contraindicated if the clinician suspects intracranial tumour. If CSF is obtained by another source, e.g. ventricular drainage or during shunt insertion, then cytological examination may reveal tumour cells.

Tumour markers: although useful as an aid to histological diagnosis (see page 296), attempts to find a substance in blood or CSF which reflects growth of a specific tumour have been limited – only the link between elevated alpha fetoprotein and human chorionic gonadotrophins with germinomas of the third ventricle helps diagnosis.

DIFFERENTIAL DIAGNOSIS OF INTRACRANIAL MASS LESIONS (other than tumour)

Vascular – haematoma
– giant aneurysm
– arteriovenous malformation
– infarct with oedema
– venous thrombosis.

Infection – abscess
– tuberculoma
– sarcoidosis
– encephalitis.

Trauma – haematoma
– contusion.

Cysts – arachnoid
– parasitic (hydatid).

INTRACRANIAL TUMOURS – MANAGEMENT

STEROID THERAPY

Steroids dramatically reduce oedema surrounding intracranial tumours, but do not affect tumour growth.

A loading dose of 12 mg i.v. dexamethasone followed by 4 mg q.i.d. orally or by injection often reverses progressive clinical deterioration within a few hours. After several days treatment, gradual dose reduction minimises the risk of unwanted side effects.

Sellar/parasellar tumours occasionally present with steroid insufficiency. In these patients, steroid cover is an essential prerequisite of any anaesthetic or operative procedure.

OPERATIVE MANAGEMENT

Most patients with intracranial tumours require one or more of the following approaches:

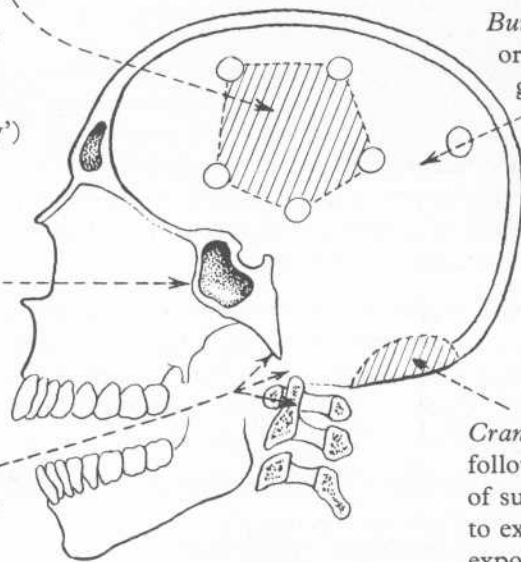
Craniotomy: flap of bone cut and reflected

If necessary, combined with either a stereotactic frame or preferably an image guided system (i.e. 'frameless stereotaxy') to give accurate lesion localisation (see page 372).

Transphenoidal route: through the sphenoid sinus to the pituitary fossa

Transoral route:

removal of the arch of the atlas, odontoid peg and clivus provides access to the anterior aspect of the brain stem and upper cervical cord. Rarely required – for anteriorly situated tumours, e.g. neurofibroma, chordoma.



Burr hole: for stereotactic or hand-held, ultrasound guided biopsy

Craniectomy: burr hole followed by removal of surrounding bone to extend the exposure – routinely used to approach the posterior fossa

The subsequent procedure – *biopsy, partial tumour removal/internal decompression or complete removal* – depends on the nature of the tumour and its site. The infiltrative nature of primary malignant tumours prevents complete removal and often operation is restricted to biopsy or tumour decompression. Prospects of complete removal improve with benign tumours such as meningioma or craniopharyngioma; if any tumour tissue is overlooked, or if fragments remain attached to deep structures, then recurrence will result.

INTRACRANIAL TUMOURS – MANAGEMENT

RADIOTHERAPY

Present-day treatment of intracranial tumours with radiotherapy utilises one of the following:

- megavoltage X-rays
- γ rays from cobalt⁶⁰
- electron beam from a linear accelerator.
- accelerated particles from a cyclotron, e.g. neutrons, nuclei of helium, protons (awaits full evaluation).

In contrast to older methods of 'deep X-ray therapy', these modern techniques produce greater tissue penetration and avoid radiation damage to the skin surface.

The effect of radiotherapy depends on the total dose – usually up to 60 Gy, and the treatment duration. This must be balanced against the risk to normal structures.

Treatment aims to provide the highest possible dose to a specified region whilst minimising irradiation to adjacent normal brain. Various methods have been developed to achieve this –

- *Stereotactic irradiation* where multiple converging beams from a linear accelerator or from multiple cobalt⁶⁰ sources are focused on a selected target (see page 371).
- *Interstitial techniques* where the tumour is treated from within (brachytherapy) by the implantation of multiple radioactive seeds, e.g. iodine¹²⁵.
- *Conformal therapy* where standard radiotherapy is administered, but the beams are shaped by the use of variable collimators or blocks which conform with the shape of the tumour, thereby eliminating normal brain.

Radiotherapy is of particular value in the management of malignant tumours – malignant astrocytoma, metastasis, medulloblastoma and germinoma, but also plays an important part in the management of some benign tumours – pituitary adenoma, craniopharyngioma. With some tumours that seed throughout the CSF pathways, e.g. medulloblastoma, *whole neural axis irradiation* minimises the risk of a distant recurrence.

Complications of radiotherapy: following treatment, deterioration in a patient's condition may occur for a variety of reasons:

- Increased oedema – during treatment – reversible.
- Demyelination – after weeks, months – usually reversible.
- *Radionecrosis* – in usually 1–2 years (range 6 months–10 years) irreversible.

Similar complications may involve the spinal cord after irradiation of spinal tumours.

INTRACRANIAL TUMOURS – MANAGEMENT

CHEMOTHERAPY

Chemotherapeutic agents have been used for many years in the management of malignant brain tumours, but clinical benefits remain uncertain.

Drugs most commonly employed include nitrosoureas (e.g. BCNU, CCNU, methyl-CCNU) procarbazine, vincristine and methotrexate.

Patients with malignant tumours can show a response to chemotherapy. When used as part of primary therapy a statistically significant prolongation of survival may result. The side effects of the treatment however leave the value of the few extra weeks gained in doubt. In malignant astrocytoma, the Nitrosoureas e.g. BCNU, are the most active drugs and are commonly used for the treatment of relapsed patients. Chemotherapy for benign or low grade tumours is of limited value. Medulloblastoma commonly responds to treatment, but its value in improving patients' survival is unclear. Chemotherapy does appear to have a role in primary germ cell tumours and in primary cerebral lymphoma.

Problems of drug administration

Toxicity: The ideal cytotoxic drug selectively kills tumour cells; but tumour cell response relates directly to the dose. High drug dosage causes *bone marrow suppression*. Often marrow depression occurs before an adequate therapeutic dose is reached.

Drug access: 'Toxic' doses are usually required before sufficient amounts penetrate the blood-brain barrier and gain access to the tumour cells.

Intrinsic resistance: Some tumour cells appear to have an inbuilt resistance to certain drugs. The vast array of available cytotoxic drugs and the infinite permutations of combined therapy creates difficulties in drug selection.

New approaches

Cell targeting: *Monoclonal antibodies* have been used in the hope that they would serve as carriers, taking cytotoxic drugs, toxins or radionuclides directly to the tumour site. Initial studies on intrinsic tumours have not lived up to expectations due to problems with access and transfer across the blood-brain barrier.

Improving access: Modifying the blood-brain barrier with mannitol or preliminary binding with *liposomes* may improve the passage of cytotoxic drugs and monoclonal antibodies to tumour tissue. Similarly direct *intracarotid injection* may improve access over conventional routes of administration. A recent study has suggested modest benefit from the intraoperative placement of 'slow release' biodegradable polymers of BCNU in patients with malignant glioma. These methods await full evaluation.

In vitro chemosensitivity testing: This approach utilises cultured tumour cells from biopsy material. In vitro analysis of growth inhibition, or the rate of cell death following application of a specific drug, points to the tumour 'sensitivity' of the drug under test. In practice, this technique appears to be of limited value. Although successfully identifying drugs which have no effect on the tumour, the demonstration of cytotoxic activity in vitro does not always reflect its in vivo performance.

PROGNOSIS OF INTRACRANIAL TUMOURS

Patient prognosis depends on the specific tumour type; this is described for individual tumours on subsequent pages.

TUMOURS OF THE CEREBRAL HEMISPHERES – INTRINSIC

Intrinsic tumours arise within the brain substance.

ASTROCYTOMA (and glioblastoma multiforme)

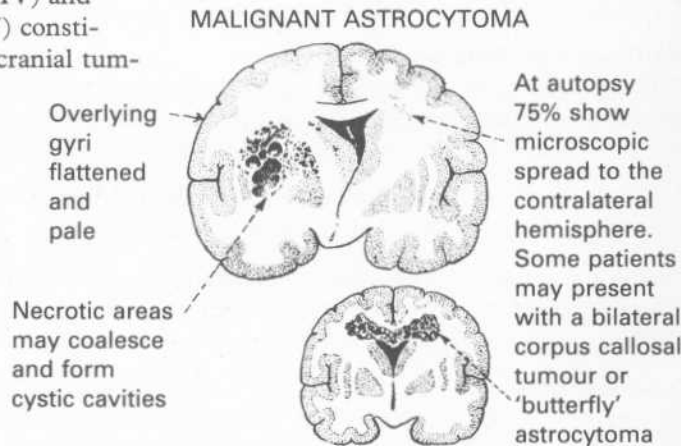
Astrocytomas may occur in any age group, but are commonest between 40 and 60 years.

Male:female = 2:1

Primary sites: Found in equal incidence throughout the frontal, temporal, parietal and thalamic regions, but less often in the occipital lobe. Microscopic classification defines 4 grades (Kernohan I-IV), but this is of limited accuracy. A more practical description for the clinician divides tumours into either 'malignant' or 'low grade'.

'Malignant' astrocytoma/glioblastoma multiforme

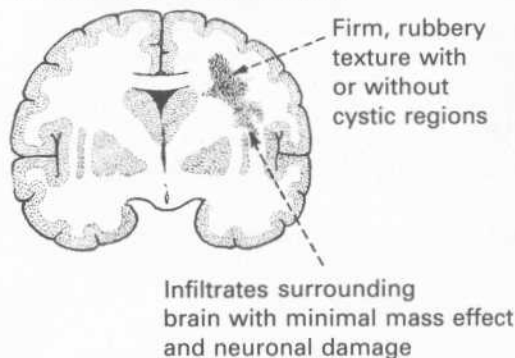
Malignant astrocytoma (grade III/IV) and glioblastoma multiforme (grade IV) constitute over 40% of all primary intracranial tumours. Peak age incidence is 55 years. These tumours widely infiltrate adjacent brain; growth is rapid. At autopsy, microscopic examination usually reveals spread to multiple distant sites.



'Low grade' astrocytoma

Low grade astrocytomas (grade I/II) make up 14% of all primary intracranial tumours and occur on average at an earlier age than their malignant counterparts (about 40 years).

FIBRILLARY ASTROCYTOMA



These tumours are diffuse and slowly growing, and composed of well differentiated astrocytic cells subdivided into fibrillary, protoplasmic or gemistocytic types. Although 'benign' they widely infiltrate surrounding brain and lack a definitive edge or capsule. A further low grade type – the pilocytic (or 'juvenile') astrocytoma occurs in the hypothalamic region as well as in the optic nerve (page 336) and cerebellum (page 319). Since partial resection may result in a cure, some believe pilocytic astrocytomas are 'hamartomas' – mesodermal cell rests, rather than true tumours.

TUMOURS OF THE CEREBRAL HEMISPHERES – INTRINSIC

ASTROCYTOMA (contd)

CLINICAL FEATURES

Astrocytomas may present with:

- epilepsy – more common with low grade tumours
- signs and symptoms of focal brain damage – dysphasia, hemiparesis, personality change
- signs and symptoms of raised intracranial pressure – headache, vomiting, depression of conscious level.

Symptoms usually develop gradually, progressing over several weeks, months or years, the rate depending on the degree of malignancy. Sudden deterioration suggests haemorrhage into a necrotic area. In a patient with long standing epilepsy, the rapid development of further symptoms may result from malignant change within a previously 'low grade' lesion.

INVESTIGATIONS

Skull X-ray: of limited value; shift of a calcified pineal or erosion of the dorsum sellae indicates the presence of an intracranial mass.

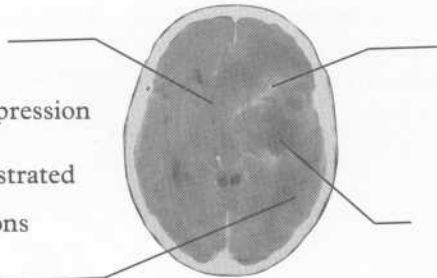
CT scan: appearances vary considerably; in general, malignant and low grade lesions show different characteristics:

Malignant astrocytoma/glioblastoma multiforme

The lesion, site and associated mass effect

- ventricular compression
 - midline shift
- are clearly demonstrated

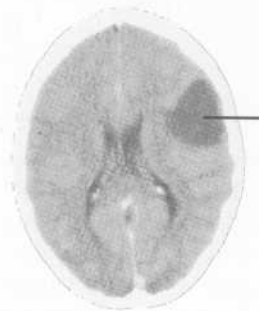
Surrounding regions of low density indicate either oedema or infiltrative tumour



Areas of mixed density, *irregularly enhance with contrast*. No plane exists between tumour and brain indicating infiltration

Central, low density regions represent necrotic areas or cystic cavities; neither enhances with contrast

Low grade astrocytoma



A low density region, *usually unenhancing with contrast* suggests a low grade infiltrative lesion; detection is often difficult in early stages. Calcification occasionally occurs.

MRI may detect low grade infiltrative tumours before these become evident on CT scan.

TUMOURS OF THE CEREBRAL HEMISPHERES – INTRINSIC

ASTROCYTOMA (*contd*)

MANAGEMENT

The management of glial tumours varies depending on a number of factors –

- the lesion site
- the degree of malignancy
- the presence or absence of raised ICP
- the degree of disability and the effect of steroid therapy
- the suspected nature of the tumour on imaging
- the patient's age
- the patient's wishes

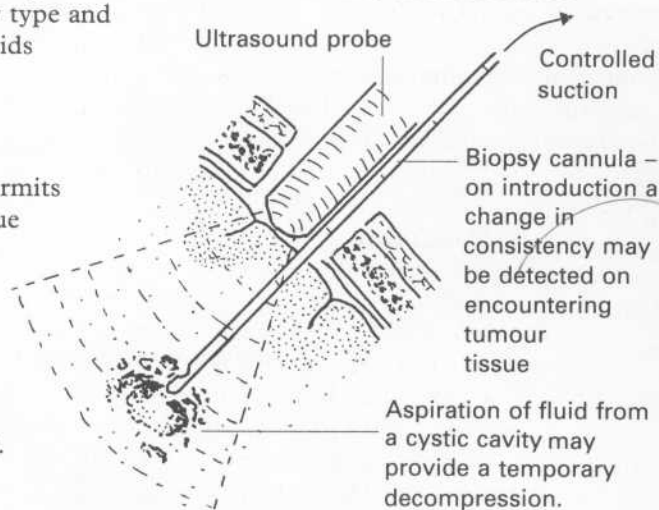
TREATMENT OPTIONS

Steroid therapy: For patients presenting with symptoms of raised intracranial pressure and/or focal neurological signs, a loading dose of dexamethasone 12 mgs i.v. followed by 4 mgs q.i.d., by injection or orally, reduces surrounding oedema and leads to rapid improvement. Steroid treatment is an essential prerequisite to operation. Its introduction has significantly reduced the perioperative mortality. After several days, a gradual reduction in dosage avoids side effects.

Biopsy: In most patients, imaging is insufficient to diagnose a malignant tumour confidently and biopsy provides a tissue diagnosis. Failure to confirm the nature of the lesion, risks omitting treatment in benign conditions such as abscess, tuberculoma or sarcoidosis. Identification of tumour type and grade gives a prognostic guide and aids further management.

METHODS:

Ultrasound guided – a brain cannula inserted into the abnormal region permits aspiration of a small quantity of tissue for immediate (smear and frozen section) and later (paraffin section) examination. Provided patients receive preoperative steroid cover the risks are small, but occasionally biopsy produces or increases a focal deficit or causes a fatal haemorrhage.



Framed or frameless stereotactic methods (see page 372) – permit accurate placement of a fine cannula at a predetermined site selected on CT scan or MRI. Stereotactic guidance is essential for small and/or deep inaccessible lesions (e.g. hypothalamus). Prior selection of the needle path avoids vessels and important structures, thus minimising the risks. Since the degree of malignancy varies from region to region within a single lesion, several samples are taken from different sites to increase accuracy. If findings vary, then the region of greatest malignancy dictates the tumour grade. These techniques are now frequently used, even for more accessible lesions, due to the low mortality and morbidity.

TUMOURS OF THE CEREBRAL HEMISPHERES – INTRINSIC

ASTROCYTOMA

TREATMENT OPTIONS (contd)

Open operation: – open biopsy
 – internal tumour decompression } perhaps combined with ultrasound or with framed or frameless stereotaxy to aid tumour localisation.

Through a craniotomy, the surgeon performs an 'open' biopsy under direct vision, or resects as much tumour tissue as is safely feasible without damaging eloquent regions. The difficulty lies in the absence of a plane of cleavage between tumour tissue and brain. Stereotactic methods can identify the boundaries seen on CT scan or MRI but this is limited by the resolution of the imaging. Large resections are most safely performed in the frontal, occipital or non-dominant temporal lobes. Reduction of the tumour mass improves the effect of adjuvant therapy.

Radiotherapy: Most effective in rapidly growing tumours – grade III and IV. Radiotherapy extends survival, but does not cure. Studies show a dose-effect relationship – the greater the dose to the tumour area, the longer the survival. Methods of 'conformal' therapy and 'interstitial radiotherapy' (see page 304) aim to achieve this.

Chemotherapy: Various combinations of chemotherapeutic agents (e.g. BCNU, 5-fluorouracil) have been used in the management of malignant astrocytoma and glioblastoma multiforme. A proportion of tumours undoubtedly respond to chemotherapy and survival times are increased by approximately 6 weeks, side effects reduce the quality of life. Treatment is usually reserved for recurrent tumours. A recent study of slow release carmustine from biodegradable polymers placed in the tumour bed has suggested a significant benefit, but other attempts at improving drug access have not gained favour.

Treatment selection and prognosis Since treatment cannot cure, the clinician must consider quality of survival as well as the duration.

Malignant astrocytoma/glioblastoma multiforme: Despite modern techniques, these tumours still carry a grave prognosis, irrespective of the selected treatment.

Although there are many protagonists for aggressive operative treatment, benefits remain unconvincing. Extensive tumour resection extends average survival by only 1 or 2 months; at 1 year, the percentage of patients surviving varies little, irrespective of whether burr hole biopsy or tumour resection is performed. Complete removal is impossible; even the formidable 'hemispherectomy' fails due to interhemispheric spread. Radiotherapy appears to have the greatest effect, extending the mean survival period by 3–4 months.

Management policies vary widely, but in general, *tumour resection with radiotherapy* is considered in:

- younger patients
- patients with symptoms of raised ICP from the mass effect
- patients with 'accessible' lesions
- patients without severe disability

Tumour recurrence in these patients may warrant *chemotherapy* or even reoperation with or without interstitial radiotherapy.

A *diagnostic biopsy* may be appropriate in – the elderly, and in patients with marked disability (e.g. severe dysphasia).

Median survival (months)	
Burr hole biopsy	3–4
Tumour resection	6
Burr hole biopsy + radiotherapy	6–8
Tumour resection + radiotherapy	9–10

TUMOURS OF THE CEREBRAL HEMISPHERES – INTRINSIC

ASTROCYTOMA (*contd*)

Low grade astrocytoma: A poorly defined region of low density on CT scan without contrast enhancement suggests a low grade tumour (grade I or II) with a better prognosis. In such patients who often present with epilepsy without other symptoms, there is no evidence that active intervention with operation and/or radiotherapy changes outcome. In this instance, both clinician and patient may prefer to follow a conservative approach. If subsequent CT scanning shows definitive tumour progression (expansion or contrast enhancement, or if clinical symptoms supervene, then surgical treatment and radiotherapy can follow as appropriate.

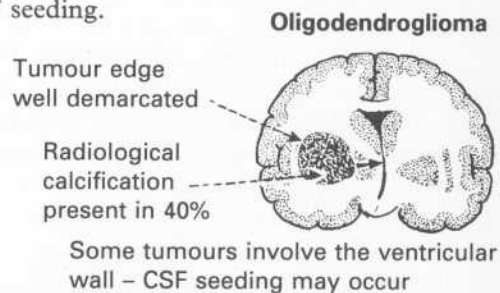
About 50–60% survive 5 years irrespective of treatment; about 40% survive 10 years.

OLIGODENDROGLIOMA

Oligodendrogliomas are far less common than astrocytomas. They occur in a slightly younger age group – 30–50 years, and usually involve the frontal lobes. Occasionally involvement of the ventricular wall results in CSF seeding.

Calcification occurs in 40%.

In contrast to astrocytomas, the tumour margin often appears well defined. Oligodendrogliomas are usually low grade tumours, but the rate of growth and the degree of malignant change can vary and anaplastic forms can exist. Malignant change may result in a histological pattern resembling glioblastoma multiforme.



Management: as for astrocytomas. Low grade lesions may benefit from ‘complete’ or ‘partial’ excision. Radiotherapy has most effect in malignant tumours.

Prognosis: depends on the tumour grade. Long term survival (over 20 years) is occasionally recorded, but in tumours showing malignant change, expected survival compares closely with that of malignant astrocytoma.

Mixed astrocytoma/oligodendroglioma: Histology may reveal a mixed form with areas of astrocytic change scattered between the oligodendroglioma. In these, grading and outcome depends on the astrocytic component.

HYPOTHALAMIC ASTROCYTOMA

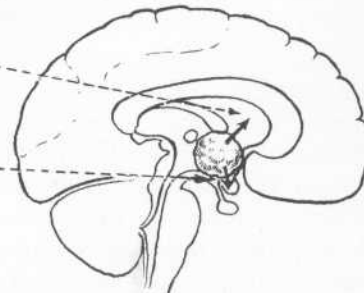Hypothalamic tumours usually occur in children; they are usually astrocytomas of the pilocytic (juvenile) type. The clinical effect of hypothalamic damage takes different forms. Initially the child *fails to thrive* and becomes *emaciated*. Signs of *panhypopituitarism* may develop. Eventually an anabolic phase results in *obesity* accompanied by *diabetes insipidus* and *delayed puberty*. Disturbance of affect and of sleep – wake rhythms may occur.

Upward tumour extension may obstruct the foramen of Munro and cause *hydrocephalus*.

Involvement of the tuberal region may result in the rare presentation of *precocious puberty* with secondary sexual characteristics developing in children perhaps only a few years old.

Downward extension invades the optic chiasma and impairs vision.

Management: The site of the lesion prevents operative removal; a stereotactic biopsy may aid tumour identification. If hydrocephalus is present, a bilateral ventriculoperitoneal shunt relieves pressure symptoms. Radiotherapy is of doubtful value.



TUMOURS OF THE CEREBRAL HEMISPHERES – INTRINSIC

METASTATIC TUMOURS

Any malignant tumour may metastasise to the brain. Malignant melanomas show the highest frequency (66% of patients); this contrasts with tumours of the cervix and uterus where < 3% develop intracranial metastasis. The most commonly encountered metastatic intracranial tumours arise from the bronchus and the breast; of patients with carcinomas at these sites, 25% develop intracranial metastasis.

In up to 50% of patients, metastases are multiple.

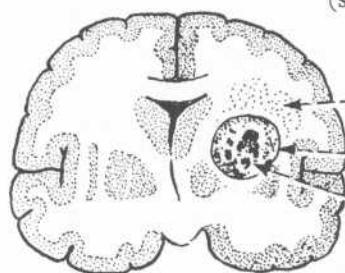
Spread usually haematogenous. Occasionally a metastasis to the skull vault may result in a nodule or plaque forming over the dural surface from direct spread.

Common primary sites

- bronchus
- breast
- kidney
- thyroid
- stomach
- prostate
- testis
- melanoma

Intracranial sites $\left\{ \begin{array}{l} \frac{3}{4} \text{ cerebral hemispheres} \\ \frac{1}{4} \text{ cerebellum} \end{array} \right\}$
(see page 317)

Involvement of the ventricular wall or encroachment into the basal cisterns may result in tumour cells seeding through the CSF pathways – malignant meningitis.



Surrounding oedema is often marked.

Tumour margin – well defined.

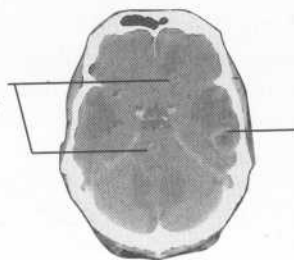
Necrotic areas may break down to form cystic cavities containing a pus-like fluid.

Clinical features

Patients with supratentorial metastatic tumours may present with epilepsy, or with signs and symptoms occurring from focal damage or raised intracranial pressure. Cerebellar metastases are discussed on page 317. Malignant meningitis causes single or multiple cranial nerve palsies and may obstruct CSF drainage (see page 497).

Investigations

A **CT scan** shows single or multiple well demarcated lesions of variable size. Often an extensive low density area, representing oedema, surrounds the lesion.



Metastatic lesions usually enhance with contrast. A ring-like appearance may resemble an abscess – but the wall is irregular and thickened.

MRI scanning, with and without paramagnetic enhancement, is even more sensitive than CT in detecting small metastatic lesions.

The search for a primary lesion if not already established must include a thorough clinical examination and a chest X-ray. Other investigations including barium studies, intravenous pyelogram (IVP), abdominal CT scans, ultrasound and sputum and urine cytology have questionable value, unless clinically indicated.

TUMOURS OF THE CEREBRAL HEMISPHERES – INTRINSIC

METASTATIC TUMOURS (contd)

Management and prognosis:

Corticosteroids (dexamethasone) have a dramatic, rapid effect, producing clinical improvement in most patients.

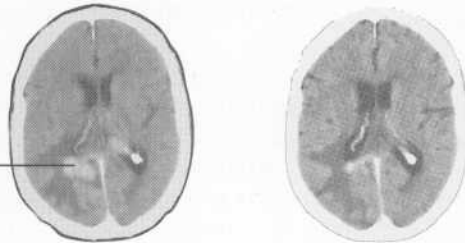
– *Solitary lesions*: If the tumour lies in an accessible site, complete excision followed by radiotherapy provides good results – survival usually depends on the extent of extracranial disease and its ability to respond to treatment rather than on intracranial recurrences. Stereotactic radiosurgery provides a valuable alternative, particularly for lesions less than 3 cms in diameter. In patients with no other evidence of systemic cancer, the median survival period approaches 2 years. In patients with other evidence of systemic disease, results are less good with a median survival of 8 months.

– *Multiple lesions*: In these patients, operative removal is seldom practical or possible. Provided no doubt exists about the diagnosis (i.e. multiple abscesses or tuberculomata may resemble metastatic deposits) then whole brain irradiation is administered.

PRIMARY CNS LYMPHOMA (PCNSL) (syn. MICROGLOMATOSIS, NON HODGKIN'S LYMPHOMA) Single or multiple β - cell lymphoma usually lie deep within the basal ganglia or in the periventricular region. Some are discrete lesions, others extensively invade surrounding brain. Histology shows sleeves of primitive reticulum cells extending outwards from the blood vessels. The incidence is significantly increased in AIDS and in immunocompromised patients.

CSF examination is important; 30% of patients with PCNSL show positive cytology. A positive Epstein-Barr test in CSF is diagnostic of AIDS lymphoma.

CT scan: shows an enhancing homogenous hyperdense region, often in a periventricular location



Multiplicity also suggests lymphoma.

Same patient after 7 days steroid treatment

Management: In AIDS patients, CT and MRI finding of PCNSL appear similar to toxoplasmosis; antiprotozoal therapy should be tried first. Failure to respond indicates the need for *biopsy*. *Steroids* can cause dramatic shrinkage, and the CT scan should be repeated if any delay occurs prior to biopsy. *Radiotherapy* also has dramatic effects, but with this treatment alone, the median survival period is only 10–12 months. Recent studies show that *chemotherapy* (in patients with a normal immune system) can increase median survival to up to 44 months. Some now advocate delaying radiotherapy treatment until a recurrence occurs. AIDS patients, who can only receive radiotherapy, have a median survival of 3 months.

GANGLIOGLIOMA

This is a rare tumour occurring in the younger age group (< 30 years), composed of abnormal neuronal growth mixed with a glial component. The proportion of each component varies from patient to patient. Growth is slow and malignant change uncommon; when this occurs it probably develops in the glial component.

Management follows that of low grade astrocytomas.

NEUROBLASTOMA

Rarely occurs intracranially in children < 10 years. Highly cellular, malignant lesion composed of small round cells, some showing neuronal differentiation.

TUMOURS OF THE CEREBRAL HEMISPHERES – EXTRINSIC

Extrinsic tumours arise outwith the brain substance.

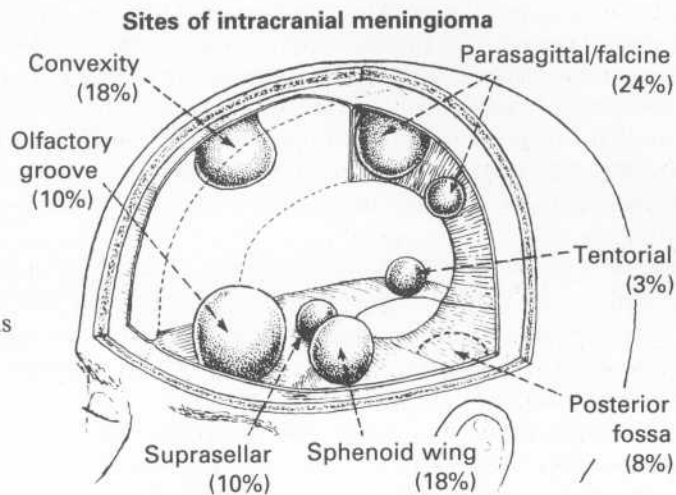
MENINGIOMA

Meningiomas constitute about one-fifth of all primary intracranial tumours. They are slow growing and arise from the arachnoid granulations. These lie in greatest concentration around the venous sinuses, but they also occur in relation to surface tributary veins. Meningiomas may therefore develop at any meningeal site. Occasionally they are multiple.

Meningiomas present primarily in the 40–60 age group and have a slight female preponderance. They are principally benign tumours, although a malignant form exists.

Pathology

Various histological types are described – syncytial, transitional, fibroblastic and angioblastic; different types may coexist within the same tumour. These distinctions serve little clinical value, although it is important to identify the haemangiopericytic variant of the angioblastic group as well as the malignant type, as these indicate the likelihood of rapid growth and a high rate of recurrence following removal.



The remainder arise from the middle fossa, orbital roof and lateral ventricle

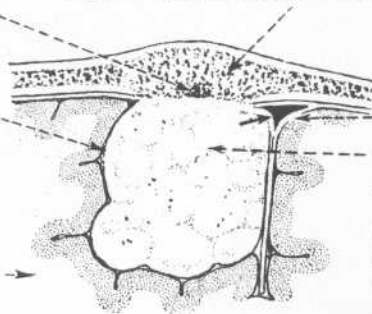
Macroscopic appearance

The dural origin usually incorporates the main arterial supply.

The tumour surface, although often lobulated, is well demarcated from the surrounding brain and attached only by small bridging vessels.

Marked *oedema* often develops in the surrounding brain.

A reactive *hyperostosis* develops in adjacent bone, forming a swelling on the inner table. Hyperostosis affecting the outer table may produce a palpable lump. Tumour tissue may infiltrate adjacent bone.



Parasagittal tumours may invade and obstruct the sagittal sinus.

Tumour texture and vascularity varies considerably from patient to patient – some are firm and fibrous, others soft. *Calcified deposits* (psammoma bodies) are often found.

En-plaque meningioma: In some patients, rather than developing a spherical form, the meningioma spreads 'en-plaque' over the dural surface. This type often arises from the outer aspect of the sphenoid wing.

TUMOURS OF THE CEREBRAL HEMISPHERES – EXTRINSIC

MENINGIOMA Clinical features:

Approximately a quarter of patients with meningioma present with epilepsy – often with a focal component. In the remainder, the onset is insidious with pressure effects (headache, vomiting, papilloedema) often developing before focal neurological signs become evident.

Notable characteristic features occur, dependent on the tumour site – PARASAGITTAL/PARAFALCINE tumours lying near the vertex affect the ‘foot’ and ‘leg’ area of the motor or sensory strip. *Partial seizures* or a ‘pyramidal’ weakness may develop in the leg (i.e. primarily affecting foot dorsiflexion, then knee and hip flexion). Extension of the lesion through the falx can produce *bilateral leg weakness*. Posteriorly situated parasagittal tumours may present with a *homonymous hemianopia*. Tumours arising anteriorly may grow to extensive proportions before causing focal signs; eventually minor *impairment of memory, intellect* and *personality* may progress to a *profound dementia*.

INNER SPHENOIDAL WING tumours may compress the optic nerve and produce *visual impairment*. Examination may reveal a central *scotoma* or other *field defect* with *optic atrophy*.

N.B. The FOSTER KENNEDY syndrome denotes a tumour causing optic atrophy in one fundus from direct pressure and papilloedema in the other due to increased intracranial pressure.

Involvement of the cavernous sinus or the superior orbital fissure may produce *ptosis* and *impaired eye movements* (III, IV and VI nerve palsies) or *facial pain and anaesthesia* (V₁ nerve damage) – see diagram on page 149. *Proptosis* occasionally results from venous obstruction from tumour extension into the orbit.

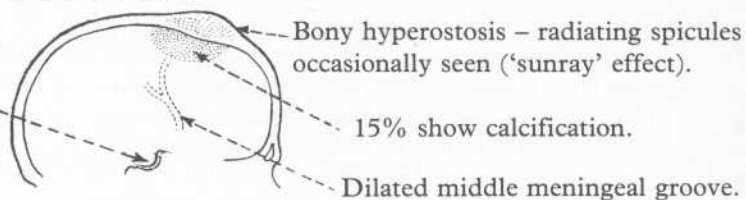
OLFACTORY GROOVE tumours destroy the olfactory bulb or tract causing unilateral followed by bilateral *anosmia*. Often unilateral loss passes unnoticed by the patient; with tumour expansion, dementia may gradually ensue.

SUPRASELLAR tumours – see pages 326–336.

Investigations:

SKULL X-RAY – note:

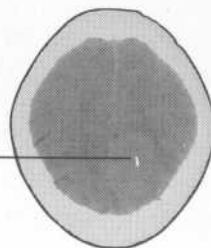
Associated signs of long-standing increased ICP, i.e. posterior clinoid erosion.



CT SCAN

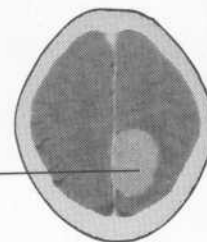
Before i.v. contrast

Meningioma – well circumscribed lesions of a density usually greater than, or equal to brain with a surrounding area of low attenuation (oedema). Calcification may be evident.



After i.v. contrast

A dense, usually homogeneous enhancement occurs after contrast injection. N.B. CT is more sensitive than MRI in meningioma detection.

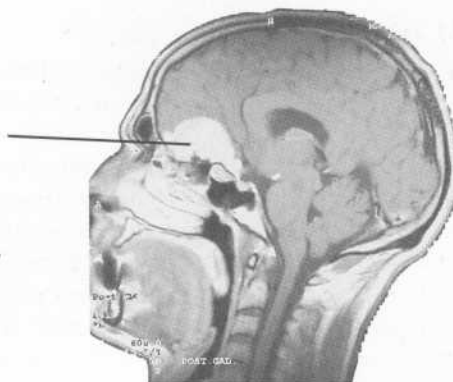


TUMOURS OF THE CEREBRAL HEMISPHERES – EXTRINSIC

MENINGIOMA Investigations (contd)

MRI: On T1 weighted images most meningiomas are isointense with brain, but after gadolinium injection, they diffusely and strikingly enhance. T2 weighted images give useful preoperative information by identifying major vessels and showing their relationship with the tumour.

ANGIOGRAPHY: Characteristically shows a highly vascular lesion with a typical tumour 'blush', but with the availability of MRI, its main value is in selective catheterisation and embolisation of external carotid feeding vessels to reduce tumour vascularity and diminish operative risks from excessive haemorrhage.

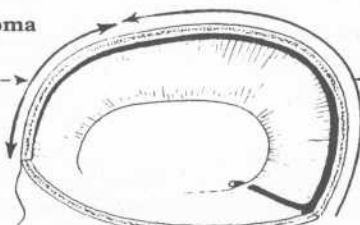


Management

Management aims at complete removal of both the tumour and its origin without damaging adjacent brain; but this depends on the tumour site and its nature. Even with 'convexity' tumours, where complete excision of the dural origin is possible, overlooking a small fragment of tumour may result in recurrence. This is more likely with haemangiopericytic or malignant meningiomas where the plane of cleavage is often obscured.

Parasagittal meningioma

Involvement of the anterior one-third of the sagittal sinus permits total resection of the tumour and origin.



Resection of the posterior two-thirds of the sagittal sinus carries an unacceptably high risk of bilateral venous infarction; in this region every effort is made to spare the sinus and its draining veins.

Tumours arising from the skull base seldom permit excision of the origin. Occasionally the patient's age or the tumour site prevents operation or allows only a limited removal; in these patients, a conservative approach may be more appropriate, only intervening if tumour progression causes disabling symptoms. Alternatively stereotactic irradiation could be considered. Standard radiotherapy is unlikely to help unless histology reveals the haemangiopericytic variant or evidence of malignant change.

Operative results: with modern techniques, operative mortality has fallen to less than 5%, but this varies depending on the size and position of the tumour.

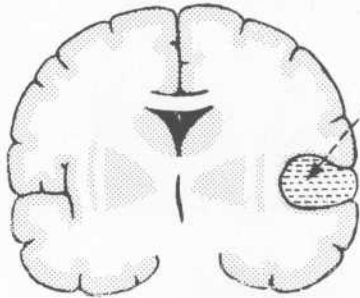
Although *in vitro* studies have demonstrated numerous hormonal receptors (e.g. progesterone and oestrogen) in meningioma tissue, clinical studies of hormonal therapy have as yet failed to show any benefit.

Tumour recurrence: depends predominantly on the completeness of removal. Tumour type seems less important although a higher rate of recurrence has been reported in the haemangiopericytic variant of the angioblastic group as well as in tumours showing malignant features.

Meningiomas recur in up to one-third of patients followed up for more than ten years.

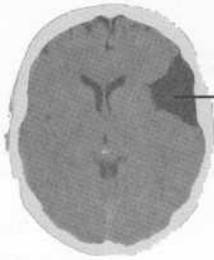TUMOURS OF THE CEREBRAL HEMISPHERES – EXTRINSIC

ARACHNOID CYSTS



These cystic collections of CSF-like fluid lie in the Sylvian fissure, the chiasmatic cistern, the cisterna magna or over the hemisphere convexity. Some are related to a previous infective meningitis with subsequent adhesions but most are probably congenital in origin. Those occurring in the Sylvian fissure may be associated with temporal lobe agenesis.

Occasionally arachnoid cysts present with mass effects, due to a one-way valve effect and progressive enlargement, but more often they are found by chance on CT scan.



CT scan: shows a low density (CSF density) well demarcated lesion, occasionally producing expansion of the over-lying bone.

Treatment: only required if the mass effect becomes symptomatic – *marsupialisation* or *cystoperitoneal shunt*.

EPIDERMOID/DERMOID CYSTS

These cysts, more commonly found in the posterior fossa (page 325), occasionally develop in the Sylvian or interhemispheric fissure. They are either of congenital or acquired origin due to implantation and sequestration of ectoderm. They may present with epilepsy, features of raised intracranial pressure or with focal neurological signs. Rupture into the subarachnoid space causes a chemical meningitis.

On CT scan, the extreme low attenuation of the cyst contents is characteristic. Symptoms may necessitate operative evacuation of the cyst contents. Removal of the cyst wall is difficult and reaccumulation may occur.

Lipomas

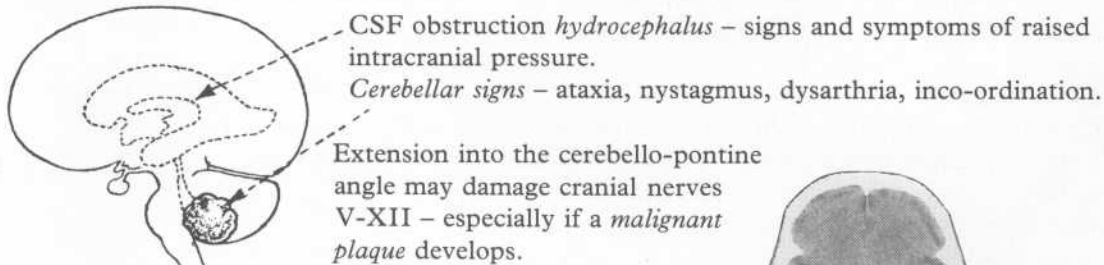
Lipomas are usually found incidentally on imaging or at autopsy and are often associated with other developmental anomalies such as agenesis of the corpus callosum. They are located in midline structures e.g. corpus callosum, dorsal midbrain and cerebellar vermis. They require no treatment.

TUMOURS OF THE POSTERIOR FOSSA – INTRINSIC

CEREBELLAR METASTASIS

In adults, metastasis is the commonest tumour of the cerebellar hemisphere. Primary tumour sites match those of supratentorial lesions (page 311).

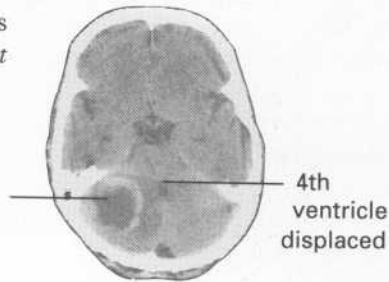
Clinical features: may present acutely or progress over several months.



Investigations

CT scan shows a well-defined solid or cystic lesion lying within the cerebellar hemisphere and enhancing irregularly with contrast.

Obstructive hydrocephalus is often evident on higher scan cuts. As with cerebral metastases MRI is more sensitive.

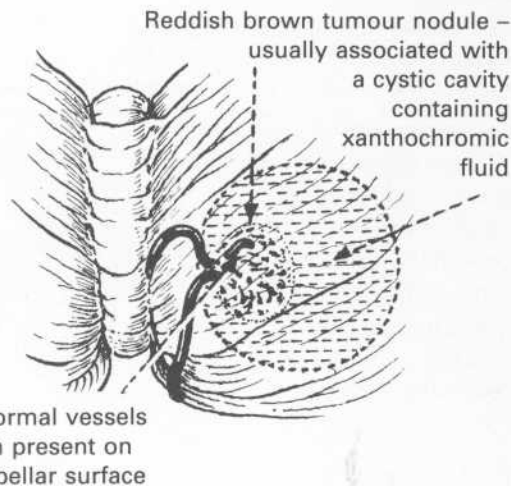


Management

Operative removal of a single metastasis through a suboccipital craniectomy is worthwhile, provided the patient has a reasonable prognosis from the primary tumour. Risks are small – extensive cerebellar hemisphere resection (on one side) seldom produces any significant permanent deficit. A course of *radiotherapy* can follow operation if resection is incomplete. Persistence of obstructive hydrocephalus requires a ventriculoperitoneal shunt.

HAEMANGIOBLASTOMA

This benign tumour of vascular origin occurs primarily in the middle-aged; it is slightly more prevalent in males and is the commonest primary cerebellar tumour of adults. In some patients, haemangioblastomas occur at other sites, e.g. the spinal cord and retina and may be associated with other pathologies, e.g. polycythaemia and cysts in the pancreas and kidneys – *Von Hippel-Lindau disease* (page 542).



TUMOURS OF THE POSTERIOR FOSSA – INTRINSIC

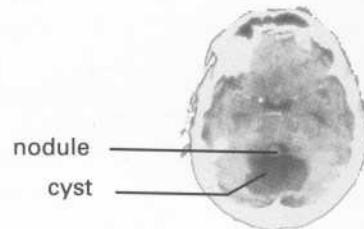
HAEMANGIOBLASTOMA (*contd*)

Clinical features

Cerebellar signs and symptoms or the effects of CSF obstruction usually develop insidiously. Occasionally subarachnoid haemorrhage occurs. In female patients, symptoms often appear during pregnancy. Polycythaemia due to increased erythropoietin production is common.

Investigations

CT scan shows a well defined low density cystic region in the cerebellum with a strongly enhancing nodule in the wall. Occasionally, multiple lesions are evident. MRI gives more anatomical detail (see pages 39-41).

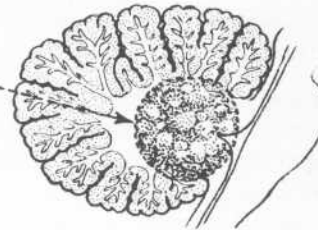


Management

In most patients *operative removal* of the tumour nodule is straightforward, but recurrences (or further tumours at other sites, e.g. spine) develop in 20%.

MEDULLOBLASTOMA

Medulloblastomas occur predominantly in childhood, with a peak age incidence of about 5 years. They arise in the cerebellar vermis and usually extend into the 4th ventricle. All are highly malignant and spread readily throughout the CSF pathways, often seeding to the lateral ventricles or the spinal theca. The origin is uncertain but appears to arise from primitive embryonic cells.



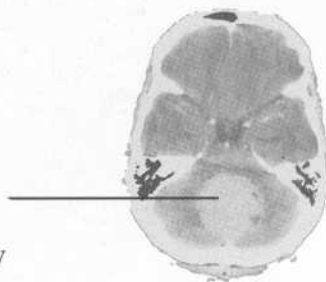
Clinical features

Destruction of the cerebellar vermis causes truncal and gait ataxia often developing over a few weeks.

Alternatively, the patient presents with signs and symptoms of raised intracranial pressure due to blockage of CSF drainage. In the very young, failure to recognise these features has resulted in permanent visual loss from severe papilloedema.

Investigations

CT scan shows an isodense midline lesion in the cerebellar vermis, compressing and displacing the 4th ventricle and enhancing strongly with contrast.



Higher cuts shows dilated ventricles, sometimes containing CSF tumour seedlings.

TUMOURS OF THE POSTERIOR FOSSA – INTRINSIC

MEDULLOBLASTOMA (*contd*)

Management

Staging is essential because of the high incidence of leptomeningeal spread and bone marrow involvement. Assess this with spinal MRI with gadolinium, CSF analysis and bone marrow examination.

Operation: The aim is to remove as much tumour as possible, yet producing minimal damage to surrounding tissue, in particular crucial structures in the floor of the 4th ventricle. Some patients require a CSF shunt, although this provides a further potential route for tumour seeding.

Radiotherapy: Medulloblastomas are radiosensitive. Whole neural axis irradiation attempts to cover any CSF seeding.

Chemotherapy: Although medulloblastomas respond to chemotherapy and are routinely treated, the extent to which they alter the quality or duration of survival is far less certain.

Prognosis

Studies in the last decade show a 5-year survival of approximately 40–60%. With present treatment methods, it is hoped this figure will approach 70%.

CEREBELLAR ASTROCYTOMA

In contrast to astrocytomas of the cerebral hemispheres, cerebellar astrocytomas are usually low grade tumours of the fibrillary or pilocytic types. They are particularly common in children and carry an excellent prognosis. Occasionally a more diffuse or anaplastic type occurs with a less favourable outcome. They usually lie in the cerebellar hemisphere or vermis but occasionally extend through a peduncle into the brain stem. Many have cystic components.

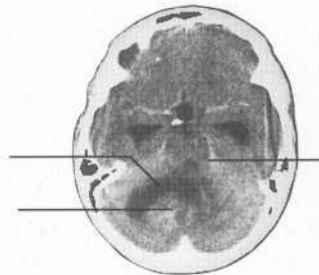
Clinical features

Cerebellar signs and symptoms tend to develop gradually over many months; if CSF obstruction occurs, the patient may present acutely with headache, papilloedema and deteriorating conscious level.

Investigations

CT scan – density changes and the degree of contrast enhancement are variable.

Often a low density cystic area abuts or encircles the tumour mass



Displaced 4th ventricle

Management

Ideally, complete *operative removal* is attempted provided the brain stem is not involved. With 'juvenile' pilocytic tumours, long-term survival is likely. Even after partial removal 'cures' have been reported; although histologically similar to some supratentorial lesions, growth characteristics clearly differ. Persistent hydrocephalus may require a ventriculoperitoneal shunt.

TUMOURS OF THE POSTERIOR FOSSA – INTRINSIC

BRAIN STEM ASTROCYTOMA

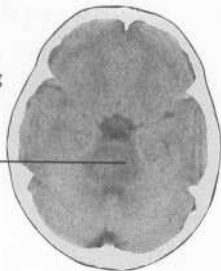
Rarely, astrocytomas arise within the brain stem. Most are of the fibrillary or pilocytic types and diffusely expand the pontine region although they can be malignant. They develop mainly in children or young adults.

Clinical features

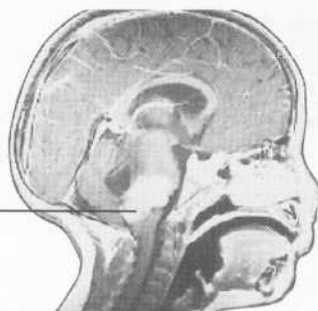
Cranial nerve palsies and long tract signs gradually develop as the tumour progresses. Eventually conscious level is impaired. More malignant gliomas are associated with a rapidly progressing course, often with signs of raised intracranial pressure.

Investigations

CT scan may show low density within the brainstem, with absence of surrounding cisterns and posterior displacement of the 4th ventricle



MRI scanning is superior to CT scanning in the detection and evaluation of brain stem astrocytoma.



Management

Operative exploration is rarely indicated. Radiotherapy is often administered, usually after a stereotactic biopsy, with occasional palliation of symptoms and uncertain effect on survival. Chemotherapy is of no value.

Prognosis

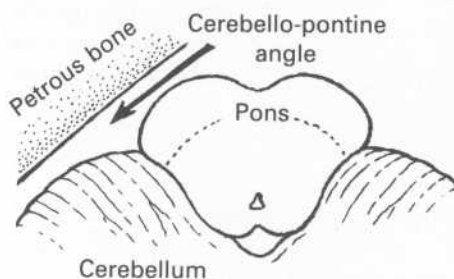
At best, the 5-year survival following radiotherapy is 35%. Rarely, patients may survive for up to 20 years with minimum disability.

TUMOURS OF THE POSTERIOR FOSSA – EXTRINSIC

ACOUSTIC NEUROMA/SCHWANNOMA

Nerve sheath tumours are the commonest infratentorial tumours, constituting 6% of all primary intracranial tumours and 80% of cerebellopontine angle lesions. They usually present in middle age (40–50 years) and occur more frequently in women. Bilateral neuromas occur in 5% of patients and are characteristic of type 2 neurofibromatosis (NF 2) (page 540).

They are benign, slowly growing tumours which arise primarily from the *vestibular* portion of the VIII cranial nerve and lie in the cerebellopontine angle – a wedge shaped area bounded by the petrous bone, the pons and the cerebellum. Rarely these tumours arise from the V cranial nerve.




TUMOURS OF THE POSTERIOR FOSSA – EXTRINSIC

ACOUSTIC NEUROMA/SCWANNOMA (*contd*)


Pathology: The other type of nerve sheath tumour – neurofibroma (page 295) – does not occur intracranially.

Different histological types exist, often within the same tumour:

Antoni type A – shoals and whorls of tightly packed cells in groups or palisades



Antoni type B – a meshwork of interlinked loosely packed stellate cells.



Clinical features

Patients with acoustic tumours often complain of *occipital pain* on the side of the tumour. In addition:

VIII nerve damage causes a *gradually progressive sensorineural deafness* noted over many months or years. *Vertigo* is rarely troublesome since slow tumour growth readily permits compensation. Similarly *tinnitus* is usually minimal.

V nerve damage causes *facial pain, numbness* and *paraesthesia*. *Depression of the corneal reflex* is an important early sign.

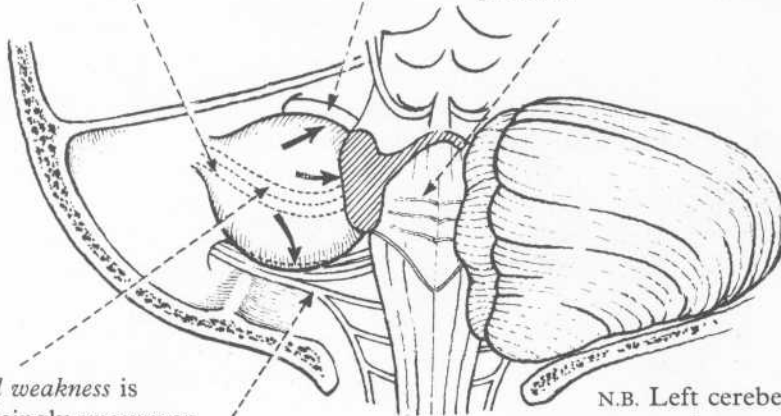
Compression of the aqueduct and the 4th ventricle may result in hydrocephalus with *symptoms and signs of raised intracranial pressure*.

Facial weakness is surprisingly *uncommon* despite marked VII nerve compression

IX, X and XI nerve damage seldom occurs but occasionally large tumours cause *swallowing difficulty, voice change* and *palatal weakness*.

N.B. Left cerebellar hemisphere removed to expose the divided cerebellar peduncles.

Cerebellar and pontine damage – large tumours may compress the cerebellum causing *ataxia, ipsilateral inco-ordination* and *nystagmus*. Pontine damage may produce a *contralateral hemiparesis*.



TUMOURS OF THE POSTERIOR FOSSA – EXTRINSIC

ACOUSTIC NEUROMA/SCWANNOMA (contd)

Investigations

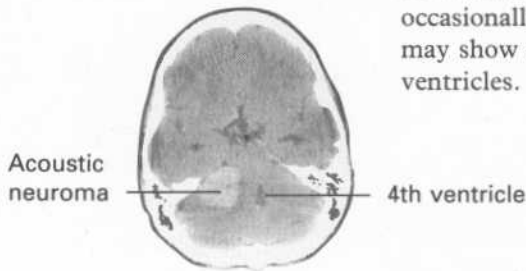
Neuro-otological test (see pages 60–62)

- audiometry
- speech audiometry
- stapedial reflex decay
- brain stem auditory evoked potential
- caloric testing – invariably shows absence or impairment of the response on the affected side.

help differentiate deafness due to:
 conductive deficit
 sensorineural $\left\{ \begin{array}{l} \text{cochlear deficit} \\ \text{retrocochlear deficit} \\ \text{(e.g. acoustic tumour)} \end{array} \right.$

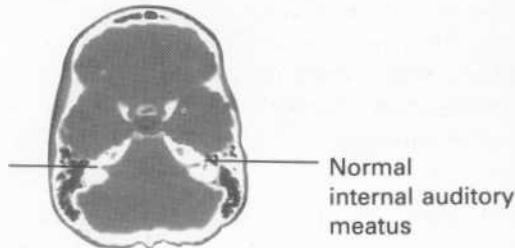
CT scan

I.V. contrast is essential, since acoustic tumours are often isodense. After contrast the tumour, lying adjacent to the IAM enhances strongly. Low density cystic areas are occasionally seen. Patients with 4th ventricle compression may show associated dilatation of the 3rd and lateral ventricles.



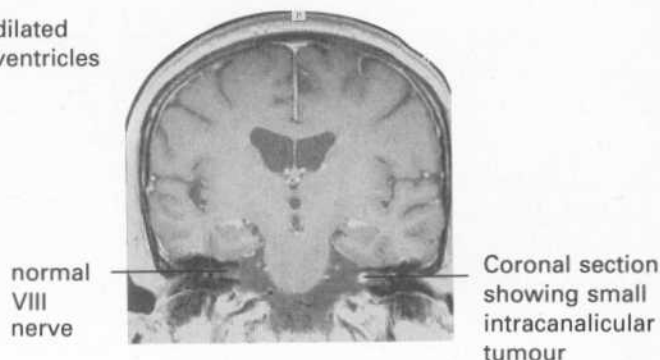
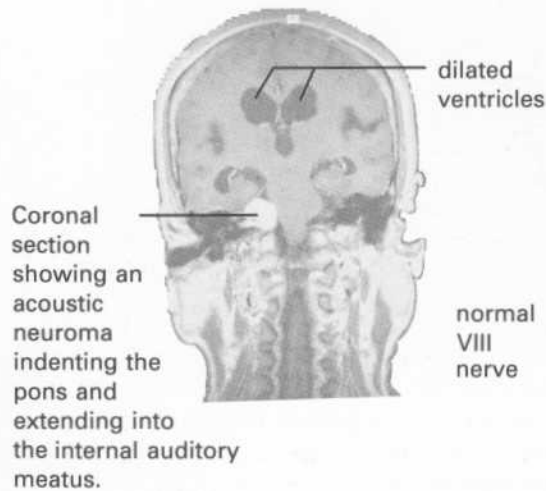
CT scanning also demonstrates the size of the mastoid air cells – useful information for operation.

Bone window levels usually show dilation of the internal auditory meatus.



MRI

The investigation of choice, particularly for small intracanalicular tumours. On a T1 weighted image, the lesion enhances strongly after i.v. gadolinium.



TUMOURS OF THE POSTERIOR FOSSA – EXTRINSIC

ACOUSTIC NEUROMA/SCHWANNOMA Management

Treatment aims at

- tumour removal with minimal risk,
- preservation of facial nerve function,
- retention of useful hearing unless this is already lost.

Since the chance of success relates directly to tumour size, few advocate a conservative approach, even though the growth rate is usually slow.

Technique

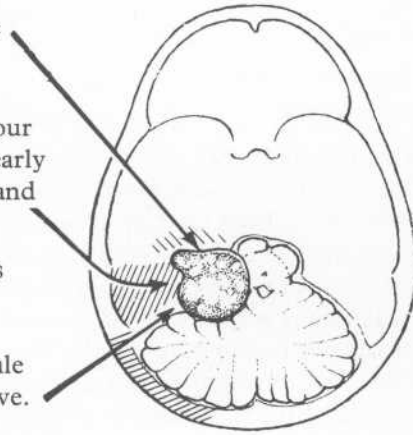
Middle fossa approach: temporal lobe retraction exposes the acoustic tumour and facial nerve from above. The tentorium cerebelli and the superior petrosal sinus are divided if necessary.

TRANSLABYRINTHINE APPROACH: approaching the tumour through the mastoid air cells and the labyrinth, permits early identification of the facial nerve; tumour decompression and removal follows.

SUBOCCIPITAL APPROACH: the cerebellopontine angle is approached from below by removing occipital bone and retracting the cerebellum.

Tumour debulking aids dissection of the tumour capsule from the surrounding structures, including the facial nerve. Drilling away the posterior wall of the internal meatus exposes the tumour and facial nerve lying within the canal.

Some surgeons prefer a joint translabyrinthine/suboccipital approach.



All methods have their advocates. Limited visualisation of the brain stem structures through a translabyrinthine approach makes this inappropriate for large tumours. Inevitably this approach damages hearing. With very small tumours, careful removal via the suboccipital route may preserve the cochlear nerve as well as facial nerve function. Perioperative electrophysiological monitoring may aid preservation of these structures.

Results

Outcome relates to tumour size. With a tumour diameter of 5 mm or less, some hearing can be preserved in about 50% and facial nerve function in > 90%. With tumours of 2–3 cms, all lose hearing and only 50% retain facial nerve function, and this may take many months to recover. Incomplete eye closure may require *tarsorrhaphy* to prevent corneal ulceration. When facial nerve palsy persists, *hypoglossal-facial anastomosis* may improve the cosmetic result. Swallowing difficulty from X cranial nerve damage seldom persists; intravenous or cautious oral fluid administration should prevent aspiration.

The risk of death or severe disability approaches 5% for very large tumours. Death usually results from damage to important vascular structures (e.g. anterior inferior cerebellar artery) or from postoperative cerebellar swelling.

Every effort should be made to remove all tumour tissue, with a two-stage operation if necessary. Incomplete removal results in late recurrence. Despite this, in some elderly patients, a subtotal intracapsular decompression may provide the safest approach.

TUMOURS OF THE POSTERIOR FOSSA – EXTRINSIC

TRIGEMINAL NEUROMA/SCHWANNOMA

Rarely neurilemmomas arise from the trigeminal ganglion or nerve root. These lie in the middle fossa or extend into the cerebellopontine angle, compress surrounding structures – cavernous sinus, midbrain and the pons – and erode the apex of the petrous bone.

Clinical features are usually long-standing – facial pain, paraesthesia and numbness. Compression of posterior fossa structures results in nystagmus, ataxia and hemiparesis.

CT scan or MRI with contrast demonstrates an enhancing lesion eroding the petrous apex and extending into the middle and/or posterior fossa.

Management: Operative removal, even if subtotal, should provide long-lasting benefit. The tumour is approached through either the middle fossa or through a suboccipital craniectomy depending on the predominant site.

MENINGIOMA

Approximately 8% of all intracranial meningiomas arise in the posterior fossa.

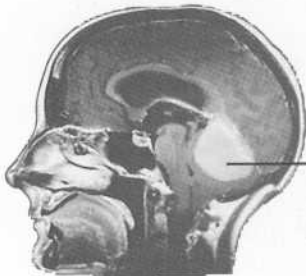Clinical features

These depend on the exact tumour site. Those arising over the *cerebellar convexity* may not present until the mass obstructs CSF drainage. Meningiomas arising in the *cerebellopontine angle* may involve any cranial nerve from V to XII. A *clivus* meningioma may cause bilateral VI nerve palsies before pontine pressure causes long tract signs.

Tumours growing at the *foramen magnum*, compressing the cervico-medullary junction, produce characteristic effects – pyramidal weakness initially affecting the ipsilateral arm, followed by the ipsilateral leg, spreading to the contralateral limbs with further tumour growth.

Investigations

CT scan with intravenous contrast will identify the tumour site, but *MRI* with gadolinium enhancement shows more anatomical detail.



T1 weighted MRI with gadolinium showing a large tumour arising from the tentorium and straight sinus, compressing the cerebellar vermis and the 4th ventricle.

Management

As with supratentorial meningiomas, treatment aims at complete tumour removal. In the posterior fossa, cranial nerve involvement makes this difficult and exacting; excision of the tumour origin is seldom possible.

TUMOURS OF THE POSTERIOR FOSSA – EXTRINSIC

EPIDERMOID/DERMOID CYSTS

These rare cysts of embryological origin develop from cells predestined to become either epidermis or dermis. They most commonly arise in the cerebellopontine angle but may also occur around the suprasellar cisterns, in the lateral ventricles and in the Sylvian fissures, often extending deeply into brain tissue.

Pathology: Depends on cell of origin:

Epidermoid (epidermis) – a thin transparent cyst wall often adheres firmly to surrounding tissues; the contents – keratinised debris and cholesterol crystals – produce a ‘pearly’ white appearance.

Dermoid (dermis) – as above, but thicker walled and, in addition, containing hair follicles and glandular tissue. Midline dermoid cysts lying in the posterior fossa often connect to the skin surface through a bony defect. This presents a potential route for infection.

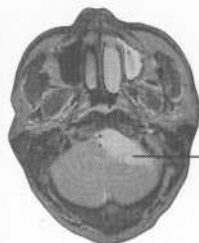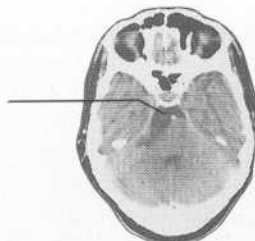
Clinical features

When lying in the cerebellopontine angle, epidermoid/dermoid cysts often cause *trigeminal neuralgia* (see page 159). Neurological findings may range from a depressed corneal reflex to multiple cranial nerve palsies. Rupture and release of cholesterol into the subarachnoid space produces a severe and occasionally fatal *chemical meningitis*. The presence of a *suboccipital dimple* combined with an attack of infective meningitis should raise the possibility of a posterior fossa dermoid cyst with a cutaneous fistula.

Investigations

CT scan shows a characteristic low density (often ‘fat’ density) lesion, unchanged after contrast enhancement or showing only slight peripheral enhancement. Calcification may be evident.

T2 weighted *MRI* appears more sensitive than CT in detecting an abnormality, but the hyperintense signal does not differentiate an arachnoid cyst from an epidermoid.



T2 weighted MRI showing lower cranial nerves traversing the lesion.

Treatment

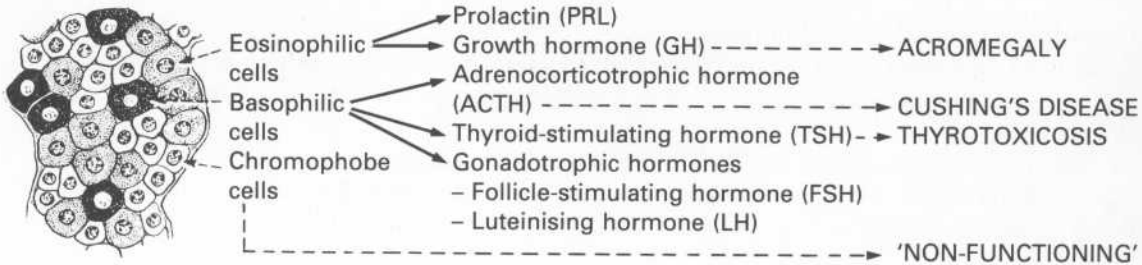
Adherence of the cyst wall to important structures often prevents complete removal, but evacuation of the contents provides symptomatic relief. Aseptic meningitis in the postoperative period requires prompt treatment with steroids. Even when removal is incomplete, recollection of the keratinised debris is uncommon and may take many years.

SELLAR/SUPRASELLAR TUMOURS – PITUITARY ADENOMA

Tumours of the pituitary gland constitute about 5–10% of intracranial tumours. They arise from the anterior portion of the gland and are usually benign.

Previous classification

Previously based on the light microscopic appearance of the tumour cell type.

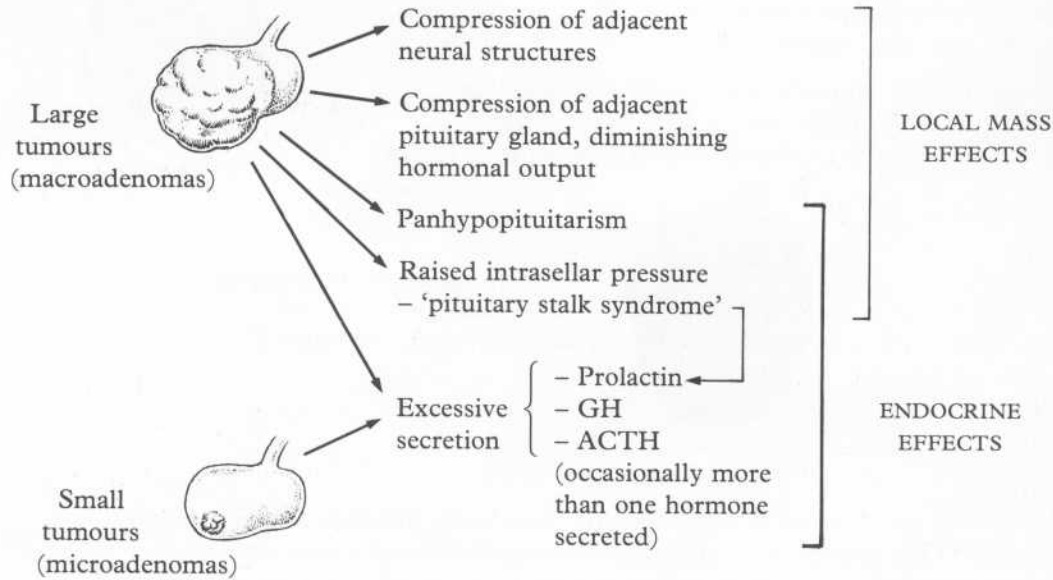


PRESENT classification

Recent immunoassay techniques permit a more practical classification based on the hormone type secreted. About half of the 'non-functioning' chromophobe adenomas are shown to secrete prolactin.

	Incidence
- GH secreting tumour	20–25%
- Prolactinoma	25–50%
- ACTH secreting tumour	5–10%
- TSH secreting tumour	} rare
- FSH/LH secreting tumour	
- Inactive	25–40%

CLINICAL PRESENTATION



SELLAR/SUPRASELLAR TUMOURS – PITUITARY ADENOMA

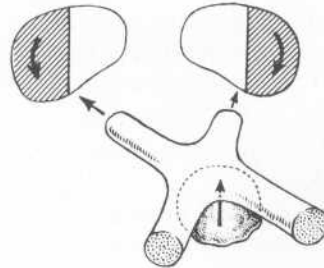
LOCAL MASS EFFECT

Headache

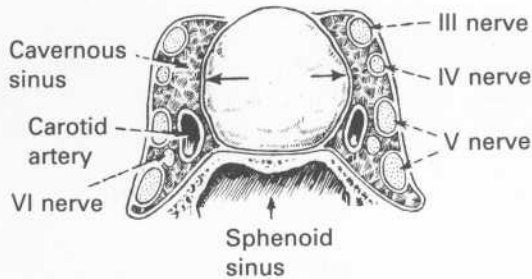
Occurs in most patients with enlargement of the pituitary fossa. It is not specific in site or nature.

Visual field defects

Pressure on the inferior aspect of the optic chiasma usually causes *superior temporal quadrantanopia* initially, with progression to bitemporal hemianopia, but any pattern can occur.



Cavernous sinus compression



In some pituitary tumours, lateral expansion may compress nerves lying within the walls of the cavernous sinus. The III nerve is especially vulnerable. Rarely vertical expansion obstructs the foramen of Munro causing hydrocephalus and/or hypothalamic compression (page 334).

ENDOCRINE EFFECT

1. HYPERSECRETION

The clinical syndrome produced is dependent on the hormone secreted.

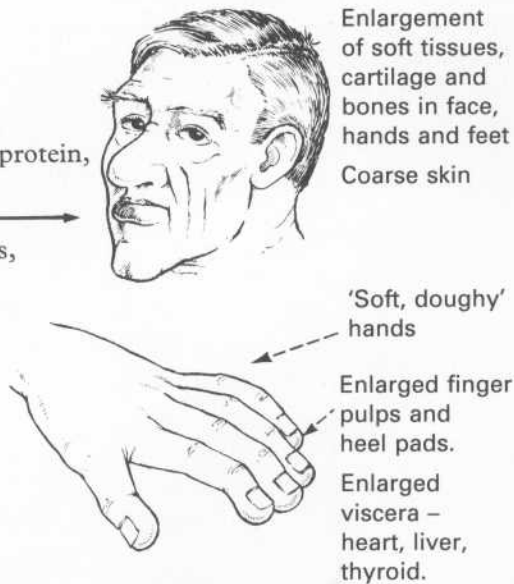
Growth hormone (GH)

Stimulates growth and plays a part in control of protein, fat and carbohydrate metabolism. Excess GH in the adult causes ACROMEGALY.

In childhood, prior to fusion of bone epiphyses, GH excess causes GIGANTISM.

GH levels are usually increased to > 10 mU/l. Increased serum levels of insulin growth factor-1 enhances the effect of growth hormone on target organs.

Hyperglycaemia normally suppresses GH secretion. GH samples are taken in conjunction with blood glucose during a glucose tolerance test. The lack of GH suppression after glucose administration confirms the presence of a tumour.



Diabetes occurs in 10%

SELLAR/SUPRASELLAR TUMOURS – PITUITARY ADENOMA

HYPERSECRETION (*contd*)

Prolactin

This hormone helps to promote lactation. The introduction of immunoassay techniques has shown prolactinomas to be the commonest type of pituitary tumour and aided early detection of prolactin microadenomas. Female: Male ratio – 4:1

This tumour may present with

- INFERTILITY
- AMENORRHOEA
- GALACTORRHOEA

In males, the tumour may present with IMPOTENCE or remain undetected until local pressure effects occur.

In most centres, a serum prolactin of 360 mU/l is considered abnormal, but before assuming the presence of a prolactin secreting tumour, other causes must be excluded.

Causes of hyperprolactinaemia

- Stress
 - Pregnancy
 - Drugs (phenothiazines, oestrogens)
 - Hypothyroidism
 - Renal disease
 - Pituitary adenoma
 - Hypothalamic lesion (e.g. sarcoid, craniopharyngioma) or the pituitary stalk syndrome
 - Seizures
- Since thyrotrophic hormone (TRH) stimulates prolactin release, prolactin levels are high in primary hyperthyroidism.

Prolactin differs from other anterior pituitary hormones in that it is under tonic *inhibitory* control from the hypothalamus. Hypothalamic lesions or raised intrasellar pressure, compromising hypothalamic-pituitary perfusion (i.e. the '*pituitary stalk syndrome*') produce a rise in serum prolactin, but levels seldom exceed 2000 mU/l. Prolactin levels above 4000 mU/l invariably indicate prolactinoma.

SELLAR/SUPRASELLAR TUMOURS – PITUITARY ADENOMA

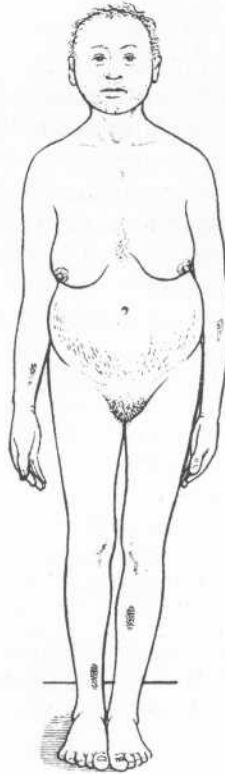
Adrenocorticotrophic hormone (ACTH)

ACTH stimulates secretion of cortisol and androgens. Hypersecretion from a pituitary adenoma or hyperplasia causes CUSHING'S DISEASE (bilateral adrenal hyperplasia) which presents with the characteristic features of CUSHING'S SYNDROME.

This syndrome may also be caused by excessive oral corticosteroids, but also by an adrenal tumour or by ectopic secretion from a bronchial carcinoma.

Features of Cushing's syndrome

- Moon face
- Acne
- Hirsutism and baldness
- Buffalo-type obesity
- Purple striae over flanks and abdomen
- Bruising
- Muscle weakness and wasting
- Osteoporosis
- Hypertension
- Increased susceptibility to infection
- Latent diabetes mellitus



The diagnosis of a pituitary cause is suggested by finding normal or moderately raised ACTH levels which suppress with high doses of dexamethasone.

Ectopic ACTH production does not suppress with dexamethasone and with adrenal tumours, ACTH levels are virtually undetectable.

Other tests include

- the effect of corticotrophin releasing factor (\uparrow ACTH if pituitary origin)
- petrosal versus peripheral venous sampling to identify the source of the ACTH.

Bilateral adrenalectomy for Cushing's syndrome is sometimes followed by the development of *Nelson's syndrome* – high ACTH levels, pituitary enlargement and marked skin pigmentation.

TSH – stimulates thyroid hormone secretion
 FSH – controls growth of ovarian follicles/spermatogenesis
 LH – induces ovulation/testosterone secretion

} Hypersecreting
 tumours
 very rare.

SELLAR/SUPRASELLAR TUMOURS – PITUITARY ADENOMA

2. HYPOSECRETION

Many pituitary tumours are diagnosed before panhypopituitarism develops, but large tumours may cause gradual impairment of pituitary hormone secretion. Growth hormone and the gonadotrophins are first affected, followed by TSH and ACTH.

Panhypopituitarism only occurs when more than 80% of the anterior pituitary is destroyed.

Impaired secretion	Adults	Children
GH –	‘Adult GH deficiency syndrome’ – weight gain, loss of libido, fatigue Amenorrhoea, sterility, loss of libido Glucocorticoid and androgen deficiency, muscle weakness and fatigue Secondary hypothyroidism – sensitivity to cold, dry skin, physical and mental sluggishness, coarseness of hair Failure of lactation	Pituitary dwarfism – [diminished somatic growth, retarded sexual development, hypoglycaemic episodes, normal intelligence]
Gonadotrophins –		
ACTH –		
TSH –		
Prolactin* –		

*Prolactin secretion is most resistant to pituitary damage. Deficiency is seldom evident, usually only presenting after postpartum haemorrhage (Sheehan’s syndrome) as a failure of lactation associated with the other features of panhypopituitarism.

Pituitary hormone assay cannot distinguish low ‘normal’ levels from impaired secretion, but low levels of pituitary hormone in the presence of low target gland hormones confirm hyposecretion, e.g. low TSH levels despite a low serum thyroxine. Basal levels guide replacement therapy.

The lack of response to tests designed to increase specific pituitary hormones provides additional confirmation of hypofunction:

- GH } – *Insulin tolerance test*: Hypoglycaemia acting via the hypothalamic pituitary axis should elevate GH and ACTH levels, the latter causing a significant rise in plasma cortisol.
- ACTH }
- Gonadotrophin – *Gonadotrophin releasing hormone (GnRH) injection* should produce a rapid rise in LH and a slower rise in FSH.
- TSH } – *Thyrotrophin releasing hormone (TRH) injection* should increase plasma levels of both TSH and prolactin.
- Prolactin }

The above tests can be carried out simultaneously as the *Combined pituitary stimulation test*. Insulin, GnRH and TRH are injected intravenously and all anterior pituitary hormones measured from repeated blood samples taken over a 2-hour period. Glucose levels are also checked to ensure adequacy of the hypoglycaemia.

PITUITARY APOPLEXY

This is an uncommon complication of pituitary tumours due to the occurrence of haemorrhage into the tumour substance. Severe headache of sudden onset simulating subarachnoid haemorrhage, rapidly progressive visual failure and extraocular nerve palsies accompany acute pituitary insufficiency. Death may follow unless urgent steroid treatment is instituted.

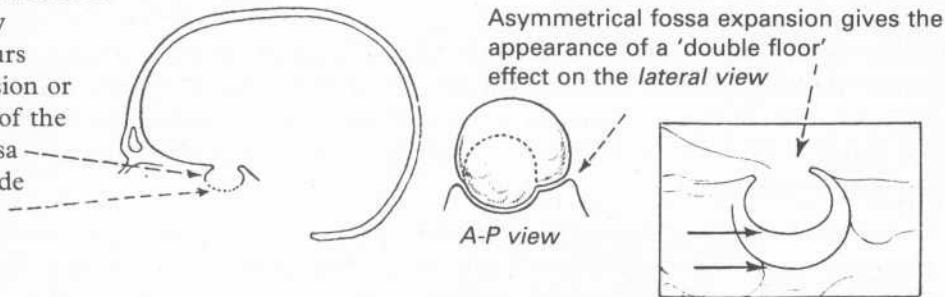
SELLAR/SUPRASELLAR TUMOURS – PITUITARY ADENOMA

NEURORADIOLOGICAL INVESTIGATION

LARGE TUMOURS

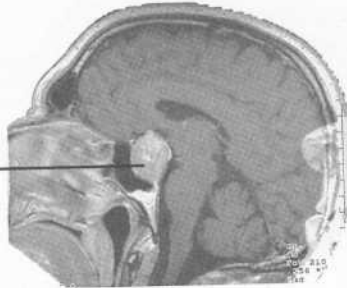Skull X-ray

Large tumours cause expansion or 'ballooning' of the pituitary fossa and may erode the floor

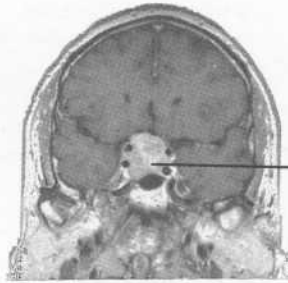


CT scan with contrast enhancement demonstrates tumours filling the pituitary fossa and expanding into the suprasellar compartment, but **MRI** gives more anatomical detail, clearly delineating any suprasellar extension and the effect on adjacent structures.

Sagittal T1 weighted MRI with gadolinium showing a large pituitary tumour of mixed intensity with suprasellar extension.

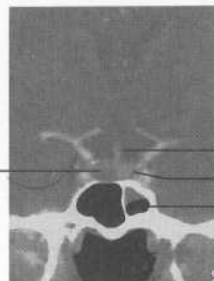

Coronal view of same patient showing relationships of the tumour to the carotid arteries and the cavernous sinus.



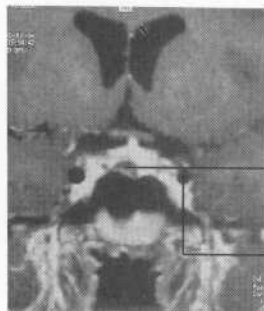MICROADENOMAS

Coronal **CT Scanning** with contrast may demonstrate a low density region within the gland tissue (or may show deviation of the pituitary stalk from the midline). Tumours > 5 mm diameter produce these characteristic appearances. Tumours under this size are difficult to detect.



Pituitary stalk (undeviated)
Normal gland
Sphenoid sinus

MRI is marginally better than CT scanning in the detection of microadenomas but both have false positives and false negatives.



Microadenoma
Carotid artery within cavernous sinus

Angiography or MRI may be required before transphenoidal operation to exclude the presence of an incidental medially projecting aneurysm.

SELLAR/SUPRASellar TUMOURS – PITUITARY ADENOMA

MANAGEMENT

A variety of different forms of treatment are available:

Drug therapy

Bromocriptine: a dopamine agonist which lowers abnormal circulating hormone concentrations, especially prolactin. In two-thirds of patients with prolactinomas, the prolactin levels fall and the tumour shrinks. These patients require long-term therapy as the source of the hyperprolactinaemia persists. Cessation of treatment can result in rapid tumour re-expansion.

Somatostatin analogues: e.g. octreotide, inhibit growth hormone production and cause some tumour shrinkage in a proportion of patients. It is no longer used as long-term therapy unless a specific contraindication to surgery exists.

Operative approach

From BELOW:

1. *Trans-sphenoidal*

Through an incision in the upper gum the nasal mucosa is stripped from the septum and the pituitary fossa approached through the sphenoid sinus.

2. *Transethmoidal*

An incision is made on the medial orbital wall and the pituitary fossa approached through the ethmoid and sphenoid sinuses.

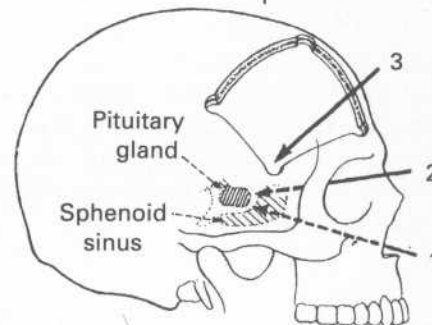
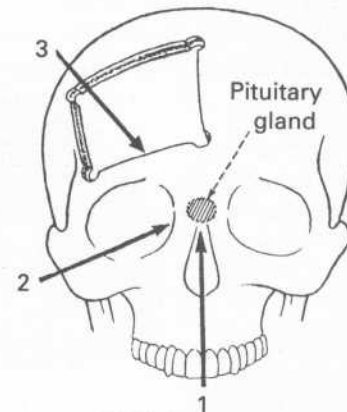
With the transethmoidal and trans-sphenoidal routes the pituitary gland can be directly visualised and explored for microadenoma. Even large tumours with suprasellar extensions may be removed from below, avoiding the need for craniotomy.

From ABOVE

3. *Transfrontal*

Through a craniotomy flap the frontal lobe is retracted to provide direct access to the pituitary tumour. This approach is usually reserved for tumours with large frontal or lateral extensions.

N.B. All patients require steroid cover before any anaesthetic or operative procedure.



Radiotherapy

Pituitary adenomas are radiosensitive and external irradiation is commonly employed. Occasionally, radioactive seeds of yttrium or gold are implanted into the pituitary fossa, either via a trans-sphenoidal approach or stereotactically through a frontal burr hole.

Several months elapse before hormone levels begin to fall. Pituitary function gradually declines over a 5–10 year period after treatment and most patients eventually require replacement hormone therapy to prevent symptoms of hypopituitarism developing.

SELLAR/SUPRASELLAR TUMOURS – PITUITARY ADENOMA

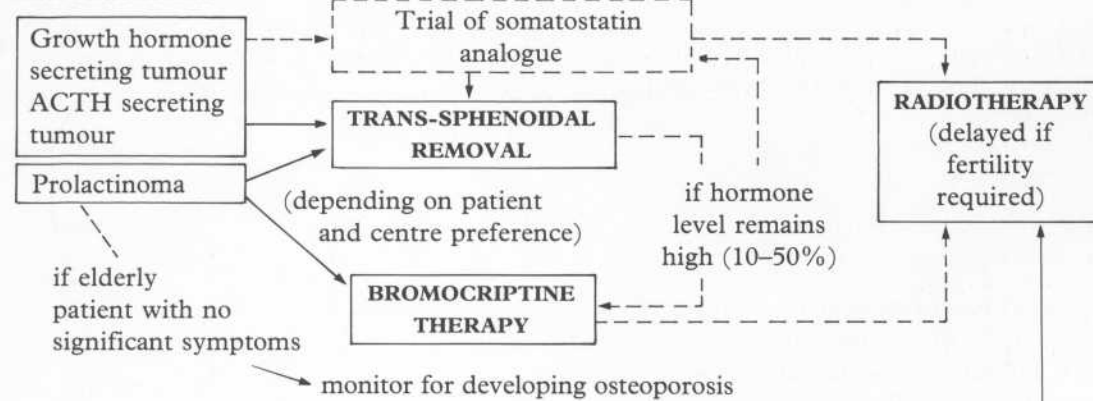
MANAGEMENT (contd)

Treatment selection

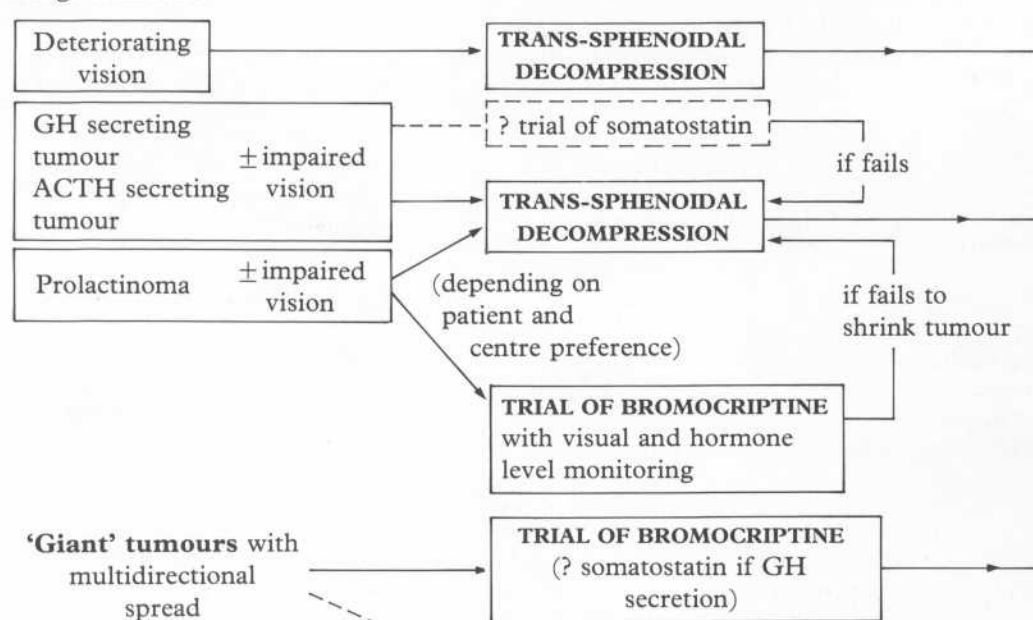
Treatment choice depends on:

- presenting problems and patient's requirements, e.g. restoring fertility, halting visual deterioration.
- patient's age.
- preference and experience of the treatment centre.

Microadenomas



Large tumours



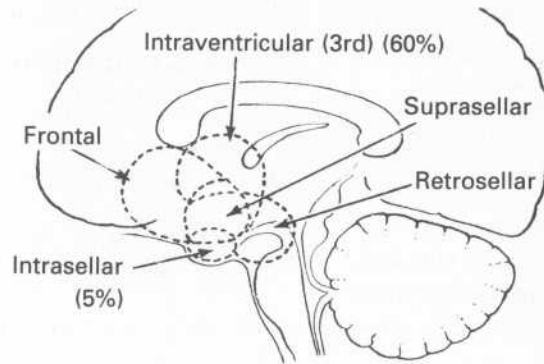
Avoid operation (frontal or trans-sphenoidal decompression) unless rapid deterioration of vision

SELLAR/SUPRASellar TUMOURS

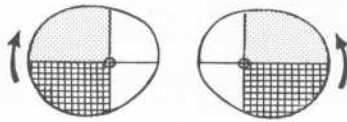
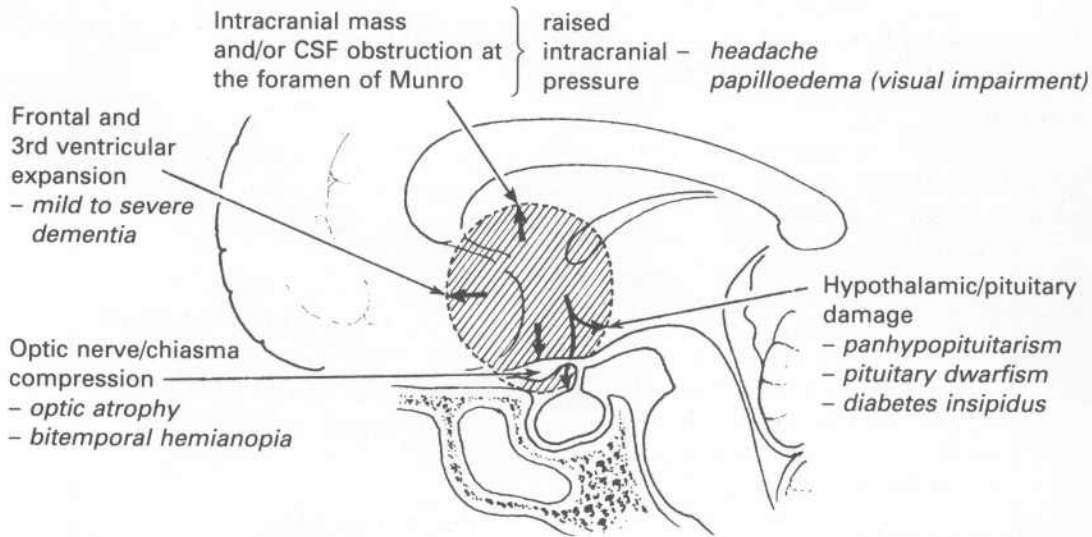
CRANIOPHARYNGIOMA

These cystic tumours constitute about 3% of all primary intracranial tumours. They present predominantly in children and in young adults but symptoms may develop at any age. Although benign, their proximity to crucial structures poses complex problems of management. About 40% of craniopharyngiomas have solid components of squamous epithelium with calcified debris and one or more cystic regions containing greenish cholesteatomatous fluid. In 20% the tumour is solid throughout. Although the tumour capsule appears well defined, histological examination reveals finger-like projections extending into adjacent tissue with marked surrounding gliosis.

Sites: Growth usually begins near the pituitary stalk, but may extend in many directions.



Clinical features: depend on the exact site and size of the tumour. Growth is slow and most signs and symptoms develop insidiously.



Since chiasmal pressure tends to come from above, an *inferior temporal quadrantanopia* usually develops first

SELLAR/SUPRASELLAR TUMOURS

CRANIOPHARYNGIOMA (*contd*)

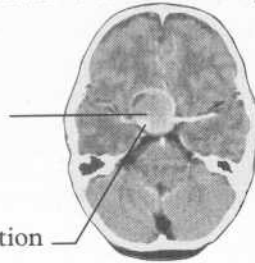
Investigations

Skull X-ray: shows calcification above or within the pituitary fossa in most children and in 25% of adults.

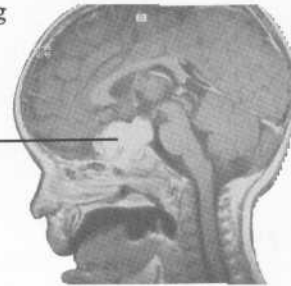
CT scan: shows a lesion of mixed density containing solid and cystic components lying in the suprasellar region.

In children, CT scan invariably shows some calcification

The cyst capsule often enhances with contrast.



Coronal or sagittal *MRI* helps by demonstrating the exact relationships of the tumour to the 3rd ventricle



Pituitary function studies (page 330): often demonstrate the need for hormone replacement.

Management

Several options exist; the more aggressive the treatment, the higher the risks, but the lower the recurrence rate.

All patients require steroid cover before any anaesthetic or operative procedure.

Operative removal usually involves a subfrontal or subtemporal craniotomy, perhaps combined with a transcallosal approach (i.e. splitting the anterior corpus callosum from above and approaching the tumour through the 3rd ventricle). The trans-sphenoidal route may permit removal of purely intrasellar tumours.

Methods

1. Total tumour excision (+ radiotherapy if recurrence develops)
2. Subtotal tumour excision + radiotherapy
3. Cyst drainage + (with an indwelling catheter and reservoir)
 - radiotherapy
 - or
 - implantation of yttrium-90 or chemotherapeutic agent (bleomycin)

Attempted total excision carries a risk of life-threatening hypothalamic damage, but if successful avoids the immediate need and associated risks of radiotherapy to a developing brain. Operative mortality lies between 0–10% and depends on the tumour site and the extent of the attempted removal. Some report a recurrence rate of up to 50% within 10 years of an apparent 'total' removal. This presumably results from residual tumour extensions lying beyond the capsule.

With subtotal removal the recurrence rate approaches 90%, but with radiotherapy this falls to 30–50%.

The decision to aim for total or subtotal removal requires careful judgement.

Preoperative investigations help but the final decision often awaits direct exploration.

SELLAR/SUPRASSELLAR TUMOURS

OPTIC NERVE (GLIOMA) ASTROCYTOMA

This rare tumour usually presents in children under 10 years. Up to one-third, are associated with neurofibromatosis (NFI) where the tumour may be bilateral. Tumour growth expands the nerve in a fusiform manner. Some extend anteriorly into the orbit, others posteriorly to involve the optic chiasma. All are of the pilocytic type and growth is slow.

Clinical features

Visual field scotomas gradually progress to *complete visual loss*.

Orbital extension causes *proptosis*.

In some patients posterior expansion beyond the chiasma causes *hypothalamic damage* (*precocious puberty and other endocrine disturbance*) and/or hydrocephalus.

X-rays of the orbital foramina show dilatation and *CT scans* demonstrate an enhancing mixed attenuation mass within the orbit or lying in the suprasellar region. *MRI* is more sensitive for chiasmatic extensions.

Management

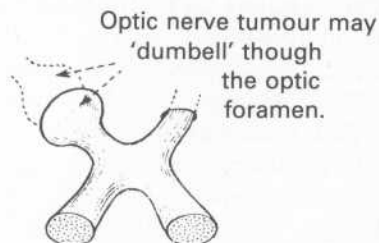
Unilateral within orbit – Complete excision with orbital enucleation if necessary

Lesion involving the optic chiasma – Conservative approach (the value of radiotherapy is not known and may risk vasculitis and intellectual deterioration).

Prognosis

– Long-term survival expected.

– Patients may retain vision for many years; survival is often long-term. Those with hypothalamic damage have a poor prognosis.



SUPRASSELLAR MENINGIOMA

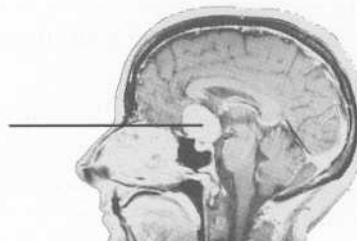Meningiomas arising from the tuberculum sellae often present early as a result of chiasmatic compression causing visual field defects – usually a *bitemporal hemianopia*.

Straight X-rays may show *hyperostosis* of the tuberculum sellae or planum sphenoidale.

CT scan shows a rounded, often partly calcified suprasellar mass homogeneously enhancing with contrast. *MRI* provides improved anatomical detail.

Unfortunately the visual defect often persists after operation, but attempted removal is essential to prevent further progression.

T1 weighted MRI with gadolinium



MENINGIOMA OF THE OPTIC NERVE SHEATH

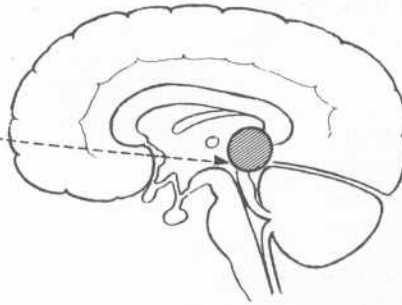
Rarely, meningiomas arise from the optic nerve sheath, usually extending in dumbbell fashion through the optic foramen. Some penetrate the orbital dura and invade the orbital contents. Total excision is impossible without sacrificing the adjacent optic nerve.

SUPRASSELLAR EPIDERMOID/DERMOID (see page 325).

Note: large aneurysms or granulomas (TB, sarcoid) may simulate a sellar/suprasellar tumour on CT scan or MRI. If in doubt, perform angiography or MRA prior to operative exploration.

PINEAL REGION TUMOURS

Pineal region tumours are relatively uncommon. They consist of a variety of different pathological types and as a result of the direct anatomical relationship with the third ventricle include tumours arising at this site. Less than 20% actually originate from 'pineal' cells.



PATHOLOGICAL TYPES

Germinoma: the commonest pineal region tumour, malignant in nature and resembling seminoma of the testis. It adheres firmly to the surrounding tissues and cells readily spread to the floor or anterior wall of the third ventricle. Cells may also seed through the CSF pathways to the spinal cord or cauda equina.

Teratoma: well differentiated tumour occurring predominantly in males, and formed from various cell types – muscle, bone, cartilage, dermis.

Tumour consistency depends on the predominant cell type. In most patients the tumour margin is well defined. Malignant, poorly differentiated forms occasionally occur.

Pineocytoma: well differentiated, slowly growing tumour

Pineoblastoma: poorly differentiated, highly malignant tumour

} rare tumours of true
'pineal' origin.

Glial cell tumours – astrocytoma – arising from cells within the pineal gland, or from adjacent brain.

ependymoma – arising from cells lining the third ventricle.

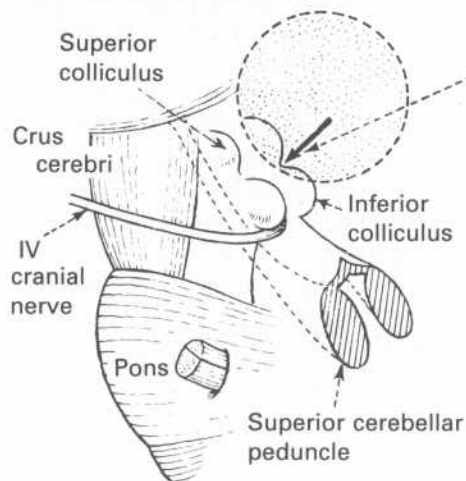
Meningioma

Dermoid

Epidermoid

} rarely occur in the pineal region.

CLINICAL FEATURES Develop due to:



LOCAL MASS EFFECT

Pressure on the tectal region (midbrain) – *PARINAUD'S syndrome* (impaired upward gaze, pupillary abnormalities) (page 153).

Compression of the aqueduct of Sylvius – *obstructive hydrocephalus* with signs and symptoms of raised intracranial pressure.

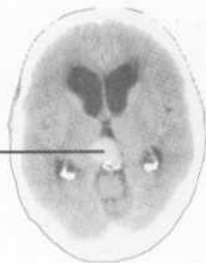EFFECTS FROM SPREAD THROUGH THE THIRD VENTRICLE

e.g. germinoma – hypothalamic damage, diabetes insipidus, hypo/hyperphagia, precocious puberty, hypopituitarism.
– optic chiasmal involvement with visual field defects.

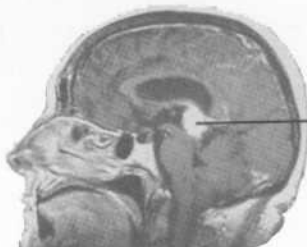
PINEAL REGION TUMOURS

INVESTIGATIONS

CT scan shows a mass projecting into the posterior aspect of the third ventricle with associated dilatation of the third and lateral ventricles.



T₁ weighted MRI with gadolinium



Sagittal MRI clarifies the exact tumour relationship to the third ventricle.

Pineal region tumour (pinealcytoma)

Pineocytomas – may appear calcified.

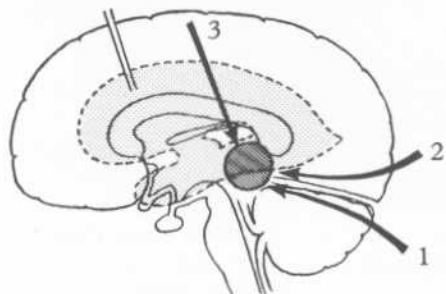
Teratomas – may contain mixed densities from fat to calcification.

Tumour markers – Serum/CSF human chorionic gonadotrophin } May rise in patients
 – Serum/CSF alpha fetoprotein } with germinoma

CSF cytology: Malignant pineal region tumours can metastasise through CSF and cytology is important in planning treatment.

MANAGEMENT

Hydrocephalus often requires urgent treatment with a *ventriculoperitoneal shunt*. Large tumours may obstruct the foramen of Munro, making *bilateral ventricular drainage* necessary.



Routes of direct approach

- 1 – Infratentorial
- 2 – Supratentorial
- 3 – Transventricular

The site of pineal region tumours makes the operative approach difficult, although modern techniques have considerably diminished the risks involved. Either *stereotactic biopsy* or more recently, biopsy via an *endoscope* guided into the third ventricle can obtain a tissue diagnosis, although both procedures carry some risk and some neurosurgeons advocate *direct operative exploration* as the procedure of first choice. Others still advise an initial trial of *radiotherapy* without first obtaining a tissue diagnosis, particularly in the presence of elevated CSF or serum tumour markers. About 70% of tumours (particularly the germinomas) are radiosensitive and show a dramatic reduction in size. Failure to respond indicates the need for either biopsy or direct operation. The entire craniospinal axis is irradiated if CSF cytology is positive.

Patients undergoing a CSF shunt followed by radiotherapy survive 4 years on average.

TUMOURS OF THE VENTRICULAR SYSTEM

EPENDYMOMA

Intracranial ependymomas originate from cells lining the ventricular cavities. Most arise in the 4th ventricle and in this site occur predominantly in children. Both low grade and malignant forms are found and tumour cells may seed throughout CSF pathways.

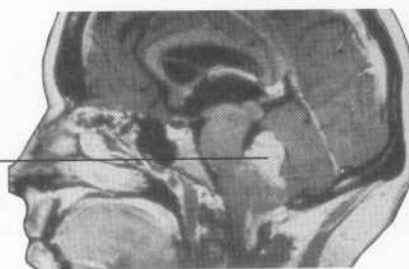In the 4th ventricle, ependymomas present with cerebellar signs or, more commonly, with signs and symptoms of raised intracranial pressure from CSF obstruction. Vomiting is often an early feature from direct brain stem involvement.

CT scanning shows an isodense mass, with or without calcification, lying within the 4th ventricle and usually enhancing with contrast. MRI more clearly delineates the anatomical relationships.

Management

The aim is complete operative removal, although infiltration of the floor of the 4th ventricle may prevent this. Most clinicians advise radiotherapy postoperatively, but its value is limited in the low grade tumours. CSF metastases are treated by total neuraxis irradiation

4th ventricle
ependymoma



Prognosis

Despite relatively slow growth, results are often disappointing with 5-year survival ranging from 20–50%.

CHOROID PLEXUS PAPILLOMA

Rare, benign tumour with a granular surface and a gritty texture.

They develop from the choroid plexus – in the 4th ventricle – adults,
– in the lateral ventricle – children.

Malignant forms occasionally occur in children.

Most patients present with hydrocephalus, either due to obstruction or to excessive CSF secretion from the tumour.

CT scanning shows a hyperdense mass within the ventricular system.

Operative removal gives good results.

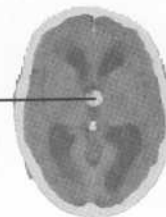COLLOID CYST OF THE THIRD VENTRICLE

A benign cyst, containing a mucoid fluid may arise from embryological remnants in the roof of the third ventricle. When of sufficient size (about 2 cm) it occludes CSF drainage from both lateral ventricles through the foramen of Munro.

Clinical features: Symptoms may be intermittent, possibly due to a ball-valve effect, with episodes of loss of consciousness, sudden weakness of legs, or even sudden death.

CT scan shows a small round mass of increased density, lying level with the foramen of Munro, causing lateral ventricular dilatation. The cyst wall will enhance following contrast on MRI.

These cysts can be drained through a stereotactically placed needle or an endoscope, but with this treatment, recurrence is almost inevitable. Operative removal through a transcallosal or transventricular approach carries little additional risk.

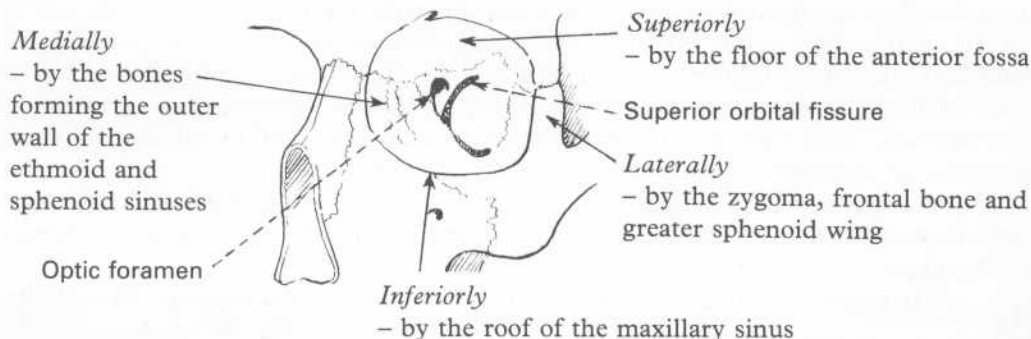


MENINGIOMA: rarely arises in the lateral ventricles. Often symptoms are mild and long standing. Operative removal only becomes necessary when symptoms and signs appear.

GERMINOMA } see Pineal region tumours, page 337.
TERATOMA }

TUMOURS OF THE ORBIT

The orbital cavity is bounded –



PATHOLOGY

Tumours may arise from any of the structures lying within or around the orbit.

LACRIMAL GLAND

- PLEOMORPHIC ADENOMA usually benign, but unless excision is complete recurrences occur
- CARCINOMA

BONE

- OSTEOMA: usually involving frontal or ethmoidal sinuses (may cause a frontal mucocele)
- DERMOID CYST
- EPIDERMOID CYST

PARANASAL SINUSES NASOPHARYNX

- CARCINOMA: often invades the medial wall of the orbit early in the course of the disease

LYMPHOID TISSUE

- LYMPHOMA: developing primarily within the orbit, or secondarily to generalised disease

OPTIC NERVE SHEATH

- MENINGIOMA: often extends intracranially through the optic foramen (see page 336)

RETINA

- RETINOBLASTOMA: highly malignant tumour of childhood
- MELANOMA

OPTIC NERVE

- GLIOMA (pilocytic astrocytoma): very slow growth (see page 336)
- NEUROFIBROMA/NEUROMA

CONNECTIVE TISSUE

- RHABDOMYOSARCOMA: malignant childhood tumour with rapid growth and local spread

BLOOD BORNE METASTASIS

- Adults e.g.
 - BREAST Ca.
 - BRONCHIAL Ca
- Children
 - NEUROBLASTOMA
 - EWING'S SARCOMA
 - LEUKAEMIA

NON-NEOPLASTIC ORBITAL LESIONS

- CAVERNOUS HAEMANGIOMA/LYMPHANGIOMA: common benign lesions in adults
- ORBITAL GRANULOMA (PSEUDOTUMOUR)
- DYSTHYROID EXOPHTHALMOS
- WEGENER'S GRANULOMATOSIS
- SARCOIDOSIS
- HISTIOCYTOSIS X

} (see over)

N.B. CAROTID-CAVERNOUS FISTULA presents with a pulsatile exophthalmos.

TUMOURS OF THE ORBIT

CLINICAL SYMPTOMS AND SIGNS

Orbital pain: prominent in rapidly growing malignant tumours, but also a characteristic feature of orbital granuloma and carotid-cavernous fistula.

Proptosis: forward displacement of the globe is a common feature, progressing gradually and painlessly over months or years (benign tumours) or rapidly (malignant lesions).

Lid swelling: may be pronounced in orbital granuloma, dysthyroid exophthalmos or carotid-cavernous fistula.

Palpation: may reveal a mass causing globe or lid distortion – especially with lacrimal gland tumours or with a mucocele. *Pulsation* indicates a vascular lesion – carotid-cavernous fistula or arteriovenous malformation – listen for a bruit.

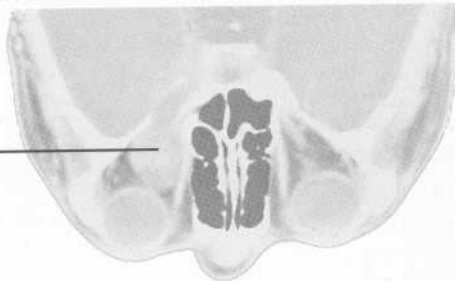Eye movements: often limited for mechanical reasons, but if marked, may result from a dysthyroid ophthalmoplegia or from III, IV or VI nerve lesions in the orbital fissure (e.g. Tolosa Hunt syndrome) or cavernous sinus.

Visual acuity: may diminish due to direct involvement of the optic nerve or retina, or indirectly from occlusion of vascular structures.

INVESTIGATIONS

X-ray of the orbit: may reveal local erosion (malignancy), dilatation of the optic foramen (meningioma, optic nerve glioma) and occasionally calcification (retinoblastoma, lacrimal gland tumours). A meningioma often causes local sclerosis.

CT scan of the orbits demonstrates the precise site of intraorbital pathology and shows the presence of any intracranial extension.



Axial view showing an optic nerve glioma. Coronal views are of value in assessing the size of the optic nerve and extraocular muscles and the floor and roof of the orbit

MRI may provide more information in certain conditions, e.g. meningioma of the optic nerve sheath.

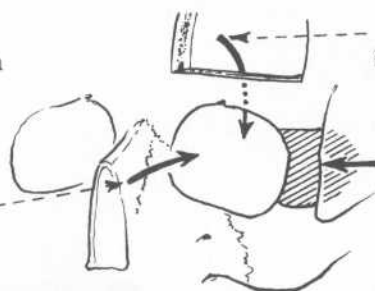
MANAGEMENT

BENIGN tumours: require excision, but if visual loss would inevitably result, the clinician may adopt a conservative approach.

MALIGNANT tumours: require biopsy plus radiotherapy. Lymphomas may also benefit from chemotherapy. Occasionally localised lesions (e.g. carcinoma of the lacrimal gland) require radical resection.

Operative approach

Ethmoidal: for anterior tumours, lying medial to the optic nerve



Frontal-transcranial: for tumours with intracranial extension or lying posterior and medial to the optic nerve

Lateral: for tumours lying superior, lateral or inferior to the optic nerve

NON-NEOPLASTIC ORBITAL LESIONS

ORBITAL GRANULOMA (pseudotumour)

Sudden onset of *orbital pain* with *lid oedema*, *proptosis* and *chemosis* due to a diffuse granulomatous infiltrate of lymphocytes and plasma cells involving multiple structures within the orbit.

This condition usually occurs in middle age and seldom occurs bilaterally. CT scanning or MRI shows a diffuse orbital lesion, although one structure may be predominantly involved, e.g. optic nerve, extraocular muscles or the lacrimal gland. If diagnostic doubt remains, a biopsy is required. Most patients show a dramatic response to high dose *steroid therapy*. If symptoms persist, the lesion should respond well to radiotherapy.

DYSTHYROID EXOPHTHALMOS

The thyrotoxic patient with bilateral exophthalmos presents no diagnostic difficulty, but dysthyroid exophthalmos, with marked lid oedema, lid retraction and ophthalmoplegia *may occur unilaterally* without evidence of thyroid disease.

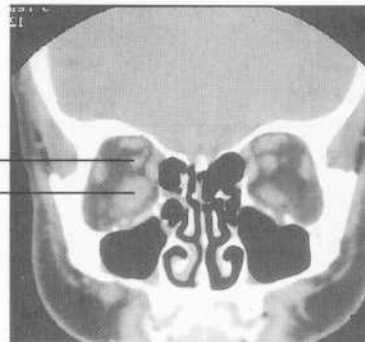
Coronal CT scanning establishes the diagnosis by demonstrating enlargement of the extraocular muscles – primarily the medial and inferior recti. MRI shows a similar appearance.

Circulating thyroid hormone levels are often normal. Thyroid releasing hormone stimulation or thyroid suppression tests may support the diagnosis.

Management

Steroids should help. A few patients require orbital decompression in an attempt to prevent corneal ulceration, papilloedema and blindness.

Optic nerve
Dilated inferior rectus



TUMOURS OF THE SKULL BASE

MALIGNANT CARCINOMA

Carcinoma of the nasopharynx, paranasal sinuses or ear may extend intracranially either by direct erosion or through the skull foramina. It frequently penetrates the dura (in contrast to metastatic carcinoma of the spine) and may involve almost any cranial nerve. Symptoms of nasopharyngeal or sinus disease are often associated with facial pain and numbness. Spread to the CSF pathways leads to *carcinomatous meningitis* and may cause multiple cranial nerve palsies. *Skull X-ray*, *CT scan* and *MRI scan* will demonstrate a lesion involving the skull base. *CT scanning* most clearly shows the bone involvement. *Treatment* is usually restricted to retropharyngeal biopsy plus radiotherapy.

CHORDOMA

Rare tumours of notochordal cell rests arising predominantly in the sphenoido-occipital (clivus) and sacrococcygeal regions. Although growth begins in the midline, they often expand asymmetrically into the intracranial cavity. Chordomas may present at any age, but the incidence peaks in the 4th decade. They are locally invasive and rarely metastasise.

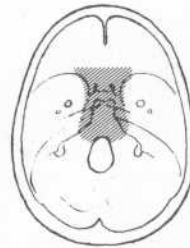Clinical: most patients develop nasal obstruction. Cranial nerve palsies usually follow and depend on the exact tumour site.

Skull X-ray shows a soft tissue mass with an osteolytic lesion of the sphenoid, basi-occiput or petrous apex.

CT scan confirms the presence of a partly calcified mass causing marked bone destruction and extending into the nasopharyngeal space.

MRI scan more clearly demonstrates the structural relationships.

Management: the tumour site prevents complete removal. Usually extensive debulking (sometimes through the transoral route) is combined with radiotherapy. Most patients die within 10 years of the initial presentation.



Chordoma – sites of intracranial origin

BENIGN

GLOMUS JUGULARE TUMOUR (syn: chemodectoma, paraganglioma)

Rare tumour arising from chemoreceptor cells in the jugular bulb or from similar cells in the middle ear mucosa. This tumour extensively erodes the jugular foramen and petrous bone; many patients present with cranial nerve palsies, especially IX–XII. Chemodectomas occasionally arise at other sites and metastasis may occur.

X-ray and *CT scan* demonstrate an osteolytic lesion expanding the jugular foramen.

MRI shows the anatomical relationships.

Angiography reveals a vascular tumour, usually only filling from the external carotid artery, but occasionally from vertebral branches.

Management: tumour vascularity makes excision difficult. Selective embolisation may considerably reduce the operative risks or provide an alternative treatment. The value of radiotherapy is uncertain.

OSTEOMA

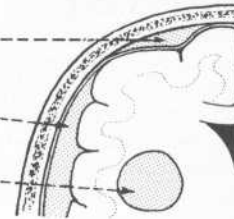
Rare tumours, usually occurring in the frontal sinus and eroding into the orbit, nasal cavity or anterior fossa. If sinus drainage becomes obstructed, a *mucocoele* develops, often with infected contents. These lesions require excision, either through an ethmoidal approach or through a frontal craniotomy.

INTRACRANIAL ABSCESS

The advent of antibiotics and improved treatment of ear and sinus infection has led to a reduction in intracranial abscess formation but the incidence still lies at 2-3 patients per million per year.

Pus may accumulate in:

- the extradural space
- EXTRADURAL ABSCESS
- the subdural space
- SUBDURAL EMPYEMA
- the brain parenchyma
- CEREBRAL ABSCESS

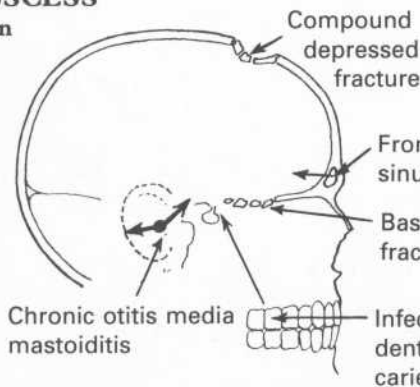


CEREBRAL ABSCESS

Source of infection

Haematogenous spread

- Subacute bacterial endocarditis
- Congenital heart disease (especially right to left shunt)
- Bronchiectasis or pulmonary abscess



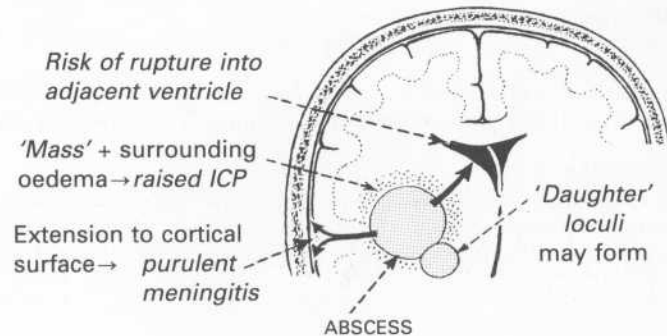
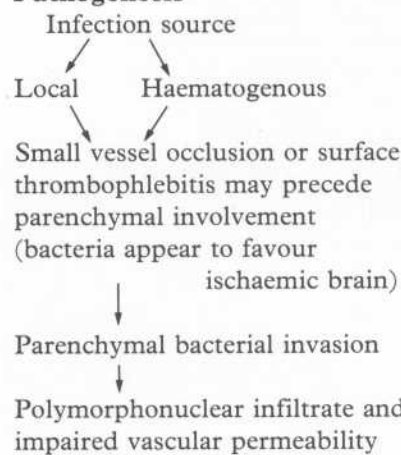
Local spread

- direct penetration of the dura
 - indirect
 - extension of an infected thrombus
 - embolic spread along a vein
- Abscess site depends on the source, e.g. frontal sinusitis
- frontal lobes
 - mastoiditis → temporal lobe or cerebellum

Organisms: Improved aerobic and anaerobic culture techniques now reveal the responsible organism in over 80% of patients. These depend on the source -

- Middle ear - *Strep. milleri*, *Bacteroides fragilis*, *E. Coli* } often mixed
- Proteus*, *Strep. pneumoniae*.
- Sinus - *Strep. pneumoniae*, *Strep. milleri*.
- Blood - *Strep. pneumoniae*, *Strep. milleri*, *Staph. aureas*.
- Accidental or surgical trauma - *Staph. aureas*.
- Immunocompromised patients - *Toxoplasma*, *Aspergillus*, *Candida*, *Nocardia* (see page 494)
- *Listeria* (microabscesses)

Pathogenesis



Mature capsule forms with central zone of necrotic tissue, inflammatory cells and necrotic debris.

Zone of granulation tissue 'CEREBRITIS' → Thin capsule of fibroblasts and reticular fibres form

INTRACRANIAL ABSCESS

CEREBRAL ABSCESS (*contd*)

Clinical effects

Symptoms and signs usually develop over 2–3 weeks and progress. Occasionally the onset is more gradual, but features may develop acutely in the immunocompromised patient.

Clinical features arise from:

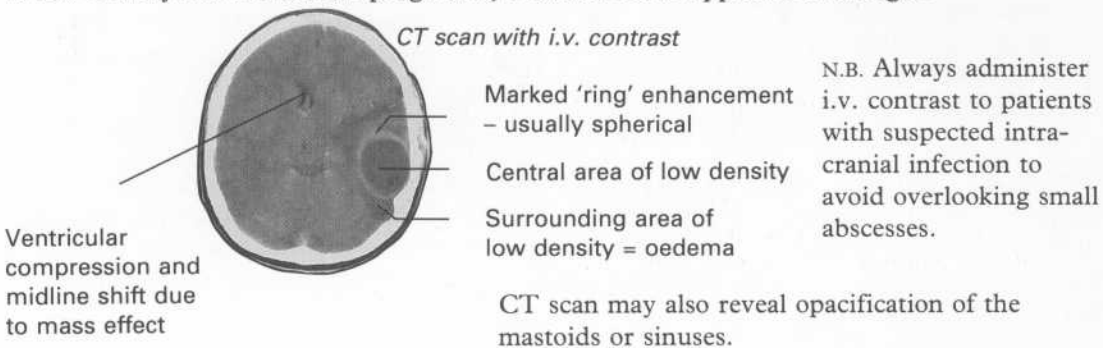
- Toxicity – *pyrexia, malaise* (although systemic signs often absent).
- Raised intracranial pressure – *headache, vomiting* → *deterioration of conscious level*.
- Focal damage – *hemiparesis, dysphasia, ataxia, nystagmus*
 - *epilepsy* – partial or generalised, occurring in over 30%
- Infection source – *tenderness over mastoid or sinuses, discharging ear*.
 - bacterial endocarditis – *cardiac murmurs, petechiae, splenomegaly*.
- Neck stiffness due to coexistent meningitis or tonsillar herniation occurs in 25%.

N.B. Beware attributing patient's deteriorating clinical state to the primary condition, e.g. otitis media, thus delaying essential investigations.

Investigations

X-ray of the sinuses and mastoids: opacities indicate infection.

CT scan: in the stage of 'cerebritis' the CT scan may appear normal or only show an area of low density. As the abscess progresses, a characteristic appearance emerges:



If abscesses occur at multiple sites, suspect a haematogenous source.

MRI: will more readily detect the 'cerebritic' stage, but does not distinguish infection from other pathologies.

Lumbar puncture is contraindicated in the presence of a suspected mass lesion, but if CSF is obtained inadvertently, this will show ↑ protein e.g. 1 g/l, ↑ white cell count (several hundred /ml) – polymorphs or lymphocytes. The Gram stain is occasionally positive.

Peripheral blood – may show ↑ ESR, leucocytosis. Blood culture is positive in 10%.

INTRACRANIAL ABSCESS

CEREBRAL ABSCESS (*contd*)

Management:

1. Antibiotics

Commence i.v. antibiotics on establishing the diagnosis (prior to determining the responsible organism or its sensitivities). Antibiotics are selected for their ability to cross the blood-brain barrier. The ease with which they penetrate the abscess capsule remains uncertain. Use combined therapy:

- PENICILLIN 4 mega-units q.i.d. - to cover streptococcus
- METRONIDAZOLE 1 g q.i.d. - to cover anaerobic organisms
- CHLORAMPHENICOL 500 mgs q.i.d. - to cover all other organisms
(or third generation cephalosporin e.g. cefotaxime 2 g q.i.d. or ceftriaxone 2-4 g/day)

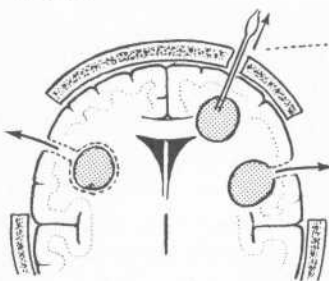
In immunocompromised patients – see page 494.

Later determination of the organism and its sensitivities permits alteration to more specific drugs. Intravenous antibiotics should continue for 2-3 weeks followed by oral medication for a further 3-4 weeks.

2. Abscess drainage

Various methods exist:

Primary excision of the whole abscess including the capsule (standard treatment of cerebellar abscess)



Burr hole aspiration of pus, with repeated aspirations as required.

Evacuation of the abscess contents under direct vision, leaving the capsule remnants.

Burr hole aspiration is simple and relatively safe. Persistent reaccumulation of pus despite repeated aspiration requires secondary excision. Primary excision removes the abscess in a single procedure, but carries the risk of damage to surrounding brain tissue. Open evacuation of the abscess contents requires a craniotomy, but minimises damage to surrounding brain.

3. Treatment of the infection site

Mastoiditis or sinusitis requires prompt operative treatment, otherwise this acts as a persistent source of infection.

Steroids help reduce associated oedema but they may also reduce antibiotic penetration and impede formation of the abscess capsule. Their value in management remains controversial.

Conservative management: In some situations the risks of operative intervention outweigh its benefits. In those patients, treatment depends on i.v. antibiotics.

- Indications:
- small deep abscesses, e.g. thalamic (although stereotactic aspiration may help).
 - multiple abscesses.
 - early 'cerebritic' stage.

Prognosis

The use of CT scanning in the diagnosis and management of intracranial abscesses and the recognition and treatment of pathogenic anaerobic organisms have led to a reduction in the mortality rate from 40% to 10%. In survivors, focal deficits usually improve dramatically with time. Persistent seizures occur in 50%.

INTRACRANIAL ABSCESS

SUBDURAL EMPYEMA

Subdural empyema occurs far less frequently than intracerebral abscess formation. Infection usually spreads from infected sinuses or mastoids, but may arise from any of the aforementioned sources. The responsible organism is usually *Strep. pneumoniae*, *Strep. milleri* or *Staph. aureus*. Clinical features match those of intracerebral abscess but since rapid extension occurs across the subdural space, overwhelming symptoms often develop suddenly. Seizures occur in 70% at onset.

CT scan shows a low density extracerebral collection with mass effect, often with enhancement on the cortical surface; occasionally isodense lesions make identification difficult.

Management: Intravenous antibiotic treatment is combined with evacuation of pus either through multiple burr holes or a craniotomy flap. Despite active treatment, the mortality rate still runs at approximately 20%.

GRANULOMA

TUBERCULOMA

Although tuberculomas still constitute an important cause of mass lesions in underdeveloped countries (20% in India), they are now rare in Britain. The lesions may be single or multiple. They often lie in the cerebellum, especially in children.

Clinical features are those of any intracranial mass; alternatively tuberculoma may present in conjunction with tuberculous meningitis.

CT scan clearly demonstrates an enhancing lesion – but this often resembles astrocytoma or metastasis; tuberculomas have no distinguishing features. *MRI* is even more sensitive and may show additional lesions.

Other investigations: ESR, chest X-ray often fail to confirm the diagnosis. A Mantoux (PPD) test is usually positive but a negative test does not eliminate the diagnosis.

Management: When tuberculoma is suspected, a trial of antituberculous therapy is worthwhile. Follow up *CT* scans should show a reduction in the lesion size. Other patients require an exploratory operation and biopsy followed by long-term drug treatment.

SARCOIDOSIS

Sarcoidosis is a systemic disease of unknown aetiology characterised by noncaseating epithelioid cell tubercles. Nervous system involvement occurs in 8% and may dominate the presentation.

When sarcoid infiltrates the central nervous system it usually involves the meninges. In some patients mass lesions may arise from the dura, but more commonly signs and symptoms relate to an adhesive arachnoiditis involving the skull base, cranial nerves and pituitary stalk. Mass lesions may occasionally arise within the brain and spinal cord without obvious meningeal involvement.

Investigation: *MRI* (T_1 weighted) shows either a hyperintense mass or multiple periventricular foci. A definitive diagnosis is based on clinical and radiological evidence of multisystem disease confirmed by characteristic histology.

The diagnosis is often elusive and suggested by clinical presentation supported by some of the following.

- elevated serum and CSF angiotensin converting enzyme (ACE),
- elevated serum immunoglobulins,
- elevated serum calcium,
- elevated CSF cell count (monocytes) and immunoglobulins.

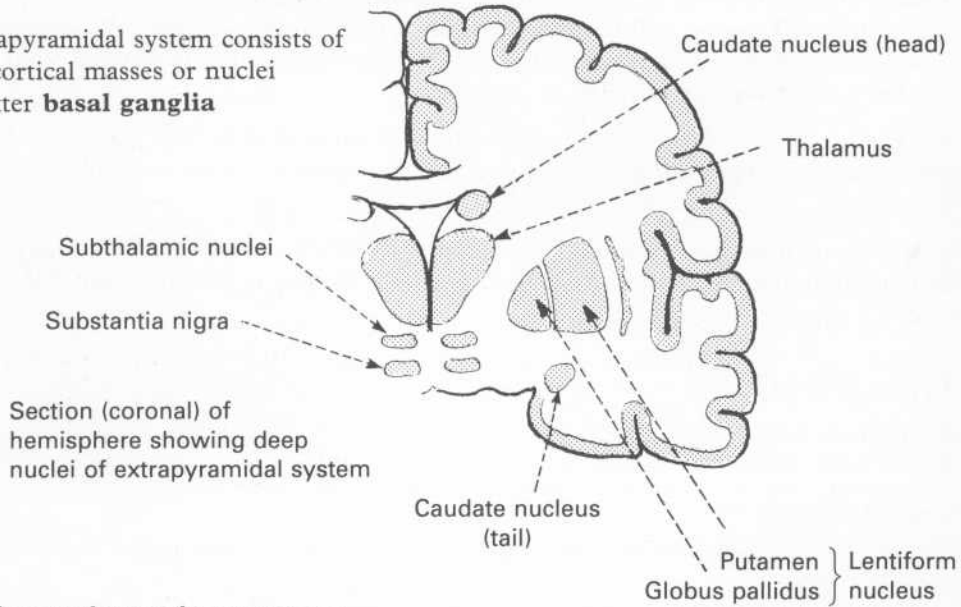
The Kveim test is not specific and is rarely used.

Management: Long-term steroids. Or in resistant cases, azathioprine or cyclophosphamide.

MOVEMENT DISORDERS – EXTRAPYRAMIDAL SYSTEM

The control of voluntary movement is effected by the interaction of the pyramidal, cerebellar and extrapyramidal systems interconnecting with each other as well as projecting to the anterior horn region or cranial nerve motor nuclei.

The extrapyramidal system consists of paired subcortical masses or nuclei of grey matter **basal ganglia**



The caudate nucleus and putamen are collectively referred to as the STRIATUM.

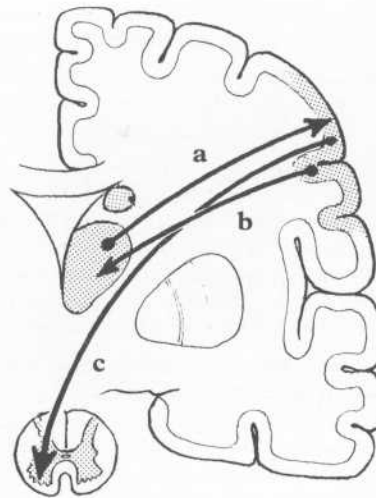
Interconnections of the deep nuclei

The connections between components of the extrapyramidal system and other parts of the brain are complex. However, certain simple observations can be made:

a – The thalamus plays a vital rôle in projecting information from the basal nuclei and cerebellum to the motor cortex via *thalamocortical pathways* and exerts an influence on the *corticospinal pathway* at its origin.

b – The cortical neurons project to the thalamus thus providing a feedback loop between these structures.

c – Outflow is solely through the corticobulbar and corticospinal (pyramidal) pathways.



MOVEMENT DISORDERS – EXTRAPYRAMIDAL SYSTEM

NEUROPHARMACOLOGY

The observation that drugs such as reserpine and phenothiazines regularly produce extrapyramidal syndromes has clarified the neurochemical basis of movement disorders and delineated the role of neurotransmitters.

Neurotransmitter substances are synthesised and stored presynaptically. When released by an appropriate stimulus they cross the synaptic gap and combine with specific receptors of the postsynaptic cell,

- e.g. – acetylcholine – serotonin
 – dopamine – glutamate
 – γ -aminobutyric acid

Neuromodulator substances diminish or enhance the effects of neurotransmitters in the basal ganglia,

- e.g. – substance P
 – enkephalin
 – cholecystokinin
 – somatostatin.

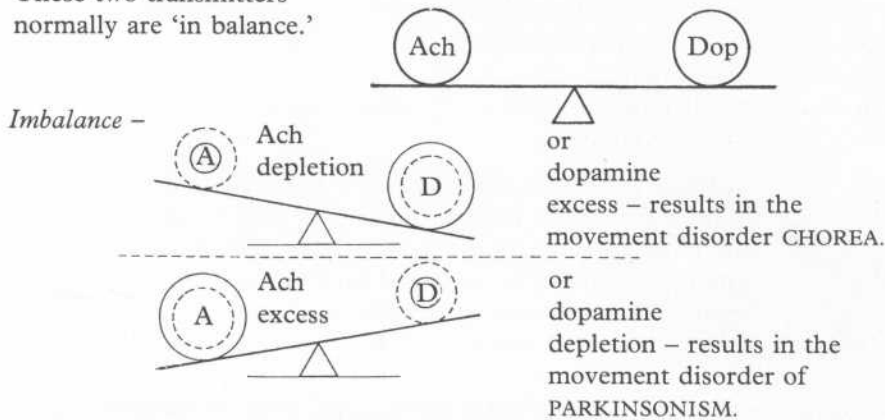
ACETYLCHOLINE

- Synthesised by small striatal cells
- Greatest concentration in striatum
- Excitatory effect.

DOPAMINE

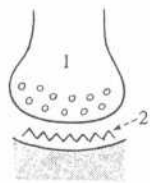
- Synthesised by cells of substantia nigra (pars compacta) and nigral projections in striatum.
- Greatest concentration in substantia nigra.
- Inhibiting effect.

These two transmitters normally are 'in balance.'



γ -Aminobutyric acid (GABA) is synthesised in the striatum and globus pallidus. It has inhibitory actions and deficiency is associated with Huntington's chorea.

Drugs may produce movement disorders by interfering with neurotransmission in the following ways:



- By reducing transmitter presynaptically e.g. tetrabenazine reduces dopamine.
 - By blocking the receptor site postsynaptically – as phenothiazines do to dopamine receptors.
- Both reduce effective dopamine and create a relative excess of acetylcholine
 ↓
 Parkinsonism

MOVEMENT DISORDERS – EXTRAPYRAMIDAL DISEASES

CLINICAL FEATURES

The effects of disease of the extrapyramidal system on movement can be regarded as *negative* (primary functional deficit) and *positive* (secondary effect due to release or disinhibition in undamaged regions).

Negative features

1. *Bradykinesia*: – a loss or slowness of voluntary movement.

This is a major feature of Parkinson's disease and produces:

- reduced facial expression (mask-like)
- reduced blinking
- reduced adjustments of posture when seated.

When agitated the patient will move swiftly – 'kinesia paradoxa'.

2. *Postural disturbance*: – most commonly seen in Parkinson's disease.

Flexion of limbs and trunk is associated with a failure to make quick postural or 'righting' adjustments to correct imbalance. The patient falls whilst turning or if pushed.

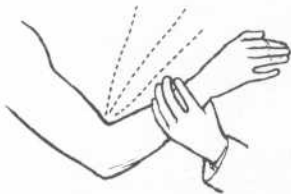
Positive features

1. *Involuntary movements*:

- tremor
- chorea (irregular, repetitive, jerking movements).
- athetosis (irregular, repetitive, writhing movements).
- dystonia (slow, sustained, abnormal movement).
- ballismus (explosive, violent movement).

Chorea and athetosis may merge into one another – choreoathetosis.

2. *Rigidity*



Stiffness felt by the examiner when passively moving a limb.

This 'resistance' is present to the same degree throughout the full range of movement, affecting flexor and extensor muscle groups equally and is described as PLASTIC or LEAD PIPE rigidity. When tremor is superimposed upon rigidity it produces a COGWHEELING quality.

In Parkinson's disease both positive features, e.g. tremor, and negative features, e.g. bradykinesia, occur.

In Huntington's chorea positive features, e.g. chorea, predominate.

PARKINSON'S DISEASE

Described by James Parkinson (1817) in 'An essay on the shaking palsy'.

Recognised as an extrapyramidal disorder by Kinnier Wilson (1912).

Annual incidence: 20 per 100 000. Prevalence: 190 per 100 000.

Sex incidence: male:female – 3:2

Age of onset: 50 years upwards. Incidence peaks in mid-70s then declines.

Familial incidence occurs in 5%.

AETIOLOGY

The cause of Parkinson's disease is unknown. Discordance in identical twins suggests that genetic factors are not important and environmental mechanisms appear to play a role.

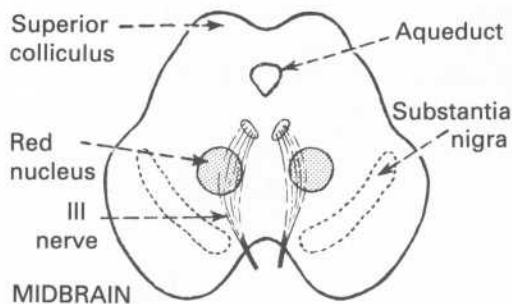
Increased interest in the role of exogenous toxins has arisen through the recent observation that, in drug abusers, 1-methyl-4-phenyl 1236 tetrahydropyridine (MPTP) produces parkinsonism by selectively destroying nigral cells and their striatal projections.

Observations of altered iron metabolism, increased oxidative stress, reduced glutathione and mitochondrial complex I deficiency indicate a widespread biochemical abnormality.

Features of Parkinson's disease occur in many disorders (Akinetic rigid syndromes)

- idiopathic Parkinson's disease
- secondary Parkinsonism
 - drug induced e.g. haloperidol
 - post encephalitic
 - toxic e.g. Carbon monoxide
 - toxic (endogenous) e.g. Wilson's disease
- Multiple System Atrophy (MSA)
- Progressive supranuclear palsy
- Corticobasal degeneration
- Diffuse Lewy body disease
- Alzheimer's disease

PATHOLOGY of idiopathic Parkinson's disease



The substantia nigra contains pigmented cells (neuromelanin) which give it a characteristic 'black' appearance (macroscopic). These cells are lost in Parkinson's disease and the substantia nigra becomes pale. Remaining cells contain atypical eosinophilic inclusions in the cytoplasm – *Lewy bodies* – although these are not specific to Parkinson's disease. Lewy bodies may be found in the cerebral cortex especially when dementia is present (Diffuse Lewy body disease).

Minor changes are seen in other basal nuclei – striatum and globus pallidus.

Radiolabelled ligand studies have identified two dopamine receptors on striatal cell membranes – D₁ – D₅ receptors.

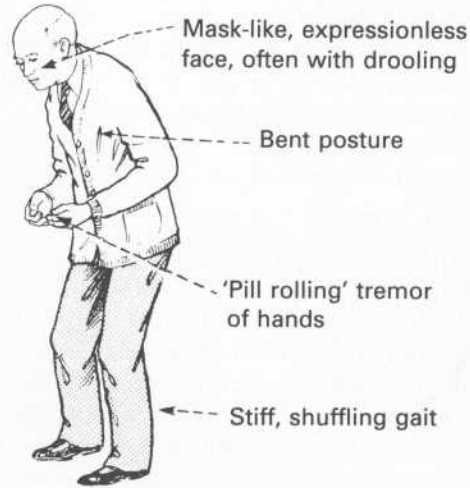
The D₂ receptor correlates with Parkinson's disease. When blocked by phenothiazines it enhances symptoms; when activated by dopamine or dopamine agonists it reduces symptoms.

PARKINSON'S DISEASE

CLINICAL FEATURES

Initial symptoms are vague, the patient often complains of aches and pains.

1. A coarse TREMOR at a rate of 4 per second usually develops early in the disease. It begins unilaterally in the upper limbs and eventually spreads to all four limbs. The tremor is often 'pill rolling', the thumb moving rhythmically backwards and forwards on the palm of the hand. It occurs at rest, improves with movement and disappears during sleep.



2. RIGIDITY is detected by examination. It predominates in the flexor muscles of the neck, trunk and limbs and results in the typical 'flexed posture'.
3. BRADYKINESIA: This slowness or paucity of movement affects facial muscles of expression (mask-like appearance) as well as muscles of mastication, speech, voluntary swallowing and muscles of the trunk and limbs. Dysarthria, dysphagia and a slow deliberate gait with little associated movement (e.g. arm swinging) result.

Tremor, rigidity and bradykinesia deteriorate simultaneously, affecting every aspect of the patient's life:

Handwriting reduces in size.

The gait becomes shuffling and festinant (small rapid steps to 'keep up with' the centre of gravity) and the posture more flexed.

Rising from a chair becomes laborious with progressive difficulty in initiating lower limb movement from a stationary position.

Eye movements may be affected with loss of ocular convergence and upward gaze.

Excessive sweating and greasy skin (seborrhoea) can be troublesome.

Depression, drug-induced confusional states and dementia occur in 30% of patients.

Occasionally autonomic features occur – postural hypotension.

Postencephalitic Parkinson's disease (encephalitis lethargica), now rarely encountered, is characterised by an earlier age of onset and oculogyric crises (acute ocular deviation).

PARKINSON'S DISEASE

DIAGNOSIS

When tremor, rigidity and bradykinesia coexist, distinguish Parkinson's disease from secondary parkinsonism by the absence of a relevant drug history.

Distinguish TREMOR from

- | | | |
|---------------------------------------------------------------------------------------------------------------------------|---|-------------------------------------------------------------------|
| <ul style="list-style-type: none"> - senile tremor - essential tremor - metabolic tremor | } | all are absent at rest and more pronounced on voluntary movement. |
|---------------------------------------------------------------------------------------------------------------------------|---|-------------------------------------------------------------------|

Distinguish RIGIDITY from spasticity – with passive limb movement, spasticity is felt towards the end rather than through the full range of movement.

Distinguish BRADYKINESIA from – gait disturbance of normal pressure hydrocephalus. SPECT imaging with ^{123}I -iodobenzamide (IB_2M) as a D_2 ligand and PET studies with ^{18}F 6 fluorodopa appear promising diagnostic tests. Pharmacologic tests of dopaminergic responsiveness with apomorphine (D_1 and D_2 receptor agonist) do not give definite diagnostic information.

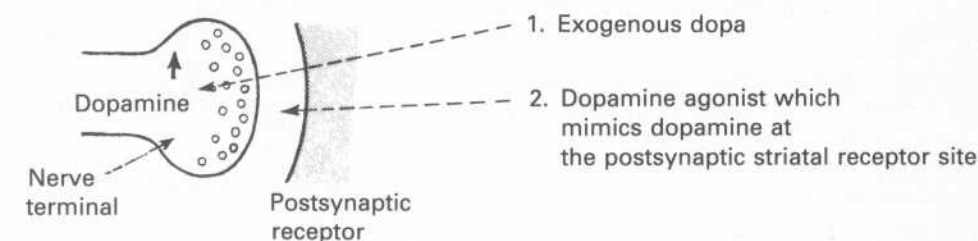
TREATMENT is symptomatic and does not halt the pathological process. It aims at restoring the dopamine/acetylcholine balance (dopamine deficiency) by:

1. Anticholinergic drugs

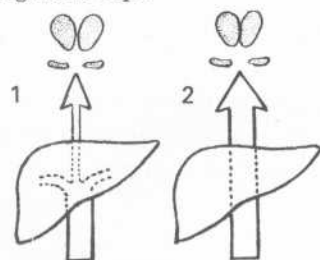
Synthetic anticholinergics, e.g. benzhexol – useful in control of tremor, but effect on rigidity and bradykinesia is often minimal.

Side effects: dry mouth, blurred vision, urinary retention and confusion.

2. Increase dopamine



Exogenous dopa



Given as 1 — levodopa, or 2 — levodopa + decarboxylase inhibitor, which prevents peripheral breakdown in the liver allowing a higher concentration of dopa to reach the blood-brain barrier; also the peripheral side effects (nausea, vomiting, hypotension) are diminished.

Central side effects: confusion, depression, dyskinetic movements and following long-term treatment – 'On/Off' phenomenon (see later).

Controlled-release or long acting preparations produce constant plasma levels and a more even clinical response.

Exogenous dopa improves bradykinesia, rigidity and, to a lesser extent, tremor, but in 20% the response is poor. 'Good' responders often develop central side effects later – especially the 'on/off' phenomenon.

PARKINSON'S DISEASE

TREATMENT (contd)

Dopamine agonists: When levodopa responsiveness is lost dopamine agonists are used.

Bromocriptine is a D_2 agonist with mixed agonist and antagonist effects at D_1 receptors.

Lisuride and *Pergolide* are more potent and act mainly at D_2 receptors. *Apomorphine* is an agonist at both D_1 and D_2 receptors given by continuous infusion or intermittent injection and is effective in shortening periods of prolonged immobility (freezing).

Dopamine agonists may produce postural hypotension and confusion.

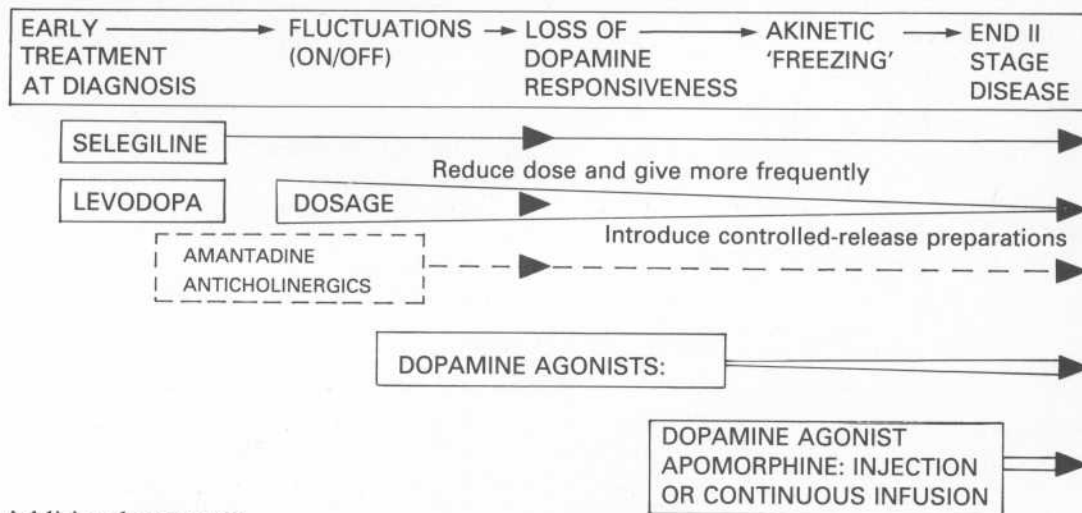
Selegiline: the enzymes monoamine oxidase (MAO) A and B play a key role in the breakdown of dopamine. This drug is an MAO-B inhibitor. Its usage results in increased dopamine levels. A recent randomised study has suggested a neuroprotective as well as symptomatic effect.

Amantidine, an antiviral drug, may help rigidity. The mode of action is not known.

Advances in drug treatment in recent years have reduced the need for **stereotactic surgery** (see page 370), but in patients with intractable tremor this is still of benefit. A stereotactic lesion is made in the globus pallidus or ventrolateral nucleus of the thalamus (contralateral to the tremor). Pallidotomy relieves contralateral dyskinesia.

Human fetal and medullary transplantation: experimental evidence shows that transplantation to the striatum of tissue capable of synthesising and releasing dopamine reverses the motor symptoms of Parkinson's disease. Despite much publicity, this treatment remains experimental.

Regime of Treatment (Drug therapy becomes more complex as disease progresses)



Additional measures

Nausea: ————— domperidone (peripheral dopamine antagonist)

Hypotension: ————— tilt bed head, elastic stockings + mineralocorticoid

Peak dose dyskinesia: ————— lower levodopa dose

End dose dyskinesia: ————— add dopamine agonist

Nocturnal pain/immobility: — add controlled-release levodopa at night

Confusion/aggravated ————— add clozapine (cortical dopamine antagonist)

dementia: if no help reduce levodopa and/or dopamine agonist

CHOREA

An involuntary, irregular, jerking movement affecting limb and axial muscle groups. These movements are suppressed with difficulty and are incorporated into voluntary gestures resulting in a 'semipurposful' appearance, e.g. crossing and uncrossing of legs.

Causes of chorea

- | | |
|------------------------------------|-----------------------------------------------|
| Hereditary: – Huntington's disease | Metabolic: – Hyperthyroidism |
| – Benign chorea | – Hypocalcaemia |
| Drugs: – Antiparkinsonian drugs | Immunological: – Systemic lupus erythematosus |
| – oral contraceptives | – Polyarteritis nodosa |
| Toxins: – alcohol | Miscellaneous: – Chorea gravidarum |
| – carbon monoxide poisoning | – Polycythaemia rubia vera |
| Infections: – Sydenham's chorea | |
| – encephalitis | |

HUNTINGTON'S DISEASE

This is an autosomal dominant disorder with onset in middle life and progression to death within 10 – 12 years. Parents of either sex can transmit and penetrance is complete.

It may occur in young persons (juvenile form); here chorea is less apparent and negative symptoms (rigidity) predominate.

Pathology

Neuronal loss in the striatum is associated with a reduction in projections to other basal ganglia structures. In addition, cells of the deep layers of the frontal and parietal cortex are lost (corticostriatal projections). The neurochemical basis of this disorder involves deficiency of gamma aminobutyric acid (GABA) and acetylcholine with reduced activity of enzymes glutamic acid decarboxylase (GAD) and choline acetyltransferase (CAT).

Symptoms and signs

Chorea – may be the initial symptom. This progresses from mere fidgetiness to gross involuntary movements which interrupt voluntary movement and make feeding and walking impossible.

Dementia – this is of a subcortical type (see page 122).

Behavioural disturbance – personality change, affective disorders and psychosis occur.

Hypotonicity often accompanies fidgety, choreiform movements.

Primitive reflexes – grasp, pout and palmomental – are usually elicited. Eye movements are disturbed with impersistence of gaze.

Diagnosis

On clinical grounds with a family history (although true parents may be unknown, or knowledge of illness suppressed). Distinguish from benign hereditary chorea in which intellect is preserved. Exclude senile chorea by older age of onset and absence of dementia. CT scanning may demonstrate atrophy of the caudate nucleus. MRI shows an increase in the T₂ signal in the caudate nucleus.

Prediction of disease

The Huntington mutation is a tribucleotide repeat on chromosome 4. Identifying this locus provides a reliable method of detecting the disease. Presymptomatic testing is now available in many centres. These tests raise ethical issues but also the possibility of early neuroprotective therapy (NMDA receptor antagonists).

Treatment Phenothiazines, haloperidol or tetrabenazine, may control the movements in the preliminary stages.

CHOREA

SYDENHAM'S CHOREA

Acute onset. Associated with streptococcal infection. Remits in weeks.

Pathology: Necrotising arteritis in thalamus, caudate nucleus and putamen.

Diagnosis is confirmed by elevated ESR and ASO (antistreptolysin) titre.

Treatment: Sedation, phenothiazines.

The condition may become recurrent – during pregnancy, intercurrent infection.

CHOREA GRAVIDARUM

Acute onset in pregnancy, usually the first trimester.

Restricted to face or generalised. Perhaps caused by reactivation of Sydenham's chorea.

Pathology: Unknown.

Treatment: Haloperidol.

Benign Chorea

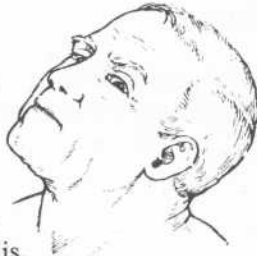Dominant inheritance with incomplete penetration.

Onset in childhood

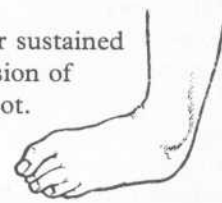
The movements are mild, occasionally aggravated by physical exercise and only rarely progressive.

DYSTONIA

Dystonia manifests as a sustained abnormal posture produced by contraction of large trunk and limb muscles, e.g. sustained head retraction . . .



. . . or sustained inversion of the foot.



Dystonias may be:

generalised – idiopathic torsion dystonia, or *partial* (focal), e.g. spasmodic torticollis.

The precise neuropathological basis of dystonia is uncertain. Vascular and traumatic lesions of the putamen occasionally produce this movement disorder.

IDIOPATHIC TORSION DYSTONIA (DYSTONIA MUSCULORUM DEFORMANS)

Onset in childhood. Sporadic or dominant inheritance. Recent genetic linkage studies have localised dominantly inherited disease to chromosome 9.

Initially, a flexion deformity of leg develops when walking.

Movements then become generalised with abnormal posturing of head, trunk and limbs. They are initially intermittent but ultimately constant. Despite eventual gross contortion the postures disappear during sleep.

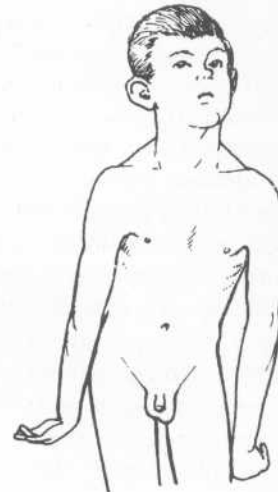
Diagnosis is made on clinical grounds and by exclusion of other disorders.

– EMG studies show inappropriate co-contraction of antagonistic muscle groups.

Pathology: No known pathological substrate.

Treatment: levodopa or carbamezapine are of benefit in some patients; anticholinergics help in others. A small proportion are dramatically dopa-responsive.

Stereotactic surgery – a lesion in the region of the ventrolateral nucleus of the thalamus may reduce the dystonia in the contralateral limb.



DYSTONIAS – FOCAL & SEGMENTAL IDIOPATHIC

SPASMODIC TORTICOLLIS (Wry neck)



Unilateral deviation of the head.

Aetiology is unknown. Vestibular abnormalities occur on testing, but it is uncertain whether these cause torticollis or result from the abnormal head posture.

Dystonic contraction of the *left* sternomastoid produces head turning to the *right*.

Pressure of the index finger on the *right* side of the chin may turn the head back to the neutral position (*geste antagoniste*).

Turning of the head is specially noticeable when the patient is walking. Eventually hypertrophy of the sternomastoid occurs.

Pathology: unknown. **Diagnosis** is based on clinical findings.

Treatment: anticholinergics and phenothiazines produce some benefit in 50% of patients. Injection of *Botulinum* toxin into the sternomastoid muscle gives variable symptomatic relief though requires regular repetition.

(Operative techniques no longer performed).

Prognosis: Remission occurs in 20% of patients. Dystonia may spread into other muscle groups. In the long term, psychological disturbance often occurs.

WRITER'S CRAMP

Variable age of onset.

Muscles of the hand and forearm tighten on attempting to write and pain may occur in the forearm muscles.

Previously regarded as an 'occupational neurosis' but now classified as a partial dystonia.

May be a precursor of Parkinson's disease.

Treatment: Benzodiazepines and anticholinergics are of limited value.

OROMANDIBULAR DYSTONIA

Constant involuntary prolonged tight eye closure (blepharospasm) is associated with dystonia of mouth, tongue or jaw muscles (jaw clenching and tongue protrusion). Response to treatment is poor though phenothiazines should be tried. Section of the nerves to orbicularis oculi muscles will relieve blepharospasm. Botulinum toxin injection is also effective.

DRUG INDUCED DYSTONIA

Acute adoption of abnormal dystonic posture – usually head and neck or oculogyric crisis (upward deviation of eyes) – caused by phenothiazines, butyrophenones, e.g. haloperidol, metoclopramide.

Anticholinergics, e.g. benztropine for 24–48 hours helps symptoms settle.

LEVODOPA RESPONSIVE DYSTONIA

This disorder presents in childhood and generally involves the legs only. Falls are frequent and the response to levodopa is maintained over many years.

PROGRESSIVE SUPRANUCLEAR PALSY

A condition characterised by gaze palsies, extrapyramidal features, *axial dystonia* (truncal dystonia) and progressive pseudobulbar palsy. Onset in the 5th to 6th decade.

Aetiology: unknown.

Pathology: Neuronal loss is evident in periaqueductal grey matter, brain stem, nuclei, subthalamic nuclei and the superior colliculi.

Neurofibrillary tangles as seen in Alzheimer's disease are also found.

Signs: Downward eye movement is initially impaired followed by all other voluntary eye movement. Lid retraction is common. Pseudobulbar signs develop (see page 534).

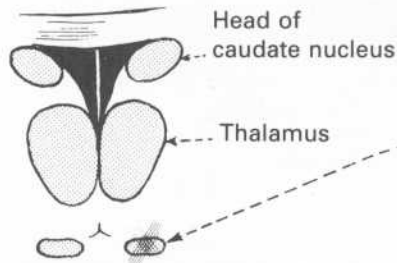
The head then hyperextends (dystonia) and rigidity ensues in the limbs.

Treatment: Levodopa and anticholinergics give disappointing results.

The course is relentless with progression and death in 2–5 years.

OTHER MOVEMENT DISORDERS

HEMIBALLISMUS



This is a movement disorder characterised by unilateral, violent flinging of the limbs. This involuntary movement is occasionally severe enough to throw the patient off balance or even from his bed.

The anatomical basis is a lesion of the *subthalamic nuclei* or its connections contralateral to the abnormal movement. It usually results from vascular disease (posterior cerebral artery territory), but occasionally occurs in multiple sclerosis.

Drug treatment is ineffective. The condition often settles spontaneously.

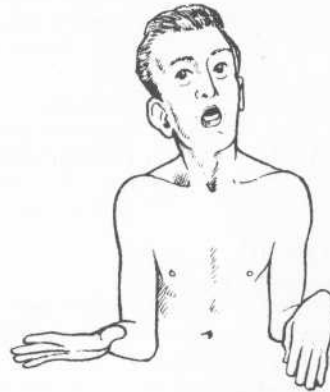ATHETOSIS

Athetosis presents in childhood and appears as a slow writhing movement disorder with a rate of movement between that of chorea and dystonia. It usually involves the digits, hands and face on each side.

These abnormal movements may result from:

- Hypoxic neonatal brain damage,
- Kernicterus,
- Lipid storage diseases.

Response to anticholinergics is variable and occasionally dramatic.



TARDIVE DYSKINESIA

This is a consequence of long-term treatment with neuroleptic drugs – phenothiazines, butyrophenones – and results from the development of drug-induced supersensitive dopamine receptors.

Involuntary movements in the face, mouth and tongue (orofacial dyskinesia) as well as limb movements of a *choreoathetoid nature* occur.

This movement disorder may commence even after stopping the responsible drug and can persist indefinitely.

Prevention

Incidence may be reduced by:

1. Drug 'holidays' (periods of rest from causal drug).
2. Early recognition and drug withdrawal.

The practice of increasing the dose of the offending drug when movements occur should be avoided. This will improve movements initially, but they will 'break through' later.

Treatment

Discontinue neuroleptic. If not possible, continue on lowest possible dose. Drugs which increase acetylcholine (Deanol), reduce catecholamine release (lithium), or deplete dopamine (reserpine) are variably effective.

TICS

Abrupt jerky movements affecting head, neck and trunk. Tics can be voluntarily suppressed and often take the form of winking, grimacing, shoulder shrugging, sniffing and throat clearing.

Gilles de la Tourette Syndrome is characterised by motor and vocal tics, copropraxia (making obscene gestures), coprolalia (obscene utterances) and obsessive behaviour. Onset is in childhood, males are more often affected and the condition may be inherited.

The neurotransmitter disturbance is unknown but patients respond to phenothiazines and clonidine.

OTHER MOVEMENT DISORDERS

MALIGNANT NEUROLEPTIC SYNDROME

A rare condition associated with prescribing dopamine antagonist and long-acting depot neuroleptic preparations. Drowsiness, fever, tremor and rigidity occur suddenly. Muscle necrosis (rhabdomyolysis) results in myoglobinuria and occasionally renal failure. Early identification and treatment with dopamine receptor agonists (bromocriptine) and muscle relaxants (sodium dantrolene) may be life saving.

WILSON'S DISEASE (hepatolenticular degeneration)

A rare autosomal recessive disorder of copper metabolism in which extrapyramidal features are evident. The gene abnormality has been located to chromosome 13.

Pathology

Cavitation and neuronal loss occurs within the putamen and the globus pallidus.

The liver shows the appearance of coarse cirrhosis.

Copper accumulates in all organs, especially in Descemet's membrane in the eye, nail beds and kidney.

Biochemistry

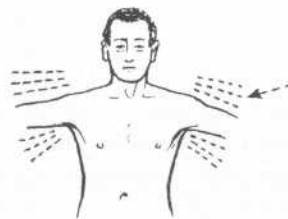There is deficiency of α_2 globulin – Ceruloplasmin – which normally binds 98% of copper in the plasma. This results in an increase in loosely bound copper/albumin, and deposition occurs in all organs. Urinary copper is increased.

Clinical features

There are two clinical forms:

1. *Acute* (Children)
 - Bradykinesia
 - Behavioural change
 - Involuntary movements
 - Liver involvement common

Untreated: death in 2 years from hepatic and renal failure



2. *Chronic* (Young adults)
 - Marked proximal 'wing beating' tremor
 - Dysarthria, dystonia and rigidity
 - Choreoathetoid movements
 - Psychosis, behavioural disorders and dementia
 - Liver involvement less severe

Untreated: death in 10 years

The deposition of copper in Descemet's membrane produces the golden brown *Kayser-Fleischer* ring, which when seen by naked eye or slit-lamp is diagnostic.

Diagnosis

Clinical findings supported by biochemical evidence:

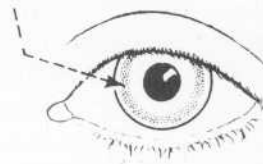
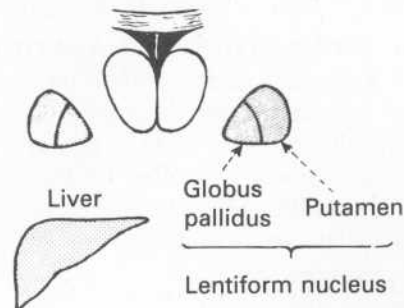
- Low ceruloplasmin (less than 20 mg/dl)
- Elevated unbound serum copper
- High urinary copper excretion
- Liver biopsy and copper metabolism tests with radioactive ^{64}Cu .
- MRI (T_2) shows thalamic and putaminal hyperintensity.

In families, biochemical tests will identify low ceruloplasmin in carriers and in presymptomatic patients. These relatives require appropriate genetic counselling and treatment when indicated.

Treatment

Low copper diet and a chelating agent, e.g. penicillamine 1–1.5g daily. Side effects such as anaphylaxis, skin rash, bone marrow suppression and glomerulonephritis are common in which case trientine is an effective alternative.

Therapy is necessary for the rest of the patient's life. Adequate treatment is compatible with normal life expectancy. Kayser-Fleischer rings will disappear with time.



HYDROCEPHALUS

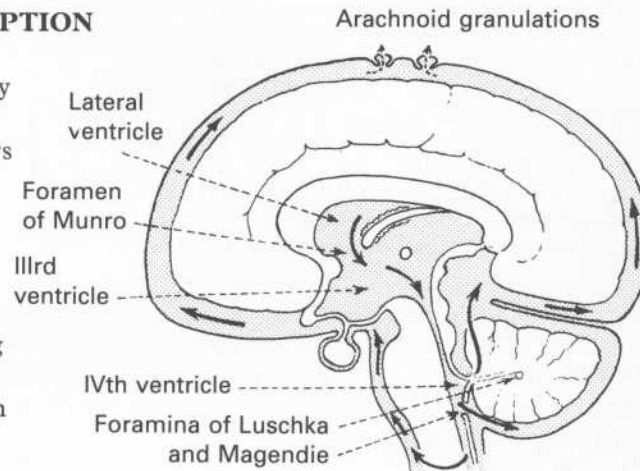
DEFINITION

Hydrocephalus is an increase in cerebrospinal fluid (CSF) volume, usually resulting from impaired absorption, rarely from excessive secretion.

This definition excludes ventricular expansion secondary to brain shrinkage from a diffuse atrophic process (hydrocephalus ex vacuo).

CSF FORMATION AND ABSORPTION

CSF forms at a rate of 500 ml/day (0.35 ml/min), secreted predominantly by the choroid plexus of the lateral, third and fourth ventricles. CSF flows in a caudal direction through the ventricular system and exits through the foramina of Luschka and Magendie into the subarachnoid space. After passing through the tentorial hiatus and over the hemispheric convexity, absorption occurs through the arachnoid granulations into the venous system.



CLASSIFICATION

'Obstructive' hydrocephalus – obstruction of CSF flow *within* the ventricular system.

'Communicating' hydrocephalus – obstruction to CSF flow *outwith* the ventricular system i.e. ventricular CSF 'communicates' with the subarachnoid space.

CAUSES OF HYDROCEPHALUS

Obstructive

- Acquired*
- Acquired aqueduct stenosis (adhesions following infection or haemorrhage)
 - Supratentorial masses causing tentorial herniation
 - Intraventricular haematoma
 - Tumours
 - ventricular, e.g. colloid cyst
 - pineal region
 - posterior fossa
 - Abscesses/granuloma
 - Arachnoid cysts
- Congenital*
- Aqueduct stenosis or forking
 - Dandy-Walker syndrome (atresia of foramina of Magendie and Luschka)
 - Chiari malformation
 - Vein of Galen aneurysm

Communicating

Thickening of the leptomeninges and/or involvement of the arachnoid granulations

- infection (pyogenic, TB, fungal)
- subarachnoid haemorrhage
 - spontaneous
 - trauma
 - postoperative
- carcinomatous meningitis

Increased CSF viscosity, e.g.

high protein content

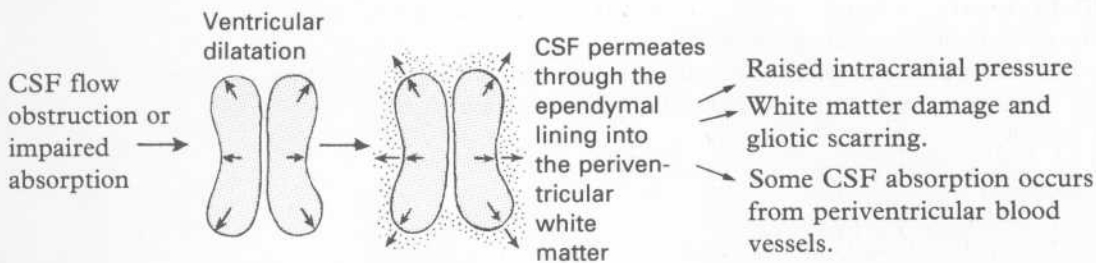
Excessive CSF production –

choroid plexus

papilloma (rare)

HYDROCEPHALUS

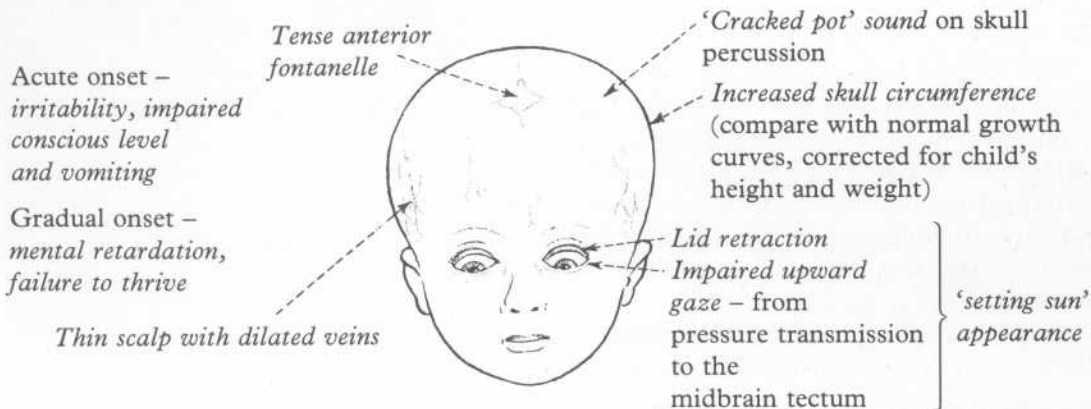
PATHOLOGICAL EFFECTS



In the infant, prior to suture fusion, head expansion and massive ventricular dilatation may occur, often leaving only a thin rim of cerebral 'mantle'. Untreated, death may result, but in many cases the hydrocephalus 'arrests'; although the ventricles remain dilated, intracranial pressure (ICP) returns to normal and CSF absorption appears to balance production. When hydrocephalus arrests, normal developmental patterns resume, although pre-existing mental or physical damage may leave a permanent handicap. In these patients, the rapid return of further pressure symptoms following a minor injury or infection suggests that the CSF dynamics remain in an unstable state.

CLINICAL FEATURES

Infants and young children



Juvenile/adult type hydrocephalus

Acute onset - signs and symptoms of \uparrow ICP - headache, vomiting, papilloedema.
- impaired upward gaze - deterioration of conscious level

Gradual onset - dementia
- gait ataxia
- incontinence

This triad of symptoms may occur despite an apparently 'normal' CSF pressure, i.e. NORMAL PRESSURE HYDROCEPHALUS (See page 126)

The condition often relates to previous trauma, meningitis or subarachnoid haemorrhage.

HYDROCEPHALUS

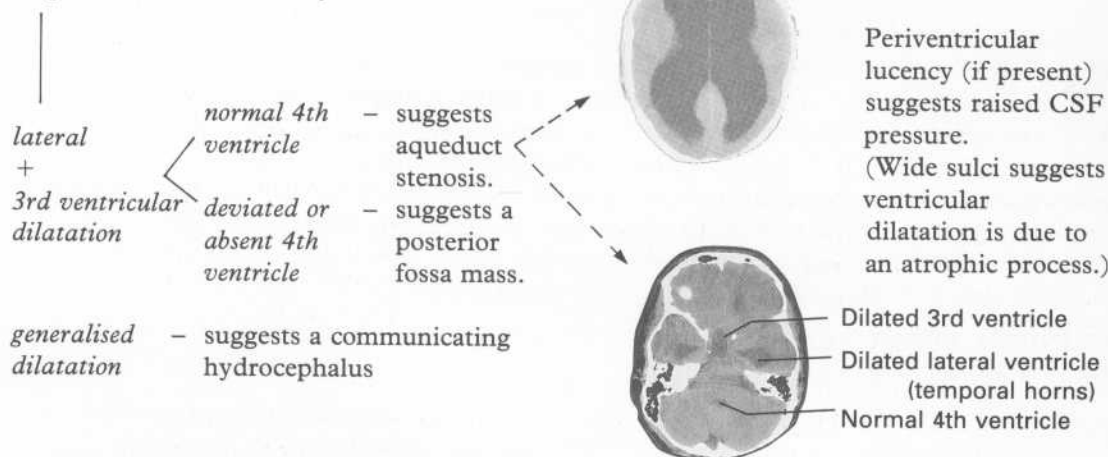
INVESTIGATIONS

Skull X-ray

- Note:
- skull size and suture width.
 - evidence of chronic raised pressure - erosion of the posterior clinoids.
 - associated defects - platybasia, basilar invagination.

CT scan

The *pattern of ventricular enlargement* helps determine the cause, i.e.



Ultrasonography through the anterior fontanelle, usefully demonstrates ventricular enlargement in infants but provides less precise information than CT scanning.

MRI shows similar ventricular expansion, but may more clearly demonstrate periventricular lucency or a neoplastic cause of the obstruction.

ICP monitoring: used to investigate patients with suspected normal pressure hydrocephalus and designed to predict the likelihood of a beneficial response to shunting (see page 127).

Developmental assessment and psychometric analysis detect impaired cerebral function and provide a baseline for future comparison.

MANAGEMENT

- Acute deterioration*
- ventricular drainage or
 - ventriculo-peritoneal (VP) (or ventriculoatrial (VA) shunt if peritoneal adhesions)
 - lumbar puncture - if communicating hydrocephalus, e.g. following subarachnoid haemorrhage.
- Gradual deterioration*
- VP shunt (lumboperitoneal shunts are occasionally used for communicating hydrocephalus).
 - removal of a mass lesion if present - this may obviate the need for a shunt.
- 'Arrested hydrocephalus' - symptomless ventricular dilatation requires no treatment, but regular developmental or psychometric assessment ensures no ill effects develop from this potentially unstable state.

HYDROCEPHALUS

Shunt techniques

A *reservoir* permits CSF aspiration for analysis.

A *valve* is incorporated in the system, with either

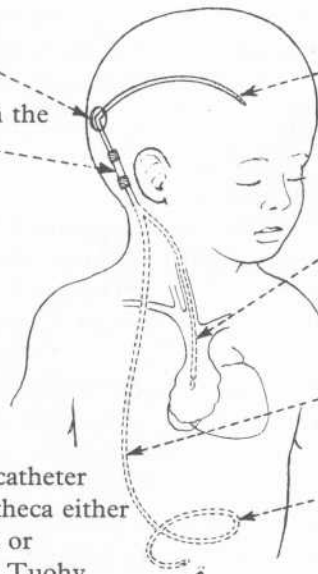
- fixed opening pressure
e.g. Heyer-Schulte, Hakim
- variable opening pressure (flow regulated) e.g. Orbis sigma, Delta
- programmable e.g. Medos, Sophy.

Valve opening

pressures range

from 5–150 mm H₂O

[*Lumboperitoneal shunt* – catheter inserted into the lumbar theca either directly at open operation or percutaneously through a Tuohy needle. The distal end is sited in the peritoneal cavity.]



A *ventricular catheter* is inserted through the occipital (or frontal) horn. The tip lies at the level of the foramen of Munro.

Ventriculoatrial shunt – distal catheter inserted through the internal jugular vein to the right atrium (T6/7 level on chest X-ray).

Silastic tubing tunnelled subcutaneously.

Ventriculoperitoneal shunt – distal catheter inserted into the peritoneal cavity. In children, redundant coils permit growth without revision.

Complications of shunting

Infection: results in meningitis, peritonitis or inflammation extending along the subcutaneous channel. In patients with a V-A shunt, bacteraemia may lead to shunt 'nephritis'. *Staphylococcus epidermidis* or *aureus* are usually involved, with infants at particular risk. Prophylactic antibiotics may minimise the risk of infection, but, when established, eradication usually requires shunt removal.

Subdural haematoma: ventricular collapse pulls the cortical surface from the dura and leaves a subdural CSF collection or tears bridging veins causing subdural haemorrhage. This risk may be reduced with a variable pressure or programmable valve.

Shunt obstruction: blockage of the shunt system with choroid plexus, debris, omentum or blood clot results in intermittent or persistent recurrence of symptoms and indicates the need for shunt revision. Demonstration of an increase in ventricular size compared to a previous baseline CT scan confirms shunt malfunction. Over a third require revision within 1 year and 80% within 10 years.

Low pressure state: following shunting, some patients develop headache and vomiting on sitting or standing. This low pressure state usually resolves with a high fluid intake and gradual mobilisation. If not, insertion of an antisyphon device or conversion to a high pressure valve is required.

Third Ventriculostomy: In patients with obstructive hydrocephalus, creating a hole in the floor of the third ventricle via a flexible or rigid endoscope, provides an alternative method of treatment which, if successful, avoids the problem of shunt obstruction, infection and over drainage.

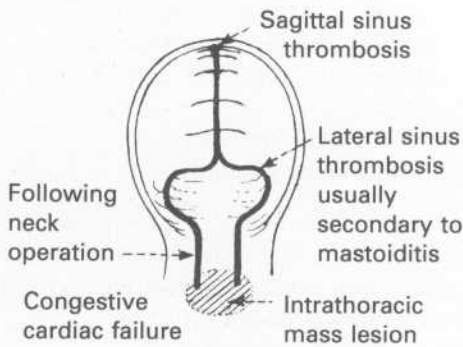
Prognosis: Provided treatment precedes irreversible brain damage, results are good with most children attaining normal IQs. Repeated complications, however, particularly prevalent in infancy and in young children carry a significant morbidity.

BENIGN INTRACRANIAL HYPERTENSION

Benign intracranial hypertension (pseudotumour cerebri) is a term applied to patients with raised intracranial pressure and no evidence of any 'mass' lesion or of hydrocephalus.

AETIOLOGY: This condition is related to a variety of clinical disorders:

Most demonstrate a direct causal link –
VENOUS OUTFLOW OBSTRUCTION TO CSF ABSORPTION



In the minority, the causal link remains obscure, but a variety of factors are associated –

DIET – obesity.

– hyper/hypovitaminosis A.

ENDOCRINE – pregnancy, menarche, menstrual irregularities, Addison's disease.

HAEMATOLOGICAL – iron deficiency anaemia.
 – polycythaemia vera.

DRUGS – oral contraceptives.

– steroid withdrawal.

– tetracycline.

– nalidixic acid.

Various mechanisms have been postulated.

– BRAIN SWELLING

– ↓ CSF ABSORPTION

– ↑ CSF SECRETION

} Different studies support different mechanisms. The link with obesity suggests an underlying endocrine basis, but, except in Addison's disease, endocrine assessment has failed to reveal abnormalities.

CLINICAL FEATURES

Age: any age, but usually in 3rd and 4th decades.

Sex: female > male – especially in the idiopathic group.

Symptoms

Headache

Visual obscurations

Impaired visual acuity

Diplopia

In women the condition is often associated with – recent weight gain, fluid retention, menstrual dysfunction, the first trimester of pregnancy and the postpartum period.

Signs

Obesity

Papilloedema

VI nerve palsy

Investigations

CT scan – ventricles usually small.

Visual field charting –

{ Enlarged blind spot (often used to monitor progress).

{ Peripheral field constriction.

Lumbar puncture and pressure measurement.

ICP monitoring – if diagnostic doubt persists.

MR Venogram – will identify a sinus thrombosis (see page 41)

TREATMENT

Treat the underlying cause if known.

Weight reduction diet.

Drugs – acetazolamide (reduces CSF production).

– thiazide diuretics.

If above fail → *lumboperitoneal shunt.*

Optic nerve sheath fenestration – if progressive impairment of visual acuity despite treatment.

PROGNOSIS

Most patients respond rapidly to

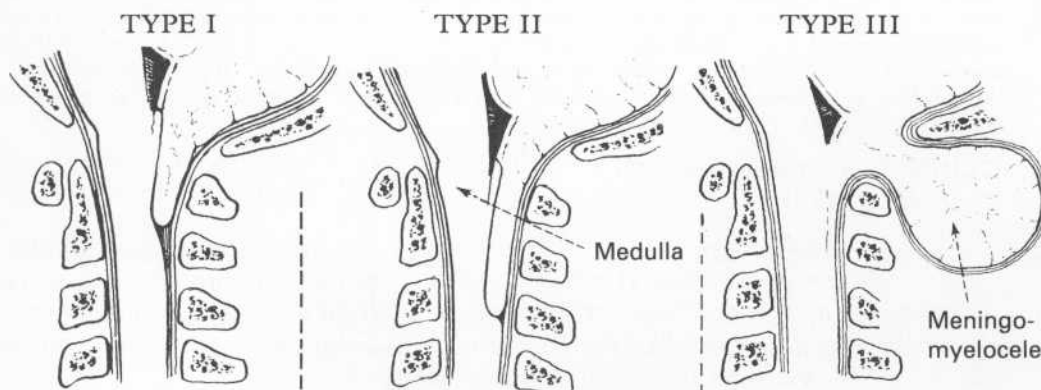
short-term treatment, but up to

one-third develop recurrent attacks.

In 10% visual impairment persists.

CHIARI MALFORMATION

Although the names of two authors (Arnold and Chiari) were originally linked to the description of malformations at the medullary-spinal junction, Chiari must take most credit for providing a detailed description of this condition.



The cerebellar *tonsils* lie below the level of the foramen magnum (cerebellar ectopia). This may not produce symptoms.

Associated conditions

(in symptomatic patients):

Spinal

Syringomyelia } (50%)
Hydromyelia }

Cranial

Hydrocephalus (10%)
(occurs less often than Chiari originally described)

Part of the cerebellar *vermis*, medulla and 4th ventricle extend through the foramen magnum, often to the midcervical region. The lower cranial nerves are stretched and the cervical nerve roots run horizontally or in an upward direction.

Spinal

Syringomyelia } (90%)
Hydromyelia }

Spina bifida – meningo-myelocele, diastomatomyelia
Cervical fusion (Klippel-Feil)

Cranial

Hydrocephalus (85%)
Aqueduct stenosis and forking
Small posterior fossa
Basilar impression
Fusion of both thalami
Fusion of the superior and inferior colliculi
Microgyria
Hypoplastic tentorium cerebelli and falx
Skull lacuniae – vault thinned or defective

Others

Developmental anomalies of the cardiovascular, gastrointestinal and genitourinary systems in 10%

Part of the cerebellum and medulla lie within a cervico-occipital meningo-myelocele.

[TYPE IV

Cerebellar hypoplasia – best considered as a separate entity.]

CHIARI MALFORMATION

PATHOGENESIS

Several hypotheses have been proposed to explain the pathological findings of these malformations. Gardner suggested that downward pressure from *hydrocephalus* played an important role in displacing the posterior fossa structures and, when associated with a patent central canal, explained the high incidence of syringomyelia (page 387). Others supposed that *traction* from a tethered spinal cord (dysraphism), or a *CSF leak* through a myelocele into the amniotic sac in fetal life resulted in caudal displacement of the posterior fossa structures. Of these theories, none provides an entirely satisfactory explanation; a more realistic view attributes the hindbrain deformity to *maldevelopment* during early fetal life. This would explain the presence of other developmental anomalies.

CLINICAL PRESENTATION

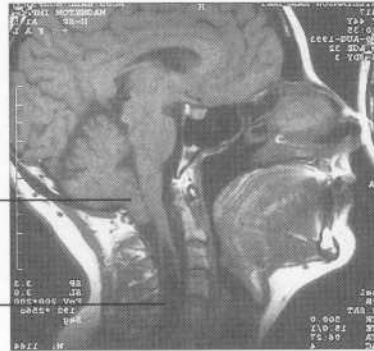
Depends on age

INFANCY	}	Severe type II (or III) deformities present with <i>respiratory difficulties</i> and <i>lower cranial nerve palsies</i> . Death may result from <i>aspiration pneumonia</i> or <i>apnoeic attacks</i> , or from complications of associated malformations, e.g. <i>spina bifida</i> . In milder forms, <i>nystagmus</i> (horizontal), <i>retrocollis</i> (neck extension) and <i>spasticity</i> predominate.					
CHILDHOOD	}	With increasing age, <i>gait ataxia</i> may become evident. Features of an associated syringomyelia – <i>dissociated sensory loss</i> and <i>spastic quadraparesis</i> often contribute to the clinical problems.					
ADULT	}	<p>Only patients with a type I or a mild type II deformity present in adult life –</p> <p><i>Occipital headaches</i> are induced by coughing or straining</p> <table border="0" style="display: inline-table; vertical-align: middle;"> <tr> <td style="vertical-align: middle;">Nystagmus – downbeat (on looking down)</td> <td style="vertical-align: middle;">or</td> <td style="vertical-align: middle;">rotatory (on lateral gaze)</td> <td style="font-size: 3em; vertical-align: middle;">}</td> <td style="vertical-align: middle;">may result from medullary compression or from an associated syringomyelia (see page 387).</td> </tr> </table> <p><i>Ataxia</i> <i>Spastic quadraparesis</i> Progression may eventually lead to severe bulbar symptoms – <i>lower cranial nerve palsies, respiratory difficulties</i>.</p>	Nystagmus – downbeat (on looking down)	or	rotatory (on lateral gaze)	}	may result from medullary compression or from an associated syringomyelia (see page 387).
Nystagmus – downbeat (on looking down)	or	rotatory (on lateral gaze)	}	may result from medullary compression or from an associated syringomyelia (see page 387).			

INVESTIGATIONS

Magnetic resonance imaging (MRI) is the investigation of choice. T1 weighted sagittal and axial scans most clearly demonstrate cerebellar ectopia and the presence or absence of an associated syringomyelia.

Chiari malformation
(with associated syringomyelia)

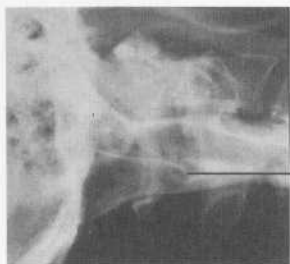


CHIARI MALFORMATION

Investigation (contd)

- Straight X-rays**
- Skull: note the presence of platybasia, basilar impression or lacunae (vault defects).
 - Cervical spine: note increased canal width or fusion of vertebrae (especially C2,3) – Klippel-Feil syndrome.
 - Lumbosacral spine: note any associated spina bifida.

Myelography (if MRI unavailable)



CT scan: difficult to interpret at the cervico-medullary junction, but shows soft tissue filling the spinal canal at this level.

Contrast run up to the foramen magnum with the patient in the supine position outlines a posteriorly situated filling defect.

MANAGEMENT (see also syringomyelia, page 387)

In patients with hydrocephalus and signs and symptoms of raised intracranial pressure. → *Ventriculoperitoneal or atrial shunt* may significantly improve signs and symptoms attributed to the Chiari malformation.

In patients with other symptoms and signs → *Posterior fossa decompression* – by removing the posterior rim of the foramen magnum and the arch of the atlas. The dura is opened and a dural graft inserted. Attempts at freeing tonsillar adhesions should be resisted. An apnoea monitor in the initial postoperative period helps detect potentially fatal apnoea, especially during sleep. In some instances, patients with minimal symptoms or with no evidence of progression may warrant a conservative approach.

PROGNOSIS

Patients with mild symptoms and signs often respond well to operation, but those with long-standing neurological deficits rarely improve. Treatment should aim at preventing further progression.

Further deterioration eventually occurs in one-third, despite operative measures.

SYRINGOBULBIA

Extension of a syringomyelic cavity upwards into the medulla may produce signs and symptoms which are difficult to distinguish from those of medullary compression in the Arnold-Chiari syndrome:

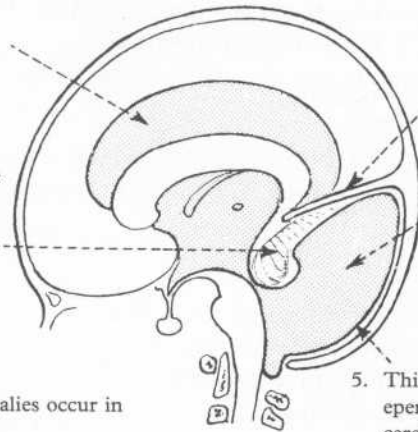
- difficulty in swallowing, dysphonia, dysarthria, vertigo, facial pain
- nystagmus, palatal and vocal cord weakness, occasional facial and tongue weakness.

DANDY-WALKER SYNDROME

This rare developmental anomaly comprises:

1. Dilatation of the lateral and third ventricles (but to a lesser extent than the fourth ventricle)

2. Widely separated, hypoplastic cerebellar hemispheres, with a small hypoplastic vermis, displaced rostrally.



3. Enlarged posterior fossa with high tentorium cerebelli and transverse sinuses.

4. Cystic dilatation of the 4th ventricle – usually related to congenital absence of the foramina of Luschka and Magendie.

5. Thin, transparent membrane containing ependymal cells and occasionally cerebellar tissue.

Other developmental anomalies occur in 65% of patients.

CLINICAL PRESENTATION

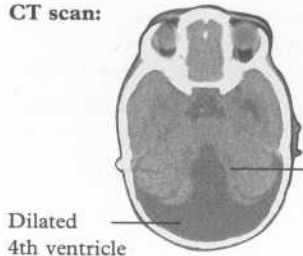
Infancy: Symptoms and signs of hydrocephalus (page 361) combined with a prominent occiput.

Childhood: Signs of cerebellar dysfunction with or without signs of hydrocephalus.

INVESTIGATIONS

Skull X-ray: Usually shows elevation of the transverse sinuses and occipital bulging, confirming the presence of an enlarged posterior fossa.

CT scan:



Confirms dilatation of the 4th ventricle with lateral displacement of hypoplastic cerebellar tissue.

Differentiate from:

- Midline arachnoid cyst
 - Enlarged cisterna magna
- } distinguish from Dandy-Walker by identifying cerebellar tissue or septum between the cyst and the 4th ventricle

Dilated 4th ventricle

MANAGEMENT

Excision of the cyst membrane, 'marsupialising' the 4th ventricle.

Alternatively, and more simply, cystoperitoneal shunt.

PROGNOSIS

Marked neurological impairment prior to treatment carries a poor outlook. In less impaired patients, the prognosis relates more to the presence of other developmental anomalies.

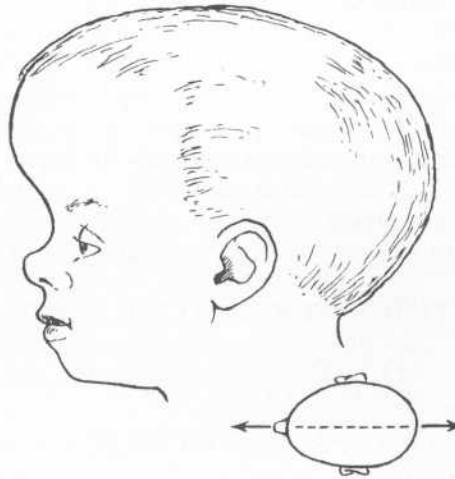
CRANIOSYNOSTOSIS

In normal childhood development, the cranial sutures allow skull enlargement as the brain grows. *Premature fusion of one or more sutures* results in restricted growth of bone alongside the suture and excessive compensatory growth at the non-united joints. The effect depends on the site and number of sutures involved. Sagittal synostosis is the most frequently occurring deformity.

SAGITTAL SYNOSTOSIS

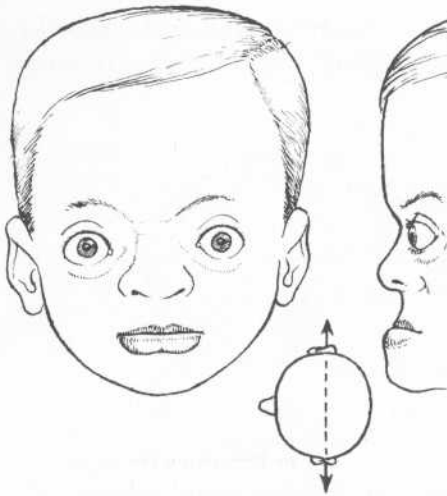
Lateral growth is restricted, resulting in a long narrow head with ridging sagittal suture (scaphocephaly).

Treatment: by wide excision of the sagittal suture.



CORONAL SYNOSTOSIS

Bilateral or unilateral.



Expansion occurs in a superior and lateral direction (brachiocephaly). This produces a short anterior fossa, shallow orbits and hypertelorism (widening of the interocular distance). Exophthalmos, elevated ICP and visual impairment from papilloedema may result. Bilateral coronal synostosis commonly occurs as one of several congenital defects incorporated in *Crouzon's* and *Apert's syndromes*.

Involvement of several sutures (oxycephaly) results in skull expansion towards the vertex, the line of least resistance.

PANSYNOSTOSIS (all sutures affected) results in failure of skull growth with a symmetrical abnormally small head and raised intracranial pressure. It is important to distinguish this from microcephaly due to inadequate primary brain development.

Treatment of coronal, metopic and pansynostosis involves extensive craniofacial surgery correcting both cranial and orbital deformities.

Indication for operative treatment is primarily cosmetic when only one suture is involved, but with involvement of two or more sutures operation is also aimed at prevention of visual and cerebral damage from raised ICP.

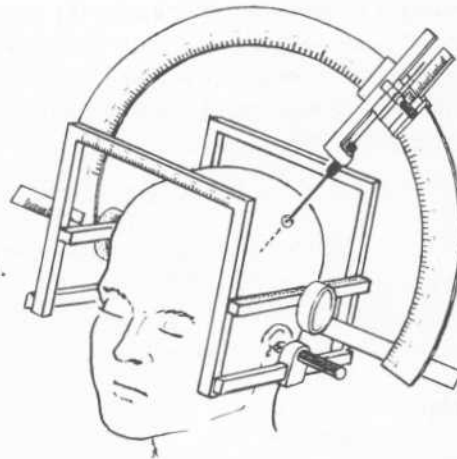
Posterior Plagiocephaly (flattening of the back of the head)

An increasing number of infants present with this condition. This is rarely due to a true lambdoid synostosis but it is thought to be an acquired 'locked suture syndrome' with secondary fusion following posterior moulding. Only those who develop a progressive skull deformity require surgical treatment.

STEREOTACTIC SURGERY

Stereotactic techniques developed initially for lesion making, enable accurate placement of a cannula or electrode at a predetermined target site within the brain with the least risk.

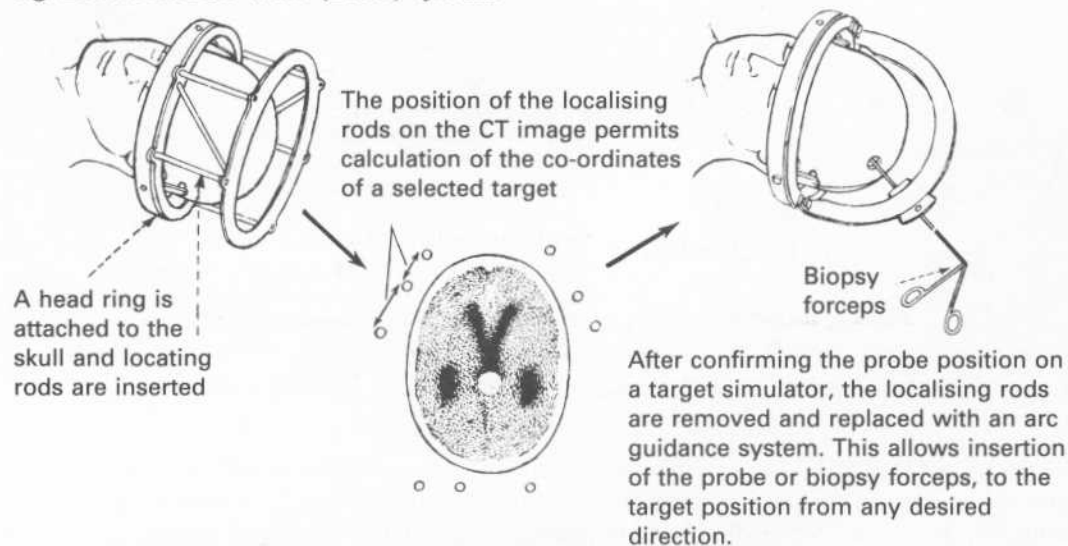
Many different stereotactic frames have been developed, e.g. Leksell, Todd-Wells, Guiot. These, combined with radiological landmarks (usually ventriculography) and a brain atlas, provide anatomical localisation to within ± 1 mm. Since some functional variability occurs at each anatomical site, electrode localisation is also based on the recorded neuronal activity and on the effects of electrical stimulation.



CT/MRI STEREOTACTIC SYSTEM

CT and MRI compatible stereotactic systems allow cannula insertion to any point selected on the image. They are all based on the concept of identifiable external reference (fiducial) markers,

e.g. Brown-Robert-Wells (BRW) system:



CT/MRI stereosurgery provides the optimal method for the biopsy or aspiration of *small, deeply situated tumours* or *abscesses*. Many now use stereotactic biopsy, for larger tumours. It carries lower risk than handheld biopsy and allows selection of specific areas within the tumour. Functional stereotaxy e.g. thalamotomy, pallidotomy, still requires electrical stimulation for the final localisation.

When combined with craniotomy it permits direct macroscopic examination of a lesion and may aid localisation, e.g. a small arteriovenous malformation. The improved resolution now available with CT/MRI scanning has led to sufficient anatomical localisation for accurate lesion making, obviating the need for ventriculography.

STEREOTACTIC SURGERY

METHODS OF LESION MAKING

- | | | |
|------------------|---------------------------------------------------------------------------------------------------------------------------------------------------------------------------------------------|--------------------------------------------------------------------------|
| <i>Heat</i> | - radiofrequency current delivered through a fine electrode | } lesion size
determined by
temperature
change and
duration. |
| <i>Cooling</i> | - with a cryogenic probe | |
| <i>Radiation</i> | - implantation of radioactive seed, e.g. yttrium ⁹⁰
- focussed beam from cobalt ⁶⁰ rods (sited on a specially adapted Leksell frame) or from a linear accelerator. | |

USES OF STEREOTACTIC SURGERY

Movement disorders

- tremor
- dystonia
- spasmodic torticollis
- spasticity - lesion in dentate nucleus or pulvinar.
- dyskinesia - lesion in globus pallidus

lesions in
thalamic
nuclei

Pain - especially intractable head or neck pain in malignancy.

- Lesion in centromedian nucleus of the thalamus and intralaminar nuclei, or descending tract of the trigeminal nucleus.

LESION-MAKING

Psychosurgery

- Obsessive and compulsive illness
- Intractable depression

Bilateral cingulotomy.
Subcaudate tractotomy

STIMULATION

Movement disorders

- spasticity - cerebellar stimulation
- tremor - thalamic stimulation

Pain - intractable pain, unresponsive to other measures

stimulation of the thalamic relay nuclei, internal capsule, periaqueductal or periventricular grey matter

ASPIRATION → cyst, abscess, or haematoma

BIOPSY → particularly for small and deeply situated tumours

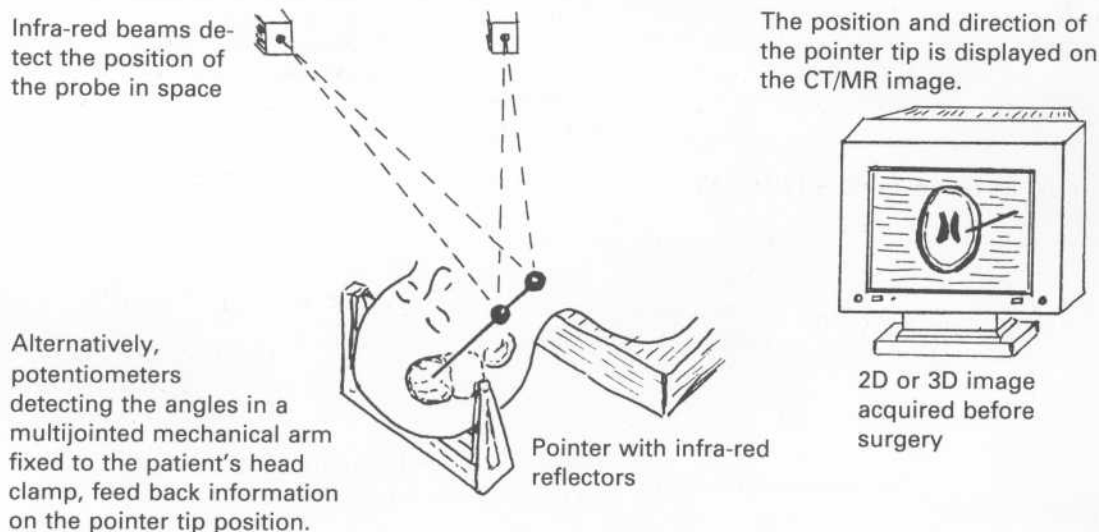
IRRADIATION → implantation of radioactive seeds, e.g. craniopharyngioma
external stereotactic irradiation appears useful in the treatment of small deep arteriovenous malformations

IMAGE GUIDED 'FRAMELESS' STEREOTAXY

Although craniotomy with conventional stereotaxy is feasible, in practice the cumbersome frame, combined with the aiming device, tend to obstruct the operating field. The need for a simultaneous CT or MRI with the head ring and locating rods in place leads to a further inconvenience.

The combination of modern imaging, elaborate computer software and a locating device now permit the surgeon to determine how the tip of a pointer outwith or within the skull, directly relates to a two or even three dimensional CT or MR image.

The accuracy of the technique depends on the quality of the digitised image and on the method used to register the patient's head to the image. The registration of recognisable skin points (e.g. nasion, inner canthus, ears) on the patient to the CT/MR image provides an accuracy of 2-3 mm and this is sufficient for most purposes.



Uses of 'frameless' stereotaxy

Aids accurate positioning of burrholes and bone flap, and the planning of the safest approach to the lesion.

TUMOURS

- biopsy
- resection: locates, then identifies the tumour margins and the position of important adjacent structures
- brachytherapy (see page 304)

ARTERIOVENOUS MALFORMATION

- localisation of lesion and the feeding vessels

ABSCCESS

- aspiration

EPILEPSY

- defining the extent of resected tissue e.g. amygdalohippocampectomy
- placement of depth electrodes

ORBIT

- location of intraorbital lesion

PSYCHOSURGERY

In 1935, observation of behavioural changes in chimpanzees following bilateral ablation of the frontal association area, led to the introduction of lesion-making for psychiatric disease (Moniz). The operation of *prefrontal leucotomy* was perfected and used on patients with a wide variety of problems. In Britain, between 1940 – 1955, neurosurgeons performed over 10 000 operations. It became evident that patients with affective problems – depression, anxiety and obsessional neurosis – showed better results than those with schizophrenia.

As a consequence of the introduction of *chlorpromazine* in the 1950s, and the operative complications and results – perhaps limited by poor case selection, prefrontal leucotomy fell into disrepute. The need for a surgical procedure persisted, however, in those patients where drugs had little effect. Despite pharmacological improvements, some patients developed chronically disabling conditions requiring continual hospital care; in others with acute depressive illness, the suicide rate was high.

Stereotactic surgery provided a method of lesion-making which was virtually risk free and this is now generally accepted as a suitable treatment in *selected patients where drug treatment has failed*. Issues of 'informed consent' for such procedures in the mentally ill are often ethically difficult.

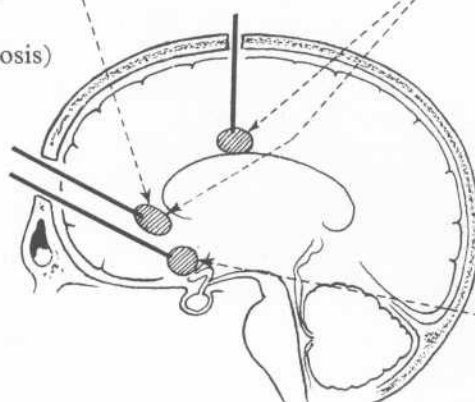
INDICATIONS FOR STEREOTACTIC SURGERY AND LESION SITE

SUBCAUDATE TRACTOTOMY

- endogenous depression
- chronic anxiety states or phobias (e.g. obsessional neurosis)

LIMBIC LEUCOTOMY

- (smaller subcaudate and cingulate lesions)
- obsessional neurosis



AMYGDALOTOMY

- severe, uncontrolled aggression related to psychiatric or neurological illness.

Results

- Depression/anxiety states – up to two-thirds benefit from subcaudate tractotomy.
- Obsessional neurosis – 80% improve following limbic leucotomy.

**LOCALISED NEUROLOGICAL DISEASE
AND ITS MANAGEMENT
B. SPINAL CORD AND ROOTS**

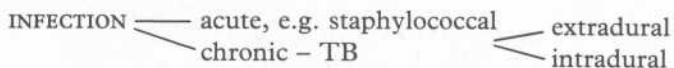
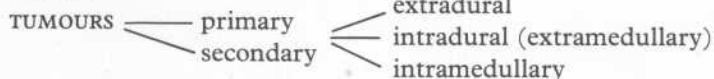SPINAL CORD AND ROOTS

Disorders localised to the spinal cord or nerve roots are detailed below, but note that many diffuse neurological disease processes also affect the cord (see Section V, e.g. multiple sclerosis, Friedreich's ataxia).

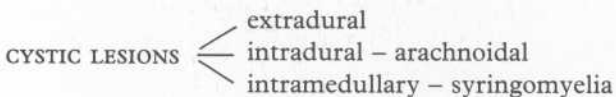
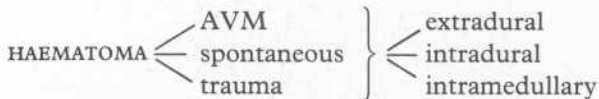
SPINAL CORD AND ROOT COMPRESSION

As the spinal canal is a rigidly enclosed cavity, an expanding disease process will eventually cause cord and/or root compression.

Causes



DISC DISEASE AND SPONDYLOSIS



Manifestations of cord or root compression depend upon the following:

Site of lesion within the spinal canal:

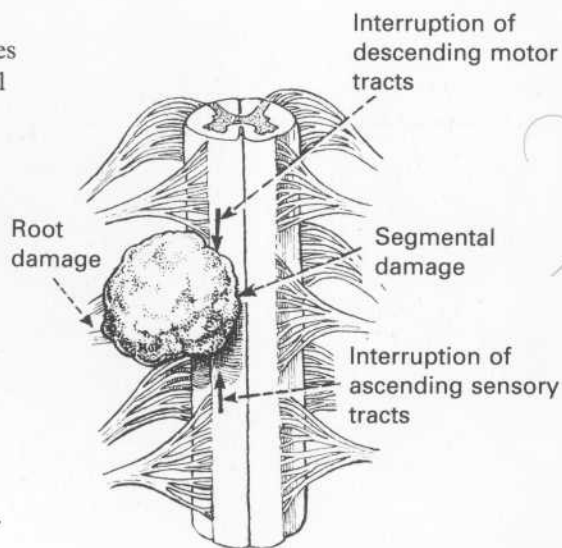
an expanding lesion outside the cord produces signs and symptoms from root and segmental damage.

ROOT - lower motor neuron (l.m.n.) and sensory impairment appropriate to the distribution of the damaged root.

SEGMENTAL → l.m.n. and sensory impairment appropriate to segmental level.

Interruption of ascending sensory and descending motor tracts produces sensory impairment and an upper motor neuron (u.m.n.) deficit below the level of the lesion.

Lesions within the cord (intramedullary) produce only segmental signs and symptoms.

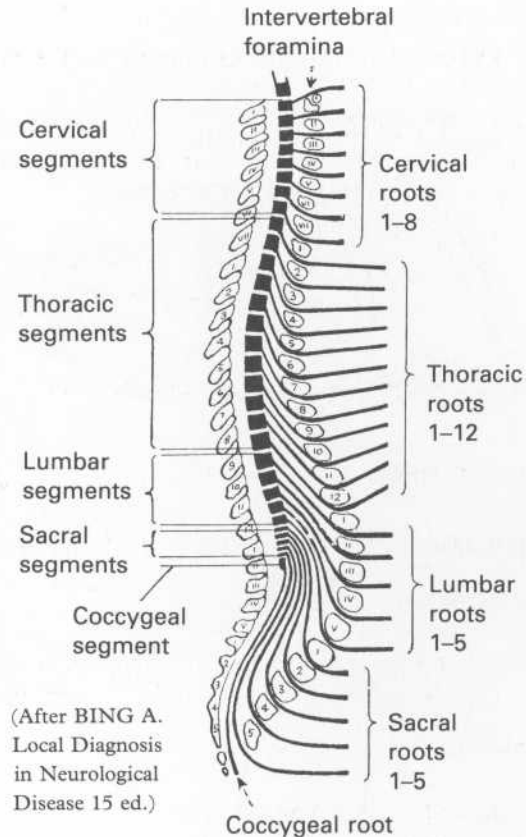


SPINAL CORD AND ROOT COMPRESSION

Level of the lesion: a lesion above the L1 vertebral body may damage both the cord and its roots. Below this, only roots are damaged.

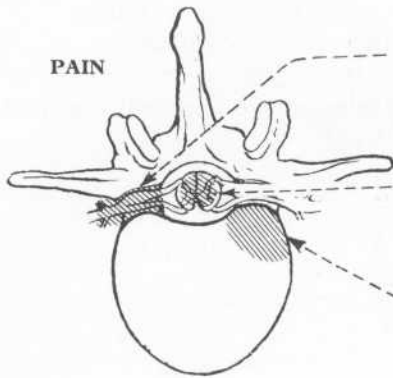
Vascular involvement: whether neuronal damage results from mechanical stretching or is secondary to arterial ischaemia or venous obstruction remains uncertain. On occasions, clinical findings indicate cord damage well beyond the level of the compressive lesion; this implies a distant ischaemic effect due to blood vessel compression at the lesion site.

Speed of onset: speed of compression affects the clinical picture. Despite producing upper motor neuron damage, a rapidly progressive cord lesion often produces a 'flaccid paralysis' with loss of reflexes and absent plantar responses. This state is akin to 'spinal shock' seen following trauma. Several days or weeks may elapse before tone returns accompanied by the expected 'upper motor neuron' signs.



Clinical features

These depend on the site and level of the compressive lesion.



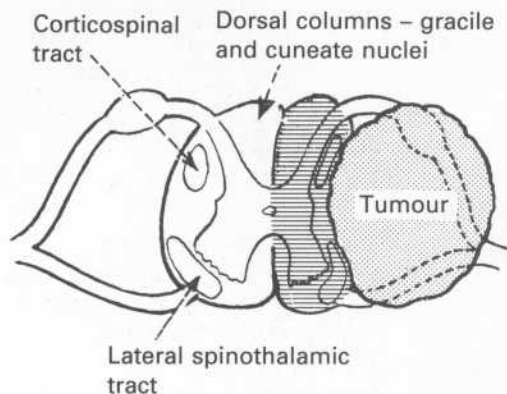
ROOT – severe, sharp, shooting, burning pain radiating into the cutaneous distribution or muscle group supplied by the root; aggravated by movement, straining or coughing.

SEGMENTAL – continuous, deep aching pain radiating into whole leg or one half of body; not affected by movement.

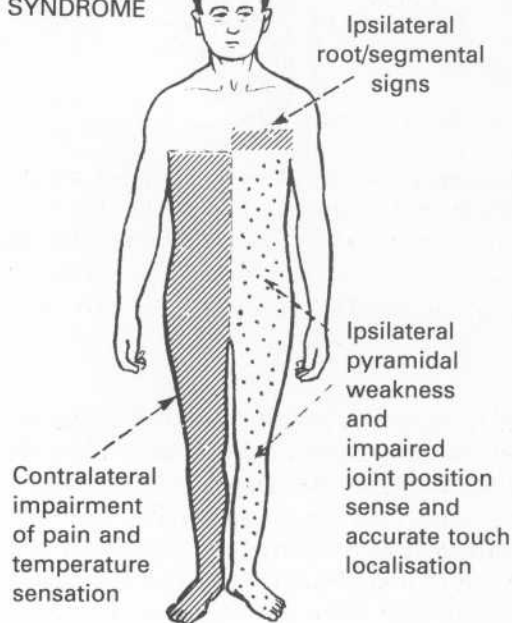
BONE – continuous, dull pain and tenderness over the affected area; may or may not be aggravated by movement.

SPINAL CORD AND ROOT COMPRESSION – NEUROLOGICAL EFFECTS

LATERAL COMPRESSIVE LESION



BROWN SÉQUARD SYNDROME



Root/segmental damage

MUSCLE WEAKNESS in groups supplied by the involved root and segment with LOWER MOTOR NEURON (l.m.n.) signs: – wasting; – loss of tone; – fasciculation; – diminished or absent reflexes. N.B. motor deficit is seldom detected with root lesions above C5 and from T2 to L1.

SENSORY DEFECT of all modalities or hyperaesthesia in area supplied by the root, but overlap from adjacent roots may prevent detection.

Long tract – signs and symptoms

Partial (Unilateral) cord lesion (Brown-Séquard syndrome)

MOTOR DEFICIT – dragging of the leg. In high cervical lesions weakness of finger movements is noted on the side of the lesion.

UPPER MOTOR NEURON (u.m.n.) signs (maximal on side of lesion):

- weakness in a ‘pyramidal’ distribution, i.e. arms – extensors predominantly affected; legs – flexors predominantly affected.
- increased tone, clonus; – increased reflexes;
- extensor plantar response.

SENSORY DEFICIT – numbness may occur on the same side as the lesion and a burning dysaesthesia on the opposite side.

- joint position sense and accurate touch localisation (two point discrimination) impaired on side of lesion.
- pinprick and temperature sensation impaired on opposite side.

In practice, cord damage is seldom restricted to one side. Usually a mixed picture occurs, with an asymmetric distribution of signs and symptoms.

Damage to sympathetic pathways in the T1 root or cervical cord causes an ipsilateral Horner’s syndrome (page 141).

BLADDER symptoms are infrequent and only occur when cord damage is bilateral. Precipitancy or difficulty in starting micturition may precede retention.

SPINAL CORD AND ROOT COMPRESSION – NEUROLOGICAL EFFECTS

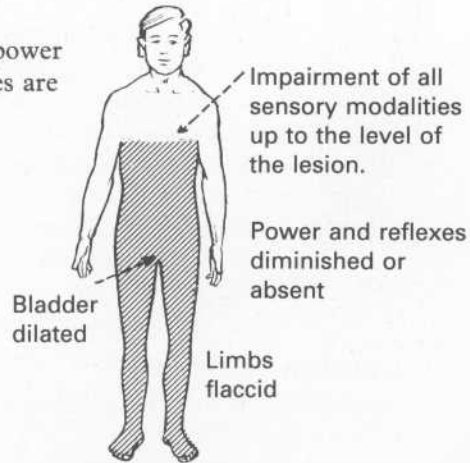
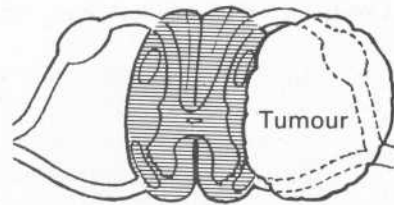
LATERAL COMPRESSIVE LESION (contd)

Long tract damage – complete cord lesion

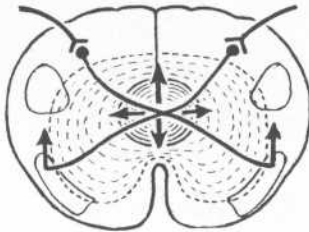
MOTOR DEFICIT: the speed of cord compression affects the clinical picture. Slowly growing lesions present with difficulty in walking; the legs may 'jump' at night. Examination reveals u.m.n. signs often with an asymmetric distribution. Rapidly progressive lesions produce 'spinal shock' – the limbs are flaccid, power and reflexes diminished or absent and plantar responses are absent or extensor.

SENSORY DEFICIT: involves all modalities and occurs up to the level of the lesion.

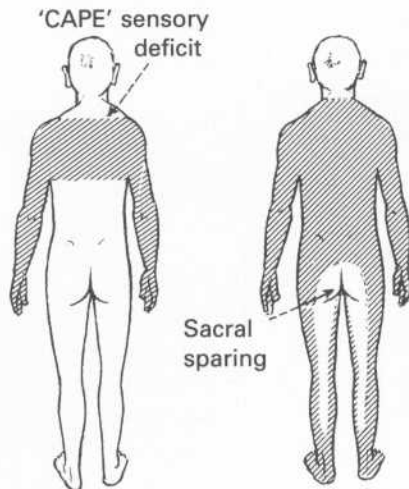
BLADDER: patient first notices difficulty in initiating micturition. Retention follows, associated with incontinence as automatic emptying occurs. *Constipation* is only noticed after a few days. Some patients develop *priapism* (painful erection).



CENTRAL CORD LESION



Segmental damage: A central lesion initially damages the second sensory neuron crossing to the lateral spinothalamic tract; pain and temperature sensations are impaired in the distribution of the involved segment. As the lesion expands, anterior horn cells are also involved and a l.m.n. weakness occurs.



Long tract effects: further lesion expansion damages the spinothalamic tract and corticospinal tracts, the most medially situated fibres being involved first. With lesion in the cervical region, the sensory deficit to pain and temperature extends downwards in a 'CAPE'-like distribution. As the sacral fibres lie peripherally in the lateral spinothalamic tract, **SACRAL SPARING** can occur, even with a large lesion. Involvement of the corticospinal tracts produces u.m.n. signs and symptoms in the limbs below the level of the lesion. The bladder is usually involved late.

In the cervical cord, sympathetic involvement may produce a unilateral or bilateral *Horner's syndrome*.

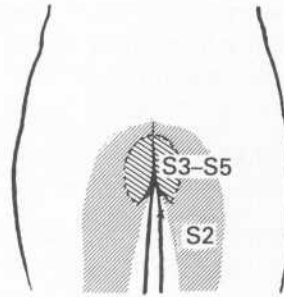
SPINAL CORD AND ROOT COMPRESSION – NEUROLOGICAL EFFECTS

LOWER CORD (CONUS) CAUDA EQUINA LESIONS



Root or segmental lesions may involve the upper part of the cauda equina and produce root/segmental and long tract signs as described on the previous page, e.g. an expanding proximal L4 root lesion causes weakness and wasting of the foot dorsiflexors, sensory deficit over the inner calf, an increased ankle jerk and an extensor plantar response. Bladder involvement tends to occur late.

The lower sacral roots are involved early, producing loss of motor and sensory bladder control with detrusor paralysis. Overflow incontinence ensues. Impotence and faecal incontinence may be noted. A l.m.n. weakness is found in the muscles supplied by the sacral roots (foot plantarflexors and evertors), the ankle jerks are absent or impaired and a sensory deficit occurs over the 'saddle' area.



'Saddle' area.

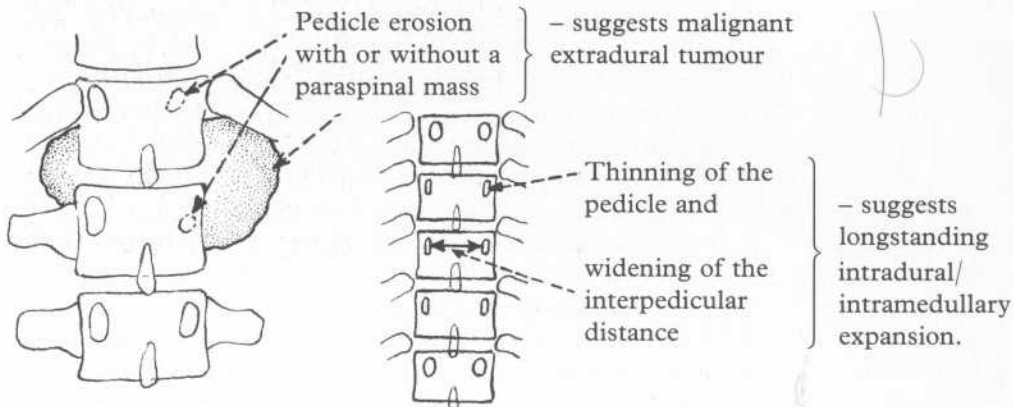
VERTEBRAL COLUMN

If a spinal cord or root lesion is suspected look for:

- | | | |
|---------------------------------------------------------------------|---|-------------------------------------------|
| - Scoliosis, loss of lordosis or limitation of straight leg raising | } | - suggests root irritation |
| - Paravertebral swelling | | - suggests malignant disease or infection |
| - Tenderness on bone percussion | } | - suggests bone, disc or root involvement |
| - Restricted spinal mobility | | - suggests spina bifida occulta/dermoid. |
| - Sacral dimple or tuft of hair | | |

SPINAL CORD AND ROOT COMPRESSION – INVESTIGATIONS

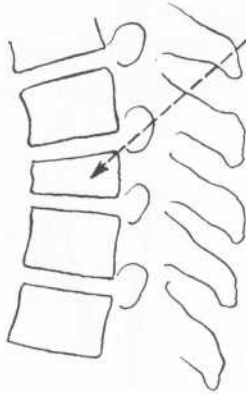
STRAIGHT X-RAY On the ANTERO-POSTERIOR views look for:



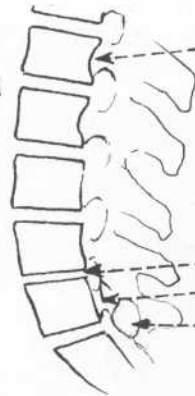
SPINAL CORD AND ROOT COMPRESSION – INVESTIGATIONS

STRAIGHT X-RAY (contd)

On the LATERAL view

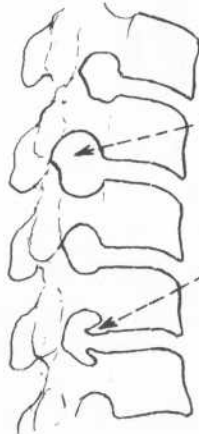


Collapse of the vertebral body suggests malignant infiltration or osteoporosis (If the disc space is destroyed, infection is more likely)



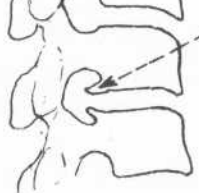'Scalloping' of the posterior surface of the vertebral body indicates a longstanding intradural lesion

Narrow disc space, narrow canal and hypertrophic facet joints support a diagnosis of disc disease or lumbar spinal stenosis (but not diagnostic)



Expansion of the intervertebral foramina suggests neurofibroma

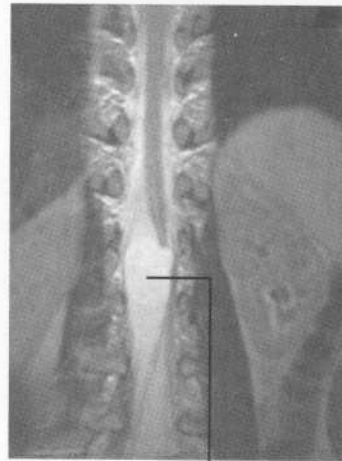On OBLIQUE views



Narrowing from osteophytic encroachment indicates possible root compression (but often seen in asymptomatic elderly patients)

MRI

This is now the investigation of choice for spinal disease, whether this lies within or outwith the dura or the spinal cord. Clinical examination and straight X-rays may suggest the level of the lesion and guide the level of examination. If this fails to detect a lesion, then further imaging must cover the whole length of the cord since occasionally the site of compression lies many segments higher than the clinical signs indicate. The examination must involve both T1 and T2 weighted images, the former often repeated with gadolinium enhancement. *Sagittal or coronal views* are of value in outlining a section of the spinal cord or the cervical medullary junction. On displaying an abnormality at a particular site, *axial views* at selected levels may provide additional information. MRI differentiates a syrinx (page 387) or a cystic swelling within the spinal cord from a solid intramedullary tumour (page 386).

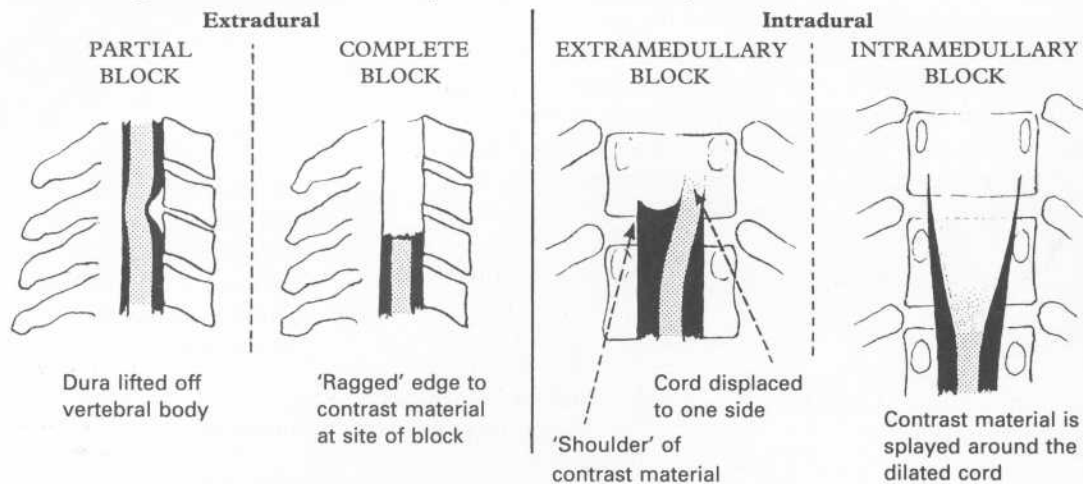


Coronal T2 weighted MRI showing an intradural, extramedullary lesion (ependymoma)

SPINAL CORD AND ROOT COMPRESSION – INVESTIGATIONS

MYELOGRAPHY

If MRI is unavailable, myelography is used to screen the spinal cord and the cauda equina. This will identify the level of a compressive lesion and indicate its probable site i.e. intradural, extradural.



Even with an apparent 'complete' block, sufficient contrast medium may be 'coaxed' beyond the lesion to determine its upper extent. If not, a cervical puncture may be necessary.

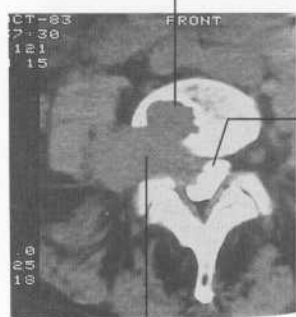
Radio-opaque markers on the skin surface at the site of the block are a useful operative guide.

Lesions in the lumbar and sacral regions require a 'radiculogram', outlining the lumbosacral roots.

CT SCAN/CT MYELOGRAPHY

It is impractical to use this as a screening investigation for cord compression, but if the level of interest is known, CT scanning provides useful additional information.

Vertebral body eroded by tumour



Displaced thecal sac containing contrast medium

Neurofibroma

CSF ANALYSIS

This is of limited value in cord compression. Abnormalities frequently occur, but lumbar puncture may precipitate neurological deterioration, presumably due to the creation of a pressure gradient.

Plain CT with axial cuts will clearly demonstrate bone erosion, osteophytic outgrowth and thickened facet joints causing narrowing of the spinal canal or intervertebral foramen. Axial cuts will also demonstrate disc disease of the lumbosacral spine, show the relationship of any paraspinal mass to the vertebral body and intervertebral foramen and identify the extraspinal extent of an intraspinal lesion, e.g. neurofibroma.

CT myelography with axial cuts (CT performed either 6–12 hours after routine myelography or immediately after intrathecal injection of just a few mls of contrast) demonstrates clearly the degree of spinal cord or nerve root compression.

If cord compression is suspect then lumbar puncture and CSF analysis should await imaging.

CSF protein: often increased, especially below a complete block.

CSF cell count: a marked leucocyte count suggests an infective cause – abscess or tuberculosis.

CSF cytology may reveal tumour cells

SPINAL CORD AND ROOT COMPRESSION

TUMOURS

Incidence: The table shows the number of patients with histologically confirmed tumours admitted to the Institute of Neurological Sciences, Glasgow, over a 5-year period (population 2.7 millions). Tumour types differ in adults and children and are considered separately.

Adults		Children	
EXTRADURAL (78%)		EXTRADURAL (18%)	
Metastasis	118	Metastasis	1
Myeloma	19	Lymphoma	1
Neurofibroma	15		
Lymphoma	14		
Others	7		
INTRADURAL (18%)		INTRADURAL (64%)	
Meningioma	22	Dermoid/epidermoid	6
Schwannoma	13	Others	1
Others	4		
INTRAMEDULLARY (4%)		INTRAMEDULLARY (18%)	
Astrocytoma	8	Astrocytoma	2
Others	1		

(Table adapted from Adams, Graham and Doyle: Brain Biopsy, 1982)

Pathology: The pathological features of spinal tumours match those of their intracranial counterparts (see page 294).

METASTATIC TUMOUR

Occurs in 5% of all cancer patients and accounts for 50% of adult acute myelopathies.

Primary site: Usually breast, lung, prostate or kidney.

Metastatic site: Thoracic vertebrae most often involved, but metastasis may occur at any site and may be multiple.

Clinical features: Bone pain and tenderness are common features usually preceding limb and autonomic dysfunction.

Investigations: Plain radiology may be diagnostic as osteolytic lesions or vertebral collapse are present in most cases. MRI or myelography will identify extradural compression and help exclude or confirm multiple level disease.

Management

In the previous decade, numerous patients with spinal cord compression were subjected to a 'decompressive' laminectomy followed by radiotherapy. Since metastatic tumour usually involves the vertebral body and pedicles, removal of the spinous processes and the lamina served only to increase instability. Not surprisingly results were extremely poor.

Most now feel that *radiotherapy* is the appropriate initial treatment, once the diagnosis is established, unless known radioresistance or a rapidly deteriorating neurological condition enforces the need for *surgical decompression*. Major operative procedures are inappropriate in the elderly, in patients with paraplegia of > 6–12 hours duration, and in patients with a dismal prognosis from their primary tumour (e.g. small cell bronchial carcinoma). In such patients, if medication fails to control pain, a palliative course of radiotherapy may help.

Aims of surgical treatment

- ← To establish a diagnosis if not already known
- ← To decompress the spinal cord yet maintain stability of vertebral column
- ← To produce stability if instability causes excessive pain

SPINAL CORD AND ROOT COMPRESSION

Techniques

Biopsy – needle biopsy of a paraspinal mass or trochar biopsy of infiltrated bone

Surgical decompression

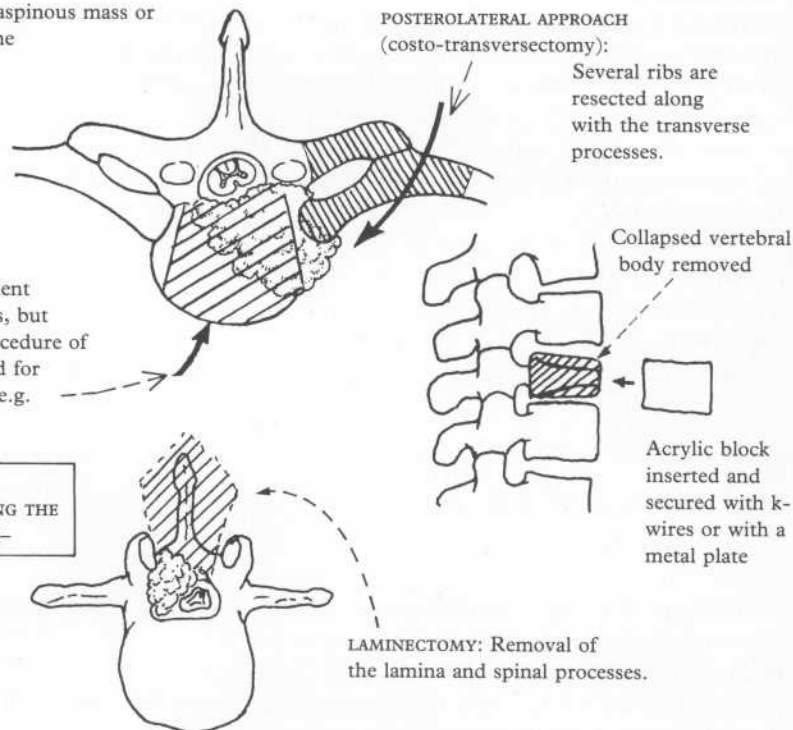
FOR TUMOUR INVOLVING THE VERTEBRAL BODY OR THE PEDICLE-

ANTERIOR TRANSTHORACIC DECOMPRESSION: Provides excellent exposure of the vertebral bodies, but requires the more extensive procedure of a thoracotomy. Usually reserved for patients with the best outcome e.g. breast carcinoma.

FOR TUMOUR LYING POSTERIOR TO THE CORD OR ONLY INVOLVING THE LAMINA AND SPINOUS PROCESSES-

POSTEROLATERAL APPROACH (costo-transversectomy):

Several ribs are resected along with the transverse processes.

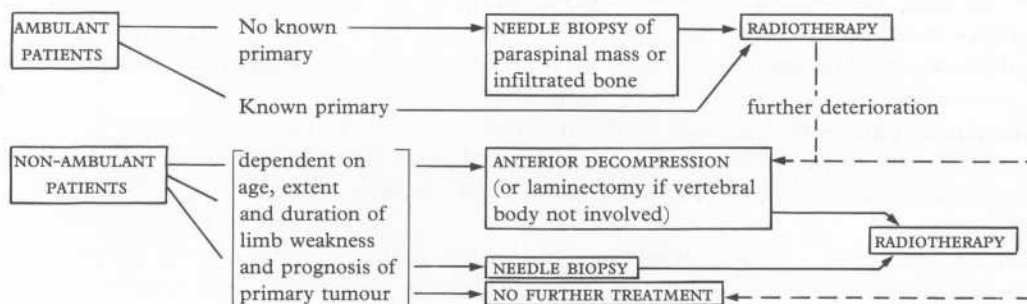


Collapsed vertebral body removed

Acrylic block inserted and secured with k-wires or with a metal plate

LAMINECTOMY: Removal of the lamina and spinal processes.

SUGGESTED SCHEME OF MANAGEMENT



Prognosis: Outcome depends on the nature of the primary tumour. Mean survival after surgery and radiotherapy ranges from 6 months for lung carcinoma to 45 months for prostatic and thyroid carcinoma.

MYELOMA

This malignant condition usually affects older age groups. It is often multifocal, involving the vertebral bodies, pelvis, ribs and skull, but solitary tumours may occur ('plasmacytoma'). Spinal cord compression occurs in 15% of patients with myeloma and rarely without vertebral body involvement due to intradural deposits. If suspect, look for characteristic changes in the plasma immunoglobulins and for Bence-Jones protein in the urine. An isotope bone scan may be less informative than a radiological skeletal survey. Bone marrow shows infiltration of plasma cells. Serum calcium levels may be high.

Management is as for metastatic tumour with additional chemotherapy. The prognosis is variable but patients may survive many years with a solitary plasmacytoma.

SPINAL CORD AND ROOT COMPRESSION

MENINGIOMA

Spinal meningiomas tend to occur in elderly patients and are more common in females than in males. They usually arise in the thoracic region and are almost always intradural. Slow growth often permits considerable cord flattening to occur before symptoms become evident. *MRI* or *CT myelography* will identify the lesion.

The operative aim is complete removal. Results are usually good, but if the tumour arises anteriorly to the cord, excision of the dural origin is difficult, if not impossible, and recurrence may result.

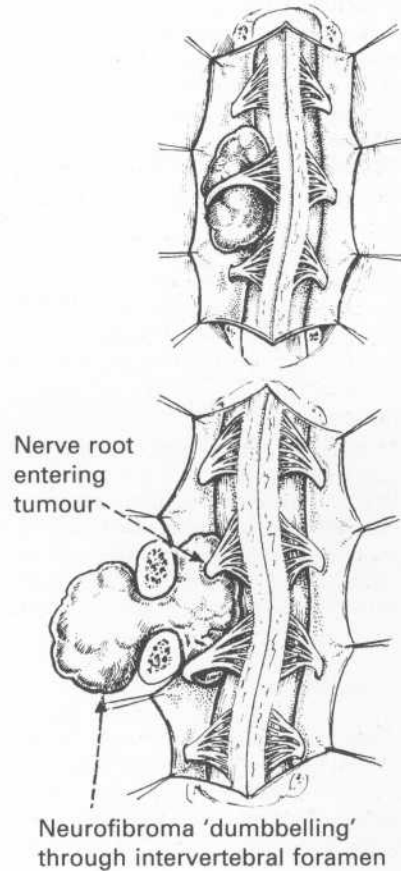
SCHWANNOMA/NEUROFIBROMA

Schwannomas are slowly growing benign tumours occurring at any level and arising from the posterior nerve roots. They lie either entirely within the spinal canal or 'dumbbell' through the intervertebral foramen, on occasions presenting as a mass in the thorax or posterior abdominal wall.

Neurofibromas are identical apart from their microscopic appearance (page 295) and their association with multiple neurofibromatosis (Von Recklinghausen's disease NFI – see page 540) – look for café au lait patches in the skin.

Schwannomas tend to occur in the 30–60 age group. Typically they present with root pain. Root signs and/or signs of cord compression may follow.

MRI or *CT myelography* identifies an intradural/extramedullary lesion. Oblique X-rays may show foraminal enlargement; CT scan will delineate any extraspinal extension (see page 382). Complete operative removal is feasible but the nerve root of origin is inevitably sacrificed. Overlap from adjacent nerve roots usually minimises any resultant neurological deficit.



Neurofibroma 'dumbbelling' through intervertebral foramen

SPINAL CORD AND ROOT COMPRESSION

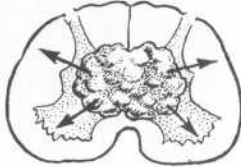
INTRAMEDULLARY TUMOURS

Intrinsic tumours of the spinal cord occur infrequently. In the Glasgow series (Table, page 383) almost all were slowly growing *astrocytomas* (grades I and II) although other series report an equal incidence of *ependymomas*. Cystic cavities may lie within the tumour or at the upper or lower pole. Benign lesions include haemangioblastoma, lipoma, epidermoid, tuberculoma and cavernous angioma.

Clinical features

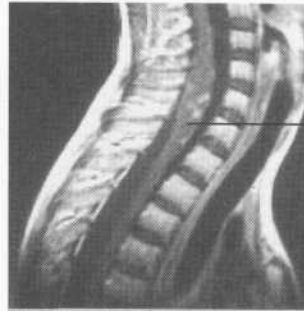The onset is usually gradual. Segmental pain is common. Interruption of the decussating fibres of the lateral spinothalamic tract causes loss of pain and temperature sensation at the level of the involved segments.

Tumour expansion and involvement of the anterior horn cells produces a lower motor neuron weakness of the corresponding muscle groups; corticospinal track involvement produces an upper motor neuron weakness below the level of the lesion. The sensory deficit spreads downwards bilaterally, the sacral region being the last to become involved.



Investigations

Straight X-rays occasionally show widening of the interpedicular distance or 'scalloping' of the vertebral bodies. Myelography confirms the presence of an intramedullary lesion, but *MRI* provides most information, differentiating tumour from syringomyelia, and identifying the extent of the lesion and the presence of any associated cysts.



T1 weighted sagittal MRI showing intramedullary lesion

Management

When an intrinsic cord tumour is suspected, an exploratory laminectomy is required. An attempt is made to obtain a diagnosis either through a longitudinal midline cord incision or by needle biopsy. Cystic cavities within a tumour or an associated syringomyelia may benefit from aspiration. With some ependymomas and benign lesions, a plane of cleavage is evident and partial or even total removal is possible. Attempted removal of low grade astrocytomas carries less encouraging results and operation is contraindicated in malignant tumours. After tumour biopsy or removal, radiotherapy is often administered, but its value is uncertain.

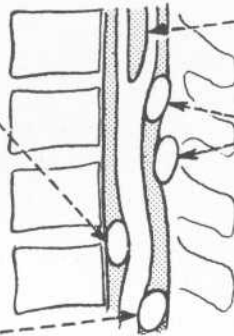
EPENDYMOMA OF THE CAUDA EQUINA

Over 50% of spinal ependymomas occur around the cauda equina and present with a central cauda equina syndrome (page 380). Operative removal combined with radiotherapy usually gives good long-term results, although metastatic seeding occasionally occurs through the CSF.

SPINAL CYSTIC LESIONS

Enterogenous cysts: cysts with a mucoid content are occasionally found lying ventral or dorsal to the cord. They are often associated with vertebral malformation or other congenital abnormality, and are thought to arise from remnants of the neuroenteric canal.

Epidermoid/dermoid cysts: may be of developmental origin or may follow implantation from a preceding lumbar puncture procedure.



Intramedullary cystic lesion: syringomyelia (see over) or cystic cavitation within a glioma.

Arachnoid cysts: arachnoid pouches filled with contrast medium are occasionally found incidentally during myelography. These may seal off, producing CSF filled cysts. They occur predominantly in the thoracic region and sometimes cause cord compression. Children with extradural arachnoid cysts frequently develop kyphosis; the causal relationship remains unknown. In ankylosing spondylitis lumbosacral cysts produce a cauda equina syndrome.

SPINAL CORD AND ROOT COMPRESSION

SYRINGOMYELIA

Syringomyelia is the acquired development of a cavity (syrinx) within the central spinal cord. The lower cervical segments are usually affected, but extension may occur upwards into the brain stem (syringobulbia, see page 367) or downwards as far as the filum terminale.

The cavitation appears to develop in association with obstruction:

- usually around the foramen magnum in conjunction with the *Chiari malformation*.
- also secondarily to *trauma* or *arachnoiditis*.

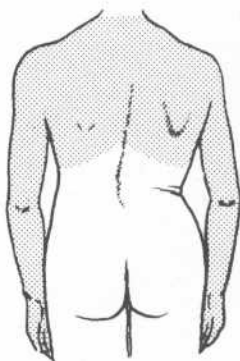
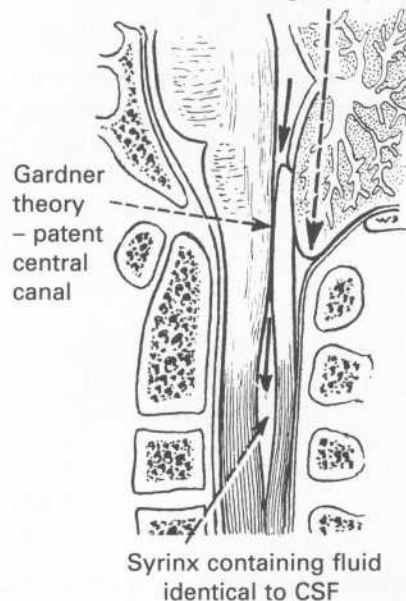
The syrinx may obliterate the central canal leaving clumps of ependymal cells in the wall. In contrast HYDROMYELIA is the congenital persistence and widening of the central canal.

Syringomyelia should be distinguished from cystic intramedullary tumours, although both pathologies may coexist.

Pathogenesis

The exact cause of this condition remains unknown but theories abound. In 1965, Gardner proposed the '*hydrodynamic theory*', suggesting that the craniovertebral anomaly may impair CSF outflow from the 4th ventricle to the cisterna magna. This in turn was believed to result in transmission of a CSF arterial pulse wave through a patent central canal, dilating the canal below the level of compression. This theory, however, does not explain the occurrence of syringomyelia in patients with non-patent central canals. Most now attribute the formation of the syrinx to pressure changes transmitted through the epidural veins to the spinal canal during coughing or straining. In the presence of an obstructive element these pressure changes appear to force CSF into the cord substance. This develops into a cystic cavity which progressively extends.

Arnold-Chiari malformation with cerebellar tonsils impacted in the foramen magnum.



Clinical features

- *Dissociated sensory loss* (i.e. loss of pain and temperature sensation with retention of other senses) occurring in a cape-like distribution. Painless burns are a classic sign.
- *Wasting and weakness of the small muscles of the hand and winging of the scapula* from anterior horn cell involvement. *Scoliosis* often results.
- *Long tract signs* follow.
- *Brain stem signs* may appear, either from syringobulbia or an associated Chiari malformation.
- *Hydrocephalus* occurs in 25% but is usually asymptomatic.

SPINAL CORD AND ROOT COMPRESSION

SYRINGOMYELIA (*contd*)

Investigations

MRI is the investigation of choice (see page 366). This will demonstrate the syrinx with any associated Chiari malformation and exclude intramedullary tumour. If MRI is unavailable – MYELOGRAPHY demonstrates widening of the spinal cord. With coexisting Chiari malformations, screening in the *supine* position will show the cerebellar tonsils descending below the foramen magnum.

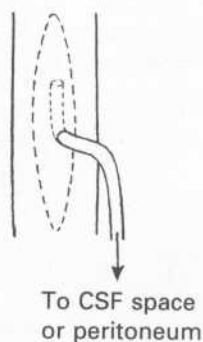
The introduction of air into the CSF space – AIR MYELOGRAPHY – may cause ‘collapse’ of the dilated segment thereby excluding an intrinsic cord tumour. A CT scan, six hours after injection of intrathecal contrast, may show uptake within the syrinx, but beware of misinterpreting normal contrast uptake within spinal cord tissue. Puncture of the syrinx is occasionally possible and subsequent injection of contrast shows its exact extent.

Management

The natural history is variable and operative techniques only of limited benefit. The approach depends on progression of symptoms and the presence or absence of an associated Chiari malformation.

If Chiari malformation is present – *decompression* by removing the posterior rim of the foramen magnum and posterior arch of the atlas results in improvement of long tract and brain stem signs in approximately 30%. Progression is halted in a further 40%. This operation relieves hind brain pressure, and may alter the hydrodynamics of the syrinx. If deterioration in the above patients continues, or if no associated Chiari malformation exists –

Syringostomy:



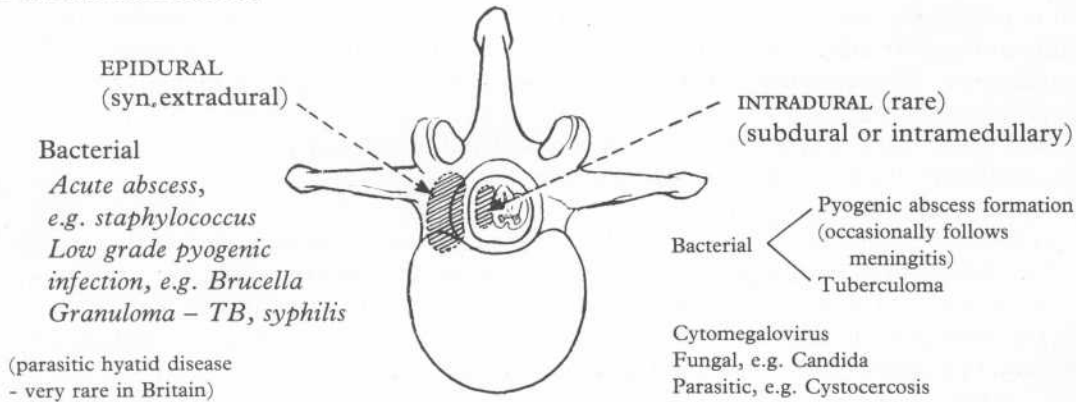
The syrinx is drained via a silastic tube into the surrounding CSF space.

Alternatively, a syringoperitoneal shunt is performed. Some patients benefit from this procedure but in one-third, progressive deterioration continues.

Syringomyelia remains a difficult condition to treat. Draining the syrinx into the CSF space by syringostomy may not significantly alter the haemodynamics. Syringoperitoneal shunt may seem to be the most logical approach. Despite all efforts, at least one-third of patients suffer progressive deterioration.

SPINAL CORD AND ROOT COMPRESSION

SPINAL INFECTION



ACUTE EPIDURAL ABSCESS

Tend to occur in debilitated patients – diabetes, malignancy, liver or renal failure, intravenous drug abuse and alcoholism.

Organism: *Staphylococcus aureus* is the most common agent (90% of cases)

Spread: Haematogenous, e.g. from a boil or furuncle, or direct from vertebral osteomyelitis.

Site: Usually thoracic, but may affect any level and be extensive. Cord damage occurs either from direct compression or secondary to a thrombophlebitis and venous infarction.

Clinical features: Develops over several days mimicking a rapidly progressive extradural tumour or haematoma with bilateral leg weakness, a sensory level and urinary retention, but distinguishing features are:

- very severe pain and tenderness over the involved site.
- toxaemia: pyrexia, malaise, increased pulse rate.
- rigidity of neck and spinal column, with marked resistance to flexion.

As the abscess extends upwards, the sensory level may rise.

Investigations: *Straight X-ray* may or may not show an associated osteitis.

An *MRI* or *myelogram* confirms the site of the extradural lesion.

CSF examination, if performed shows an increased white cell count, usually polymorphonuclear, but may be normal.

A *leucocytosis* is usually present in the peripheral blood and the *ESR* raised.

Blood cultures are usually positive.

Management: Urgent decompressive laminectomy and abscess drainage combined with intravenous antibiotic therapy over some weeks provide the best chance of recovery of function.

SPINAL CORD AND ROOT COMPRESSION

SPINAL TUBERCULOSIS (Pott's disease of the spine)

In developing countries, spinal TB is mostly a disease of childhood or adolescence. In Britain it usually affects the middle aged and is particularly prevalent in immigrant populations. The incidence is now increasing, probably due to the development of antibiotic resistance.

The lower thoracic spine is commonly involved and the disease initially affects the intravertebral disc and spreads to adjacent vertebral bodies.

Clinical features:

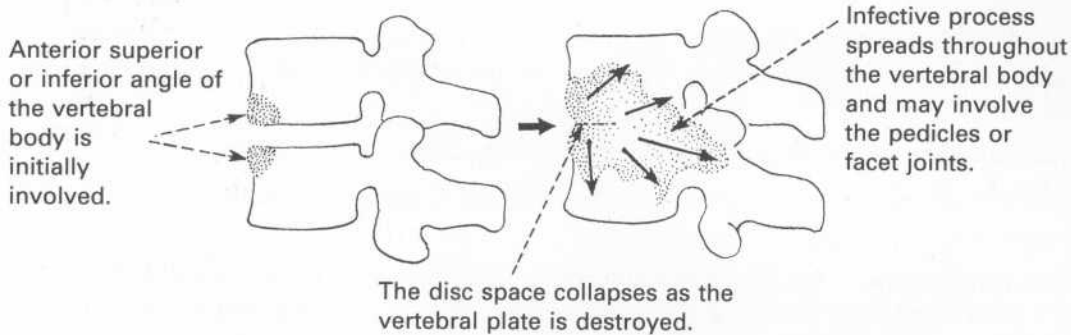
The classic systemic features of weight loss, night fever and cachexia are often absent.

Pain occurs over the affected area and is made worse by weight bearing.

Symptoms and signs of cord compression occur in approximately 20% of cases.

The onset may be gradual as pus, caseous material or granulation tissue accumulate, or sudden as vertebral bodies collapse and a kyphosis develops.

STRAIGHT X-RAYS are characteristic.



MRI with gadolinium shows an epidural mass with paraspinal soft tissue swelling.

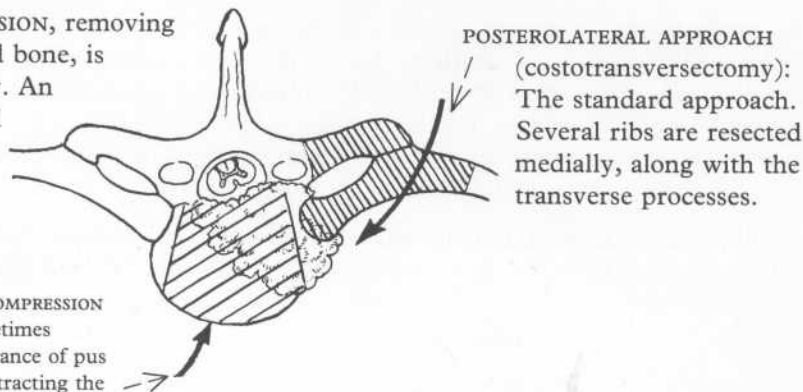
Management:

Every effort is made to establish the diagnosis. A *needle biopsy* is often sufficient, but occasionally an exploratory operation (costotransversectomy) is required. Long-term *antituberculous therapy* is commenced.

If signs of cord compression develop, decompression is necessary.

A POSTERIOR DECOMPRESSION, removing the remaining unaffected bone, is likely to cause instability. An anterior or posterolateral approach is therefore required.

ANTERIOR TRANSTHORACIC DECOMPRESSION with strut graft fusion is sometimes performed. This permits clearance of pus and caseous debris without retracting the spinal cord.

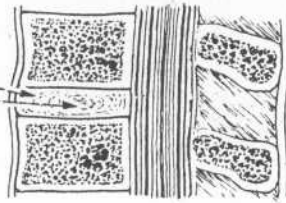


DISC PROLAPSE AND SPONDYLOSIS

Intervertebral discs act as shock absorbers for the bony spine.

A tough outer layer – the annulus fibrosis surrounds a softer central nucleus pulposus.

Discs degenerate with age, the fluid within the nucleus pulposus gradually drying out. Disc collapse produces excessive strain on the facet joints, i.e. the superior and inferior articular processes of each vertebral body, and leads to degeneration and hypertrophy.

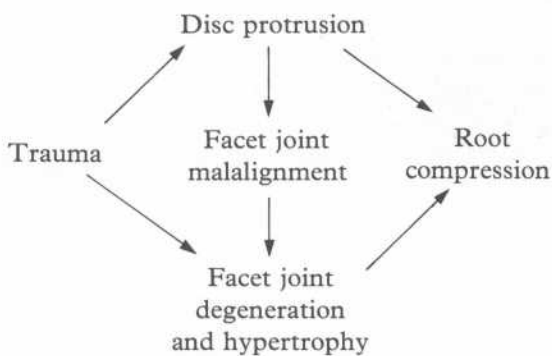
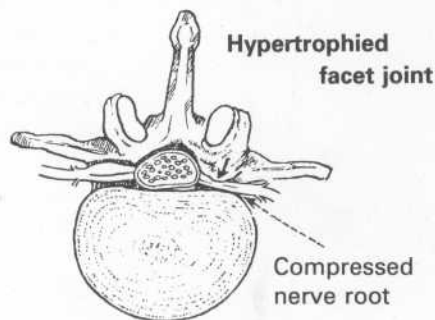
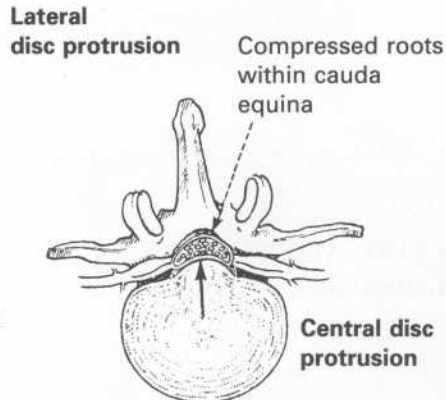
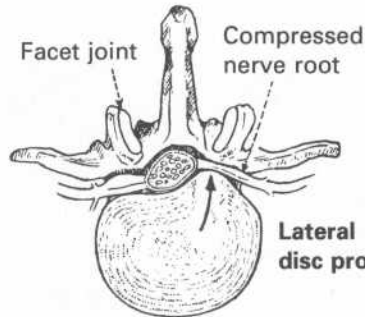
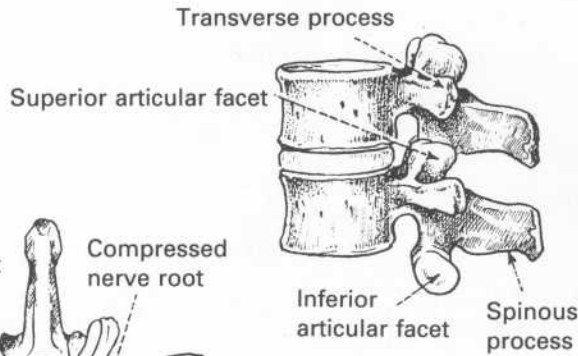


LUMBAR DISC PROLAPSE

An *acute disc prolapse* occurs when the soft nucleus herniates through a tear in the annulus and may result from a single or repeated traumatic incidents. Herniation usually occurs laterally and compresses adjacent nerve roots, but may occasionally occur centrally, compressing the cauda equina.

A 'free fragment' of the nucleus pulposus may extrude and lie above or below the level of the disc space.

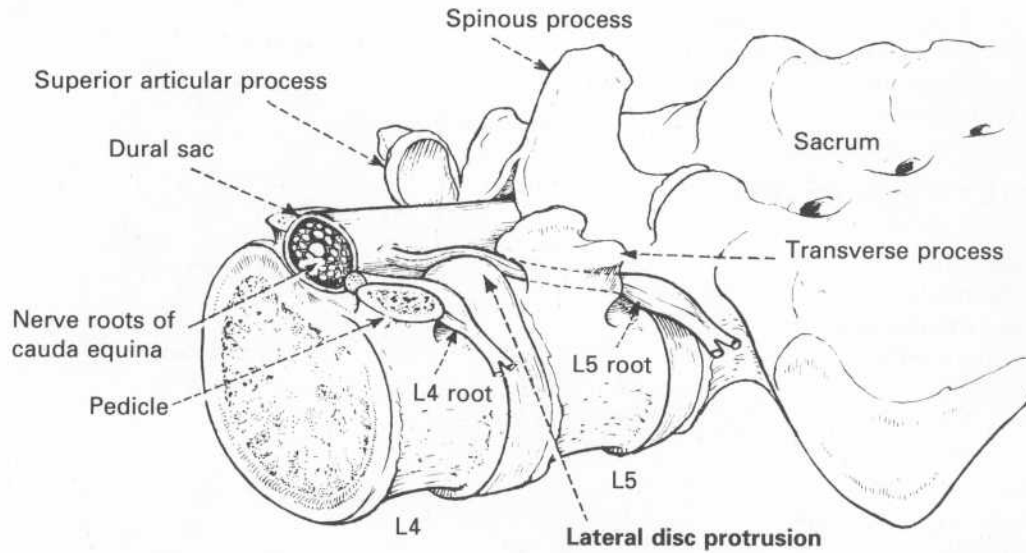
Associated hypertrophy of degenerated facet joints is often a further source of back and leg pain and is an important cause of root compression.



LUMBAR DISC PROLAPSE

A congenitally narrowed spinal canal increases susceptibility to the development of nerve root compression. Here the spinal canal diameter is considerably diminished and minor disc protrusion or mild joint hypertrophy may more readily compress the nerve root.

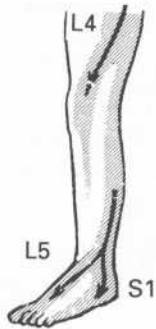Lateral disc herniations usually compress the nerve root exiting through the foramen below the affected level, e.g. an L3/4 disc lesion will compress the L4 nerve root, but large disc protrusions or a free fragment may compress any adjacent root.



Lumbar disc lesions may occur at any level but L4/5 and L5/S1 are the commonest sites (95%).

CLINICAL FEATURES

Lateral disc protrusion



Injury: A history of falling, or lifting heavy weights often precedes the onset of symptoms.

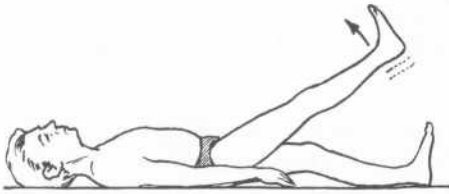Leg pain: Root irritation or compression produces pain in the distribution of the affected root and this should extend below the mid-calf. Coughing, sneezing or straining aggravates the leg pain which is usually more severe than any associated backache. If compression causes severe root damage the leg pain may disappear as neurological signs develop.

Paraesthesia: Numbness or tingling occurs in the distribution of the affected root.

LUMBAR DISC PROLAPSE

CLINICAL FEATURES (contd)

'MECHANICAL' SIGNS: Spinal movements are restricted, scoliosis is often present and is related to spasm of the erector spinae muscles, and the normal lumbar lordosis is lost.

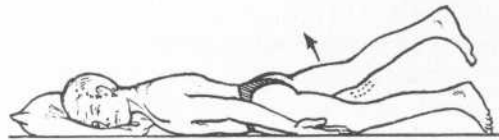

Straight leg raising: L5 and S1 root compression causes limitation to less than 60° from the horizontal and produces pain down the back of the leg. Dorsiflexion of the foot while the leg is elevated aggravates the pain. Elevation of the 'good' leg may produce pain in the other leg.

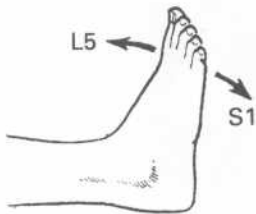
(If in doubt about the veracity of a restricted straight leg raising deficit, sit the patient up on the examination couch with the legs straight. This is equivalent to 90° straight leg raising.)

Reverse leg raising (femoral stretch)

Tests for irritation of higher nerve roots (L4 and above)



NEUROLOGICAL DEFICIT: Depends on the predominant root involved:



- L4 – Quadriceps wasting and weakness; sensory impairment over medial calf; impaired knee jerk.
- L5 – Wasting and weakness of dorsiflexors of foot, extensor digitorum longus and extensor hallucis longus; wasting of extensor digitorum brevis; sensory impairment over lateral calf and dorsum of foot.
- S1 – Wasting and weakness of plantar flexors; sensory impairment over lateral aspect of foot and sole; impaired ankle jerk.

Root signs cannot reliably localise the level of disc protrusion due to variability of the anatomical distribution.

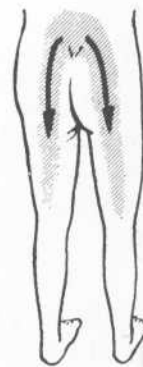Central disc protrusion

Symptoms and signs of central disc protrusion are usually bilateral, although one side is often worse than the other.

Leg pain: Extends bilaterally down the back of the thighs. Pain may disappear with the onset of paralysis.

Paraesthesia: Occurs in the same distribution.

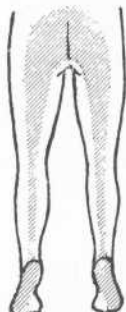Sphincter paralysis: Loss of bladder and urethral sensation with intermittent or complete retention of urine occurs in most patients. Anal sensation is usually impaired and accompanies constipation.



LUMBAR DISC PROLAPSE

Central disc protrusion (contd)

Severe pain associated with lateral disc protrusion may inhibit micturition. In this instance, strong analgesia should allow normal micturition; the presence of normal perineal sensation excludes root compression as the cause of the retention.



Sensory loss: Extends over all or part of the sacral area ('saddle' anaesthesia) and confirms a neurogenic cause for the sphincter disturbance.

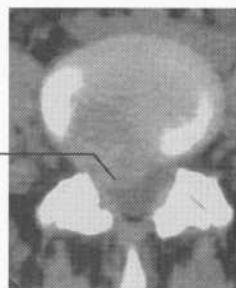
Motor loss: Usually presents as foot drop with complete loss of power in the dorsiflexors and plantarflexors of both feet.

Reflex loss: The ankle jerks are usually absent on each side

INVESTIGATION

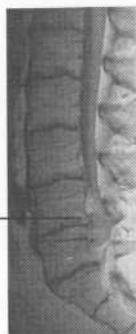Straight X-ray of lumbosacral spine is of limited benefit in the investigation of lumbar disc disease – it may show loss of a disc space or an associated spondylolisthesis (see p. 396). Straight X-rays are *important in excluding other pathology* such as metastatic carcinoma.

CT scanning of lowest three spaces will detect a disc protrusion and demonstrate the extent of root compression. CT scanning also clearly shows hypertrophy of the facet joints and the diameter of the spinal canal (see page 392).



NB A patient with characteristic 'root' pain in whom CT scanning is negative requires an MRI to exclude a lesion involving the conus medullaris.

MRI is now the investigation of first choice. Sagittal views combined with axial views at the appropriate level will demonstrate disc disease and exclude a lesion at the conus.



T1 weighted
Sagittal MR.

Radiculography shows a filling defect in the theca obliterating or displacing the nerve root sleeve at the disc level. A *CT radiculogram* may demonstrate nerve root displacement more clearly than MRI

LUMBAR DISC PROLAPSE

Management

(a) Lateral disc protrusion

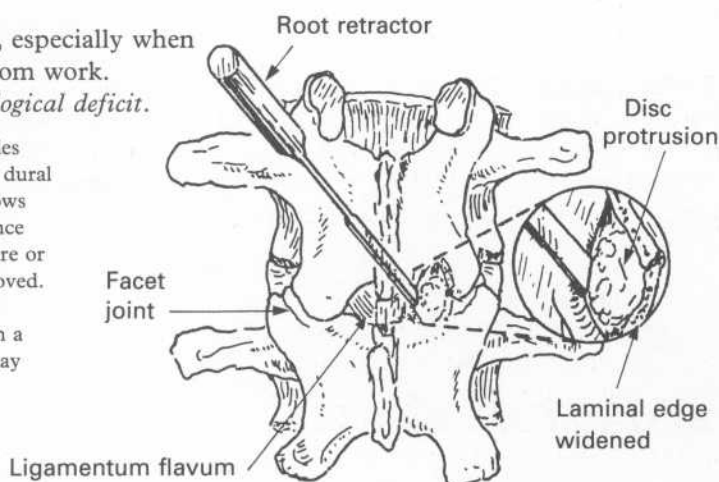
CONSERVATIVE: Most bouts of leg pain settle spontaneously by taking simple measures:

- Analgesics
- Avoiding heavy lifting and bending. Picking up objects from the floor should be performed by bending the knees and keeping the back straight
- Using an orthopaedic mattress or hard board under the mattress
- A plaster jacket or spinal brace helps some patients
- Bed rest, but only if pain prevents any movement
- Traction may help, but pain can return when traction is removed.

INDICATIONS FOR OPERATION

- Severe unremitting leg pain despite conservative measures.
- Recurrent attacks of leg pain, especially when causing repeated time loss from work.
- The development of a neurological deficit.

TECHNIQUE: Fenestration usually provides good access. Retraction of the root and dural sac exposes the disc protrusion and allows removal with rongeurs. Any protuberance from the facet joint causing root pressure or narrowing of the root canal is also removed. 'Microdissectomy' with an operating microscope allows disc removal through a smaller skin and muscle incision and may reduce the period of hospital care.



RESULTS: Over 80% of patients obtain good results after operation. The remainder may have recurrent problems due to a further disc protrusion at the same or another level. Root damage occurs in <1%

After disc operation, patients are advised to avoid heavy lifting, preferably for an indefinite period. Persistence in a heavy manual job may lead to further trouble.

In general, patients with clear-cut indications for operation do well, whereas those with dubious clinical or radiographic signs tend to have a high incidence of recurrent problems.

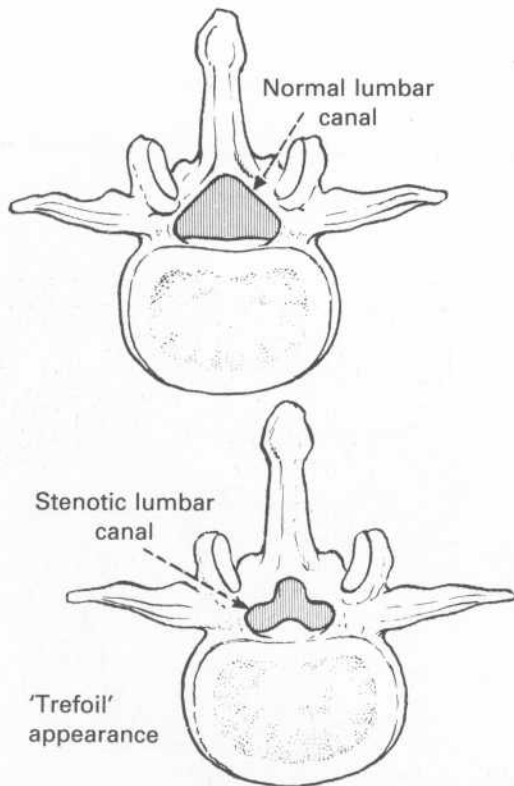
(b) Central disc protrusion

In contrast to lateral disc protrusion, compression of the cauda equina from a central disc constitutes a neurosurgical emergency. Delay in root decompression results in a reduced chance of motor and sphincter recovery.

Large disc protrusions may require a one or two level laminectomy rather than a fenestration, to minimise the risk of further root damage.

Motor, sensory and sphincter function should gradually recover over a two year period but results are often disappointing. Although most regain bladder control, few have completely normal function and in many, sexual difficulties persist.

LUMBAR SPINAL STENOSIS

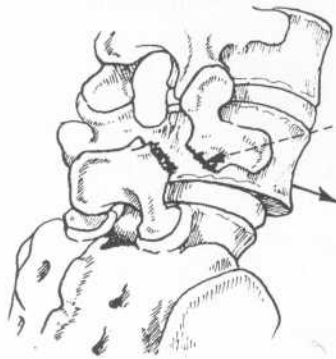

Congenital narrowing of the lumbar spinal canal, or secondary narrowing due to hypertrophic facet joints, may predispose to root compression from a herniated disc, but in addition may produce 'neurogenic claudication'. Symptoms of root pain, paraesthesia or weakness develop after standing or walking and may be relieved by sitting, bending over or lying down. Straight leg raising is seldom impaired, in contrast to patients with disc protrusion. Objective neurological findings may only appear after exercise. In some patients this condition only affects one side – the 'unilateral facet syndrome'.

Plain X-rays may show thickened joints, but CT scanning, MRI or radiculography is required to establish the diagnosis.

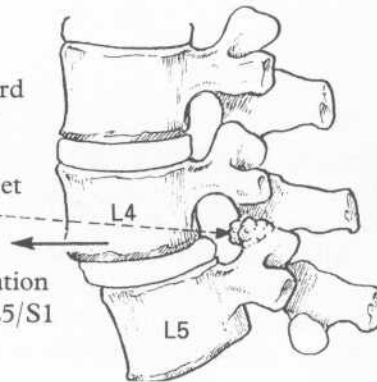
Treatment: A wide laminectomy with root decompression usually produces good results with complete relief of symptoms.

SPONDYLOLISTHESIS



Spondylolisthesis is a forward shift of one vertebral body on another. Slip occurs due to degenerative disease of the facet joints (commonly at L4/L5) or to a developmental break or elongation of the L5 lamina causing an L5/S1 spondylolisthesis.

Spondylolisthesis is often symptomless but the resultant narrowing in canal width may accentuate symptoms of root compression from disc protrusion or joint hypertrophy.



Treatment: usually conservative, but if signs of root compression are present, then decompression of the root canal is necessary. Occasionally fusion is required, especially if back pain predominates.

THORACIC DISC PROLAPSE

This occurs rarely (0.2% of all disc lesions) due to the relative rigidity of the thoracic spine.

PRESENTATION

- Root pain and/or
- Progressive or fluctuating paraparesis (may lead to mistaken diagnosis).

As vascular involvement may produce damage above the level of compression, sensory findings may be misleading.

INVESTIGATION

A combination of sagittal and axial views on either *MRI* or *CT myelography* should clearly demonstrate the disc herniation and the extent of the associated cord compression.

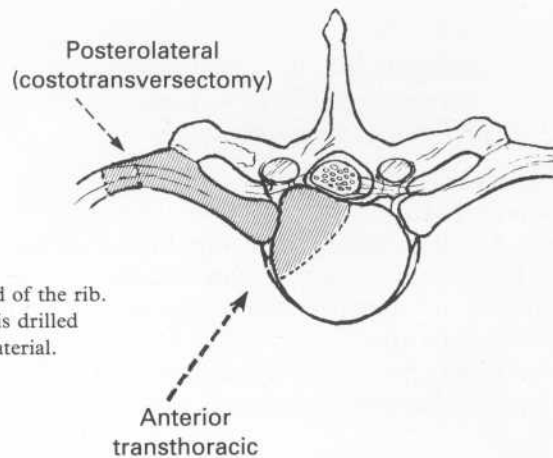


Sagittal reconstruction of CT scan at T11/12 level showing cord compression from a large disc protrusion.

MANAGEMENT

Root pain – may settle with bed rest.

In the presence of cord compression or unremitting root pain, either a *posterolateral* or an *anterior transthoracic approach* is used to remove the disc. (A posterior approach – laminectomy – carries an unacceptably high risk of paraplegia.)

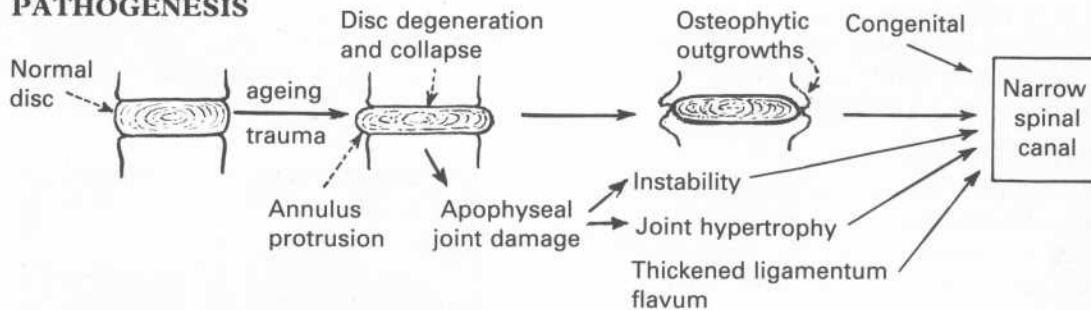


Both approaches involve removal of the head of the rib. The vertebral body adjacent to the disc space is drilled away permitting clearance of herniated disc material.

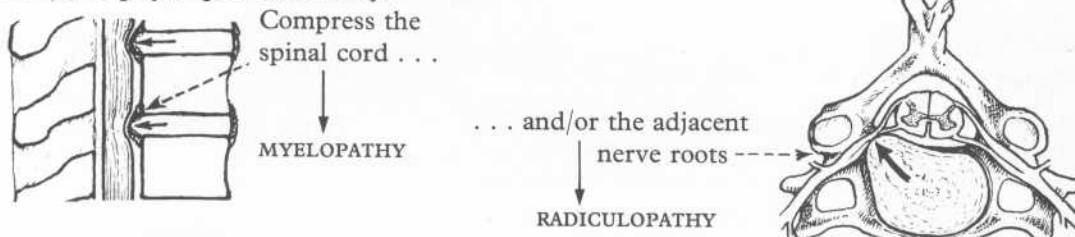
CERVICAL SPONDYLOSIS

The mobile cervical spine is particularly subject to osteoarthritic change and this occurs in more than half the population over 50 years of age; of these approximately 20% develop symptoms. Relatively few require operative treatment.

PATHOGENESIS



Disc/osteophytic protrusion may:



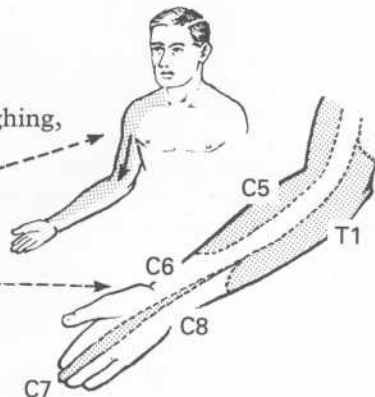
Resultant damage to the spinal cord may arise from direct pressure or may follow vascular impairment. The onset is usually gradual. Trauma may or may not predispose to the development of symptoms.

CLINICAL FEATURES

Radiculopathy

Pain: A sharp stabbing pain, worse on coughing, may be superimposed on a more constant deep ache radiating over the shoulders and down the arm.

Paraesthesia: Numbness or tingling follows a nerve root distribution.



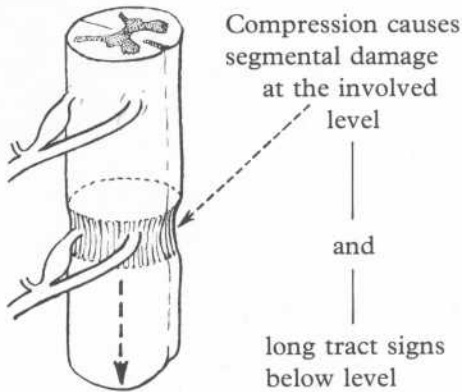
Root signs:

- **Sensory loss**, i.e. pin prick deficit in the appropriate dermatomal distribution.
- **Muscle (l.m.n.) weakness** and wasting in appropriate muscle groups, e.g. C5, C6 . . . biceps, deltoid; C7 . . . triceps.
- **Reflex impairment/loss**, e.g. C5, 6 . . . biceps, supinator jerk; C7 . . . triceps jerk.
- **Trophic change:** In long-standing root compression, skin becomes dry, scaly, inelastic, blue and cold.

CERVICAL SPONDYLOSIS

CLINICAL FEATURES (contd)

Myelopathy



Arms: l.m.n. signs and symptoms, as above, at the level of the lesion

and/or

u.m.n. signs and symptoms below the level of the lesion

e.g. C5 lesion { biceps weakness, wasting:
diminished biceps jerk:
increased finger jerks.

Legs: u.m.n. signs and symptoms, i.e. difficulty in walking due to stiffness; 'pyramidal' weakness, increased tone, clonus and extensor plantar responses; sensory symptoms and signs are variable and less prominent.

Sphincter disturbance is seldom a prominent early feature.

N.B. Involved segments may extend above or below the level of compression if the vascular supply is also impaired.

INVESTIGATION

Plain X-ray of cervical spine

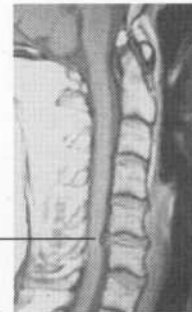Look for:

- congenital narrowing of canal, loss of lordosis.
- disc space narrowing and osteophyte protrusion (foraminal encroachment is best seen in oblique views).
- spondylolisthesis. Flexion/extension views may be required.

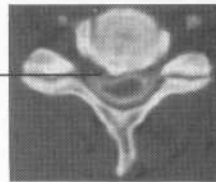
MRI: since non-invasive, now the investigation of first choice.

Sagittal views clearly demonstrate anterior cord compression at the level of the disc space (best viewed on T1 weighted images; T2 weighting may exaggerate the degree of cord compression. The hyperintensity seen within the cord on T2 weighting at the level of compression usually bears no clinical relevance). Axial views are less easy to interpret, but will confirm cord compression and foraminal narrowing.

T1 weighted MR showing a C5/6 spondylotic bar



Myelography, particularly when combined with **CT scanning**, shows in detail the degree of spinal cord and nerve root compression from osteophytic outgrowth.



MANAGEMENT

Conservative

- Analgesics
- Cervical collar
- Traction

Symptoms of radiculopathy, whether acute or chronic, usually respond to these conservative measures plus reassurance. Progression of a disabling neurological deficit however demands surgical intervention. The clinician may adopt a conservative approach when a myelopathy is mild, but undue delay in operation may reduce the chance of recovery.

CERVICAL SPONDYLOSIS

MANAGEMENT (contd)

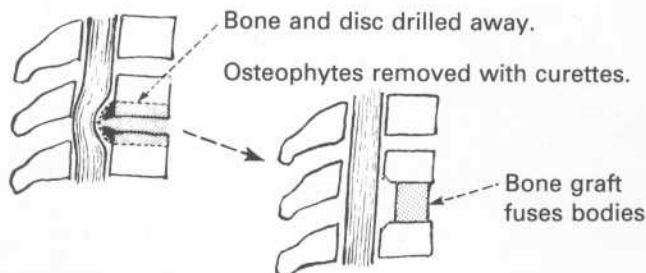
Indications for operation

1. Progressive neurological deficit – myelopathy or radiculopathy.
2. Intractable pain, when this fails to respond to conservative measures. This is rarely the sole indication for operation and usually applies to acute disc protrusions (see below) rather than chronic radiculopathy.

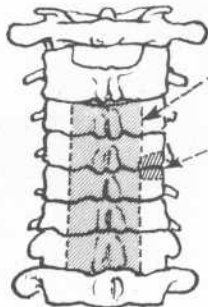
Operative techniques

1. Anterior decompression and fusion

A core of bone and disc is drilled out allowing removal of the osteophytic projection. Although not essential, most combine this with fusion using a dowel from the iliac crest.



Suitable for root or cord compression from an anterior protrusion at one level, although two and even three levels may be decompressed by this method.



2. Posterior approach

- (a) *Laminectomy*: a wide decompression, usually from C3–C7, is carried out. Only suitable for multilevel cord compression especially when superimposed on a congenitally narrow spinal canal.
- (b) *Foraminotomy*: the nerve root at one or more levels may be decompressed by drilling away overlying bone.

Results

Operative results vary widely in different series and probably depend on patient selection. Some improvement occurs in 50–80% of patients. Operation should be aimed at preventing progression rather than curing all symptoms.

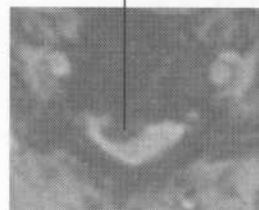CERVICAL DISC PROLAPSE

In contrast to cervical spondylosis, cervical 'soft disc' protrusion is uncommon. This tends to occur acutely in younger patients and may be related to a specific incident such as a sudden twist or injury to the neck. The protrusion usually occurs posterolaterally at the C5/C6 or C6/C7 level causing a radiculopathy rather than a myelopathy.

SAGITTAL T1 weighted MRI or CT scan with intrathecal contrast clearly outline the disc protrusion.

Operative removal through an anterior approach may be required for intractable pain or neurological deficit and gives good results.

T2 weighted axial MRI showing disc protrusion (note poorer definition than CT/myelogram)



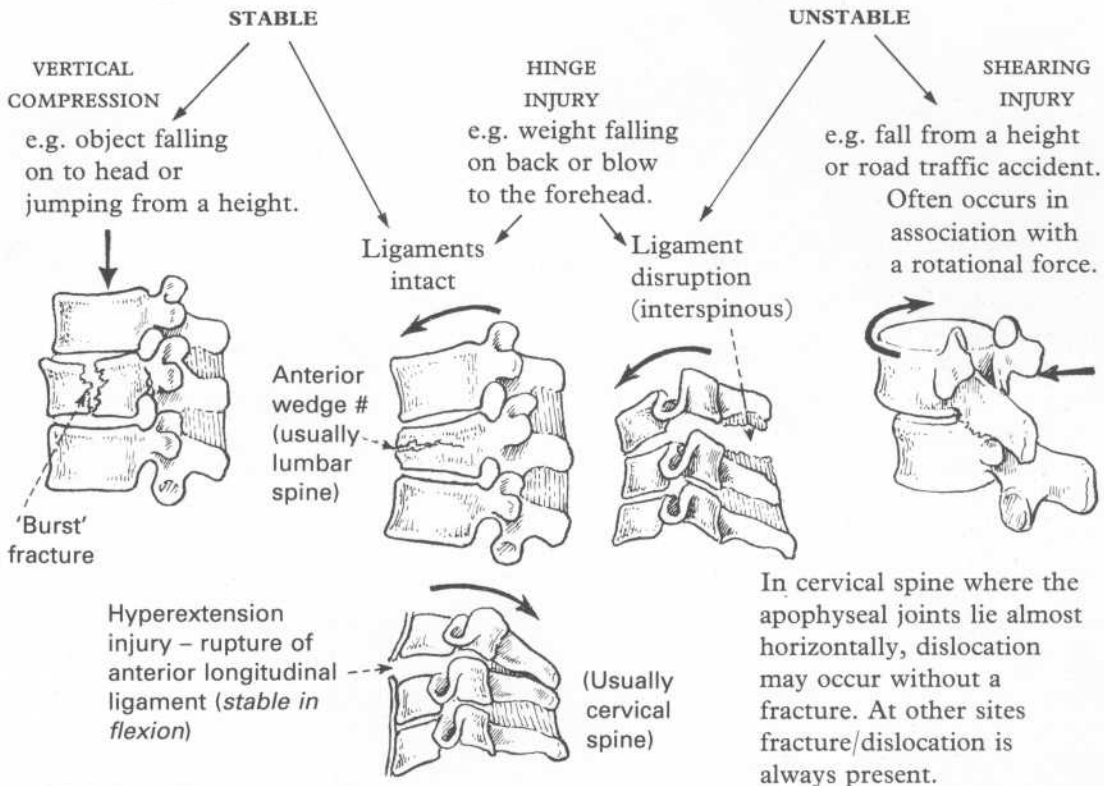
SPINAL TRAUMA

Approximately 2 per 100 000 of the population per year sustain a spinal injury. Of these, 50% involve the cervical region.

At impact, *spinal cord damage* may or may not accompany the *bony or ligamentous damage*. After impact, stability at the level of injury plays a crucial part in further management. Injudicious movement of a patient with an unstable lesion may precipitate spinal cord injury or aggravate any pre-existing damage.

MECHANISMS OF INJURY

The mechanism of injury helps determine the degree of stability:



Initial assessment

The possibility of spinal injury must be considered at the scene of the accident and all movements and transportation of the patient undertaken with extreme caution especially when comatose. Most spinal injuries occur in conscious patients who complain of *pain, numbness or difficulty with limb movements*.

Examination may reveal *tenderness over the spinous processes, paraspinal swelling or a gap between the spinous processes*, indicating rupture of an interspinous ligament.

Neurogenic paradoxical ventilation (indrawing of the chest on inspiration due to absent intercostal function) may occur with cervical cord damage.

Bilateral absence of limb reflexes in flaccid limbs, unresponsive to painful stimuli, indicates spinal cord damage (unless death is imminent from severe head injury.)

Painless urinary retention or priapism may also occur.

SPINAL TRAUMA – INVESTIGATIONS

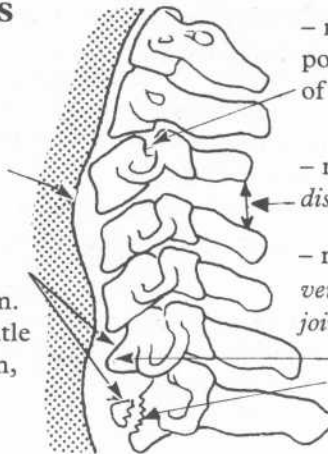
STRAIGHT X-RAYS

LATERAL VIEW

In the *cervical spine*:

– note evidence of *soft tissue swelling* between the pharynx and the vertebrae.

– ensure *C6 and C7* are included in the film. If not, repeat with gentle downward arm traction, or do a CT scan



– note any *malalignment* of the anterior or posterior margins of the vertebral body or of the lamina, i.e. *subluxation*.

– note any undue *widening of the interspinous distance or of the disc space*.

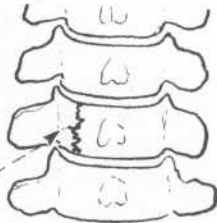
– note *damage to the vertebral body, apophyseal joints, lamina or spinous process*, e.g.

– anterior wedge collapse, 'burst' fracture.

In the upper thoracic spine only **Tomography** may satisfactorily demonstrate the lateral view.

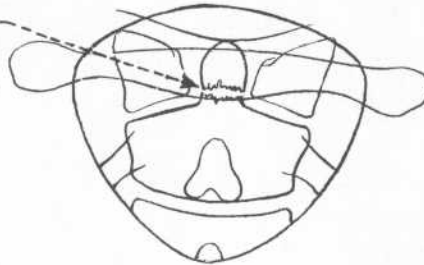
ANTERO-POSTERIOR VIEW

– note the *alignment* of the spinous processes and the *width of the apophyseal joints* and look for *vertical fracture lines*.



ANTERO-POSTERIOR 'OPEN MOUTH' VIEW

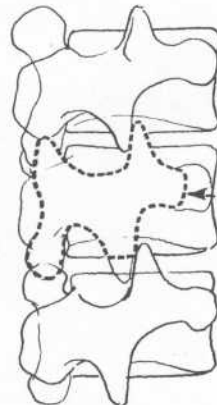
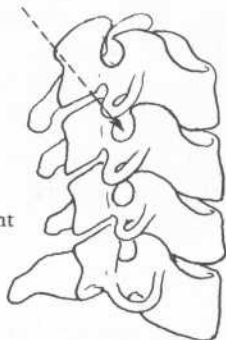– may be required to demonstrate a *fracture of the odontoid peg*.



If doubt remains – take **OBLIQUE VIEWS** to demonstrate the *intervertebral foramina*.

CERVICAL SPINE

Disruption of the *foraminal outline* suggests *malalignment*



In the **LUMBAR** spine look for the normal '*scotty dog*' appearance – if *misshapen*, suggests a *fracture/dislocation*.

If in doubt about cervical stability, take **FLEXION/EXTENSION VIEWS**, but only with expert supervision.

CT scanning may aid identification of a fracture and show fragments extending into the spinal canal. **CT/myelography** or **MRI** may provide additional information, but these investigations only help if operative decompression and/or stabilisation is considered.

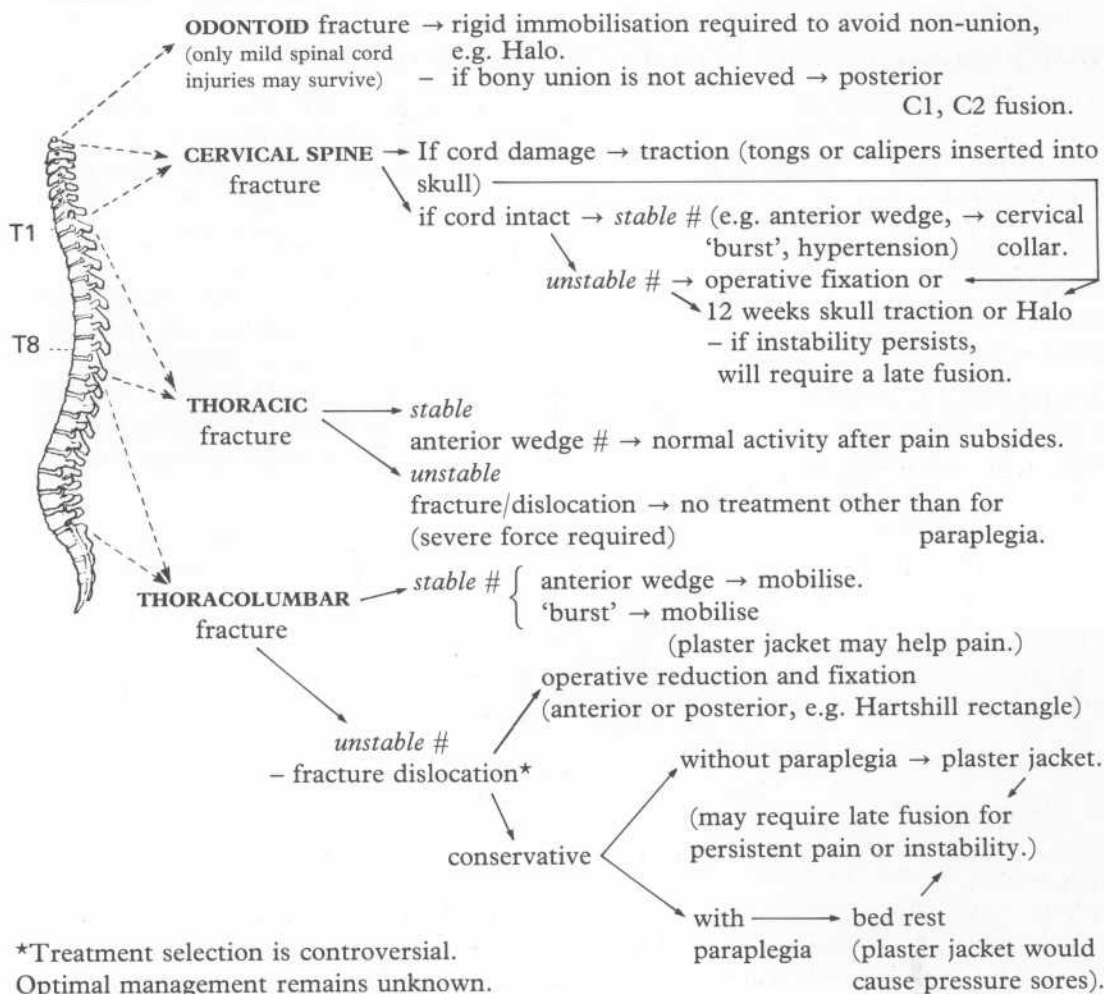
SPINAL TRAUMA – MANAGEMENT

Management depends on the site and stability of the lesion, but basic principles apply.

1. An *unstable* lesion risks further damage to the spinal cord and roots and requires either –
 - *operative fixation* or
 - *immobilisation*, e.g. skull traction, Halo or plaster jacket.
2. There is no evidence that ‘decompressing’ the cord lesion (either anteriorly or posteriorly) improves the neurological outcome, but –
3. If a patient with normal cord function or with an incomplete cord lesion (i.e. with some residual function) *progressively deteriorates*, then *operative decompression* is required.

Many additional therapies and techniques (e.g. steroids, cord cooling, hyperbaric oxygen) are employed with the aim of improving neurological outcome; only METHYLPREDNISOLONE given within 8 hours of injury has been shown to produce benefit, but it is not known whether this significantly improves functional outcome.

Management of injury at specific sites



SPINAL TRAUMA – MANAGEMENT

Management of the paraplegic patient

After spinal cord injury, transfer to a spinal injury centre with medical and nursing staff skilled in the management of the paraplegic patient provides optimal daily care and rehabilitation.

Important features include:

1. *Skin care* – requires meticulous attention. Two-hourly turning should prevent pressure sores. Attempt to avoid contact with bony prominences or creases in the bed sheets. Air or water beds or a sheepskin may help.
2. *Urinary tract* – long-term catheter drainage or intermittent self-catheterisation is required. Infection requires prompt treatment. Eventually, training may permit automatic reflex function (in cord lesions) or micturition by abdominal compression (in root lesions). In some, urodynamic studies may indicate possible benefit from bladder neck resection.
3. *Limbs* – intensive physiotherapy helps prevent flexion contractures (in cord injury) and plays an essential rôle in rehabilitation.

OUTCOME FOLLOWING SPINAL CORD OR ROOT INJURY

Patients with high cervical cord lesions *seldom survive* without immediate ventilatory support.

Patients who survive a lesion above C7 usually remain *dependent* on others for daily care.

Sparing of the C7 segment retains elbow and wrist extension and enables transfer from wheel chair to bed, providing a *degree of independence*.

Patients with thoraco-lumbar injuries usually regain *full independence*.

A **MIXED** cord and lumbar root lesion may occur at this level. Fortunately roots are more resistant to injury – '*root escape*' – and the outlook is more favourable.



'COMPLETE': if no sign of motor or sensory function within 24 hours, then recovery will not occur. (The early return of anal and penile reflexes is not necessarily a good sign.)

After a few days or weeks, tone returns to the flaccid limbs and reflexes become brisk. Flexor spasms may follow with the risk of contractures. A reflex bladder develops with automatic emptying.

'INCOMPLETE': any retention of motor or sensory function indicates an incomplete lesion with the potential for recovery.

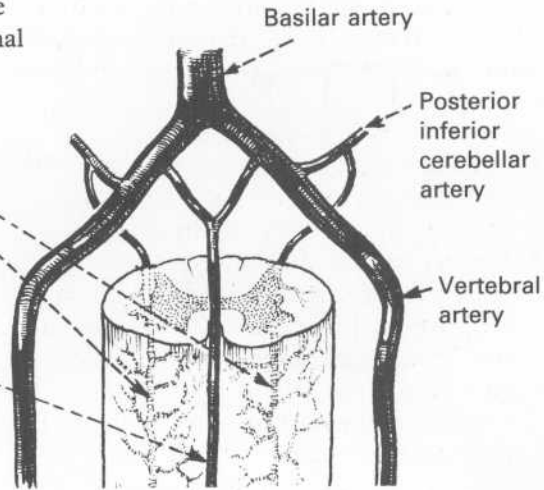
Recovery may theoretically occur as the roots regenerate, perhaps only after many months delay. The limbs remain flaccid throughout.

VASCULAR DISEASES OF THE SPINAL CORD

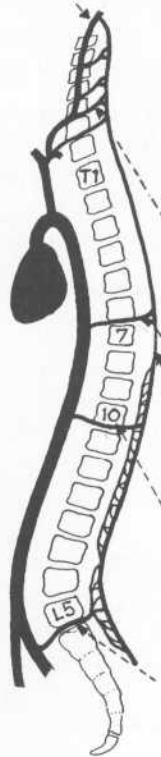
Blood supply to the spinal cord is complex; the main vessels are the anterior and posterior spinal arteries.

The posterior spinal arteries: usually arise from the posterior inferior cerebellar arteries and form a plexus on the posterior surface of the spinal cord.

The anterior spinal artery: branches from each vertebral artery unite to form a single vessel lying in the median fissure of the spinal cord.



Vertebral artery



Both anterior and posterior spinal arteries run the length of the spinal cord and receive anastomotic vessels.

The plexus of the posterior spinal artery is joined by approximately 12 *unpaired* radicular feeding arteries. This rich collateral circulation protects the posterior part of the spinal cord from vascular disease.

The anterior spinal artery has a much less efficient collateral supply and is thus more vulnerable to the effects of vascular disease. It is joined by 7–10 *unpaired* radicular branches, usually from the left side.

Cervical arteries arise from vertebral and subclavian vessels, form plexuses and supply the cervical and upper thoracic cord.

Intercostal artery branches supply the midthoracic cord.

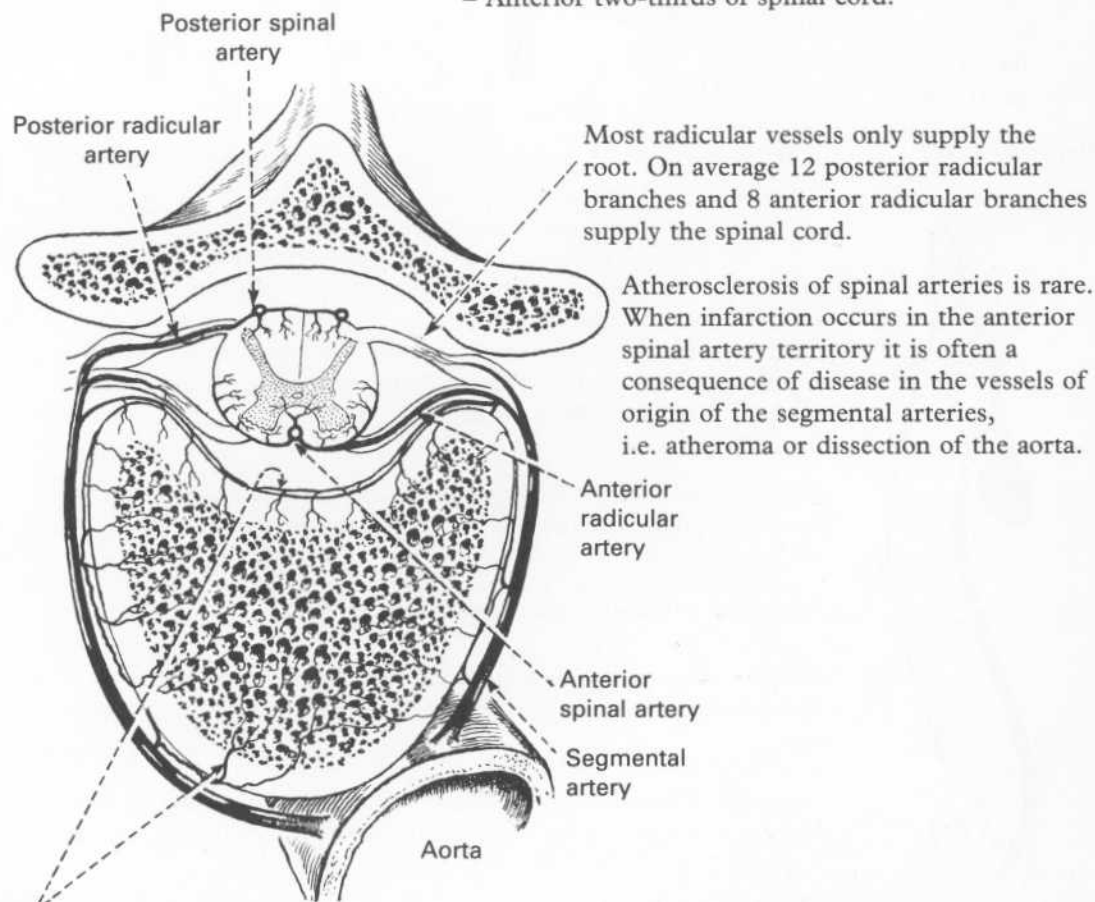
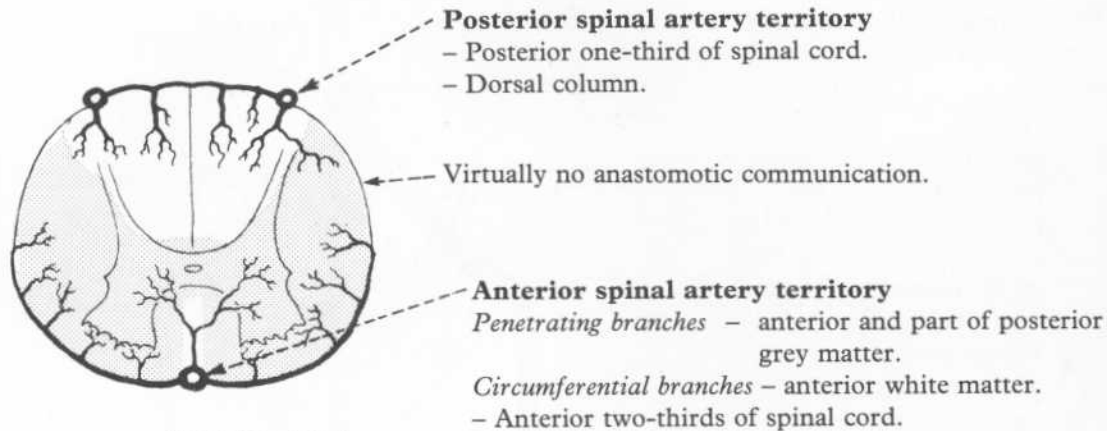
Anterior spinal artery is at its narrowest at T8. This level of the spinal cord is liable to damage during hypertension – watershed area.

Artery of Adamkiewicz, the largest radicular artery, supplies the low thoracic and lumbar cord. It usually arises at T9–L2 level and is on the left side in 70% of the population.

Sacral arteries arise from the hypogastric artery and supply the sacral cord and cauda equina.

Anterior radicular branches joining anterior spinal artery

VASCULAR DISEASES OF THE SPINAL CORD



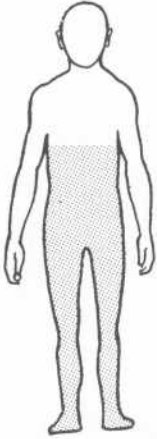
Rich anastomotic network occurs between each segmental artery through the vertebral body and across the extradural space

Section through spinal cord in thoracic region.

VASCULAR DISEASES OF THE SPINAL CORD

SPINAL CORD INFARCTION

Anterior spinal artery syndrome



The level at which infarction occurs determines symptoms and signs.

Characteristic features include:

- Radicular pain at onset
- Sudden para/quadruplegia
- Flaccid limbs $\xrightarrow{\text{days}}$ spastic
- Areflexia $\xrightarrow{\text{days}}$ hyper-reflexia and extensor plantar responses
- Sensory loss to pain and temperature up to the level of cord damage
- Preserved vibration and joint position sensation (dorsal columns supplied by the posterior spinal arteries)
- Urinary retention

When only penetrating branches are involved, long tract damage may be selective and sensory loss may be minor.

Spinal cord ischaemia due to aortic atheroma evolves slowly and preferentially affects anterior horn cells.

A pure conus syndrome (page 380) occasionally occurs.

Investigative approach

- *Exclude* other causes of acute para/quadruplegia – cord compression. Guillain Barré syndrome – by appropriate imaging or neurophysiology
- *Confirm* spinal ischaemia by MRI (T2 weighted imaging showing hyperintense signal changes)
- *Explore* possible sources of spinal ischaemia

Small vessel diseases

diabetes – random or fasting blood glucose

vasculitis – see pages 261-263

neurosyphilis – CSF VDRL and Captia G

endarteritis secondary to – CSF meningeal infection or granulomatous disease

aortic (large) vessel diseases

atheromatous – vascular risk factor e.g. cholesterol

embolic – echocardiography, blood cultures

thrombotic – coagulation screen

dissection/aneurysm – transoesophageal echo (TOE) angiography

hypotension – ECG, cardiac enzymes

Treatment is symptomatic and the outcome variable.

Posterior spinal artery syndrome

This is rare as white matter structures are less vulnerable to ischaemia. The dorsal columns are damaged and ischaemia may extend into the posterior horns.

Clinical features: – Loss of tendon reflexes/motor weakness

- Loss of joint position sense.

Venous infarction

A rapid 'total' cord syndrome with poor outcome often associated with pelvic sepsis.

VASCULAR DISEASES OF THE SPINAL CORD

SPINAL ARTERIOVENOUS MALFORMATION (Angiomatous malformation)

Arterio-venous malformations (AVMs) are congenital abnormalities of blood vessels rather than neoplastic growths. Arteries communicating directly with veins bypass the capillary network which has failed to develop, creating a 'shunt'. The AVM appears as a mass of convoluted dilated vessels.

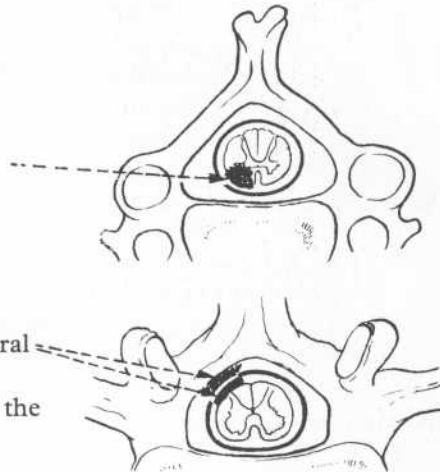
Site



Cervical: uncommon site (~15%)
Arises from the anterior spinal artery and usually lies within the cord substance (intramedullary).

Upper thoracic: (20%)

Thoracolumbar: this is the commonest site (~65%). It may be extra- or intradural or within both compartments. The main feeding vessels are often dural arteries of the spinal nerve roots (Dural fistula). Intramedullary lesions at this site are less common.



Spinal AVMs may present clinically at any age in either sex, but dural lesions are most common in males between 40–70 yrs of age.

Clinical features

SUDDEN ONSET (10–15%)

Due to – subarachnoid haemorrhage: headache, neck stiffness, back and leg pain
 – extradural haematoma
 – subdural haematoma
 – intramedullary haematoma (haematomyelia) } signs of acute cord damage.

GRADUAL ONSET (85–90%)

Probably due to ↑ *venous pressure* but other factors may play a part:

- venous thrombosis
- 'steal' phenomenon
- venous bulk
- arachnoiditis (if previous bleed).

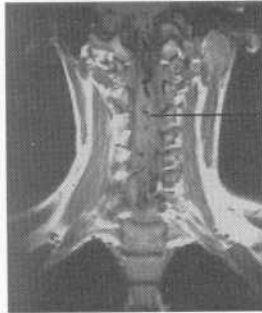
Progressive deterioration of all spinal modalities simulating cord compression. Pain is common. With thoracolumbar lesions a mixed u.m.n./l.m.n. weakness in the legs is typical. Intramedullary AVMs may cause fluctuating signs and symptoms and may mimic intermittent claudication.

A bruit may be heard overlying a spinal AVM and occasionally midline cutaneous lesions – haemangiomas, naevi or angioliomas – are found. (Note that cutaneous angiomas are not uncommon and do not necessarily imply an underlying lesion.)

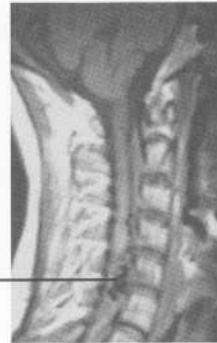VASCULAR DISEASES OF THE SPINAL CORD

Investigation

MRI will demonstrate abnormal signal from the lesion or from draining veins. *Myelography* will also demonstrate abnormal draining veins. *Selective angiography* is required to delineate arterial feeders.



Coronal MRI showing dilated draining veins



Corresponding sagittal MRI showing lesion at C5/6 level

Management

Untreated, 50% of patients with gradual onset of symptoms would be unable to walk within 3 years. Treatment should prevent progression and may well improve a gait or bladder disturbance. Delay may result in irreversible cord damage.

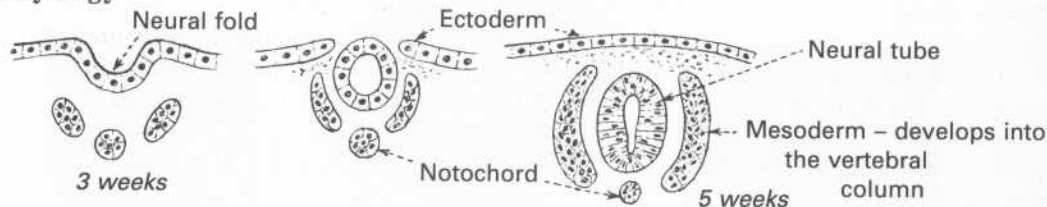
- Techniques:**
- Embolisation* – may successfully obliterate dural AVMs, particularly when fed by one or two dural arteries
 - may aid subsequent operative treatment
 - or may produce symptomatic improvement in inoperable lesions.
 - Surgery* – It is important to identify and divide the feeding vessel and excise the shunt. Total excision of all the dilated veins is probably unnecessary and would increase the operative hazards. A decompressive laminectomy alone is of no benefit. Intramedullary AVMs and/or AVMs lying ventral to the cord cannot be excised.

Spinal Epidural and Subdural Haematomas: These may present with a rapid onset of paraplegia. Epidural or less commonly, subdural haematoma may occur due to rupture of a spinal AVM, after minor trauma or lumbar puncture, or spontaneously in patients with a bleeding disorder, liver disease or on anticoagulant therapy. MRI (or myelography) clearly demonstrates the lesion. Urgent decompression is required after correcting any coagulation deficit, without waiting for spinal angiography. Pathological examination of the haematoma may reveal angiomatous tissue; in other patients, there is no evident cause.

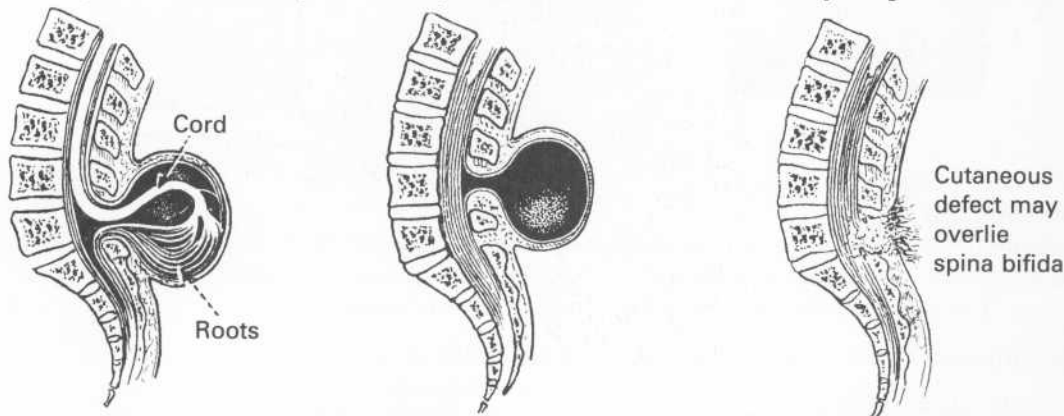
SPINAL DYSRAPHISM

SPINAL DYSRAPHISM: This term encompasses all defects (open or closed) associated with a failure of closure of the posterior neural arch.

Embryology



Developmental errors may occur early in fetal life and lead to a variety of spinal defects:



MYELOMENINGOCELE

The spinal cord and roots protrude through the bony defect and lie within a cystic cavity, lined with meninges and/or skin. In most patients, the meningeal covering ruptures and the spinal cord and roots lie exposed to the air – myelodysplasia. CSF may leak from the open lesion.

Site: 80% occur in the lumbosacral region.

Incidence: 2/1000 births in Britain, but there is a geographical variation (0.2/1000 in Japan). A familial incidence increases the risk (5% if a sibling is affected). This suggests a genetic factor, but teratogens, e.g. sodium valproate, also have a role.

MENINGOCELE

Cystic CSF filled cavity – lined with meninges but devoid of neural tissue. The cavity communicates with the spinal canal through the bone defect (usually lumbosacral). Meningoceles occur far less frequently than myelomeningocele; they are rarely associated with other congenital anomalies.

SPINA BIFIDA OCCULTA

A bony deficit – present in 5–10% of the population and not clinically significant. Those who also have a lumbosacral cutaneous abnormality however (*tuft of hair, dimple, sinus or 'port wine' stain*) have a high incidence of related underlying defects:

- *diastatomyelia*
- *lipoma*
- *dermoid cyst.*

These defects may cause symptoms of pain or neurological impairment after many years.

SPINAL DYSRAPHISM

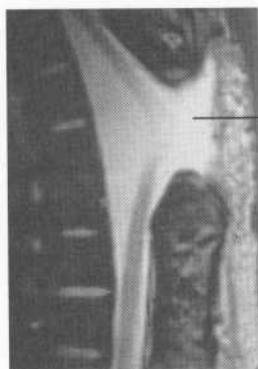
Clinical assessment

Myelomeningocele: This lesion should be carefully examined for the presence of neural elements. Transillumination of the sac may help. Observation of movement in the limbs and in specific muscle groups, occurring spontaneously and in response to pain applied both above and below the level of the lesion, helps determine the degree and level of neurological damage. Also note the presence of a dilated bladder and a patulous anal sphincter. Look for any associated congenital anomalies, e.g. hydrocephalus, scoliosis, foot deformities.

Meningocele: Patients with this lesion seldom show any neurological deficit.

Investigations

Ultrasound or *MRI* may detect neural elements extending into the sac.



MRI showing a thoracic myelomeningocele with spinal cord extending through the deficit.

Management

Myelomeningocele: Advances in both orthopaedic and urological procedures have considerably improved the long-term management of the associated disabilities in most patients. Active treatment, however, in patients with gross hydrocephalus, complete paraplegia and other multiple anomalies as well as the spinal dysraphism, may merely prolong a painful existence. In these patients, many adopt a thoughtful conservative approach.

Immediate treatment requires closure and replacement of the neural tissues into the spinal canal to prevent infection. If necessary, this initial step provides more time to consider the wisdom of embarking on further active management.

Meningocele: In the presence of a CSF leak, urgent excision is performed; otherwise this is deferred, perhaps indefinitely if the lesion is small.

Spina bifida occulta: Treatment may not be required, although patients with a cutaneous abnormality or with neurological signs, should undergo ultrasound or MRI to exclude an intraspinal anomaly.

Antenatal diagnosis

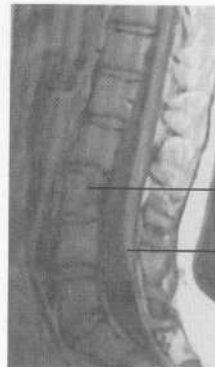Screening the maternal serum/amniotic fluid for alpha-fetoprotein and acetylcholinesterase, fetal ultrasonography and contrast enhanced amniography in high risk patients (e.g. with an affected sibling) provides an effective method of detecting neural tube defects. This gives the parents the possibility of therapeutic abortion and in the long term may reduce the incidence of this condition.

SPINAL DYSRAPHISM

TETHERED CORD: in some patients the conus medullaris lies well below its normal level (L1), 'tethered' by the filum terminale. Since vertebral growth proceeds more rapidly than growth of the spinal cord, tethering may produce progressive back pain or neurological impairment as the cord is stretched.

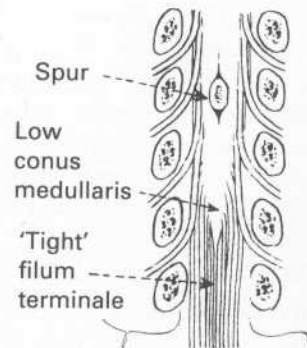
DIASTOMATOMYELIA: A congenital splitting of part of the spinal cord by a *bony, fibrous or cartilaginous spur*. This usually lies at the upper lumbar region and extends directly across the spinal canal in an antero-posterior direction. The split cord does not always reunite distal to the spur (diplomylelia).

Investigation: MRI is the investigation of choice in spinal dysraphism, but straight X-ray may reveal associated congenital abnormalities: spina bifida occulta, fused or hemivertebrae. CT scanning may help demonstrate the presence of a bony spur.



T1 weighted MRI

Butterfly vertebra (congenital anomaly)
Conus medullaris extending down to L4 due to tethering



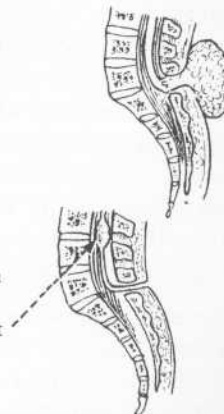
Management: Although some recommend prophylactic division of the tethered filum terminale in the absence of neurological impairment, most reserve operative treatment for those who present with a neurological deficit, especially if there is evidence of progression, or prior to correction of any spinal deformity. In contrast, prophylactic removal of the spur in patients with diastomatomyelia is usually performed, even in the absence of neurological impairment.

LIPOMENINGOCELE

Lipomas may occur in association with spinal dysraphism and range from purely intraspinal lesions to very large masses extending along with neural tissues through the bony defect. All are adherent to the conus and closely related to the lumbosacral roots, preventing complete removal and increasing operative hazards.

CONGENITAL DERMAL SINUS TRACT/DERMOID CYST

This congenital defect results from a failure of separation of neuronal from epithelial ectoderm and may occur with other midline fusion defects, e.g. diastomatomyelia and a tethered cord. A tiny sinus in the lumbosacral region may represent the opening of a blind ending duct or may extend into the spinal canal. Dermoid cysts arise at any point along the sinus tract and often lie adjacent to the conus.



Clinical presentation varies from repeated attacks of unexplained meningitis to neurological deficits arising from the presence of an intraspinal mass. Treatment involves excision of the whole tract and any associated cyst (after treating any meningitic infection).

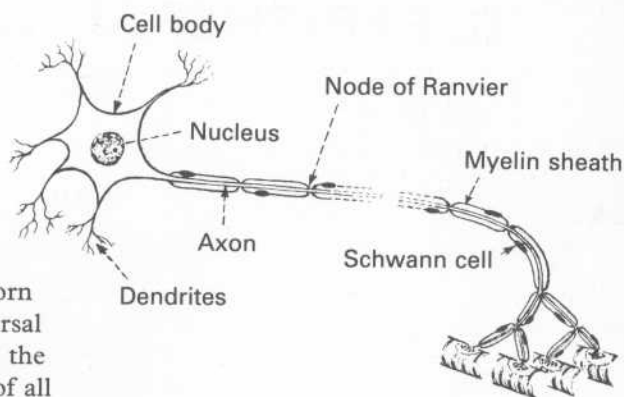
**LOCALISED NEUROLOGICAL DISEASE
AND ITS MANAGEMENT
C. PERIPHERAL NERVE AND MUSCLE**

THE POLYNEUROPATHIES – FUNCTIONAL ANATOMY

The function of the peripheral nervous system is to carry impulses to and from the central nervous system. These impulses regulate motor, sensory and autonomic activities.

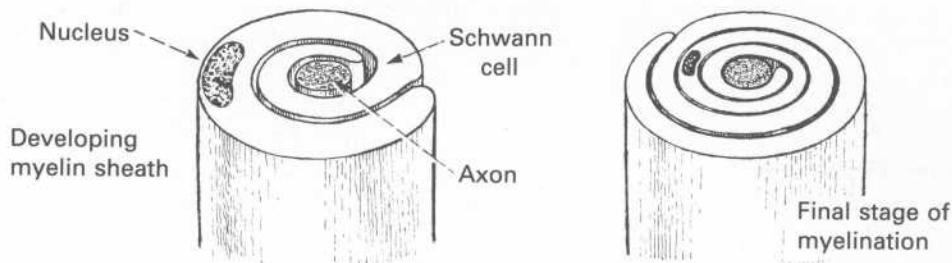
The peripheral nervous system is comprised of structures that lie outside the pial membrane of the brainstem and spinal cord and can be divided into cranial, spinal and autonomic components.

STRUCTURE OF THE NERVE CELL AND AXON



Each axon represents an elongation of the nerve cell – this lying within the central nervous system, e.g. anterior horn cell, or in an outlying ganglion, e.g. dorsal root ganglion. The cell body maintains the viability of the axon, being the centre of all cellular metabolic activity.

Many axons are surrounded by an insulation of myelin, which is enveloped by the Schwann cell membrane. Myelin is a protein-lipid complex. The membrane of the Schwann cell 'spirals' around the axon resulting in the formation of a multilayered myelin sheath.



All axons have a cellular sheath – Schwann cell – but not all axons are myelinated.

Schwann cells with associated myelin are 250–1000 μm in length and separated from each other by the node of Ranvier. The axon is bare at this node and, during conduction, impulses jump from one node to the next – *saltatory* conduction. The rate of conduction in myelinated nerves is markedly increased in comparison with unmyelinated fibres. Myelin thus facilitates fast conduction. In unmyelinated fibres conduction depends upon the diameter of the nerve fibre, this determining the rate of longitudinal current flow.

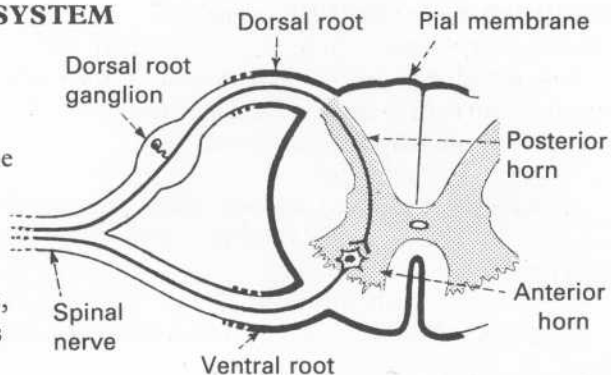
THE POLYNEUROPATHIES – FUNCTIONAL ANATOMY

SPINAL PERIPHERAL NERVOUS SYSTEM

Entry to and exit from the central nervous system is achieved by paired spinal nerve roots (30 in all).

These dorsal and ventral roots lie in the spinal subarachnoid space and come together at the intervertebral foramen to form the spinal nerve.

The dorsal root contains sensory fibres, arising from specialised sensory receptors in the periphery.



The dorsal root ganglia are collections of sensory cell bodies with axons extending peripherally as well as a central process which passes into the spinal cord in the region of the posterior horn of grey matter and makes appropriate central connections.

Sensation can be divided into:

- Pain and temperature
- Simple touch
- Discriminatory sensation – proprioception, vibration.

These different forms of sensation are carried from the periphery by axons with specific characteristics. The central connections and pathways vary also (see page 196).

The anterior horns of the spinal cord contain cell bodies whose axons pass to the periphery to innervate skeletal muscle – the alpha motor neurons. Smaller cell bodies also project into the anterior root and innervate the intrafusal muscle fibres of muscle spindles – the gamma motor neurons.

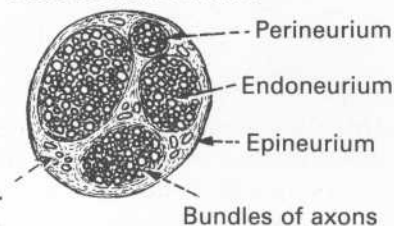
Each alpha motor neuron through its peripheral ramifications will innervate a number of muscle fibres. The number of fibres innervated from a single cell varies from less than 20 in the eye muscles to more than 1000 in the large limb muscles (innervation ratio). The alpha motor neuron with its complement of muscle fibres is termed the *motor unit*.

PERIPHERAL NERVES

Peripheral nerves are composed of many axons bound together by connective tissue. A 'mixed' nerve contains motor, sensory and autonomic axons.

The blood supply to these bundles is by means of small nutrient vessels within the epineurium – the *vasa nervorum*.

Cross section of nerve



THE POLYNEUROPATHIES – FUNCTIONAL ANATOMY

PERIPHERAL NERVES (*contd*)

Nerve fibre type

Axons within the peripheral nerve vary structurally. This is related to function. Three distinct fibre types can be distinguished:

TYPE A 2–20 μm in diameter.
Myelinated.

Function: Motor and sensory (vibration, proprioception).
Conduction velocity: 10–70 metres/second.

TYPE B 3 μm diameter.
Thinly myelinated.

Function: Mainly preganglionic autonomic, some pain and temperature.
Conduction velocity: 7–5 metres/second.

TYPE C < 1 μm diameter
Unmyelinated.

Function: Sensory – pain and temperature.
Conduction velocity: < 2 metres/second.

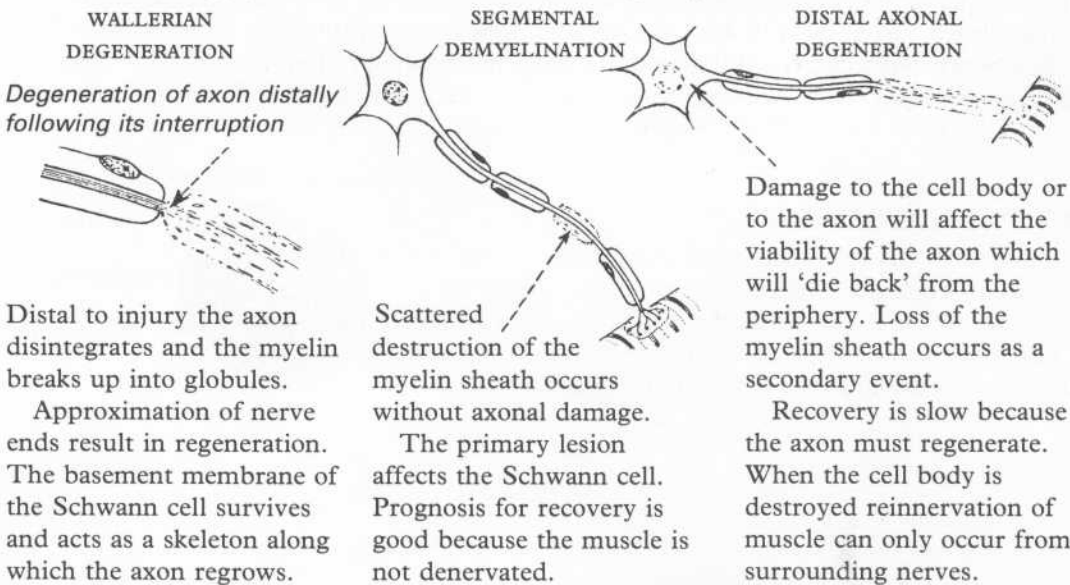
The structure of the spinal peripheral nervous system has been considered but the arrangement is also important. Spinal nerves, after emerging from the intervertebral foramen pass into the brachial plexus to supply the upper limbs and the lumbosacral plexus to supply the lower limbs.

The thoracic nerves supply skeletal muscles and subserve sensation of the thorax and abdomen.

The Autonomic Nervous System is described on page 441.

PATTERNS OF INJURY

Damage may occur to: axon, myelin sheath, cell body, supporting connective tissue and nutrient blood supply to nerves. Three basic pathological processes occur.



Distal to injury the axon disintegrates and the myelin breaks up into globules.

Approximation of nerve ends result in regeneration. The basement membrane of the Schwann cell survives and acts as a skeleton along which the axon regrows.

Scattered destruction of the myelin sheath occurs without axonal damage.

The primary lesion affects the Schwann cell. Prognosis for recovery is good because the muscle is not denervated.

Damage to the cell body or to the axon will affect the viability of the axon which will 'die back' from the periphery. Loss of the myelin sheath occurs as a secondary event.

Recovery is slow because the axon must regenerate. When the cell body is destroyed reinnervation of muscle can only occur from surrounding nerves.

THE POLYNEUROPATHIES – SYMPTOMS

Sensory

Negative phenomena – loss of sensation.

Disease of *large myelinated fibres* produces loss of touch and joint position perception.

Patients complain of difficulty in discriminating textures. Their hands and feet feel like cotton wool. Gait is unsteady, especially when in darkness where vision cannot compensate for loss of joint position sensation (proprioception).

Disease of *small unmyelinated fibres* produces loss of pain and temperature appreciation as a consequence of which painless burns/trauma result. Damage to joints without pain results in a 'neuropathic' joint (Charcot's joint) in which traumatic deformity is totally painless.

Positive phenomena

Disease of *large myelinated fibres* produces paraesthesia – a 'pins and needles' sensation with a peripheral distal distribution.

Disease of *small unmyelinated fibres* produces painful positive phenomena:

- Burning extremities
- Dysaesthesia – when touching is painful
- Hyperalgesia – when threshold to pain appears lowered
- Hyperpathia – when threshold to pain appears elevated but, once reached, the painful stimulus is excessively felt.

Lightning pains take the form of sudden, very severe shooting pains and are virtually pathognomonic for tabes dorsalis.

Causalgia results from nerve trauma. A spontaneous burning sensation in the distribution of the injured nerve is associated with an increased sensitivity to painful stimulation.

Motor

The patient notices weakness:

- When distal, e.g. difficulty in clearing the kerb when walking
- When proximal, e.g. difficulty in climbing stairs or combing hair
- Cramps may be troublesome
- Twitching of muscles (fasciculation) may be felt.

THE POLYNEUROPATHIES – SIGNS

SENSORY EXAMINATION

All modalities are tested
 Light touch
 Two point discrimination
 Vibration sensation
 Joint position perception
 Temperature perception
 Pain perception.

} Functions of large myelinated sensory fibres.

} Functions of small unmyelinated and thinly myelinated sensory fibres.

Initially the area of total sensory loss is defined. The test object, e.g. a pin, should be moved from anaesthetic to normal area; it is more accurate to state when an object is felt rather than when it disappears.

In polyneuropathies, sensory loss is symmetrical and follows a characteristic stocking and glove distribution.

Examination of gait is important; with joint position impairment, sensory ataxia is evident. Romberg's test is positive (see page 187). Neuropathic burns/ulcers or joints may be present.

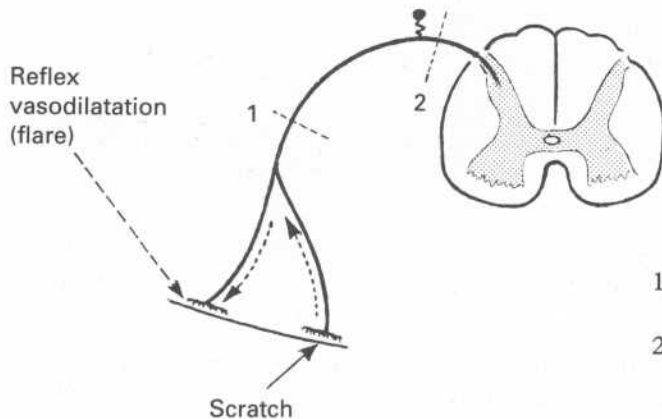
Trophic changes

- Cold blue extremities.
- Cutaneous hair loss.
- Brittle finger/toe nails occasionally occur.

The AXON REFLEX can be used to 'place' lesions in the sensory pathway.

Normally:

the skin is scratched – local vasoconstriction (white reaction) } due to local
 next – local oedema (red reaction) } histamine release.
 and finally – surrounding vasodilatation or flare, dependent on antidromic impulses from the dorsal root ganglion along an intact sensory neuron.



1. A distal sensory lesion will result in an absent flare response.
2. A proximal root lesion will not impair the response.

THE POLYNEUROPATHIES – SIGNS

MOTOR EXAMINATION

Muscle wasting. Evident in axonal but absent in demyelinating neuropathies. Oedema of immobile limbs may mask wasting. The 1st dorsal interosseus muscle in the upper limbs and extensor digitorum brevis in the lower limbs are muscles that commonly first show wasting in the neuropathies, but examine all muscle groups. Look for *fasciculations* – irregular twitches of groups of muscle fibres due to diseased anterior horn cells, these may be induced by exercise or muscle percussion.

Muscle weakness. The degree of weakness is 'scored' using the MRC (Medical Research Council) scale.

- Score 0 – No contraction
- Score 1 – Flicker
- Score 2 – Active movement/gravity eliminated
- Score 3 – Active movement against gravity
- Score 4 – Active movement against gravity and resistance
- Score 5 – Normal power

Weakness is proportional to the number of affected motor neurones. It develops suddenly or slowly and is generally symmetrical, usually starting distally in the lower limbs and spreading to upper limbs in a similar manner before ascending into proximal muscle groups. This pattern of progression is supposedly due to the 'dying back' of axons towards their nerve cells – the longest being the most vulnerable.

Some neuropathies, e.g. Guillain Barré, chronic inflammatory demyelinating polyneuropathy, may affect proximal muscle groups first.

In severe neuropathies, truncal and respiratory muscle involvement occurs. Respiratory muscle weakness may result in death.

Tendon reflexes

The tendon reflex depends on:

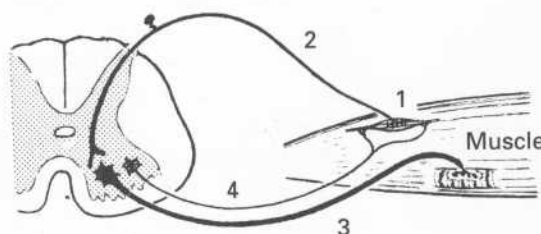
- stretch of the muscle spindle (1),
- activation of spindle afferent fibres (2),
- monosynaptic projections to the alpha motoneurons (3)

The gamma motoneuron fibres, projecting to the spindle (4) 'modulate' activity in the reflex loop.

Reflexes commonly tested:

Deltoid	– C5,6 – Circumflex nerve	Triceps	– C6,7,8 – Radial nerve
Biceps	– C5,6 – Musculocutaneous nerve	Knee	– L2,3,4 – Femoral nerve
Supinator	– C6,7 – Radial nerve	Ankle	– S1,2 – Sciatic nerve

The tendon reflexes are lost when any component of the reflex response is affected by disease. Reflexes are lost early in peripheral neuropathies when power and muscle bulk appear normal. Distal reflexes are generally lost before proximal ones.



THE POLYNEUROPATHIES – CLASSIFICATION

There are several approaches to classification:

by **MODE of ONSET** – acute, subacute, chronic

by **FUNCTIONAL DISTURBANCE** – motor, sensory, autonomic, mixed

by **PATHOLOGICAL PROCESS** – axonal, demyelinating

by **CAUSATION** – e.g. infections; carcinomatous, diabetic, inflammatory, vascular

by **DISTRIBUTION** – e.g. symmetrical, asymmetrical; proximal, distal.

Clinically it is of most value to classify the neuropathies according to mode of onset.

The following table is for reference. Certain neuropathies will be dealt with separately (see pages 424–428).

ACUTE	CAUSE	FUNCTIONAL DISTURBANCE	PATHOLOGY
A few days-4 weeks	Inflammatory ——— (Postinfectious Guillain-Barré)	Predominantly motor Distal or proximal Autonomic disturbance	Demyelinative with perivascular lymphocytic infiltration
	Diphtheria ———	Cranial nerve onset Mixed motor/sensory	Demyelinative. No inflammatory infiltration.
	Porphyria ———	Motor (may begin in arm). Autonomic disturbance Minimal sensory loss.	Axonal
SUBACUTE	Drug-induced		
Develop over weeks	Isoniazid	Usually mild sensory motor disturbance	Axonal degeneration
	Metronidazole		
	Dapsone	Dapsone – pure motor involvement	
	Nitrofurantoin		
	Cisplatin		
	Vincristine etc.		
	Intramuscular injection	Localised neuropathies	
	Environmental toxins ———	Occasionally acute	Lead-axonal degeneration with segmental demyelination. Other heavy metals and solvents produce axonal degeneration
	Solvents	Usually sensory, motor disturbance; severity related to dose	
	Lead	Lead – severe, predominantly motor with arms involved first	
Acrylamide			
Carbon disulphide			
Hexocarbons			
Organophosphates			
Nutritional ———	Sensory disturbance with 'burning feet' and other painful dysaesthesiae	Axonal degeneration with segmental demyelination. (Demyelination is minimal in alcoholic neuropathy)	
Deficiency B complex (includes alcoholic neuropathy)	Motor component may be present and severe Autonomic disturbance is common but mild		
Substance abuse ———	Sensory, (facial numbness) motor disturbance	Axonal degeneration	
Solvents	Peripheral nerve lesion and plexopathies		
Heroin			

THE POLYNEUROPATHIES – CLASSIFICATION

CHRONIC	CAUSE	FUNCTIONAL DISTURBANCE	PATHOLOGY
Develop over months, years	Malignant disease —	Sensory or sensory/motor disturbance	Axonal degeneration
	Carcinoma	May predate recognition of malignancy by some years	
	Lymphoma		
	Paraproteinaemias —	Sensory/motor disturbance	Axonal or demyelinating degeneration
	e.g. Monoclonal gammopathies (IgG, IgA, IgM)		
	Connective tissue disorders —	In rheumatoid arthritis multiple mononeuropathy is common	Occlusion of nutrient blood vessels to nerves (vasa nervorum)
	Rheumatoid arthritis	Motor/sensory disturbance is rare	
	Systemic lupus erythematosus	Systemic lupus erythematosus – mild motor/sensory disturbance	
	Polyarteritis nodosa	Polyarteritis nodosa usually produces multiple mononeuropathy	
	Sclerodema		
	Amyloid disease —	Motor/sensory disturbance with autonomic involvement	Thickened nerves with amyloid deposition as well as small fibre axonal degeneration
	Primary, familial or secondary	Also may develop 'entrapment' neuropathies	
	Metabolic disorders —	Uraemic neuropathy is sensory/motor in type.	Axonal degeneration
	Uraemia		
	Hypothyroidism	Hypothyroidism produces mild sensory/motor disturbance.	
	Diabetes	Diabetic neuropathy takes many forms	
	Chronic inflammatory demyelinating polyneuropathy (CIDP) —	Sensory, motor disturbance	Demyelination
	Hereditary neuropathies		
	Refsum's disease	A phytanic acid storage disorder. Onset in first decade and slowly progressive. A severe sensorimotor neuropathy with associated cerebellar ataxia, ichthyosis, pigmentary retinal degeneration, deafness and cardiac abnormalities. Elevated serum phytanate	Schwann cell hyperplasia – hypertrophic neuropathy
	Hereditary motor and sensory neuropathy (HMSN)	See page 428	

INVESTIGATION OF NEUROPATHY

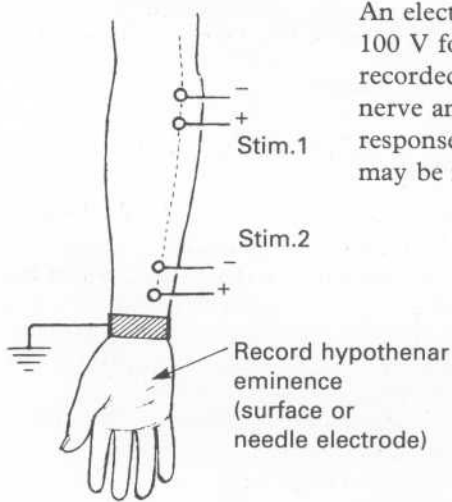
Despite extensive investigation, the cause of chronic neuropathy cannot be identified in 30% of such cases.

The following conditions require exclusion before a chronic neuropathy is classified as idiopathic or of unknown aetiology: diabetes, uraemia, deficiency states, connective tissue disorders, paraproteinaemias, underlying malignancy, drugs and toxins. Hereditary disease can sometimes be excluded by clinical examination and genetic analysis of relatives.

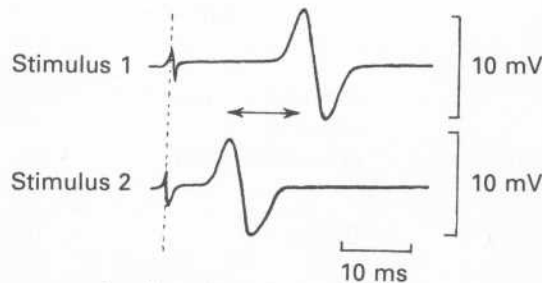
The cause of acute or subacute neuropathy can usually be defined. Here, CSF examination may prove a useful diagnostic investigation, e.g. Guillain-Barré syndrome.

SPECIAL INVESTIGATIONS

1. Nerve conduction studies



An electrical stimulus is applied at points along a nerve (20–100 V for 0.05–0.1 ms) and the evoked muscle response recorded. By applying a stimulus at various points along a nerve and recording the latency between stimulus and muscle response the motor conduction velocity of a particular nerve may be measured.



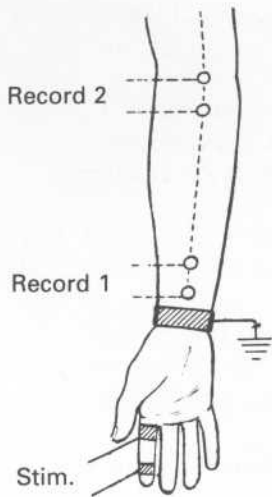
$$\text{Conduction velocity} = \frac{\text{Distance between two stimuli}}{\text{Difference in conduction time between the two sites}}$$

Motor conduction velocity can be measured in most motor peripheral nerves from the brachial plexus in the upper limbs and sciatic and femoral outlets in the lower limbs.

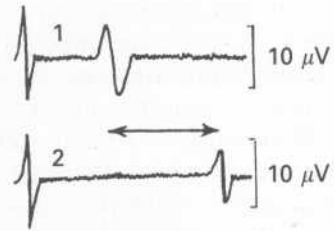
These studies not only aid in the diagnosis of generalised neuropathies but also in entrapments, e.g. ulnar nerve at elbow or median nerve at wrist (carpal tunnel syndrome).

INVESTIGATION OF NEUROPATHY

Sensory conduction can also be measured:



The index finger is stimulated and the evoked sensory potential recorded at wrist and elbow. Measurements enable calculation to be made of the latencies and conduction velocity. Note the considerable difference in amplitude between sensory and motor evoked potentials.



$$\text{Conduction velocity} = \frac{\text{Distance between two recording sites}}{\text{Difference in latency between the two evoked responses.}}$$

GENERAL OBSERVATIONS

Amplitude of response – a function of the number of axons which respond to stimulation.

Latency of response – a function of the speed at which the largest fibres in a nerve will conduct.

Axonal degeneration → *reduced amplitude or absence of response* to stimulation with mild slowing of conduction velocity.

Demyelinative disorders → *marked slowing of conduction velocity (30% at least reduced) with progressive reduction of amplitude.*

Localised compression of nerve → slowing of conduction in region of block, e.g. over the elbow when ulnar nerve is compressed at that site. Conduction block, distant from entrapment sites may suggest multifocal motor neuropathy (see page 427).

2. Electromyography

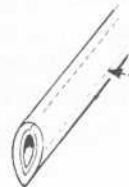
A fine needle is inserted into the muscle and the recorded activity displayed on an oscilloscope. Electromyography is primarily of value in muscle disease but can also give indirect evidence of a neuropathic process. The presence of denervation in paraspinal muscles indicates proximal nerve root disease.

If chronic denervation has occurred, reinnervation may be present with long duration high amplitude motor unit potentials.

Also, with voluntary efforts, poor recruitment of motor units is seen on the oscilloscope screen.

3. Nerve biopsy

A biopsy is most likely to aid diagnosis in asymmetric multiple mononeuropathies (vasculitis, amyloidosis, sarcoidosis etc). The sural nerve is usually chosen, provided its sensory conduction is abnormal.



The concentric needle has at its centre an insulated wire and potential differences between the centre and outer casing are measured

2mV Normal

Reinnervation

Long duration, high amplitude, polyphasia

THE POLYNEUROPATHIES – SPECIFIC TYPES

ACUTE INFLAMMATORY POSTINFECTIOUS POLYNEUROPATHY (GUILLAIN-BARRÉ SYNDROME)

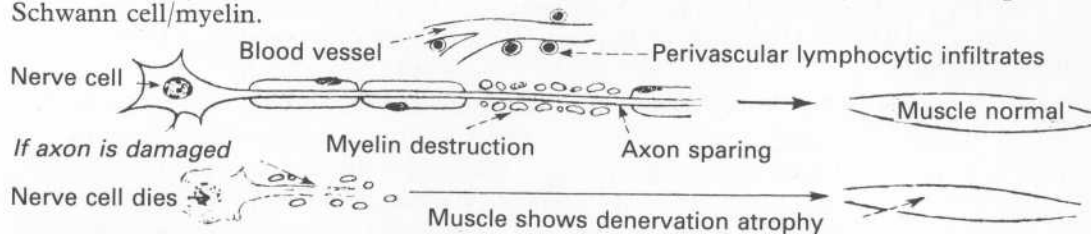
Incidence: 2 per 100 000 population per year. Characteristically it occurs 1–3 weeks after a viral or other infection or immunisation.

Aetiology/pathology

The condition may follow viral infection, e.g. varicella-zoster, mumps and cytomegalovirus. It is also associated with *Mycoplasma*, *Salmonella*, *Campylobacter* infections, immunisations with both live and dead vaccines, antitoxins, trauma, surgery and, rarely, malignant disease and immunodeficiency.

Both antibody and cell-mediated reactions to peripheral nerve myelin are involved. Some patients produce antibodies to myelin glycoproteins or gangliosides others develop a T cell-mediated assault on myelin basic protein.

Segmental demyelination results with secondary axonal damage if the process is severe. Perivascular infiltration with lymphocytes occurs within peripheral nerves and nerve roots. Lymphocytes and macrophages release cytotoxic substances (cytokines) which damage Schwann cell/myelin.



When axon damage and nerve cell death occur, regeneration cannot take place.

Clinical features

Sensory symptoms predominate at the beginning with paraesthesia of the feet, then hands. Pain, especially back pain, is an occasional initial symptom. Weakness next develops – this may be generalised, proximal in distribution or commence distally and ascend. In severe cases, respiratory and bulbar involvement occurs. Weakness is maximal three weeks after the onset. Tracheostomy/ventilation is required in 20% of cases. Facial weakness is present to some extent in 50% of cases. Papilloedema may occur when CSF protein is markedly elevated (blocked arachnoid villi?). Autonomic involvement – tachycardia, fluctuating blood pressure, retention of urine – develops in some cases.

Sensory signs are uncommon.

Investigations

CSF protein is elevated in most patients but often not until the second or third week of illness. Cells are usually absent but in 20% up to 50 cells/mm³ may be found.

Nerve conduction studies

When carried out early in the illness, these may be normal. Findings of multifocal demyelination soon develops with slowing of motor conduction, conduction block and prolonged distal motor latencies.

Ancillary investigations

Performed to identify any precipitating infection: e.g. viral studies. Electrolytes are checked for inappropriate secretion of antidiuretic hormone and immune complex glomerulonephritis.

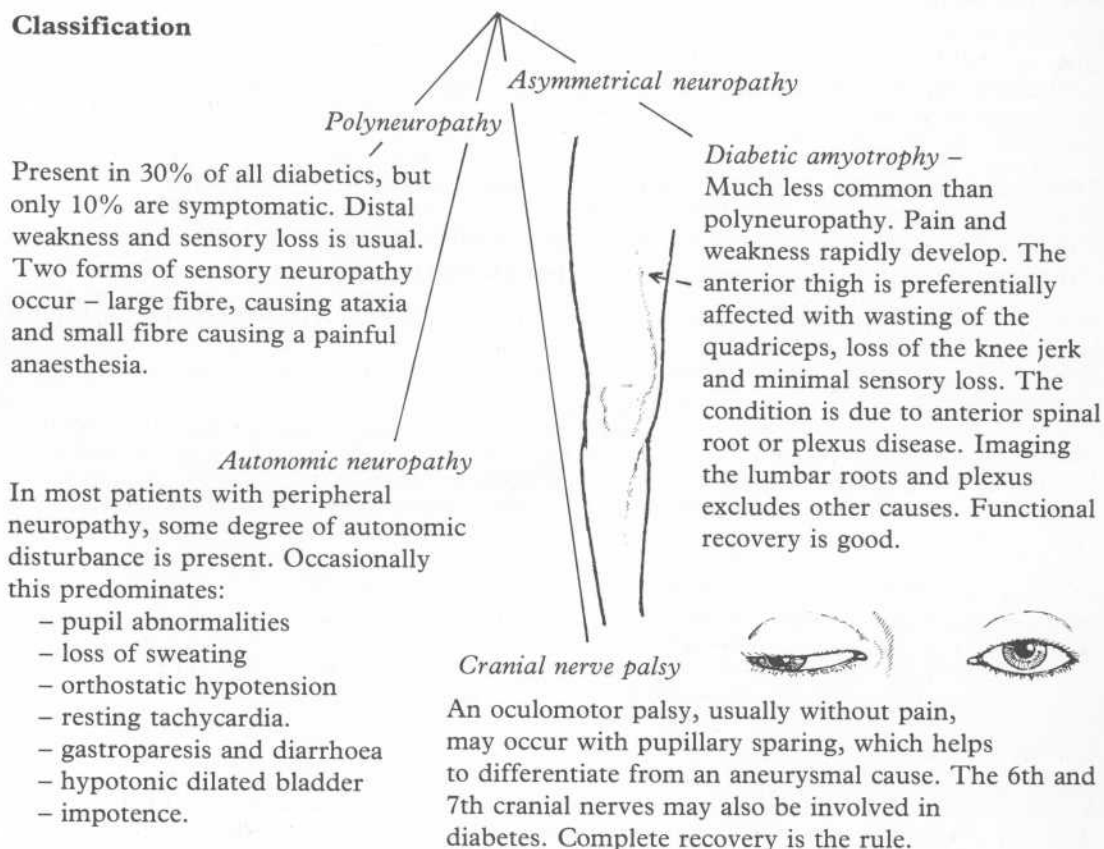
THE POLYNEUROPATHIES – SPECIFIC TYPES

DIABETIC NEUROPATHY

This condition is uncommon in childhood and increases with age.

Peripheral nerve damage is related to poor control of diabetes. This is more common in insulin-dependent patients. Damage results from either metabolic disturbance with sorbitol and fructose accumulation in axons and Schwann cells or an occlusion of the nutrient vessels supplying nerves (*vasa vasorum*). The frequent occurrence of neuropathy with other vascular complications – retinopathy and nephropathy – suggests that the latter is the more usual mechanism. Neurological complications correlate with levels of glycosylated haemoglobin A1C, an indicator of the long-term control of hyperglycaemia.

Classification



Treatment

Improved control of diabetes is essential.

Carbamazepine, antidepressants or α -adrenergic blockers, e.g. phenoxybenzene, help control pain.

Drugs which reduce aldose reductase and halt accumulation of sorbitol and fructose in nerves are being evaluated.

Management of autonomic neuropathy – see page 444.

Asymmetrical neuropathies usually spontaneously recover, whereas prognosis for symmetric neuropathies is less certain.

THE POLYNEUROPATHIES – SPECIFIC TYPES

CARCINOMATOUS POLYNEUROPATHY

Sensory or mixed 'sensorimotor' neuropathy is often associated with malignant disease, particularly small cell carcinoma of the lung. Neuropathy may also occur with Hodgkin's disease and lymphomas. The neuropathy is characterised by the presence of antibodies (anti Hu) that are detected in serum. Such antibodies not only recognise antigen in tumours but also bind to peripheral nervous system neurones.

Pathology

The sensory type is characterised by degeneration and inflammatory changes in the dorsal root ganglion. The ventral roots and peripheral nerve motor fibres are spared. In the sensorimotor type, degeneration of the dorsal root ganglion is less marked and axonal and demyelinating changes affect motor and sensory fibres equally.

Clinical features

Symptoms and signs may predate the appearance of causal malignant disease by months or even years.

Sensory neuropathy: Progressive sensory loss often commencing in upper limbs is associated with paraesthesia, unpleasant 'burning' dysaesthesia and sensory ataxia.

Sensorimotor neuropathy: The onset is gradual with distal sensory loss and mild motor weakness. Occasionally a more acute, severe neuropathy resembling Guillain-Barré syndrome occurs.

Detection and treatment of the underlying malignancy may lead to recovery of the neuropathy. Alternatively the use of immunosuppressive agents, plasma exchange or intravenous gammaglobulin (IVIG) may help.

MULTIFOCAL MOTOR NEUROPATHY WITH CONDUCTION BLOCK

This presents with asymmetric lower motor neurone weakness and may be mistaken for motor neurone disease. Neurophysiological investigation shows 'conduction block' at sites distant from possible entrapment. Antibodies to gangliosides (Anti GM1) are found in serum. Immunosuppressive treatment (cyclophosphamide) or intravenous immunoglobulin (IVIG) when indicated, result in clinical improvement.

NEUROPATHIES ASSOCIATED WITH PARAPROTEINS

Approximately 10% of patients with chronic peripheral neuropathy have a circulating monoclonal paraprotein in the serum. If myeloma, lymphoma, amyloidosis and Waldenström's macroglobinaemia are excluded, the condition is referred to as a 'monoclonal gammopathy of uncertain significance' (MGUS). IgM is reactive against myelin associated glycoprotein. IgA and IgB are not. Neuropathies may be axonal, demyelinating or mixed and show a variable response to immunotherapy.

PORPHYRIA

Acute intermittent porphyria is an autosomal dominant disorder in which symptoms of abdominal pain, psychosis, convulsions and peripheral neuropathy occur.

The metabolic fault occurs in the liver. An increased production of porphobilinogen is reflected by its increased urinary excretion. δ -amino laevulinic acid, a porphyrin precursor, is also increased.

Clinical features

The onset is acute and predominantly motor with upper limb and occasional cranial nerve involvement. Respiratory failure occurs in severe cases. Autonomic involvement with tachycardia, blood pressure changes, abdominal pain and vomiting often develop. The neuropathy must be distinguished from Guillain-Barré.

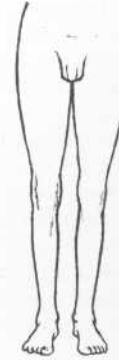Clinical course is variable. Spontaneous recovery occurs over several weeks. Respiratory failure will require ventilation and carries a poor prognosis. During an attack, a high carbohydrate diet and prevention and treatment of electrolyte disturbances are essential. Chelating agents (EDTA or Penicillamine) are used in severe cases. Recurrent attacks may be anticipated. Certain drugs may precipitate these attacks and must be avoided, e.g. sulphonamides, barbiturates, phenytoin, griseofulvin.

THE POLYNEUROPATHIES – SPECIFIC TYPES – INHERITED NEUROPATHIES

HEREDITARY MOTOR SENSORY NEUROPATHY (HMSN) (Charcot – Marie – Tooth)

A heterogeneous group of disorders with a prevalence of 1:2500 – the largest category of genetic neurological disease. The characteristic appearance is that of distal wasting. The lower limbs having an 'inverted wine bottle' appearance.

Classification	Clinical features	Pathology	Neuro-physiology	Inheritance
HMSN type I	Age of onset < 30 yrs. Wasting and weakness of intrinsic foot muscles, peroneal and tibial groups. Distal upper limb involvement. Pes cavus/hammer toes – 75%. Palpable peripheral nerves – 25%. Associated ataxia and tremor – 10%.	Demyelination with thickened 'onion bulb' areas of remyelination.	Motor conduction velocities slowed < 38 m/sec in common peroneal nerve.	<i>Autosomal dominant</i> duplication or point mutation chromosome 1 or chromosome 17 or <i>X linked</i> – Point mutation proximal long arm of X chromosome.
HMSN type II	Age of onset > 30 yrs. Wasting and weakness as type I. Foot deformities absent. Peripheral nerves not palpable.	Axonal loss.	Motor conduction velocities normal or marginally slowed.	<i>Autosomal dominant</i> – mechanism and gene locus unknown.
HMSN type III (Dejerine – Sottas disease)	Age of onset: childhood. Wasting and weakness may be proximal. Peripheral nerves and spinal roots thickened. CSF protein elevated.	Demyelination with 'onion bulb' formation.	Motor conduction velocities profoundly slowed – 5–10 m/sec.	<i>Autosomal recessive</i> – point mutation chromosome 1 or 17 or <i>sporadic</i>



Complex forms of HMSN occur. Several pedigrees show additional features such as – optic atrophy, retinopathy, deafness, ataxia, spasticity and cardiomyopathy. Such 'extra' features complicate a simple classification. Treatment is symptomatic with provision of appropriate footwear, splints or orthopaedic procedures to maintain mobility. In adult onset disease, the rate of progression is exceedingly slow. The demonstration of genetic markers and the application of nerve conduction studies allows early and correct diagnosis in those at risk. Nerve biopsy is of no diagnostic value.

Other rare forms of hereditary neuropathy

- *Hereditary sensory and autonomic neuropathies* – Autosomal recessive
Childhood onset
Characterised by insensitivity to pain and disordered sweating
- *Hereditary liability to pressure palsies* – Autosomal dominant
Adult onset
Characterised by recurrent entrapment neuropathies e.g. carpal tunnel syndrome
- *Hereditary neuropathy with spinocerebellar degeneration* – e.g. *Friedrich's ataxia* (pages 532–533)
- *Hereditary neuropathy with metabolic defect* – e.g. Familial amyloid neuropathy – mutation of transthyretin gene
Porphyria – abnormality of hepatic haem biosynthesis
Refsums disease – abnormality of phytanic acid metabolism.

PLEXUS SYNDROMES AND MONONEUROPATHIES

Disease of a single peripheral or cranial nerve is termed *mononeuropathy*. When many single nerves are damaged one by one, this is described as *mononeuritis multiplex*. Damage to the brachial or lumbosacral plexus may produce widespread limb weakness which does not conform to the distribution of any one peripheral nerve. A knowledge of the anatomy and muscle innervation of the plexuses and peripheral nerves is essential to localise the site of the lesion and thus deduce the possible causes.

Certain systemic illnesses are associated with the development of mononeuropathy or mononeuritis multiplex:

- diabetes mellitus
- sarcoidosis
- rheumatoid arthritis
- polyarteritis nodosa.

Entrapment mononeuropathies result from damage to a nerve where it passes through a tight space such as the median nerve under the flexor retinaculum of the wrist. These are often related to conditions such as acromegaly, myxoedema and pregnancy, in which soft tissue swelling occurs. A familial tendency to entrapment neuropathy has been described.

Cranial nerve mononeuropathies have been dealt with separately.

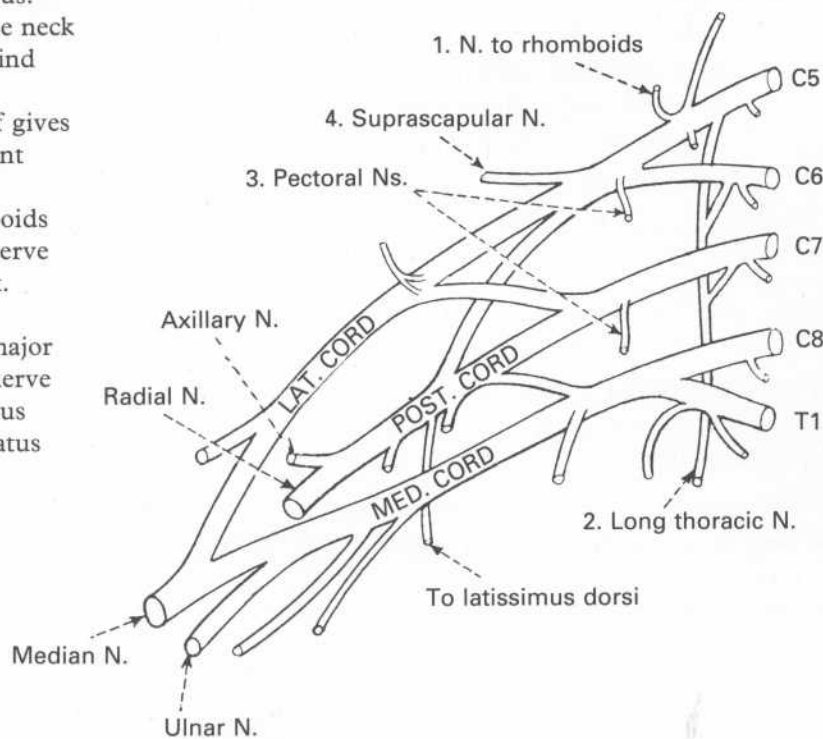
BRACHIAL PLEXUS

The plexus lies in the posterior triangle of the neck between the muscles scalenus anterior and scalenus medius.

At the root of the neck the plexus lies behind the clavicle.

The plexus itself gives off several important motor branches:

1. Nerve to rhomboids
2. Long thoracic nerve
 - to serratus ant.
3. Pectoral nerves
 - to pectoralis major
4. Suprascapular nerve
 - to supraspinatus and infraspinatus



BRACHIAL PLEXUS SYNDROMES

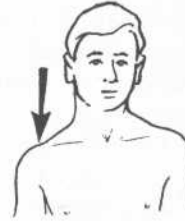UPPER PLEXUS LESION (C₅C₆)

Traction on the arm at birth (Erb-Duchenne paralysis) or falling on the shoulder may damage the upper part (C₅C₆) of the plexus.

Deltoid	}	paralysed.
Supraspinatus		
Infraspinatus		
Biceps	}	elbow flexors – also paralysed.
Brachialis		

Adductors of shoulder – mildly affected.

When damage to C₅C₆ is more proximal, nerve to rhomboids and long thoracic nerve may be affected.



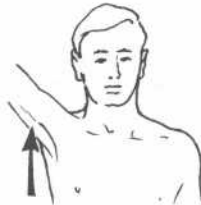POSTERIOR CORD LESION (C₅C₆C₇C₈)

Deltoid	}	paralysed
Extensors of elbow (triceps)		
Extensors of wrist (extensor carpi radialis longus and brevis, extensor carpi ulnaris)		
Extensors of fingers (extensor digitorum)		

LOWER PLEXUS LESION (C₈T₁)

Forced abduction of the arm at birth (Klumpke's paralysis) or trauma may produce damage to the lower plexus. This results in paralysis of the intrinsic hand muscles producing a claw hand, C₈T₁ sensory loss and a Horner's syndrome (page 141) if the T₁ root is involved.

N.B. A combined ulnar and median nerve lesion will produce a similar picture in the hand but with involvement also of flexor carpi ulnaris and pronator teres.



TOTAL BRACHIAL LESION

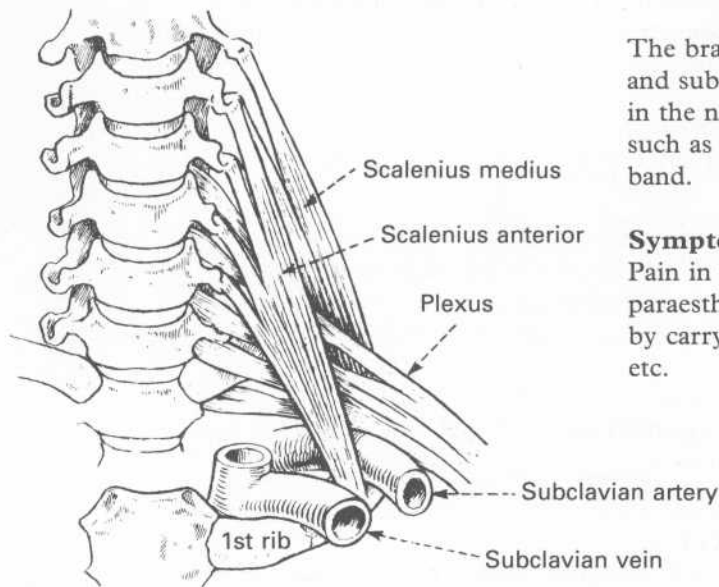
This results in complete flaccid paralysis and anaesthesia of the arm.

The presence of a Horner's syndrome indicates proximal T₁ nerve root involvement.

N.B. When trauma is the cause of brachial paralysis, early referral to a specialist unit with experience in the surgical repair of plexus injuries is advised.

BRACHIAL PLEXUS SYNDROMES

THORACIC OUTLET SYNDROME



The brachial plexus, subclavian artery and subclavian vein may be compressed in the neck by contiguous structures such as a cervical rib or tight fibrous band.

Symptoms

Pain in the neck and shoulder with paraesthesia in the forearm, made worse by carrying a suitcase, shopping bag, etc.

Signs

Sensory loss in a T₁ distribution.

Wasting and weakness of thenar and occasionally interosseous muscles.

Signs of vascular compression:

- Unilateral Raynaud's phenomenon.
- Pallor of limb on elevation.
- Brittle trophic finger nails.
- Loss of radial pulse in arm on abduction and external rotation at the shoulder or on bracing the shoulders - ADSON's sign.
- Subclavian venous thrombosis may occur, especially after excessive usage of arm.

Investigation

Coronal MRI is the definitive investigation.

Plain radiology of the thoracic outlet may reveal a cervical rib or prolonged transverse process. Nerve conduction/electromyography will distinguish this from other peripheral nerve lesions. Arteriography or venography is occasionally necessary if there are obvious vascular problems.

Treatment

In middle-aged people with poor posture and no evidence of abnormality on plain radiology, neck and postural exercises are helpful.

In younger patients with clinical and electrophysiological changes supporting the radiological abnormalities, exploration and removal of a fibrous band or rib may afford relief.

BRACHIAL PLEXUS SYNDROMES

BRACHIAL NEURITIS (Neuralgic amyotrophy)

Brachial neuritis is a relatively common disorder sometimes associated with:

- Viral infection (infectious mononucleosis, cytomegalovirus) } Probable variant
- Vaccination (tetanus toxoid, influenza) } of Guillain-Barré
- Strenuous exercise
- Intravenous heroin abuse (mainlining).

In most cases it develops without any evident precipitating cause.

Clinical features

- Acute onset with preceding shoulder pain.
- Weakness is usually proximal, though the whole arm may be affected.
- Occasionally both arms are affected simultaneously.
- Sensory findings are minor (loss over the outer aspect of the shoulder) and occur in 50%.
- Reflex loss occurs.
- Wasting is apparent after 3-6 weeks.
- Recurrent episodes can occur, especially in the presence of a family history.

Differential diagnosis

A painful weak arm.

Consider:

- Cervical spondylosis.
- Cervical disc lesion.
- Brachialgia due to local bursitis.
- Polymyalgia rheumatica.

Investigation

Viral titres may be positive, e.g. Coxsackie.

CSF may show a mild protein rise and a pleocytosis.

Nerve conduction studies will show slowing in affected nerves after 7-10 days.

Treatment

Narcotic analgesics may be required if pain is extreme. Corticosteroids are normally given though the value of immunotherapy is uncertain. By 2 yrs - 75% have fully recovered.

Familial brachial neuritis is associated with abnormalities of peripheral nerves (thickened myelin sheath) and evidence on nerve conduction studies of a diffuse neuropathy.

PANCOAST'S TUMOUR

Involvement of the plexus by an apical lung tumour (usually squamous cell carcinoma). The lower cervical and upper thoracic roots are involved.

Clinical features

- Severe pain around the shoulder and down the inside of the arm.
- Weak wasted hand muscles.
- Sensory loss (C₈T₁).
- Horner's syndrome (invasion of sympathetic chain and stellate ganglion).

BRACHIAL NEUROPATHY FOLLOWING RADIOTHERAPY

Irradiation of the axilla for breast carcinoma may damage the lower brachial plexus in 1-3% of patients. This is often associated with lymphoedema.

Onset may be delayed from 5-30 months.

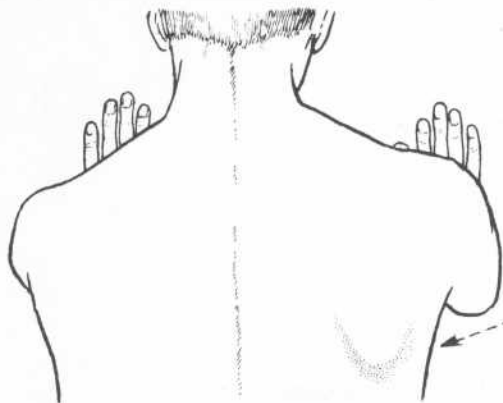
Entrapment of the plexus by resultant fibrosis seems the probable cause.

Distinguish from direct metastatic spread, in which plexus involvement is more widespread, pain more severe and Horner's syndrome often present.

UPPER LIMB MONONEUROPATHIES

LONG THORACIC NERVE (C₅C₆C₇)

Supplies: Serratus anterior muscle



Damaged by:

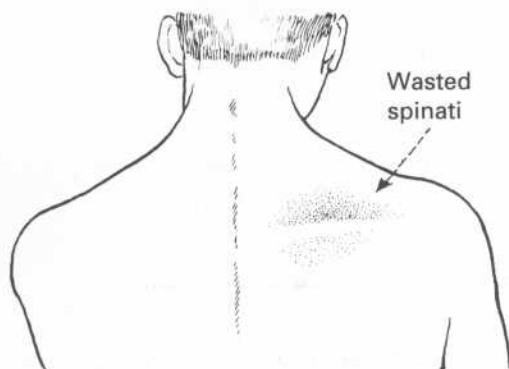
- Carrying heavy objects
- Strapping the shoulder
- Limited brachial neuritis
- Diabetes mellitus

Results in:

Winging of the scapula when arms are stretched in front

SUPRASCAPULAR NERVE (C₅C₆)

Supplies: Supraspinatus and infraspinatus muscles.



Damaged by:

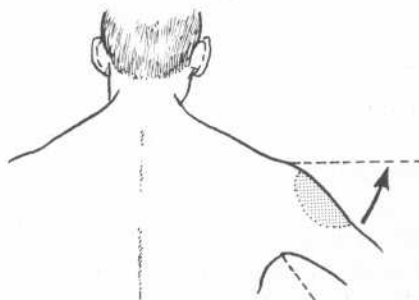
- [as for Long thoracic nerve (above)]

Results in:

- Weakness of abduction of arm (supraspinatus)
- Weakness of external rotation of arm (infraspinatus).

AXILLARY NERVE (posterior cord) (C₅C₆)

Supplies: Deltoid and teres minor muscles.



Damaged by:

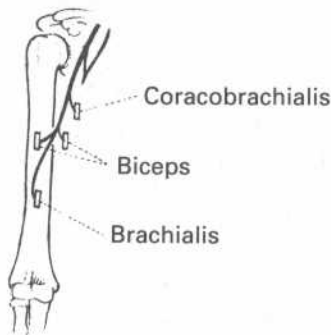
- Shoulder dislocation.
- Limited brachial neuritis.

Results in:

- Weakness of abduction of shoulder between 15–90° and sensory loss over the outer aspect of the shoulder.

UPPER LIMB MONONEUROPATHIES

MUSCULOCUTANEOUS NERVE (Lateral cord) (C₅C₆)



Sensory supply: Lateral border of the arm.

Damaged by:

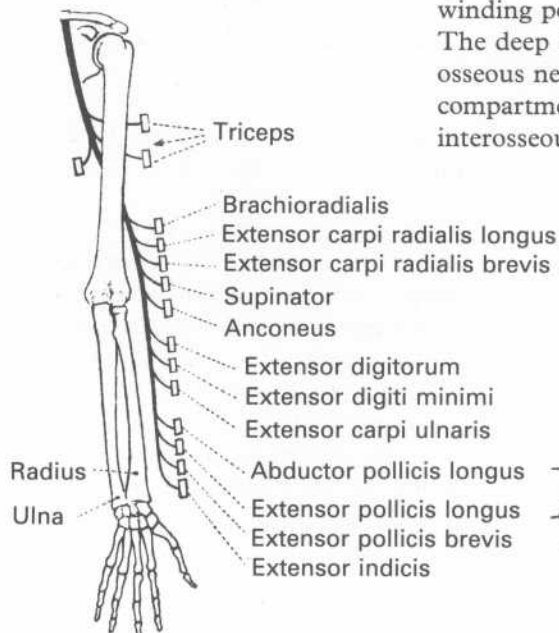
- Fracture of the humerus.
- Systemic causes.

Results in:

- Weakness of elbow flexion and forearm supination with characteristic sensory loss and absent biceps reflex.

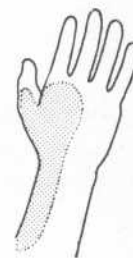

RADIAL NERVE (Posterior cord) (C₆C₇C₈)



Sensory supply: Dorsum of hand.

The nerve descends from the axilla, winding posteriorly around the humerus. The deep branch – the posterior interosseous nerve – lies in the posterior compartment of the forearm behind the interosseous membrane.

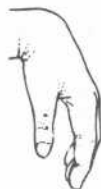

Damaged by:

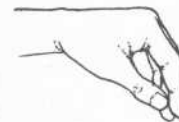
- Fractures of the humerus.
- Prolonged pressure (Saturday night palsy).
- Intramuscular injection.
- Lipoma, fibroma or neuroma.
- Systemic causes.

Results in:

- Weakness and wasting of muscles supplied, characterised by wrist drop with flexed fingers (weak extensors). Sensory loss on dorsum of hand and forearm. Loss of triceps reflex (when lesion lies in the axilla) and supinator reflex.



The *posterior interosseous branch* of the radial nerve can be compressed at its point of entry into the supinator muscle. The clinical picture is similar to a radial nerve palsy, only brachioradialis and wrist extensors are spared. Examination shows weakness of finger extension with little or no wrist drop.



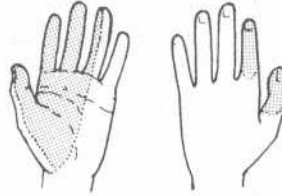
UPPER LIMB MONONEUROPATHIES

MEDIAN NERVE (Lateral and medial cords) (C₇C₈)

Sensory supply:

Palmar surfaces of the radial border of the hand.

The nerve lies close to the brachial artery in the upper arm. It passes under the transverse carpal ligament as it approaches the palm of the hand.

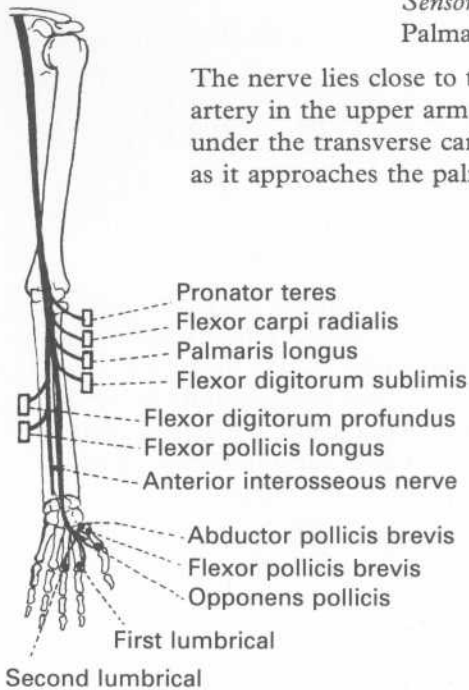


Damaged by:

- Injury in axilla, e.g. dislocation of shoulder, compression in the forearm – anterior interosseous branch, compression at the wrist (carpal tunnel syndrome).

Results in:

- Weakness of abduction and apposition of thumb.
- Weakness of pronation of the forearm.
- Deviation of wrist to ulnar side on wrist flexion.
- Weakness of flexion of distal phalanx of thumb and index finger.
- Wasting of thenar muscles is evident.
- Sensory loss is variable but most marked on index and middle fingers

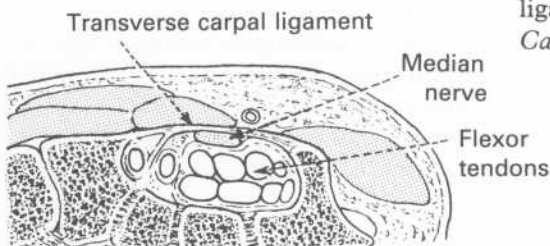


Carpal tunnel syndrome

The most common entrapment neuropathy, more frequent in women, results from median nerve entrapment under the transverse carpal ligament at the wrist.

Causes: - Connective tissue thickening, e.g.

- Rheumatoid arthritis
- Acromegaly
- Hypothyroidism.
- Infiltration of ligament, e.g. amyloid disease.
- Fluid retention, e.g. in pregnancy, weight gain.



Symptoms:

Pain, especially at night, and paraesthesia, eased by shaking the hand or dangling it out of the bed.

Objective findings may follow with cutaneous sensory loss and wasting and weakness of thenar muscles (abductor and opponens pollicis). Percussion on the nerve at the wrist produces heightened paraesthesia (Tinel's sign).

Nerve conduction studies are helpful in confirming diagnosis by showing slowing of conduction over the wrist.

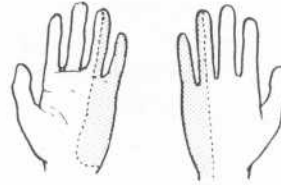
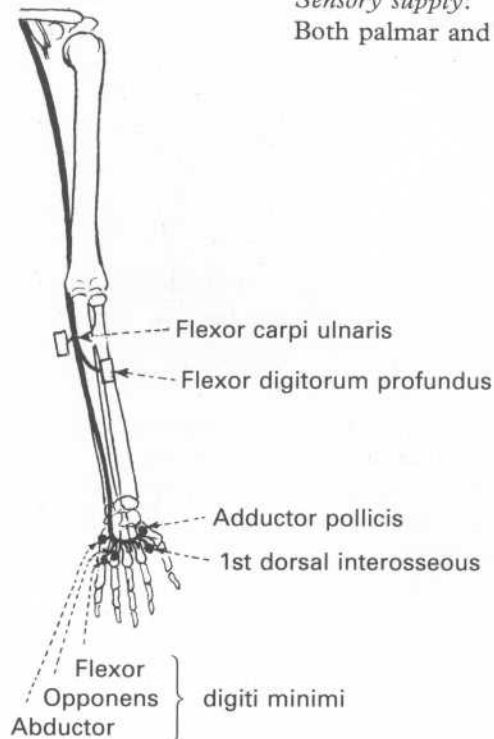
Treatment: of the cause, weight loss and diuretics. Surgical division of the transverse ligament if symptoms fail to improve produces excellent results (90% symptom free).

UPPER LIMB MONONEUROPATHIES

ULNAR NERVE (Medial cord) (C₇C₈)

Sensory supply:

Both palmar and dorsal surfaces of the ulnar border of the hand.



In the upper arm the nerve is closely related to the brachial artery and the median nerve, and passes behind the medial epicondyle of the humerus into the forearm.

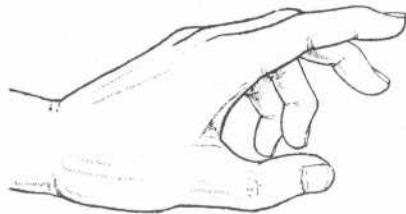
In the hand, close to the hamate bone, it divides into deep and superficial branches.

Damaged by:

- Injury at elbow, e.g. dislocation.
- Entrapment at elbow or distal to the medial epicondyle.
- Pressure on the nerve in the palm of the hand damages the deep branch resulting in wasting and weakness without sensory loss.

Results in:

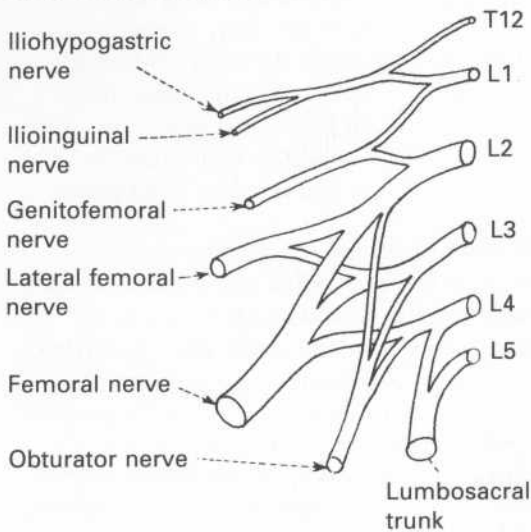
- Weakness and wasting of muscles supplied, with a characteristic posture of the hand – *ulnar claw hand* – as well as sensory loss. The level of the lesion dictates the extent of the motor paralysis. Nerve conduction studies are helpful in confirming entrapment at the elbow.



Surgical transposition may be necessary in such cases.

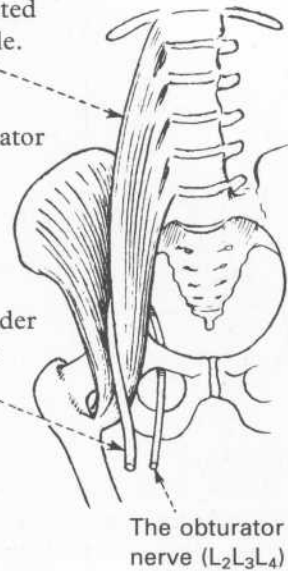
LUMBOSACRAL PLEXUS

LUMBAR PLEXUS

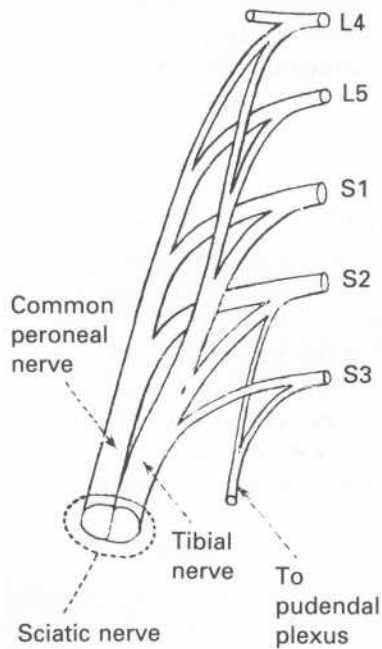


The plexus is located in the psoas muscle. The important branches are the femoral and obturator nerves.

The femoral nerve ($L_2L_3L_4$) emerges from the lateral border of the psoas muscle and leaves the abdomen laterally below the inguinal ligament with the femoral artery.



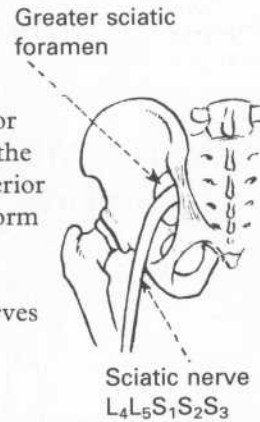
SACRAL PLEXUS



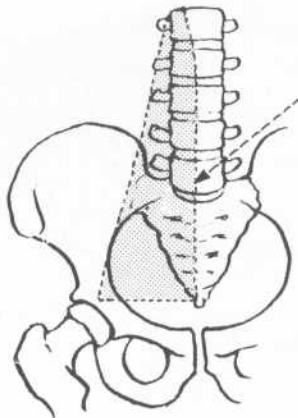
The plexus is located on the posterior wall of the pelvis. The five roots of the plexus divide into anterior and posterior divisions. The $L_4L_5S_1S_2$ divisions form the common peroneal nerve. The $L_4L_5S_1S_2S_3$ anterior divisions fuse to form the sciatic nerve. Both these nerves

The posterior divisions S_2S_3 pass to the pudendal plexus.

The common peroneal and tibial nerves (sciatic nerve) leave the pelvis by the greater sciatic foramen. In the popliteal fossa the sciatic nerve splits into its constituent nerves.



LUMBOSACRAL PLEXUS SYNDROMES



The proximity of the plexus to important abdominal and pelvic structures renders it liable to damage from diseases of these structures.

Trauma following surgery, e.g. hysterectomy, lumbar sympathectomy or during labour. Compression from an abdominal mass, e.g. aortic aneurysm. Infiltration from pelvic tumour. Radiotherapy.

Symptoms may be unilateral or bilateral, depending upon causation. Weakness, sensory loss and reflex changes are dictated by the location and extent of plexus damage. Pain of a severe burning quality may be present; it may be worsened by coughing, sneezing, etc.

In general:

Lower plexus lesions produce:
Weakness of posterior thigh (hamstring) and foot muscles with posterior leg sensory loss.

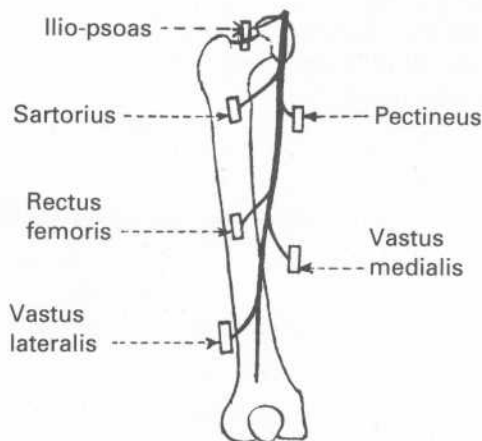


Upper plexus lesions produce:
Weakness of hip flexion and adduction with anterior leg sensory loss.

The lumbosacral plexus may be affected in the same way as the brachial plexus in brachial neuritis – lumbosacral neuritis – the association with infection, etc., being similar. Recovery is usually good. Recurrent episodes may occur. Plexus lesions also occur in *diabetes mellitus* and *polyarteritis nodosa*. In both, the symptoms and signs may be bilateral. Investigate with CT/MR and neurophysiology.

LOWER LIMB MONONEUROPATHIES

FEMORAL NERVE ($L_1L_2L_3$)



Damaged by:

- Fractures of the upper femur
- Congenital dislocation of the hip, hip surgery
- Neoplastic infiltration
- Psoas muscle abscess
- Haematoma into iliopsoas muscle (haemophilia, anticoagulants)
- Systemic causes of mononeuropathy, e.g. diabetes.

Results in:

- Weakness of hip flexion
- Weakness of knee extension with wasting of thigh muscles
- Sensory loss over the anterior and medial aspects of the thigh
- The knee jerk is lost.

LOWER LIMB MONONEUROPATHIES

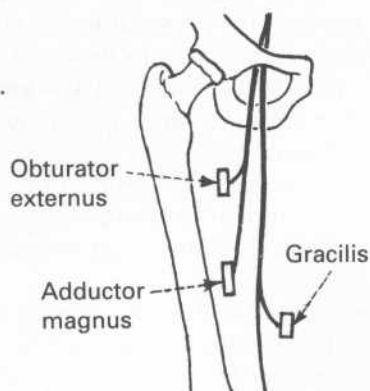
OBTURATOR NERVE (L₂L₃L₄)

Damaged by: – Same process as the femoral nerve.

- During labour and occasionally as a consequence of compression by hernia in the obturator canal.

Results in: – Weakness of hip external rotation and adduction.

- The patient may complain of inability to cross the affected leg on the other.
- Sensory loss is confined to the innermost aspect of the thigh.
- The adductor reflex is absent (adductor response to striking the medial epicondyle).



SCIATIC NERVE (L₄L₅S₁S₂)

The nerve descends between the ischial tuberosity and the greater trochanter of the femur.

In the thigh it innervates the hamstring muscles (semitendinosus, semimembranosus and biceps).

Damaged by: – Congenital or traumatic hip dislocation.

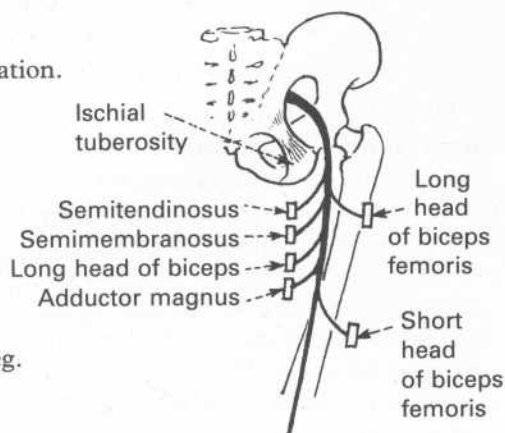
- Penetrating injuries.
- Accidental damage from 'misplaced' intramuscular injection.

– Entrapment at sciatic notch.

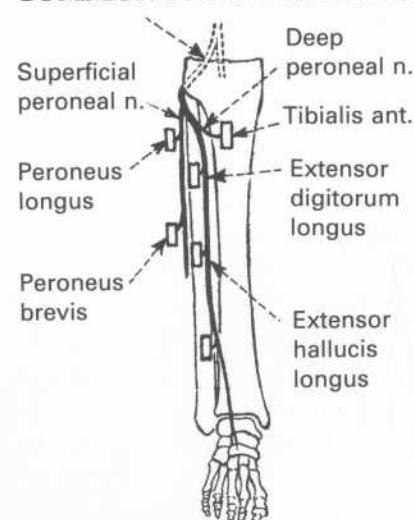
– Systemic causes of mononeuropathy

Results in: – Weakness of hamstring muscles with loss of knee flexion.

- Distal foot and leg muscles are also affected.
- Sensory loss involves the outer aspect of the leg.
- The ankle reflex is absent.



COMMON PERONEAL NERVE (L₄L₅)



The nerve arises from the division of the sciatic nerve in the popliteal fossa. It bears a close relationship with the head of the fibula as it winds anteriorly. It divides into superficial and deep branches as well as giving off a purely sensory branch which, with sensory twigs from the tibial nerve, forms the *sural nerve*, mediating sensation from the dorsum and lateral aspect of the foot.

Damaged by: – Trauma to the head of the fibula; pressure here from kneeling, crossing legs.

– Systemic causes of mononeuropathy, e.g. diabetes.

Results in: Weakness of dorsiflexion and eversion of the foot. The patient walks with a 'foot drop'. Sensory loss involves the dorsum and outer aspect of the foot. Partial common peroneal nerve palsies are common with very selective muscle weakness.

LOWER LIMB MONONEUROPATHIES

POSTERIOR TIBIAL NERVE (S₁S₂)

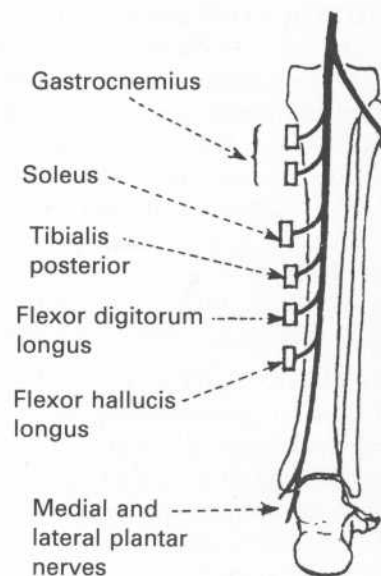
This nerve also arises from the division of the sciatic nerve in the popliteal fossa and descends behind the tibia, terminating in the medial and lateral plantar nerves which innervate the small muscles of the foot. The sensory branch contributes to the *sural nerve*.

Damaged by:

- Trauma in the popliteal fossa.
- Fracture of the tibia.
- Systemic causes of mononeuropathy.

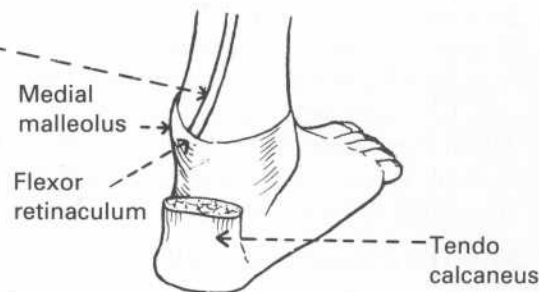
Results in:

- Weakness of plantar flexion and inversion of the foot.
- The patient cannot stand on toes.
- Sensory loss involves the sole of the foot.
- The ankle reflex is lost.



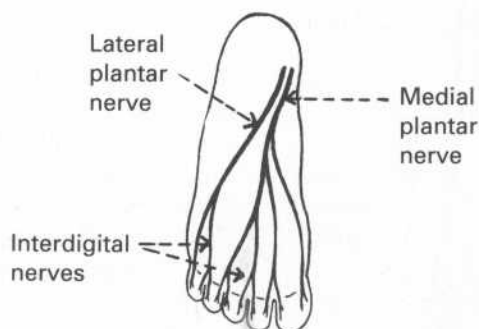
Tarsal tunnel syndrome

The posterior tibial nerve may be entrapped below the medial malleolus. This produces a burning pain in the sole of the foot. Weakness of toe flexion and atrophy of small muscles of the foot occur in advanced cases. A prolonged sensory conduction velocity confirms the diagnosis. Surgical decompression is often required.



PLANTAR AND SMALL INTERDIGITAL NERVES

Compression of these nerves at the sole of the foot produces localised burning pain. Involvement of interdigital nerves produces pain and analgesia in adjacent halves of neighbouring toes.

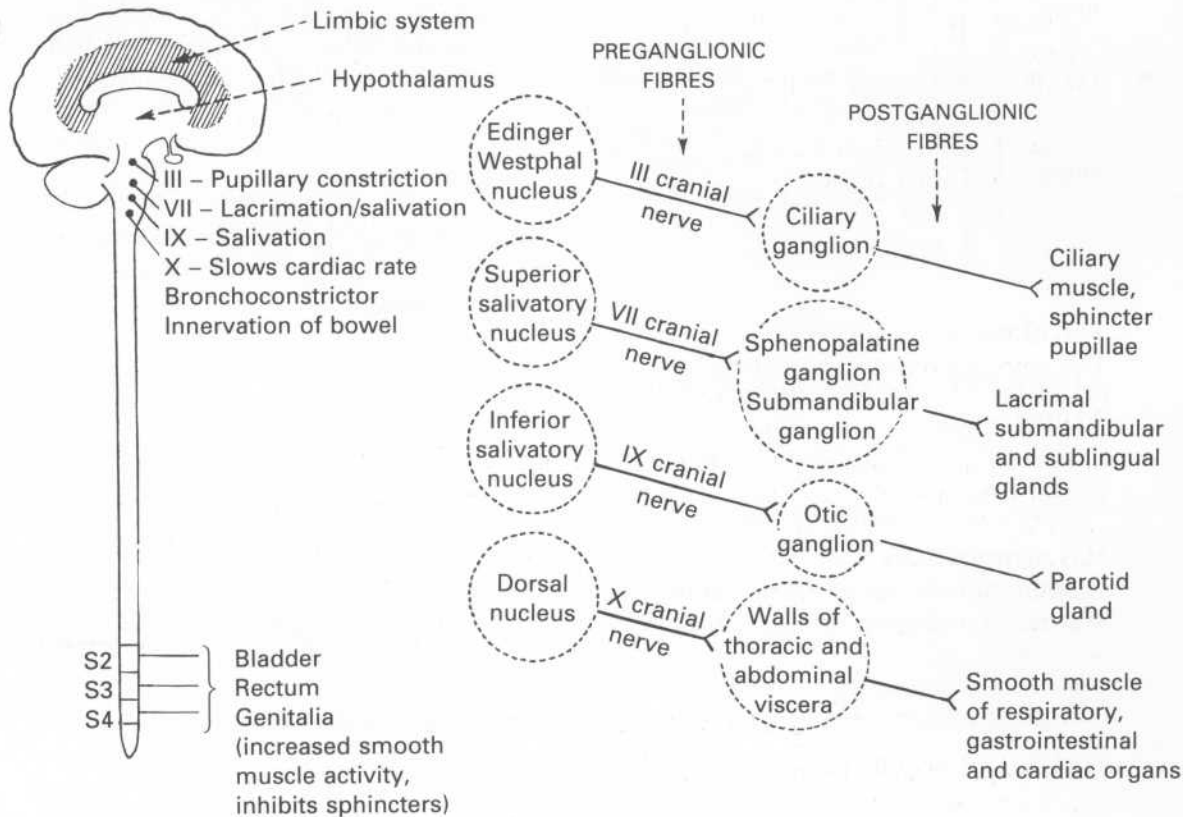


AUTONOMIC NERVOUS SYSTEM

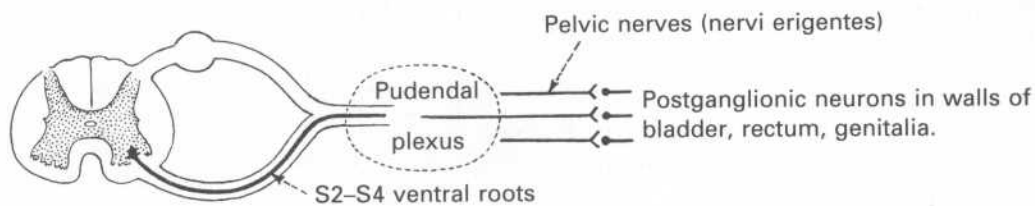
The autonomic nervous system maintains the visceral and homeostatic functions essential to life. It is divided into SYMPATHETIC and PARASYMPATHETIC components and contains both motor (efferent) and sensory (afferent) pathways.

Both sympathetic and parasympathetic systems are regulated by the *limbic system*, *hypothalamus* and *reticular formation*. Fibres from these structures descend to synapse with preganglionic neurons in the intermediolateral column T1-T12 (sympathetic) and in the III, VII, IX and X cranial nerve nuclei and S2-S4 segments of the cord (parasympathetic).

PARASYMPATHETIC OUTFLOW

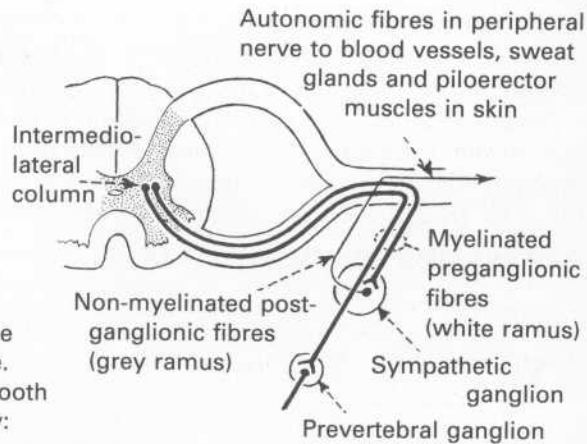
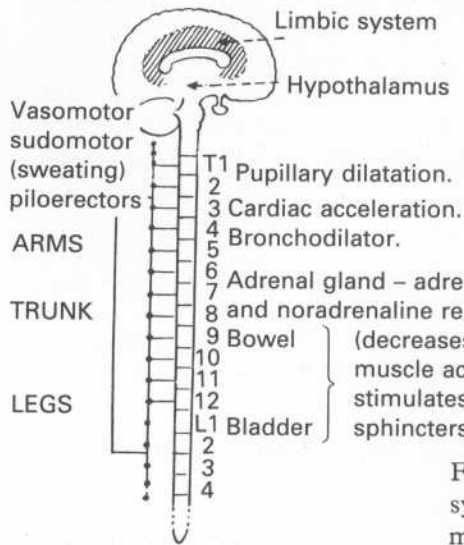


SACRAL OUTFLOW



AUTONOMIC NERVOUS SYSTEM

SYMPATHETIC OUTFLOW



Fibres which pass through the sympathetic ganglion to synapse on a prevertebral ganglion, e.g. coeliac or mesenteric ganglia constitute the *splanchnic nerves* and innervate the viscera.

AFFERENT AUTONOMIC NERVOUS SYSTEM

Sympathetic

Terminate in spinal cord in intermediate zone of grey matter – in relation to preganglionic neurons.

Function: Important in the appreciation of visceral pain.

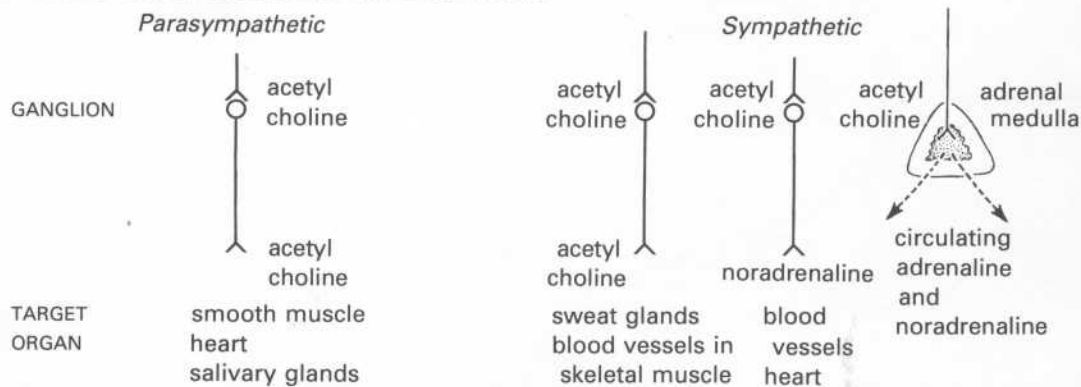
Parasympathetic

Afferent fibres from the mouth and pharynx, and respiratory, cardiac and gastrointestinal systems, travelling in the VII, IX and X cranial nerves, terminate in the nucleus of tractus solitarius.

Function: Important in maintaining visceral reflexes.

The sacral afferents end in the S2–S4 region in relation to preganglionic neurons.

NEUROTRANSMITTER SUBSTANCES



TESTS OF AUTONOMIC FUNCTION

BLOOD PRESSURE CONTROL

1. Maintenance of blood pressure with alteration in posture – is normally dependent upon reflex baroreceptor function. A fall in BP occurs with efferent or afferent lesions – postural (orthostatic) hypotension.
2. Exposure to cold induces vasoconstriction and a rise in BP – cold pressor test. Stress will produce a similar pressor response, e.g. ask patient to do mental arithmetic.
Both central and peripheral lesions affect these tests.
3. Valsalva manoeuvre:
The patient exhales against a closed glottis, increases intrathoracic pressure and thus reduces venous return and systemic BP. The heart rate accelerates to maintain BP. On opening the glottis, venous return increases and an overshoot of BP with cardiac slowing occurs. An impaired response occurs with afferent or efferent autonomic lesions.
4. Noradrenaline infusion test:
A postganglionic sympathetic lesion results in 'supersensitivity' of denervated smooth muscle to adrenaline, with a marked rise in BP following infusion.

HEART RATE

1. Massage of the carotid sinus should stimulate the baroreceptors, increase vagal parasympathetic discharge and slow the heart rate. Either efferent or afferent lesions abolish this response.
2. Atropine test:
Intravenous atropine 'blocks' vagal action and with intact sympathetic innervation results in an increase in heart rate.

SWEATING

A rise in body temperature causes increased sweating, detectable on the skin surface with starch-iodide paper. Any lesion from the central to the postganglionic sympathetic system impairs sweating.

SKIN TEMPERATURE

Skin temperature is a function of the sympathetic supply to blood vessels. With pre- or postganglionic lesions the skin becomes warm and red. With chronic postganglionic lesions the skin may become cold and blue (denervation hypersensitivity.) Compare the temperature of various regions.

PUPILLARY FUNCTION

Check the response to light and accommodation.

Pharmacological tests are important:

1. Atropine – blocks parasympathetic system – dilates pupil.
2. Cocaine – stimulates adrenergic receptors – dilates pupil.

In highly specialised units detailed neurophysiology (e.g. thermal threshold measurements) and plasma concentrations of neurotransmitters and hormones at rest and in response to baroreceptor stimulation are employed to characterize the site and selectivity of the autonomic lesion.

AUTONOMIC NERVOUS SYSTEM – SPECIFIC DISEASES

Symptoms of autonomic dysfunction occur in many common conditions which affect both the parasympathetic and sympathetic pathways e.g. cerebrovascular disease.

The following are less common disorders which primarily may affect the autonomic nervous system -

IDIOPATHIC ORTHOSTATIC HYPOTENSION

Two types of this condition are recognised:

1. Due to degeneration of sympathetic postganglionic neurons.
2. Due to degeneration of sympathetic preganglionic neurons of the intermediolateral column T1–T12 – SHY-DRAGER SYNDROME.

In the latter disorder, features of extrapyramidal system involvement are also found.

Both disorders are characterised by: postural hypotension: anhidrosis (absent sweating): impotence:
sphincter disturbance: pupillary abnormalities.

The disorders may be separated pharmacologically; the postganglionic disorder shows hypersensitivity (denervation hypersensitivity) to noradrenaline infusion.

Treatment

Drugs such as fludrocortisone increase blood volume and may prevent postural hypotension.

DIABETIC AUTONOMIC NEUROPATHY

Symptoms of autonomic dysfunction are common in long-standing insulin-dependent diabetics:

Impotence/retrograde ejaculation.

Bladder dysfunction – decreased detrusor muscle action – resulting in increased residual volume.

Nocturnal diarrhoea.

GI dysfunction – vomiting from gastroparesis.

Orthostatic hypotension.

These problems arise from damage to both sympathetic and parasympathetic postganglionic neurons.

Treatment

Improve diabetic control and treat symptoms e.g. fludrocortisone for BP control.

POST-INFECTIOUS POLYNEUROPATHY – Guillain-Barré syndrome (see previous chapter).

Autonomic involvement occurs commonly in this disorder and may present major problems in patient management. The lesion may involve the afferent or efferent limbs of the cardiovascular reflexes (baroreceptor reflexes) resulting in postural hypotension, episodes of hypertension and cardiac dysrhythmias.

Occasionally the postinfectious neuropathy is purely autonomic.

HEREDITARY AUTONOMIC NEUROPATHY e.g. RILEY-DAY Syndrome

This autosomal recessive disorder occurs in persons of Jewish descent.

Features of autonomic dysfunction: postural hypotension, oesophageal reflux, hyperpyrexia – present from birth. Insensitivity to pain results with associated sensory neuropathy.

PRIMARY AMYLOIDOSIS

Autonomic involvement with orthostatic hypotension, impotence, diarrhoea and bladder involvement may accompany sensorimotor neuropathy in the primary and hereditary forms. Amyloid infiltration affects autonomic ganglia.

ADIE'S SYNDROME

A tonic pupil (page 140) associated with areflexia and occasionally widespread autonomic dysfunction, e.g. segmental hypohidrosis (absent sweating) and diarrhoea.

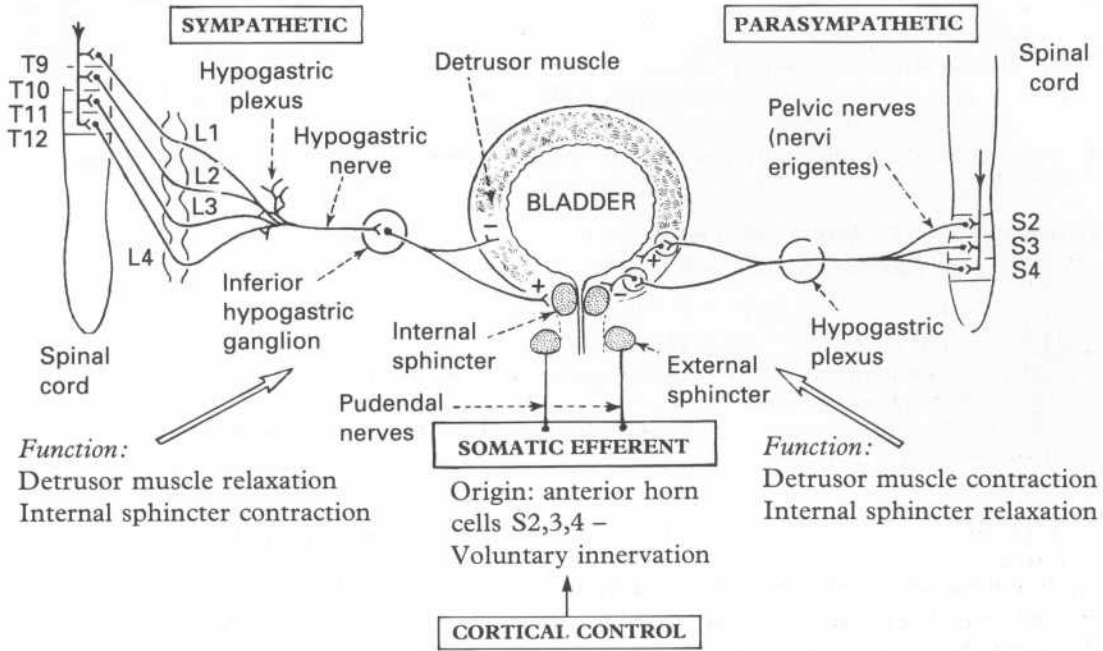
AUTONOMIC DYSFUNCTION IN QUADRIPLEGIA (autonomic dysreflexia)

A high cervical lesion which completely severs the spinal cord, e.g. traumatic cervical fracture/dislocation will isolate all but the cranial parasympathetic outflow. As a result, disturbed autonomic function is inevitable but variable.

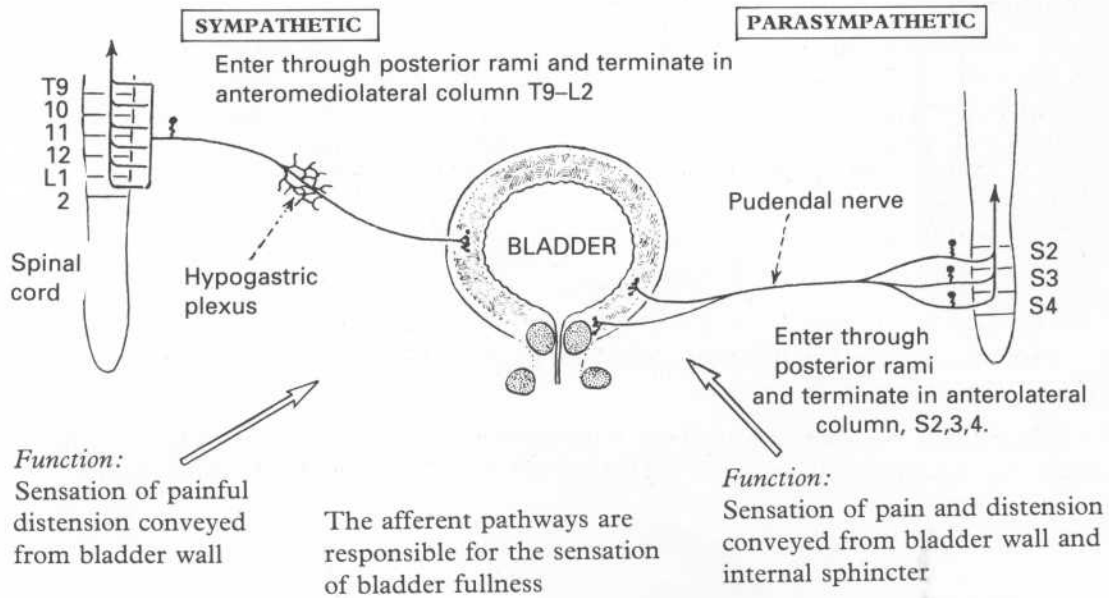
Autonomic reflexes are retained – Passive movement or tactile stimulation of limbs may result in blood pressure rise, bradycardia, sweating, reflex penile erection (priapism).

AUTONOMIC NERVOUS SYSTEM – BLADDER INNervation

Efferent innervation



Afferent innervation



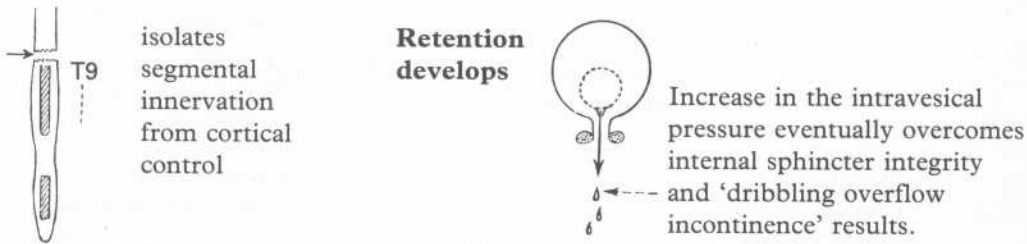
MICTURITION

PROCESS OF MICTURITION

1. Cortical centre – removal of conscious inhibition of micturition.
2. Voiding – wave-like detrusor muscle contractions with relaxation of internal and external sphincters.
3. Voiding completed – detrusor muscle relaxation
 contraction of internal sphincter
 contraction of external sphincter.
4. Voiding may be voluntarily interrupted before complete bladder emptying by forced voluntary contraction of the external sphincter.

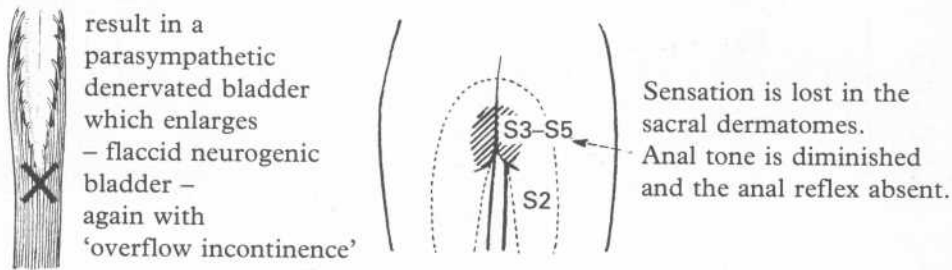
DISORDERS OF MICTURITION

Complete or partial spinal cord lesion



After some days or weeks a REFLEX BLADDER develops – *automatic emptying may be induced by abdominal tapping*. This voiding is often inadequate due to reflex contractions of the external sphincter before bladder emptying (autonomic dysynergia). High residual volumes result.

Lesions of the cauda equina



After weeks or months, abdominal compression combined with a Valsalva manoeuvre can induce efficient bladder emptying.

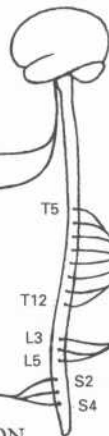Urinary and, less commonly, associated faecal incontinence occurs in women following traumatic childbirth with injury to the innervation of striated pelvic floor musculature.

BOWEL AND SEXUAL FUNCTION

PARASYMPATHETIC

Vagus - gastric emptying, intestinal peristalsis.

Sacral nerve roots S2,3,4 - peristalsis from descending colon to anus.
- erection, ejaculation.



Paracentral lobule of frontal lobe
- voluntary initiation or inhibition of defaecation.

SYMPATHETIC

Coeliac ganglion

- gastric and intestinal relaxation.
- contraction of internal anal sphincter.

Hypogastric plexus

- inhibits erectile function

NORMAL PROCESS

DEFAECATION

1. Faeces arrive at rectosigmoid junction:
- cortical awareness of urge to defaecate
- release of sympathetic tone.
2. Relaxation of pelvic floor muscles and internal anal sphincter.
Lowering of anorectum.
3. Voluntary opening of external anal sphincter.
4. Parasympathetic peristalsis and Valsalva manoeuvre empty the rectum.

SEXUAL FUNCTION

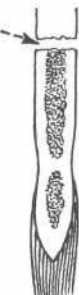Parasympathetic:

- penile/clitoral erection.
- Reflex - in response to tactile stimulation of erogenous zones.
- Psychogenic - sexual thoughts or visual erotic stimulation.
- orgasm, ejaculation

Sympathetic:

- mainly anti-erectile action.

COMPLETE OR PARTIAL CORD LESION

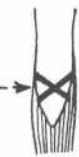

Bowel atony for up to 1 week.
→ Faecal retention with impaction and faecal fluid overflow (spurious diarrhoea). Impaired/absent external sphincter tone becomes spastic after days or weeks.
→ *Regular bowel emptying reflexly in response to digital stimulation or suppositories achieves continence.*

- ♂ Prolonged reflex erection (priapism) may occur for 2-3 days, then:
- Erections and ejaculation lost for weeks or months, then:
 - Reflex erections (only tactile) appear but reflex ejaculation seldom returns.
- Fertility is impaired or lost.

- ♀ Vaginal sensation and lubrication are lost.
Fertility is retained.

CONUS LESION

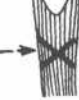


→ Mixed upper and lower neurone pattern

Flaccid external sphincter.
Faecal retention with impaction and faecal fluid overflow.
Regular clearance of constipated stool by manual evacuation or Valsalva manoeuvre achieves continence.

Loss of genital sensation.
Loss of reflex erections and ejaculation (psychogenic erection may be retained).
Male infertile; female fertility retained.
Male erections may be achieved by cavernosal blockade using intracavernosal injection of papaverine HCl.

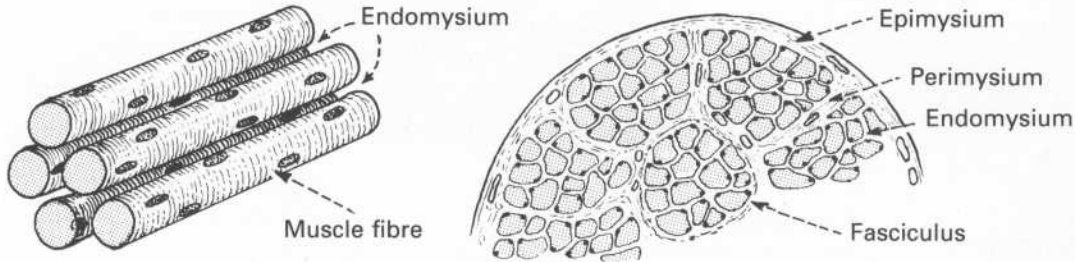
CAUDA EQUINA LESION



DISEASES OF SKELETAL (VOLUNTARY) MUSCLE

Normal skeletal muscle morphology

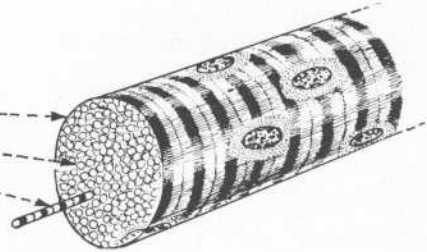
A skeletal muscle is composed of a large number of muscle fibres separated by connective tissue (endomysium) and arranged in bundles (fasciculi) in which the individual fibres are parallel to each other. Each fasciculus has a connective tissue sheath (perimysium) and the muscle itself is composed of a number of fasciculi bound together and surrounded by a connective tissue sheath (epimysium).



The three envelopes (sheaths) are made up of connective tissue richly endowed with blood vessels and fat cells (lipocytes).

The muscle fibre

This is a large multinucleated cell with an outer membrane – SARCOLEMMMA and a cytoplasm – SARCOPLASM within which lie the MYOFIBRILS



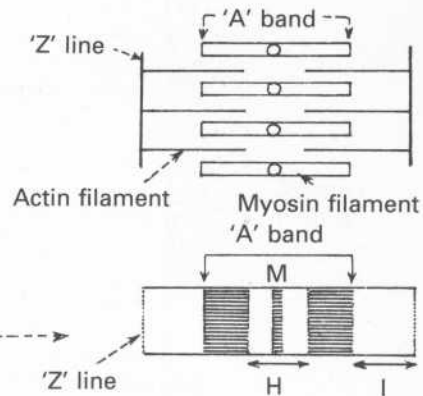
Each muscle fibre has its own endplate approximately half way along its length.

The cell also contains mitochondria, endoplasmic reticulum and microsomes – the usual cellular constituents.

Fats, glycogen, enzymes and myoglobin lie within the sarcoplasm and related structures.

The **MYOFIBRILS** are the contractile components of muscle.

Each myofibril is 1μ in diameter and contains filaments of *myosin* and *actin* interdigitating with each other between each Z line. When muscle contracts or relaxes these filaments slide over each other producing shortening and lengthening of the muscle fibre. The striated appearance of skeletal muscle is a consequence of differing concentrations of actin and myosin. These resultant bands are designated as shown.



MUSCLE MORPHOLOGY AND FUNCTION

Fibre type

Two types of muscle fibres exist based on physiology and structure.

Type I: Slow twitch, fatigue resistant.

Type II: Fast twitch, fatigue dependent.

Characteristics:

Type I

ATPase stain: Light

Oxidative metabolism

Abundant mitochondria

Type II

ATPase stain: Dark

Glycolytic metabolism

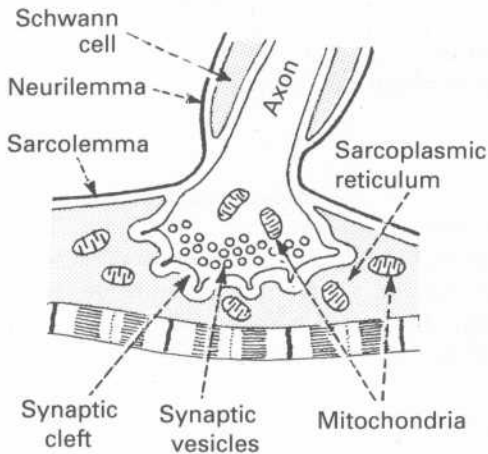
High glucogen content

Individual muscles contain a mixture of type I and type II fibres with a tendency for one type to predominate. The usual ratio in limb muscles is 1:2.

Neuromuscular junction

Each muscle fibre receives a nerve branch from the motor cell body in the anterior horn of the spinal cord or cranial nerve motor nuclei.

When a nerve fibre reaches the muscle it loses its myelin sheath and its neurilemma then merges with the sarcolemma under which the axon spreads out to form the motor endplate. The axon fibre with its endings and muscle fibres it supplies is called the MOTOR UNIT. The number of muscle fibres in a motor unit varies: in the eye muscles it is small (5-10), whereas in the limb muscles the number is large (in the gastrocnemius about 1800). Each motor unit contains only one type of muscle fibre, i.e. type I or type II. The neuromuscular junction is the point at which neuromuscular transmission is effected. The motor endplate is separated from the sarcoplasm by the synaptic cleft.



Physiology

Muscle contraction results from the following: -

- 1) A depolarisation wave arrives at the axon terminus and opens voltage sensitive Ca^{2+} channels
- 2) Ca^{2+} influx results in acetylcholine release from the synaptic vesicles into the synaptic cleft.
- 3) Acetylcholine attaches to end-plate receptors with Na^+ entry into muscle. Post synaptic depolarisation initiates an action potential that spreads along the sarcolemmal membrane.
- 4) Release of Ca^{2+} from the sarcoplasmic reticulum and the interaction of actin and myosin result in muscle contraction.

The enzyme cholinesterase, found in high concentration at motor endplates, destroys acetylcholine so that normally a single nerve impulse only gives rise to a single muscle contraction.

Biochemistry

Muscle contraction requires energy in the form of adenosine triphosphate (ATP). This is produced by breakdown of glucose and glycogen to pyruvate (glycolysis) and breakdown of lipid by beta-oxidation, both through the Krebs cycle.

MUSCLE DISEASE – CLINICAL EXAMINATION

Topographic distribution of weakness, wasting or hypertrophy aids diagnosis and classification of muscle disorders, e.g. limb girdle or scapuloperoneal dystrophies.

Certain points should be elicited from history

- Whether muscles fatigue with exercise and recover with rest
 - non-specific in muscle disease but may suggest defective neuromuscular transmission or metabolic myopathy.
- Tasks which are specifically difficult:
 - proximal weakness
 - difficulty in climbing stairs
 - lifting hands above head
 - combing hair.
 - distal weakness
 - 'scuffing' toes when walking
 - weak hands, e.g. cannot turn door handle, change gear in car.
- Speed of onset of weakness (whether acute, subacute, chronic).
- Muscle pains present at rest.
- Muscle pains and cramps during or after exercise.
- The presence of a family history of muscle disease or related disorders.
- Developmental history e.g. milestones for crawling or walking.

Examination should

- Note the presence of hypertrophy and the distribution of wasting and weakness, and grade weakness according to the MRC (Medical Research Council) scale:
 - 5- Full strength.
 - 4- Below normal.
 - 3- Lift against gravity.
 - 2- Movement with gravity eliminated.
 - 1- Muscle twitch with no movement about the joint.
 - 0- No muscle contraction.
- Palpate muscles for tenderness.
- Note the presence of contractures
- Percussion to determine presence or absence of myotonia (see later).
- Reflex examination, initially normal, may diminish with marked wasting and weakness.
- General examination is essential. Muscle disease may be a reflection of an underlying metabolic, endocrine, neoplastic or connective tissue disorder, e.g. increased pigmentation in Addison's disease, malar rash in systemic lupus erythematosus, hepatosplenomegaly in alcoholic liver disease.

MUSCULAR DYSTROPHIES

Muscular dystrophies are genetically determined progressive necrotising myopathies. Increasingly genetic loci have been identified but the mechanisms of disease production remain uncertain.

Classification is based upon the mode of inheritance and the clinical picture.

<i>X-linked recessive</i>	<i>Genetic locations where known</i>	
- Duchenne	Xp	21.2
- Becker	Xp	21.2
- Emery-Dreifuss.	Xq	28
<i>Autosomal dominant</i>		
- fascioscapulohumeral	4q	35
- scapuloperoneal		
- myotonic	19q	13.3
- oculopharyngeal.		
- limb girdle	5q	22.3-31.3
<i>Autosomal recessive</i>		
- limb girdle.	15q	22
- scapuloperoneal		

X-LINKED DYSTROPHIES

These disorders are due to abnormal *dystrophin*, a membrane associated protein coded by a 6 million base pair gene located on the X chromosome at X p 21. Dystrophin is believed to be important in maintaining membrane stability during muscle contraction and relaxation, it also appears relevant to smooth muscle function. Dystrophin is absent in Duchenne and depleted in Becker dystrophy.

DUCHENNE DYSTROPHY

1 in 3,500 male births. As an X-linked and recessive disorder it is passed to boys by unaffected 'carrier' mothers. One third of patients have negative family history - high spontaneous mutation rate.

Clinical features:

Delayed motor development is common; at 18 months only 50% of subsequent sufferers can walk. Clumsiness is the first clear manifestation; this occurs between 3-5 years.

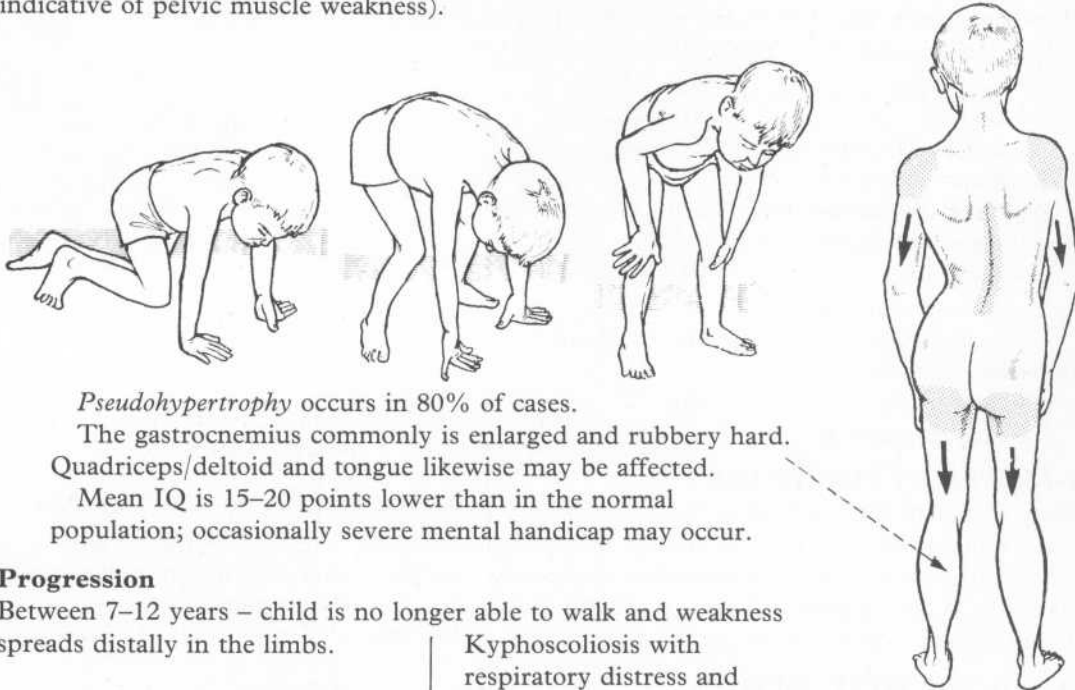
Proximal muscle involvement follows.

- glutei/quadriceps - *waddling gait*.
- shoulder girdle and upper forearm.
- axial muscles - *sway back posture*.

MUSCULAR DYSTROPHIES

Clinical features (contd)

The child cannot climb stairs or rise from a low chair, and when attempting to rise from the ground will 'climb up himself' – Gower's sign (not diagnostic of the condition, but indicative of pelvic muscle weakness).



Pseudohypertrophy occurs in 80% of cases.

The gastrocnemius commonly is enlarged and rubbery hard. Quadriceps/deltoid and tongue likewise may be affected.

Mean IQ is 15–20 points lower than in the normal population; occasionally severe mental handicap may occur.

Progression

Between 7–12 years – child is no longer able to walk and weakness spreads distally in the limbs.

↓ Kyphoscoliosis with respiratory distress and cardiac muscle involvement.

Aged 20 years – chest infection, cardiac failure and arrhythmias occur with severe muscle contractures. The patient by now is bedbound.

Survival is rare beyond mid-20s.

Investigation

Muscle enzyme – creatine kinase – is substantially elevated (several thousand units) especially in early stages. The enzyme is raised at birth and is significantly elevated in the female carrier aiding detection of this state and genetic counselling.

Electrocardiogram is abnormal in 80% with conduction abnormalities and rhythm disorders.

Electromyographic (EMG) studies will support the diagnosis and may be important in doubtful early cases with no family history, i.e. spontaneous mutation. EMG studies do not detect carrier states.

Muscle biopsy: the failure to detect dystrophin establishes the diagnosis beyond doubt.

Treatment

There is no effective treatment. Orthopaedic procedures such as tenotomy may prolong mobility. Steroids may marginally slow decline and increase muscle mass. Myoblast transfer studies are disappointing. Detection of the carrier state and advice are essential as preventive treatment. Intra-uterine diagnosis can be made and termination offered.

MUSCULAR DYSTROPHIES

BECKER'S DYSTROPHY

Becker's dystrophy has a similar prevalence 1:3500 males.

Clinical features

Onset is later than Duchenne – aged 10 years, remaining ambulant until the 3rd or 4th decade.

ECG abnormalities occur in 40% but are rarely severe.

Calf hypertrophy is common. Limb girdle muscles may be selectively involved.

Muscle biopsy in contrast to Duchenne shows dystrophin but in reduced amounts.

EMERY-DREIFUSS DYSTROPHY

Onset in childhood/adolescence. Contractures of elbows and neck are associated with periscapular and biceps weakness (with spared deltoids). Cardiomyopathy with conduction abnormalities can be life threatening. Muscle biopsy is non-specifically abnormal.

AUTOSOMAL DOMINANT DYSTROPHIES

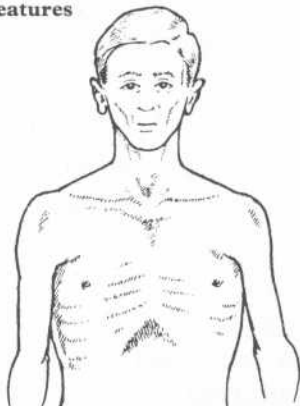
FASCIOSCAPULOHUMERAL DYSTROPHY

This is inherited as an autosomal dominant trait. Described by Dejerine (1885) it is referred to as Dejerine's dystrophy.

Abortive forms of this condition in which selective muscle involvement occurs (e.g. unilateral shoulder muscle) may 'mask' the dominant mode of inheritance.

Incidence: 1–2 per 100 000.

Clinical features



The expression of disease is variable and often mild. Onset in first or second decade. Initially the lower half of the face is involved – cannot purse lips or whistle – then spread into trapezius and pectorals occurs with scapular 'winging'. Lumbar lordosis develops from spinal muscle weakness. Pelvic musculature and quadriceps may eventually become involved. *Dromedary or camel-backed* gait with protrusion of the buttocks is characteristic. Calf and deltoid muscles may be hypertrophic.

Unlike Duchenne dystrophy the clinical course is slow and arrest of progression may occur.

In some cases weakness of facial muscles is noted in childhood without spread to other muscles until middle age. Cardiac muscle is not involved. Sensorineural deafness and retinal vascular changes (telangiectasis and detachment) may occur. Life expectancy in this condition is normal.

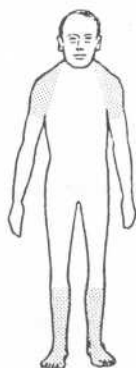
Investigations *EMG studies* show myopathic changes.

Muscle enzymes may be normal or slightly elevated.

Muscle biopsy shows increased fibre diameter; a cellular response of lymphocytes and plasma cells may be present between muscle fascicles.

Treatment There is no specific treatment other than general support with genetic guidance.

SCAPULOPERONEAL MUSCULAR DYSTROPHY



This is an autosomal dominant or recessive disorder with involvement of proximal upper limb and distal lower limb muscles. Onset is in adult life with foot drop (anterior tibial and peroneal muscle groups). Weakness next affects the upper limbs with spread from scapular muscles into deltoid, biceps and triceps. The disease runs a benign non-disabling course. Cardiac muscle involvement may occur in later life. A more aggressive X-linked form of this dystrophy has been described.

The *creatine kinase* enzyme is elevated.

The *electrocardiogram* may be abnormal with atrial arrhythmias.

EMG studies show myopathic changes.

Muscle biopsy will show non-specific myopathic features.

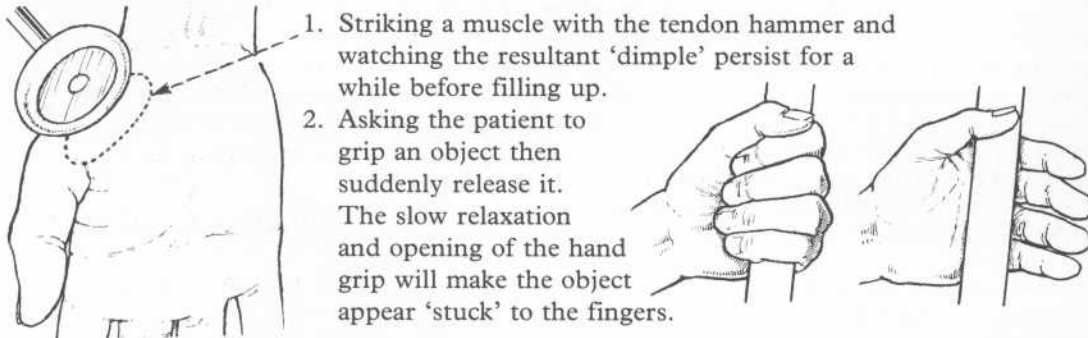
Differentiation from spinal muscular atrophy and inflammatory myopathy with the same distribution of muscle involvement may require EMG and biopsy.

MUSCULAR DYSTROPHIES

MYOTONIC DYSTROPHY

Myotonic dystrophy is a multi-system disorder characterised by the presence of MYOTONIA – failure of immediate muscle relaxation after voluntary contraction has stopped.

It can be demonstrated by:



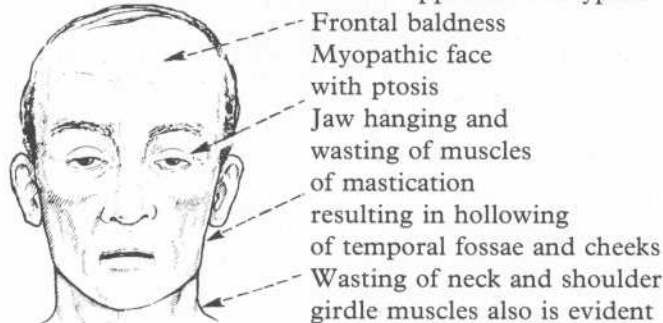
Physiologically, myotonia is due to instability of the Na^+ and Cl^- channels of the muscle membrane with repetitive discharges following a short period of contraction. Although suggestive of myotonic dystrophy, myotonia may occur in other muscle disorders due to a similar defect.

Clinical features

Myotonic dystrophy is an autosomal dominant inherited disorder transmitted by a mutation (repeat of three base pairs) in the myotonin protein kinase gene on chromosome 19.

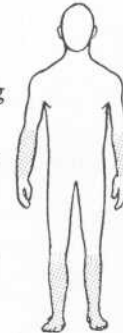
The incidence is 5 per 100 000 with the onset occurring between 15 and 40 years.

The facial appearance is typical:



In the limbs – weakness and wasting are distal though the hands are spared until late.

Mental retardation is frequent.



As the disease progresses, myotonia becomes less apparent and may disappear.

Multisystem features are common but variable

<i>Ocular</i>	<i>Cardiac</i>	<i>Skeletal</i>
ptosis/ophthalmoplegia	dilated cardiomyopathy	frontal hyperostosis
cataracts	atrioventricular conduction defects	<i>Endocrine</i>
retinal pigmentary abnormalities	<i>Respiratory</i>	insulin resistance/diabetes mellitus
	diaphragmatic weakness	infertility
	central sleep apnoea	

These may all predate or dominate over muscle disease

In affected mothers, the disease may present in the neonate with hypotonia, contractures and mental retardation. The mechanism is obscure.

MUSCULAR DYSTROPHIES

MYOTONIC DYSTROPHY (*contd*)

Investigation

The *creatin kinase* (CK) is mildly elevated.

The ECG may show bradycardia with prolonged PR interval.

The EMG shows classic features of myotonia, with waxing and waning in the amplitude and frequency of motor unit potentials, as well as myopathic changes.

Muscle biopsy may be normal or show non-specific type II fibre hypertrophy.

Other investigations:

- Slit lamp examination of the eyes is essential to exclude cataract.
- Plain radiology may show certain bony abnormalities, e.g. hyperostosis frontalis interna, small pituitary fossa.
- Elevated blood insulin levels may be found as may a diabetic glucose tolerance curve.

Myotonic dystrophy must be distinguished from other disorders in which myotonia occurs.

(see later)

Treatment

Drugs blocking Na⁺ channels (phenytoin, procainamide, quinine and mexiletine), may reduce myotonia.

Cardiac conduction defects may need a pacemaker.

Identification and treatment of diabetes mellitus is important.

Sedative drugs are to be avoided as patients show an excessive sensitivity.

Genetic counselling should be given.

Cataracts should be dealt with surgically.

OCULOPHARYNGEAL DYSTROPHY

This is an autosomal dominant disorder presenting in early middle age. Ptosis is the initial finding with progressive involvement of extraocular muscles until paralysis of all eye movements results. The pupillary reactions are spared. Dysphagia, facial weakness and proximal limb weakness develop later.

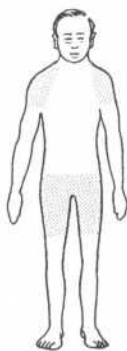
Laboratory findings demonstrate a high CK (5 × normal). Muscle biopsy is characteristic with filamentous inclusions in a proportion of muscle fibres. Treatment is supportive, with death eventually from intercurrent infection. Swallowing difficulties may necessitate cricopharyngeal myotomy.

Distinction must be made from myasthenia gravis and mitochondrial myopathy (see later) in which ptosis is a distinctive feature.

LIMB-GIRDLE MUSCULAR DYSTROPHY

This is an autosomal dominant or recessive disorder with onset often delayed to middle age.

Often muscle involvement is asymmetrical and onset is usually in the pelvic girdle muscles. Progression is slow. The disease may arrest in some patients. Muscle enlargement (calves) occurs in a proportion of cases.



Attempts have been made to subdivide on the basis of pelvic or shoulder girdle onset – this has not been convincing.

The *creatin kinase* (CK) is moderately elevated.

Cardiac involvement does not occur (ECG normal).

EMG studies show non-specific myopathic features.

Muscle biopsy confirms myopathy with connective tissue proliferation.

Differentiation: This distribution of weakness in proximal muscles may be a feature of chronic spinal muscular atrophy, certain metabolic myopathies, polymyositis and Becker's dystrophy.

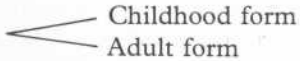
Investigation is essential to classify correctly as EMG and muscle biopsy will distinguish these disorders.

Treatment: Treatment is symptomatic. Genetic counselling is difficult because of the high frequency of sporadic cases, variable inheritance, and absence of CK elevation in the carrier states.

INFLAMMATORY MYOPATHY

Inflammatory myopathies are disorders of muscle in which there is clinical and laboratory evidence of an inflammatory process:

These are acquired muscle disorders as opposed to the *inherited* dystrophies and may be classified as follows:

Polymyositis  Childhood form
Adult form

Dermatomyositis

Inclusion body myositis

Inflammatory myopathy associated with malignant disease

Inflammatory myopathy associated with collagen vascular disorders, e.g. lupus erythematosus, systemic sclerosis, rheumatoid arthritis

Infective – viral, e.g. Coxsackievirus, echovirus, parasitic: e.g. toxoplasmosis, schistosomiasis.

Drug-induced – penicillamine, cholesterol lowering agents e.g. clofibrate, bezafibrate.

POLYMYOSITIS/DERMATOMYOSITIS

There are two principal forms of inflammatory myopathy – polymyositis and dermatomyositis which are separated clinically by the dermatological findings in the latter. All age groups are affected. Annual incidence is 8 per 100 000. These disorders are sporadic though familial cases are described.

An autoimmune basis for these disorders is supported by:

- response to immunosuppressive therapy.
- association with other known immunological disorders, e.g. collagen vascular disorders.
- elevated IgG in blood and presence of circulating autoantibodies, e.g. antinuclear antibody in some cases.
- an increased incidence of certain histocompatibility antigens (HLA antigens)-B₈, DR3.
- the reproduction of a similar disorder in laboratory animals by injection of muscle extract with Freund's adjuvant.

Humoral and cell mediated immune mechanisms seem responsible for these disorders but the trigger factor(s) remain unknown.

INFLAMMATORY MYOPATHY

Clinical presentation

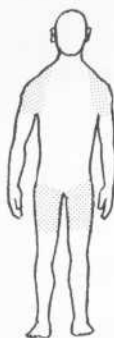
Onset is acute or subacute over a period of several weeks and may follow systemic infection.

Systemic symptoms prevail at onset, e.g. lassitude, and are then followed by muscle weakness. Extensive oedema of skin and subcutaneous tissues is common (especially in the periorbital region).

POLYMYOSITIS

Muscles may be painful and tender in 60% of cases though onset is often painless.

Proximal muscles are first involved and initially weakness may be asymmetrical, e.g. one quadriceps only.



Weakness of posterior neck muscles will result in the head 'lolling' forwards.



Occasionally weakness may spread into distal limb muscle groups.

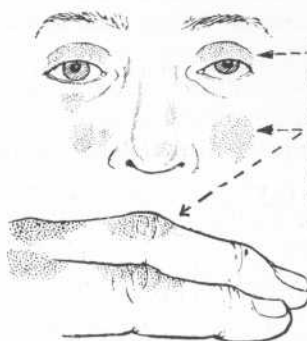
Pharyngeal and laryngeal involvement results in dysphagia and dysphonia. Cardiac muscle may also be involved. Respiratory muscle weakness causes respiratory failure (this may be disproportionately severe).

The eye muscles are *not* involved unless there is coexistent myasthenia gravis.

Reflexes are retained (if absent, consider underlying carcinoma with added neuropathy).

DERMATOMYOSITIS

Often more severe and acute
Characterised by skin rash.
Violet discoloration of light exposed skin.



Heliotropic discoloration of eyelids
Raised scaly erythematous rash involving nose and cheeks, shoulders, extensor surfaces of limbs and knuckles

Telangiectasia and tightening of skin are common and small ulcerated vasculitic lesions develop over bony prominences.

Childhood form

Adult form

Multisystem involvement.
Calcification develops in skin and muscle with extrusion through skin.
Muscle contractures develop – tip-toe gait.
Gastrointestinal ulceration occurs.

The muscle weakness is as in polymyositis but in childhood dermatomyositis may be very severe, involving chewing, swallowing and breathing.

Differential Diagnosis

Inclusion body myositis.

Acid Maltase deficiency (presenting as respiratory failure)

Limb girdle dystrophy.

Drug induced, toxic and metabolic myopathies.

INFLAMMATORY MYOPATHY

Investigations

Diagnosis is supported by the following investigations:

Muscle enzymes

Creatine kinase (CK) is elevated.
Released from necrotic muscle, it is an indicator of disease activity and severity

Circulating antibodies

e.g. rheumatoid factor, antinuclear factor. Present in 40%.

Electromyography

Shows a typical myopathic pattern.

Erythrocyte sedimentation rate (ESR)

Elevated in most patients.

Muscle biopsy shows necrosis of muscle fibres with inflammatory cells – lymphocytes, plasma cells, leucocytes.

Treatment

Steroids – Prednisolone 40–80 mg daily in divided doses with gradual reduction to maintenance (alternate day) dose once improved. If stopped too early, relapse may occur.

Cimetidine protects against the risk of gastrointestinal haemorrhage or perforation.

In refractory cases immunosuppressive drugs – methotrexate, azathioprine, cyclophosphamide, cyclosporin or high dose intravenous immunoglobulin – may be used.

Outcome

Mortality is now low though only 10% recover completely. In the rest, the disease becomes inactive after 2 years and patients are left with varying degrees of disability. When associated with collagen disease, eventual outcome will depend on the nature of that disease. When associated with neoplasm, steroids may cause temporary improvement. Removal of an associated tumour can result in remission.

Prior to the availability of treatment the outcome in inflammatory myopathy was variable and obviously influenced by the presence of associated neoplasia or collagenosis. Periods of relative improvement could occur but generally progression prevailed. Death occurred as a result of respiratory failure, gastrointestinal haemorrhage, perforation and cardiac arrest.

POLYMYOSITIS AND DERMATOMYOSITIS ASSOCIATED WITH MALIGNANT DISEASES

Approximately 10% of adults with inflammatory myopathy have underlying neoplasia usually carcinoma. In dermatomyositis, of those over 40 years of age as many as 60% harbour neoplasia. Neoplasia may present before or after the development of inflammatory myopathy.

POLYMYOSITIS AND DERMATOMYOSITIS ASSOCIATED WITH COLLAGEN VASCULAR DISEASES

Approximately 15% of adults with inflammatory myopathy have symptoms and signs of an associated collagen vascular disorder.

In 5–10% of persons with these disorders (systemic lupus erythematosus etc), inflammatory myopathy develops at some stage in their illness.

In the 'overlap' syndromes (mixed collagen vascular diseases) muscle involvement is more common.

INCLUSION BODY MYOSITIS

Present after age 50 yrs. Patchy and asymmetric in distribution.

Muscle biopsy shows basophilic inclusion granules. Often clinically confused with polymyositis but response to immunotherapy is poor.

ENDOCRINE/METABOLIC MYOPATHIES

Unlike inflammatory myopathy the weakness in these conditions is more chronic and is unassociated pathologically with inflammation. Correction of the underlying endocrine disturbance results in recovery. Usually the other features of endocrine dysfunction are more problematical and myopathy is of secondary importance.

Pituitary

Acromegaly

Proximal weakness with fatigue. Entrapment neuropathies, e.g. carpal tunnel syndrome may complicate the clinical picture of myopathy. Other features of growth hormone excess are evident.

Parathyroid

Hyperparathyroidism and osteomalacia.

Weakness of a proximal distribution with muscle tenderness occurs in 50% of patients with osteomalacia but is less common in primary hyperparathyroidism. The legs are mainly affected and a waddling gait results.

Adrenal

Hyperadrenalism and hypoadrenalism

These may both be associated with proximal myopathy. In patients treated with steroids, a similar picture may develop rapidly when drug induced. Reduction of steroid dosage results in improvement.

Thyroid

Hyperthyroidism

Weakness occurs in 20% of thyrotoxic patients. Shoulder girdle weakness is more marked than pelvic. Reflexes are brisk, fasciculation and atrophy may be present. *Distinction must be made from motor neuron disease.* There is always clinical evidence of thyrotoxicosis in these patients. Diagnosis is confirmed by thyroid function studies.

Hypothyroidism

Proximal weakness involves pelvic girdle more than shoulder. Painful cramps and muscle stiffness are common.

Muscle enlargement in limbs and tongue often occur. There is always clinical evidence of hypothyroidism in these patients. Diagnosis is confirmed by thyroid function tests and response to thyroid hormone therapy is excellent.

In chronic proximal weakness, careful clinical history taking, examination and appropriate investigation will separate the various endocrine causes.

METABOLIC MYOPATHIES: THE PERIODIC PARALYSES

These disorders are characterised by defective skeletal muscle voltage – sensitive ion channels (channelopathies):

Hypokalaemic periodic paralysis

Autosomal dominant.
Chromosomal location and defective gene unknown.
Onset in second decade.
Precipitated by: exercise, carbohydrate load.
Commences in proximal lower limb muscles and rapidly becomes generalised. Onset usually in morning on waking.
Bulbar muscles/respiration unaffected.
 K^+ falls as low as 1.5 meq/l.
Treatment:
Acute – oral KCl.
Prophylactic – acetazolamide; low carbohydrate, high K^+ diet.
With age, attacks become progressively less frequent.

Non-familial hypokalaemic periodic paralysis may occur in patients suffering from hyperthyroidism or on potassium-depleting diuretics.

Hyperkalaemic periodic paralysis

Autosomal dominant or recessive.
Chromosome 17 location.
 Na^+ channel gene defect
Onset in infancy/childhood.
Precipitated by: rest after activity or by cold.
Commences in lower limbs and evolves rapidly.
Attacks are of short duration (less than 60 min).
Myotonia is evident in some patients.
 K^+ rises only slightly.
Treatment:
Acute – intravenous calcium gluconate or sodium chloride.
Prophylactic – Na^+ channel blockers, Tocainide or Mexiletine.

Paramyotonia Congenita


Autosomal dominant.
Chromosome 17 location.
 Na^+ channel gene defect
Onset in infancy.
Precipitated by: rest after exercise, fasting and cooling.
Commences in proximal muscles.
Repetitive muscle contractions produce increasing stiffness.
EMG findings are specific with marked spontaneous activity in limb cooling.
Treatment. Na^+ channel blockers, Tocainide or Mexiletine.

METABOLIC MYOPATHIES

A group of genetically determined biochemical disorders of muscle characterised by myalgia, cramps, weakness and fatigue. These are divided into conditions with *reduced exercise tolerance* and those of *static weakness*.

REDUCED EXERCISE TOLERANCE

McArdle's disease – disorder of carbohydrate metabolism, – block in glycolytic pathway (phosphorylase deficiency).



Diagnosis: Failure of serum lactate to rise following exercise.
Muscle biopsy – absence of phosphorylase activity with appropriate histochemical staining.

Treatment with oral fructose may help.

Carnitine palmityl deficiency – disorder of fatty acid metabolism autosomal recessive localised to chromosome I.

Clinically, muscle weakness and contractures occur with exercise in children or adults. A failure to produce ketones following prolonged fast and a normal elevation in serum lactate following exercise differentiates this condition from McArdle's disease. Enzyme deficiency is shown in biochemical assay on muscle biopsy.

STATIC (FIXED) WEAKNESS

Acid maltase deficiency

The development in adult life of limb girdle weakness characterises this disorder. In some, selective involvement of the respiratory muscles causes respiratory failure.

Acid maltase deficiency occasionally presents in infancy with a floppy hypotonic weakness associated with an enlarged tongue.

Diagnosis: Confirmed by muscle biopsy.

Carnitine deficiency

Autosomal recessive lipid storage myopathy. In *systemic deficiency* onset is in childhood with cardiac and liver involvement. Untreated this is fatal. In *muscle deficiency* alone, proximal weakness and exercise induced pain are sole manifestations. Muscle biopsy shows lipid droplets. Plasma and muscle carnitine levels are low.

MITOCHONDRIAL DISORDERS

These conditions are considered with muscle diseases due to the frequency of muscle involvement. They are characterised by biochemical and genetic evidence of mitochondrial dysfunction, are maternally inherited or sporadic and often show features of multi-organ disease – renal failure, diabetes mellitus, cataract, deafness, cardiomyopathy. Neurological manifestations predominate.

Certain specific syndromes are recognised though overlap and diversity of phenotype is common.

CPEO (Chronic progressive external ophthalmoplegia)

Adolescence/adult onset of ptosis and ophthalmoplegia (without diplopia) often associated with mild proximal myopathy. When associated with heart block and retinopathy – Kearns Sayre syndrome (KSS).

Differentiate from ocular myasthenia (page 148).

Investigations Large deletion in mitochondrial DNA (mt DNA) in skeletal muscle biopsy and serum.

Prognosis good with very slow progression. Heart block may require pacing.

MELAS (Mitochondrial encephalopathy, lactic acidosis and stroke-like syndrome)

Adult onset of stroke-like episodes (posterior hemisphere) associated with focal seizures and vascular headache. 'Strokes' are not in vascular territories and are due to failure to utilise substrates rather than to a lack of them.

Differentiate from other causes of 'young' stroke.

Investigations CT/MRI shows posteriorly placed ischaemic changes, elevated lactate in serum and CSF. 'Ragged red' fibres on muscle biopsy and two-point mutation in tRNA Leu gene of mt DNA.

Prognosis is variable. Seizures and headache followed by 'strokes' and eventual dementia

NARP (Neuropathy, ataxia and retinitis pigmentosa)

Adult onset of sensory/motor neuropathy, ataxia and chronic visual impairment. The rarest mitochondrial syndrome. In some, shares a similar molecular basis as Leigh's syndrome and can demonstrate maternal, autosomal recessive or X linked inheritance.

Differentiate from other causes of ataxic neuropathy e.g. Freidreich's.

Investigations Point mutations mt DNA (ATPase) detected in serum.

Prognosis is uncertain, dementia occurs in time.

MERRF (Myoclonic epilepsy with ragged red fibres)

Adult onset of myoclonus, seizures and ataxia occasionally associated with respiratory failure. Disease expression is variable.

Differentiate from other types of myoclonic epilepsy.

Investigations Elevated lactate i.e. serum and CSF.

'Ragged red' fibres in muscle biopsy and point mutation in tRNA Lys gene of mt DNA in skeletal muscle biopsy and serum.

Prognosis is poor in fully expressed disease – death from seizures or respiratory failure.

LHON (Leber's hereditary optic neuropathy)

Adult subacute onset of loss of central vision, initially unilateral but bilateral in all patients after 1 year.

Visual acuity may be reduced to hand movements only due to marked optic atrophy. Male/female ratio: 3:1.

Differentiate from optic neuritis, alcohol/tobacco amblyopia and anterior ischaemic optic neuropathy.

Investigations Several mt DNA mutations have been detected in serum.

Prognosis for visual recovery varies and depends on the specific mutation, as do other accompanying neurological features. In the majority visual loss is irreversible.

Leigh's syndrome

Infant or childhood onset of subacute necrotising encephalomyelopathy characterised by psychomotor retardation, ataxia, optic atrophy and ophthalmoplegia.

Differentiate from other causes of progressive encephalopathy of childhood e.g. inborn errors of metabolism.

Investigations CT/MRI brain stem changes, elevated lactate and pyruvate dehydrogenase complex in CSF and serum and various mutations at Xp 22.1 and mt DNA (ATPase).

Prognosis is poor with early death.

There is no proven therapy for these conditions. Co-morbid conditions such as infection, cardiac involvement and diabetes mellitus should be treated conventionally. Pharmacologic therapies that may bypass biochemical defects are worth using e.g. L. Carnitine, Ubiquinone, riboflavin, thiamine and free radical scavengers (Vits C and E).

MYASTHENIA GRAVIS

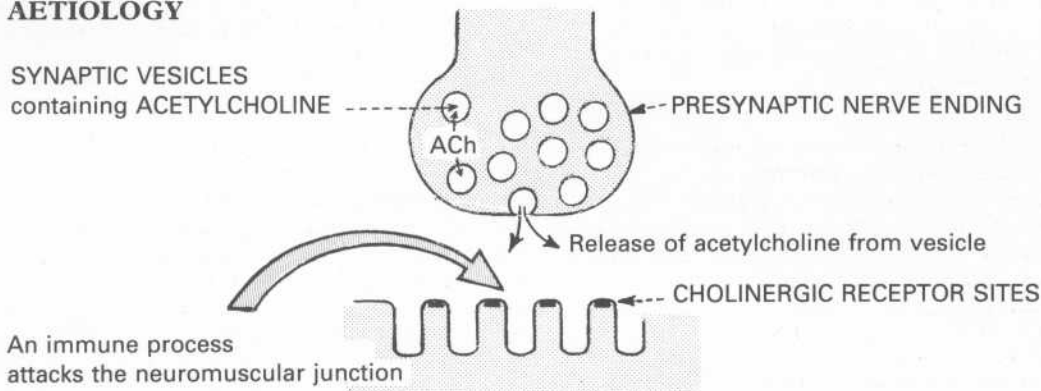
Myasthenia gravis is a disorder of neuromuscular transmission characterised by:

- Weakness and fatiguing of some or all muscle groups.
- Weakness worsening on sustained or repeated exertion, or towards the end of the day, relieved by rest.

This condition is a consequence of an autoimmune destruction of the NICOTINIC POSTSYNAPTIC RECEPTORS FOR ACETYLCHOLINE.

Myasthenia gravis is rare, with a prevalence of 5 per 100 000. The increased incidence of autoimmune disorders in patients and first degree relatives and the association of the disease with certain histocompatibility antigens (HLA) - B₇, B₈ and DR₂ - suggests an IMMUNOLOGICAL BASIS.

AETIOLOGY



Antibodies bind to the receptor sites resulting in their destruction (complement mediated). These antibodies are referred to as ACETYLCHOLINE RECEPTOR ANTIBODIES. (AChR antibodies) and are demonstrated by radioimmunoassay in the serum of 90% of patients.

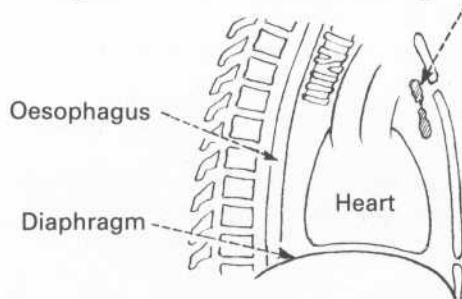
Human purified IgG (containing AChR antibodies) injected into mice induces myasthenia-like disease in these recipient animals.

In human myasthenia gravis a reduction of acetylcholine receptor sites has been demonstrated in the postsynaptic folds. Reduced receptor synthesis and increased receptor destruction, as well as the blocking of receptor response to acetylcholine, all seem responsible for the disorder.

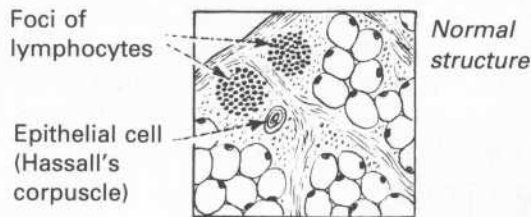
The rôle of the thymus: Thymic abnormalities occur in 80% of patients. The main function of the thymus is to effect the production of T-cell lymphocytes, which participate in immune responses. Thymus dysfunction is noted in a large number of disorders which may be associated with myasthenia gravis, e.g. systemic lupus erythematosus.

MYASTHENIA GRAVIS – PATHOLOGY

Changes are found in the THYMUS gland and in muscle.

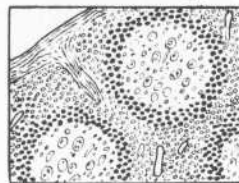


The gland is most active during the induction of normal immune responses in the neonatal period and attains its largest size at puberty after which it involutes.



In myasthenia gravis:
20%: involuted gland

70%: show hyperplasia



with lymphoid follicles demonstrating germinal centres

10%: thymoma, an encapsulate tumour of lymphoid and epithelial cells which may be locally invasive but rarely metastasises.

Muscle biopsy may show abnormalities:

- Lymphocytic infiltration associated with small necrotic foci of muscle fibre damage.
- Muscle fibre atrophy (type I and II or type II alone).
- Diffuse muscle necrosis with inflammatory infiltration (when associated with thymoma).

Motor point biopsy may show abnormal motor endplates. Supravital methylene blue staining reveals abnormally long and irregular terminal nerve branching.

Light and electron microscopy show destruction of ACh receptors with simplification of the secondary folds of the postsynaptic surface.

CLINICAL FEATURES

Up to 90% of patients present in early adult life (<40 years of age). Female: male ratio 2:1. The disorder may be selective, involving specific groups of muscles.

Several clinical subdivisions are recognised:

- | | |
|----------------------------------------------------------------------------|-------|
| Class 1 – ocular muscles only – 20% | } 80% |
| Class 2 – Mild generalised weakness | |
| Class 3 – Moderate generalised and mild to moderate ocular-bulbar weakness | |
| Class 4 – Severe generalised and ocular-bulbar weakness | |
| Class 5 – Myasthenic crises | |

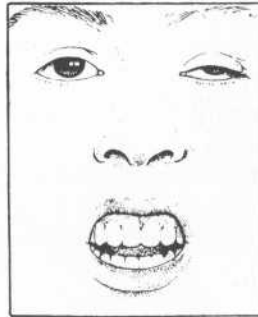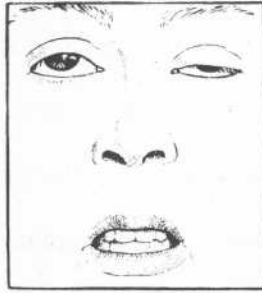Approximately 40% of class I will eventually become widespread. The rest remain purely ocular throughout the illness.

Respiratory muscle involvement accompanies severe illness.

MYASTHENIA GRAVIS – CLINICAL FEATURES (contd)

Cranial nerve signs and symptoms

- Ocular involvement produces ptosis and muscle paresis.
- Weakness of jaw muscles allows the mouth to hang open.
- Weakness of facial muscles results in expressionless appearance.



- On smiling, buccinator weakness produces a characteristic smile (myasthenic snarl).

Bulbar involvement may result in:

- dysarthric dysphonic speech and dysphagia.
- nasal regurgitation of fluids – nasal quality to speech.

Weakness of eye opening (ptosis) ... and eye closing ... in the same patient is characteristic. (failure to 'bury' eyelashes)

The demonstration of *fatiguing* is important in reaching diagnosis and in monitoring the response to treatment:

'Look upwards' SECONDS SECONDS Ptosis becomes apparent and the eye drifts to neutral position

'Look left' SECS SECS Ptosis becomes apparent and a dysconjugate drift develops

Fatiguing of other bulbar muscles may be demonstrated by:

- blowing out cheeks against pressure.
- counting as far as possible in one breath, etc.

The tongue occasionally shows the characteristic triple grooved appearance with two lateral and one central furrow.

Limb and trunk signs and symptoms

Weakness of neck muscles may result in lolling of the head. Proximal limb muscles are preferentially affected. Fatigue may be demonstrated by movement against a constant resistance.

Limb reflexes are often hyperactive and fatigue on repeated testing.

Muscle wasting occurs in 15% of cases.

Stress, infection and pregnancy and drugs that alter neuromuscular transmission all exacerbate the weakness

Natural history: (Before treatment became available)

- 10% of patients entered a period of remission of long duration.
- 20% experienced short periods of remission (1 to several months).
- 30% progressed to death.
- The remainder showed varying degrees of disability accentuated by exercise.

MYASTHENIA GRAVIS – DIFFERENTIAL DIAGNOSIS

Distinguish from:

- The patient who complains of fatiguing easily – neurotic, hysterical or depressed individual.
- The patient with progressive ophthalmoplegia, e.g. mitochondrial myopathy, oculopharangeal dystrophy.
- The patient with multiple sclerosis – diplopia, dysarthria and fatigue with a relapsing and remitting course.
- The patient with the Lambert-Eaton myasthenic syndrome (see page 529).

INVESTIGATION

PHARMACOLOGICAL

Anticholinesterase drugs are used to confirm diagnosis.

Tensilon (edrophonium) – short action, 2–4 minutes, given i.v. 2–10 mg slowly, with atropine available to counter muscarinic side effects (nausea and bradycardia). This is positive when noticeable improvement in weakness occurs on objective testing. A control injection of saline is useful, especially when assessing limb weakness only. The Tensilon test may be negative in ocular myasthenia and give a false positive in the Lambert-Eaton syndrome.

SEROLOGICAL

Acetylcholine receptor antibodies are detected in 90% of patients and are virtually specific to this disease. In ocular myasthenia, only 60% show antibodies. Magnitude of titres correlates with disease severity.


Other antibodies e.g. microsomal, colloid, rheumatoid factor, gastric parietal cell antibody – are occasionally found. These reflect the overlap between myasthenia gravis and other autoimmune disorders.

Anti striated muscle antibodies are found in 30% of all patients and in 90% of those with thymoma.

ELECTROPHYSIOLOGICAL

Reduction of the amplitude of the compound muscle action potential evoked by repetitive supramaximal nerve stimulation – ‘the decrementing response’.

Various rates of stimulation; even as low as 3/second may produce a decrementing response.



Single fibre electromyography – measure of ‘jitter’ – the time interval variability of action potentials from two single muscle fibres of the same motor unit – is a more sensitive index of neuromuscular function and is increased (95% of mild cases are abnormal).

ADDITIONAL

Chest X ray will show a large mediastinal mass but will not exclude a small thymoma. CT of chest should be performed in *all* newly diagnosed cases.

MYASTHENIA GRAVIS – TREATMENT

In severely ill patients, the first priority is to protect respiration by intubation and, if necessary, ventilation.

Anticholinesterase drugs

This is the longest established form of treatment (1930s).

Anticholinesterase drugs inhibit **cholinesterase**, the enzyme responsible for the breakdown of acetylcholine, allowing enhanced receptor stimulation. As a result, more acetylcholine is available to effect neuromuscular transmission.

ANTICHOLINESTERASES	DURATION OF ACTION	METHOD OF ADMINISTRATION
Edrophonium	4 min	– Intravenous
Neostigmine	2 hours	– Intravenous, intramuscular, oral
Pyridostigmine	4 hours	– Oral

A muscarinic inhibitor, atropine, may be required to counter side effects. (nausea, vomiting, diarrhoea, muscle fasciculations and increasing weakness). Anticholinesterases rarely give complete symptomatic relief and large doses can result in a *cholinergic crisis*

- worsening weakness
- increased sweating, saliva and bronchial secretions
- small pupils (miosis)
- eventual respiratory failure.

Atropine may mask early warning symptoms of this potential life-threatening state.

Steroids

Because this disorder is immune-mediated steroids are a logical choice in generalised and occasionally severe ocular disease. Prednisone 60 mg/day is initially used. Deterioration may briefly occur before improvement. Once a response occurs, dosage is reduced to alternate days.

Immunosuppressants other than steroids

These drugs (azathioprine, cyclophosphamide and cyclosporine) are considered in patients who do not respond to steroids or who require an unacceptably high steroid maintenance dose.

Thymectomy

There are two indications for this:

1. When thymoma is present
 2. When myasthenia is generalised and benefits of surgery outweigh risks.
- Trans-sternal is preferred to supra-sternal approach giving better chance of total clearance. Within 5 yrs of surgery 80% of patients are in remission.

MYASTHENIA GRAVIS – TREATMENT (*contd*)

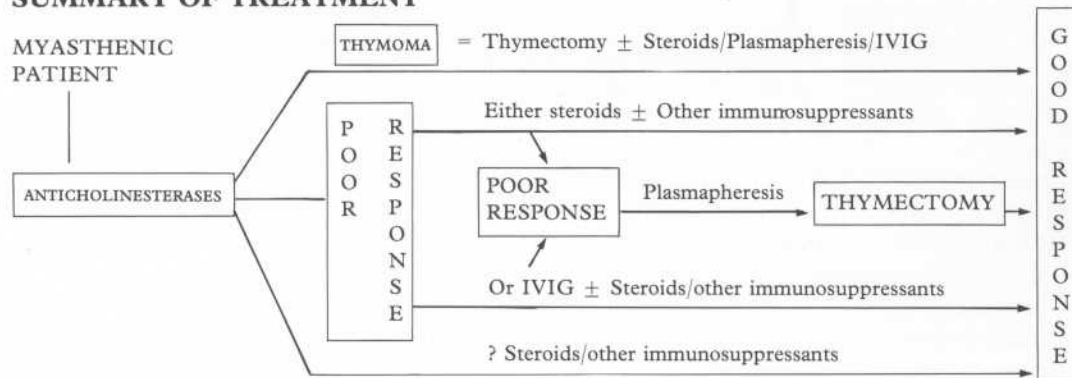
Plasmapheresis

Plasma filtration removes antibodies and other circulating factors and has short term benefit (4–6 weeks). A plasma volume of 1.5–2 litres is exchanged 3–5 times over a 6–8 day period. The technique is expensive and carries risks (hypotension, metabolic disturbance and thrombo-embolism). It is used to stabilise refractory cases and prior to thymectomy in severe disease.

Immunoglobulin (IVIG)

May be used in place of plasmapheresis at a dose of 400 mg per Kg intravenously daily for 5 days. Mechanism may act by blocking ACh receptors. A positive response (75% of patients) lasts for 2–3 months. Treatment is expensive and long term effects and complications unknown.

SUMMARY OF TREATMENT



Anticholinesterases should not be required throughout the whole illness. When immunological control of the disease is obtained, these drugs may be stopped.

EMERGENCY TREATMENT – MYASTHENIC/CHOLINERGIC CRISES

- Identify and treat precipitating cause, e.g. infection, drug interaction or overdose
- Sit patient at 45°, clear airway, give nasal O₂ and if overt respiratory failure – intubate and ventilate for as long as required.

Myasthenic crisis

- IV neostigmine 8–12 mg/24 hrs
- sc. atropine 0.5 mg tds
- Prednisilone 100 mg daily
- Consider plasmapheresis or IVIG
- Change IV to oral anticholinesterases when able to swallow

Cholinergic crisis

- Withdraw all anticholinesterases
- Monitor respiratory function (vital capacity)
- Wean from ventilation when appropriate
- Re-introduce oral anti-cholinesterases in low dose and gradually increase

NEONATAL form of myasthenia gravis: this develops in a number of infants of myasthenic mothers.

- Suggested by poor crying/sucking and floppy limbs.
- Presents within 48 hours of birth and may persist until the end of 3rd month.
- Caused by passive transplacental passage of IgG (acetylcholine receptor antibodies).
- Treatment with anticholinesterases is required until spontaneous recovery occurs. Remission occurs following exchange transfusion.

This disorder may occur in infants even when their mother has been in remission for many years.

CONGENITAL form of myasthenia gravis

This usually commences in infancy and persists through adult life. Receptor antibodies are not found and the disease may result from structural abnormalities of the receptors themselves. (A number of such disorders have been identified.) Thymectomy is contraindicated in this disorder.

MULTIFOCAL NEUROLOGICAL DISEASE AND ITS MANAGEMENT

BACTERIAL INFECTIONS – MENINGITIS

ACUTE BACTERIAL MENINGITIS

Acute bacterial meningitis is an acute infection of the subarachnoid space and meninges characterised by polymorphonuclear cells in the cerebrospinal fluid. Bacteria may invade the subarachnoid space directly by spread from contiguous structures, e.g. sinuses, or more commonly, indirectly from the bloodstream.

Causative organisms

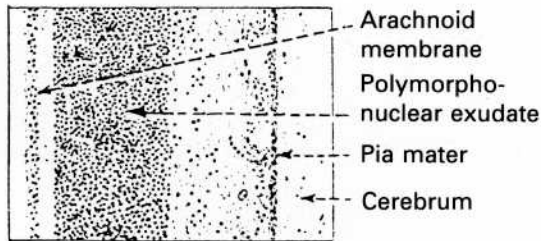
- In neonates – Gram -ve bacilli, e.g. *E. coli*, *Klebsiella*, *Haemophilus influenzae*.
 - In children – *Haemophilus influenzae*. Pneumococcus (*Strep. pneumoniae*). Meningococcus. (*Neisseria meningitidis*).
 - In adults – Pneumococcus. Meningococcus.
- Other bacteria – *Listeria monocytogenes*, *Streptococcus pyogenes* and *Staphylococcus aureus* – are occasionally responsible.

Host factors (congenital or acquired immune deficiency, hyposplenism and alcoholism) predispose to infection. as do environmental factors (overcrowding and poverty).

Infections of mixed aetiology (two or more bacteria) may occur following head injury, mastoiditis or iatrogenically after lumbar puncture.

Pathology

The presence of the blood brain barrier limits host defence mechanisms and enables multiplication of organisms.



A purulent exudate most evident in the basal cisterns extends throughout the subarachnoid space.

The underlying brain, although not invaded by bacteria, becomes congested, oedematous and ischaemic.

The integrity of the pia mater normally protects against brain abscess formation.

The inflammatory exudate may affect vascular structures crossing the subarachnoid space producing an *arteritis* or *venous thrombophlebitis* with resultant *infarction*. Similarly, cranial nerves may suffer direct damage.

Hydrocephalus can result from obstruction to CSF flow in the ventricles and subarachnoid space.

Clinical

The classical clinical triad is fever, headache and neck stiffness.

Prodromal features (variable)

A respiratory infection
otitis media or pneumonia
associated with muscle pain
backache and lethargy.

Meningitic symptoms

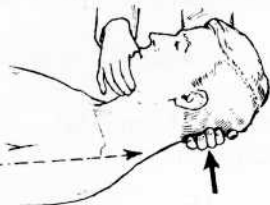Severe frontal/occipital headache
Stiff neck
Photophobia.

ACUTE BACTERIAL MENINGITIS

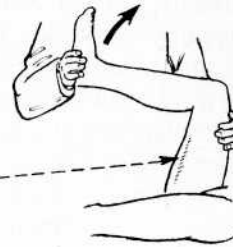Clinical (contd)

Systemic signs: – High fever. Transient purpuric or petechial skin rash in meningococcal meningitis.

Meningitic signs:
Neck stiffness – gentle flexion of the neck is met with boardlike stiffness



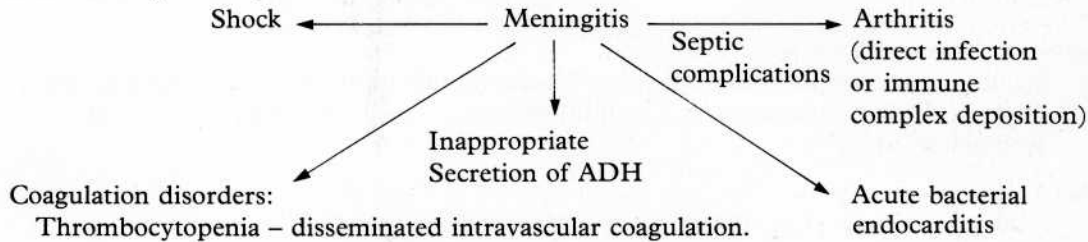
Kernig's sign – stretching the lumbar roots produces pain



Associated neurological signs

- Impaired conscious level (90%)
- Focal or generalised seizures are frequent (30%).
- Cranial nerve signs occur in 15% of patients.
- Sensorineural deafness (not due to concurrent otitis media but to direct cochlear involvement) – 20%
- Focal neurological signs – hemiparesis, dysphasia, hemianopia – occur in 10%.

Non-neurological complications



Features specific to causative bacteria

<i>Haemophilus meningitis</i>	<i>Meningococcal meningitis</i>	<i>Pneumococcal meningitis</i>
Generally occurs in small children. Preceding upper respiratory tract infection. Onset abrupt with a brief prodrome.	Often occurs in epidemics where the organism is carried in the nasopharynx. Septicaemia can occur with arthralgia; purpuric skin rash. When overwhelming, confluent haemorrhages appear in the skin due to disseminated intravascular coagulation.	Predominantly an adult disorder. Usually associated with debilitation, e.g. alcoholism. May result from pneumonia, middle ear, sinus infection or follow splenectomy. Onset may be explosive, progressing to death within a few hours. Mortality – 20%.
Outcome Generally good Less than 5% mortality.	Gradual onset – good prognosis. Sudden onset with septicaemia – poor outcome. Overall mortality – 10%.	Poor prognostic signs – coma, seizures, low cell count in CSF.

ACUTE BACTERIAL MENINGITIS

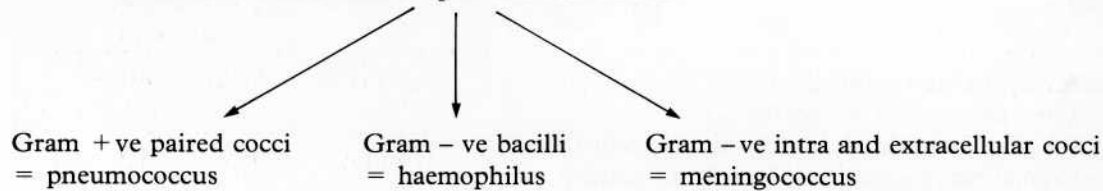
Investigations

1. If patient is in coma or has papilloedema or focal neurological signs → exclude an intracranial mass with a *CT scan*. If the patient is deteriorating rapidly, or has a bleeding disorder that cannot be rapidly corrected, take off blood cultures and commence antibiotics (see below) *prior* to scanning.

2. If above signs are absent or CT scan excludes a mass lesion → *confirm diagnosis with a lumbar puncture and identify the organism.*

CSF examination – moderate increase in pressure < 300 mm CSF.

– Gram stain of spun-down sediment.



- cell count is elevated, 100–10 000 cells/mm³ (80–90% polymorphonuclear leucocytes).
- glucose is depressed.
- enzyme lactic dehydrogenase is elevated.
- culture CSF

Serological/immunological tests

- countercurrent immunoelectrophoresis detects capsular antigen in CSF; leads to rapid diagnosis if CSF microscopy is unhelpful, especially if patient has already started antibiotics.

Blood cultures

- Organism isolated in 80% of cases of *Haemophilus meningitis*.
- Pneumococcus and meningococcus in less than 50% of patients.

3. Check serum electrolytes.

- important in view of the frequency of inappropriate antidiuretic hormone secretion in meningitis.

4. Detect the source of infection.

- Chest X-ray – pneumonia
- Sinus X-ray – sinusitis
- Skull X-ray – fracture
- Petrous views – mastoiditis

Treatment

Once meningitis is suspected, treatment must commence immediately, often before identification of the causative organism. Antibiotics must penetrate CSF, be in appropriate bacteriocidal dosage and be sensitive to causal organism once identified.

Initial therapy (before organism identification)

Neonates (above 1 month) – ampicillin, + aminoglycoside and cephalosporin

Children (under 5 years) – ampicillin, + cephalosporin

Adults – penicillin G, or cephalosporin

472 Immunocompromised patient – ampicillin + cephalosporin

ACUTE BACTERIAL MENINGITIS

Treatment (contd)

Therapy after organism identification

ORGANISM	ANTIBIOTIC	CHILD mg/kg/day	ADULT	ALTERNATIVE THERAPY
<i>Haemophilus</i>	Chloramphenicol and/ or cefotaxime	100 200	2-4 g/day 6-12 g/day	Ampicillin Cefuroxime
Pneumococcus	Benzympenicillin	180	20 million units	Chloramphenicol Cefotaxime Cefuroxime
Meningococcus	Benzympenicillin	180	20 million units	Chloramphenicol Cetatin
<i>E. coli</i>	Cefotaxime	200	6-12 g/day	Ampicillin Gentamicin
<i>Listeria</i>	Ampicillin ± gentamicin	200 5-7	8 g/day (5-7 mg/kg/day)	Chloramphenicol Cotrimoxazole

Duration

Meningococcus }
Haemophilus } continue for at least 1 week after afebrile.

Pneumococcus – continue for 10-14 days after afebrile.

Monitoring

In a deteriorating patient, CT scan will exclude the development of hydrocephalus, abscess or subdural empyema. In suspected sinus thrombosis MR venography may be required.

Remove any source of infection, e.g. mastoidectomy or sinus clearance.

In meningococcal meningitis the risk to household contacts is increased (500-800 x) and chemoprophylaxis should be offered – rifampicin 600 mg b.d. for 48 hours. Vaccines are also available.

In the critically ill, intensive supportive therapy may be required. Recent trials in children suggest that adjunctive therapy with steroids (dexamethasone) improves outcome – this may be due to reducing cytokines, released when organisms are destroyed. In adults benefit of steroids is less certain.

Meningitis/CSF shunts

Meningitic infection may follow CSF drainage operations for hydrocephalus. This may occur in the immediate postoperative period or be delayed for weeks or months. Clinical features of raised intracranial pressure may coexist due to shunt blockage. Bacteraemia is inevitable and blood cultures identify the responsible organism – usually *Staphylococcus albus*. The infection seldom resolves with antibiotic therapy alone and shunt removal is usually required.

BACTERIAL INFECTIONS – CNS TUBERCULOSIS

Tuberculosis is an infection caused in man by one of two mycobacteria – *Mycobacterium tuberculosis* and *Mycobacterium bovis*. The disease involves the nervous system in 10% of patients.

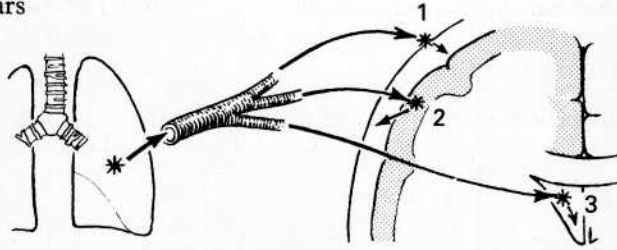
MENINGITIS

This is the commonest manifestation of tuberculous infection of the nervous system. *In children*, it usually results from bacteraemia following the initial phase of primary pulmonary tuberculosis.

In adults, it may occur many years after the primary infection.

Following bacteraemia, metastatic foci of infection lodge in:

1. Meninges
2. Cerebral or spinal tissue
3. Choroid plexus



Rupture of these encapsulated foci results in spread of infection into the subarachnoid space. In adults, reactivity of metastatic foci may occur spontaneously or result from impaired immunity (e.g. recent measles, alcohol abuse, administration of steroids).

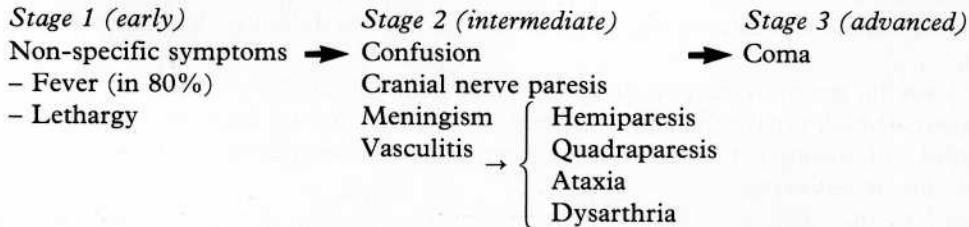
The clinical features of tuberculous meningitis (TBM) result from:

- Infection.
- Exudation – which may obstruct the basal cisterns and result in hydrocephalus.
- Vasculitis – secondary to inflammation around vessels, resulting in infarction of brain and spinal cord.

The basal meninges are generally most severely affected.

Clinical features

The majority of patients are adults; childhood TBM is now rare. Non-specific prodromal symptoms develop over 2–8 weeks.



Staging is useful for predicting outcome.

Seizures may occur at the onset. Involuntary movements (chorea, myoclonus) occur in 10%.

Atypically the illness may develop slowly over months presenting with dementia or rapidly like pyogenic (bacterial) meningitis. Occasionally cerebral features prevail rather than signs of meningitis.

Untreated, the illness may progress from phase 1 to death over a 3-week period.

Arachnoiditis inflammatory exudate may result in hydrocephalus/dementia/blindness.

TUBERCULOUS MENINGITIS

Investigations

General: Anaemia, leucocytosis. Hyponatraemia (if inappropriate ADH secretion occurs).

Cerebrospinal fluid: A lymphocytic pleocytosis is usually present, though in acute cases polymorphonuclear cells may predominate – 500/mm³. (range 50–4000/mm³)

The protein is elevated – 1–5 g/l.

The glucose level is usually less than two-thirds of simultaneously measured blood glucose.

Microscopy (Ziehl Neelsen stain) reveals acid-fast bacilli in 20% of patients.

CSF culture (6 weeks in Lowenstein-Jensen medium) should confirm the diagnosis.

Polymerase chain reaction (PCR) is increasingly available for the detection of bacterial DNA.

Chest X-ray: Reveals changes of old or recent tuberculosis in 50–70% of adults and 90% of children.

PPD skin test (tuberculin): Positive to intermediate strength in 60%. Patients developing TBM while on steroids or with recently acquired primary tuberculosis may give a negative response.

CT/MRI: Shows meningeal enhancement on basal views, ventricular enlargement, associated infarction and tuberculomas in 10% (see page 347).

Diagnosis

Diagnosis is based on the clinical presentation with characteristic CSF findings. Even if Ziehl Neelsen staining is negative, in view of the progressive disease course do not await the results of cultures before starting treatment.

DIFFERENTIAL DIAGNOSIS of subacute/chronic meningitis (see pages 497, 498).

{	<p>Viral meningoencephalitis (with <i>normal</i> CSF sugar).</p> <p>Carcinomatous meningitis (with <i>high</i> CSF protein, <i>low</i> CSF sugar).</p> <p>Partially treated bacterial meningitis.</p> <p>Fungal meningitis. Sarcoidosis.</p>
---	----------------------------------------------------------------------------------------------------------------------------------------------------------------------------------------------------------------------------------------------

Treatment

If suspect, commence antituberculous treatment.

Recommended treatment programme:

Normal regime:

Isoniazid (300 mg daily)	→ 2 months →	Isoniazid	→	6 months
Rifampicin (600 mg daily)		Rifampicin		
Pyrazinamide (15–30 mg/kg daily)				

Drug resistance suspected due to previous antituberculous therapy, e.g.

- Third World countries
- History of previous infection.

→ Add a fourth drug – streptomycin (1 g daily) or ethambutol (25 mg/kg daily).

Isoniazid and pyrazinamide penetrate meninges well; other drugs penetrate less well especially when the inflammation begins to settle.

TUBERCULOUS MENINGITIS

Treatment (*contd*)

Side effects:

- Isoniazid may produce peripheral neuropathy – protect with pyridoxine 50 mg daily.
- Ethambutol may produce optic atrophy – check colour vision.
- Streptomycin may cause 8th cranial nerve damage (vertigo and deafness).
- Nausea, vomiting, abnormal liver function and skin rashes may occur with all antituberculous drugs.

Intrathecal therapy: Since CSF penetration, especially with streptomycin, is poor, some recommend intrathecal treatment. Streptomycin 50 mg may be given daily or more frequently in seriously ill patients.

When obstructive hydrocephalus occurs, combined intraventricular (through the shunt reservoir or drainage catheter) and lumbar intrathecal injections may be administered.

Steroid therapy: Many clinicians combine antituberculous therapy with steroids in the hope that these will minimise the risk of obliterative endarteritis and arachnoid adhesions.

Although benefits are uncertain, steroids are recommended in patients with:

- deteriorating conscious level
- progressive neurological signs
- evidence of spinal block.

Hydrocephalus

Progressive dilatation of the ventricles impairing conscious level requires CSF drainage – either temporarily with a ventricular catheter (permitting intraventricular drug administration) or permanently with a ventriculoperitoneal/atrial shunt. Surgery may also be considered for co-existent tuberculomas and tuberculous abscesses though these often resolve with drug therapy.

The course of treated tuberculous meningitis

Outcome is influenced by the patient's age, general state of health, timing of initiation of treatment and the development of arachnoiditis and vascular complications.

Treatment in early stages is associated with a 10% mortality, in later stages with a 50% mortality. Of those who survive, neurological sequelae persist in 30% – hemiplegia, hypothalamic/pituitary dysfunction, blindness, deafness, dementia and epilepsy.

With treatment, CSF sugar quickly returns to normal; the cellular reaction gradually diminishes over 3–4 months; the protein level may take a similar time to return to normal.

Tuberculous meningitis in AIDS

A typical mycobacteria such as *M. avium* and *fortuitum* should be considered. Response to treatment is generally good. TBM tends to occur in the earlier phases of immunodeficiency with CD4 T cell count, at <400 per mm^3 .

OTHER FORMS OF CNS TUBERCULOUS INFECTION

TUBERCULOMAS OF THE BRAIN

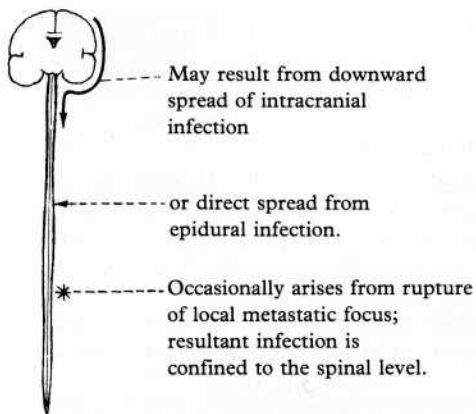
Tuberculomata may occur in cerebral hemispheres, cerebellum or brain stem with or without tuberculous meningitis, and may produce a space-occupying effect. They consist of caseating granulomas made up of epithelioid cells and macrophages containing mycobacteria. Lesions may be single or multiple. CT and MRI demonstrate lesions but appearances are not pathognomonic. Most resolve over a few weeks with antituberculous therapy.

POTT'S DISEASE

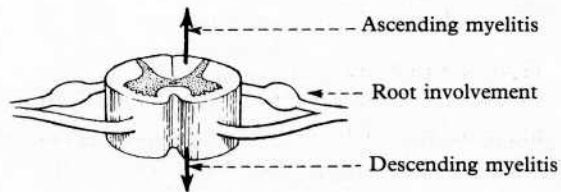
Chronic epidural infection follows tuberculous osteomyelitis of the vertebral bodies. This arises in the lower thoracic region, can extend over several segments and may spread through the intervertebral foramen into pleura, peritoneum or psoas muscle (psoas abscess) – see page 390.

TUBERCULOUS MENINGOMYELITIS

Infection of the leptomeninges results in an exudate that encases the spinal cord and nerve roots. This produces back pain, paraesthesia, lower limb weakness and loss of bowel and bladder control. Imaging may be normal while CSF shows high protein, lymphocytes and rarely acid fast bacilli. This disorder is now more frequent in AIDS patients. Differential diagnosis includes cytomegalovirus, cryptococcus, syphilis and lymphoma. Laminectomy and meningeal biopsy may be required to establish diagnosis. When suspected, empirical therapy with antituberculous drugs is appropriate.



Clinical features:



Results in

- Weakness
- pyramidal and segmental.
- Root pain.
- Sensory loss.
- Sphincter disturbance.

TUBERCULOUS ENCEPHALOPATHY

An autoimmune encephalopathy with features of acute allergic encephalomyelitis or haemorrhagic leukoencephalopathy (page 511) may complicate the course of tuberculous infection and contribute significantly to the neurological sequelae. Clinically, convulsions and deepening coma with extensor posturing characterise this complication.

SPIROCHAETAL INFECTIONS OF THE NERVOUS SYSTEM

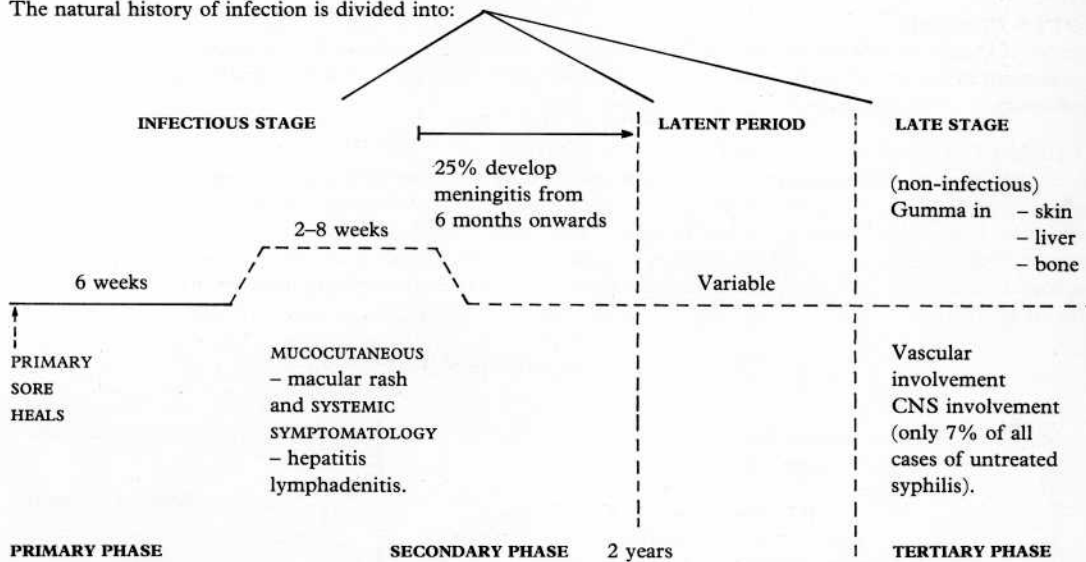
SYPHILIS

This infectious disease is caused by the spirochaete *Treponema pallidum*. Entry is by:

- inoculation through skin or mucous membrane (sexually transmitted) - acquired syphilis.
- transmission in utero - congenital syphilis.

Up to 10% of patients with HIV will test positive for syphilis. All patients with neurosyphilis should be tested for this.

The natural history of infection is divided into:



The *chancre* or *primary sore* on skin or mucous membrane represents the local tissue response to inoculation and is the first clinical event in acquired syphilis.

The organism, although present in all lesions, is more easily demonstrated in the primary and secondary phases.

In congenital syphilis fetal involvement can occur even though many years may elapse between the mother's primary infection and conception.

Widespread recognition and efficient treatment of the primary infection have greatly reduced the late or tertiary consequences.

Not all patients untreated in the secondary phase progress to the tertiary phase.

In HIV patients the neurological complications occur earlier and advance more quickly.

Investigations

Spirochaetes can be demonstrated microscopically by dark field examination in primary and secondary phase lesions.

Serological diagnosis depends on detection of antibodies.

1. Non-specific (Reagin) antibodies (IgG and IgM).

Reagin tests involve complement fixation.

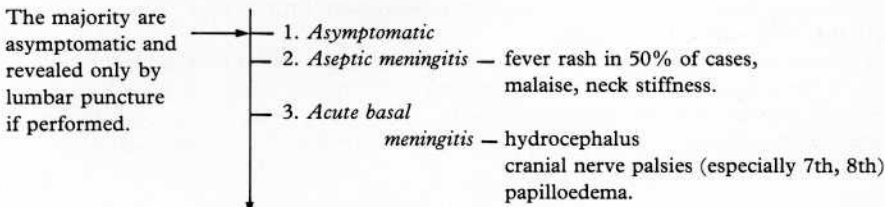
The Venereal Disease Research Laboratory (VDRL) test is the commonest and when strongly positive indicates active disease. (may be negative in HIV).

2. Specific treponemal antibodies (do not differentiate between past and present infection). Fluorescent treponemal antibody absorption (FTA) test and *Treponema* immobilisation (TPI) test.

SPIROCHAETAL INFECTION – NEUROSYPHILIS

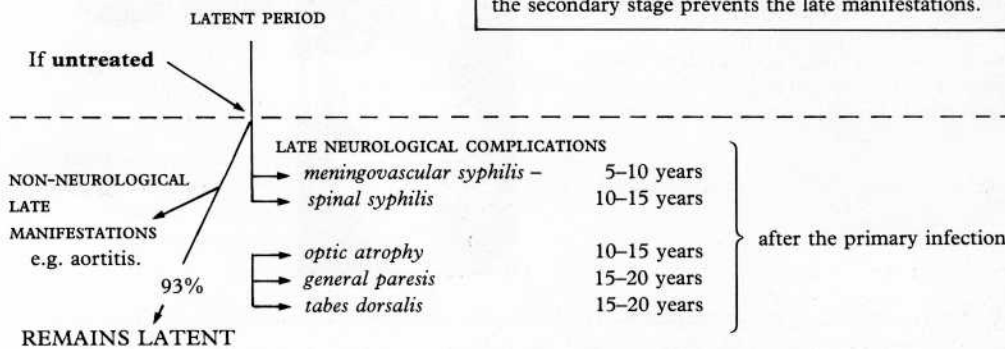
The initial event in neurosyphilis is meningitis. Of all untreated patients 25% develop an acute symptomatic syphilitic meningitis within 2 years of the primary infection.

ACUTE SYPHILITIC MENINGITIS: Three clinical forms are recognised:



CSF – lymphocytosis, 100–1000 cells/mm³, elevated protein (0.5–2 g/l), glucose reduced, Reagin tests positive.

Symptomatic meningitis responds to penicillin. Treatment during either the primary infection or the secondary stage prevents the late manifestations.



Late neurological complications occur in only 7% of **untreated** cases.

These forms are exceptionally rare and the clinical syndromes mentioned above seldom occur in a 'pure' form.

MENINGOVASCULAR SYPHILIS

'Early' late manifestation resulting in an obliterative endarteritis and periarteritis.

Presents as a 'stroke' in a young person – hemisphere, brain stem or spinal. Granulations around the base of the brain may produce cranial nerve palsies or even hydrocephalus.

CSF – lymphocytes 100/mm³, protein ↑, gammaglobulin ↑, positive serology. Penicillin arrests progression.

SPINAL SYPHILIS

Chronic meningitis with subpial damage to the spinal cord.

Presents as a progressive paraplegia, occasionally with radicular pain and wasting in upper limbs – ERB's PARAPLEGIA. CSF – as meningovascular syphilis. Penicillin arrests progression.

OCULAR MANIFESTATIONS

Meningitis around optic nerve with subpial necrosis may be the only manifestation of late syphilis.

Presents as a constriction of the visual fields with a progressive pallor of the optic disc:

- if both eyes are affected, the vision is rarely saved.
- if only one eye is involved, treatment with penicillin will save the other.

Neuroretinitis, uveitis and chorioretinitis occur, especially in HIV patients.

SPIROCHAETAL INFECTION – NEUROSYPHILIS

GENERAL PARESIS

Characterised by dementia – with memory impairment, disordered judgement and disturbed affect – manic behaviour, delusions of grandeur (rare).

- There are two phases:
1. Pre-paralytic – with progressive dementia.
 2. Paralytic – when corticospinal and extrapyramidal symptoms and signs develop associated with involuntary movements (myoclonus).

Argyll Robertson pupils may be present (see page 133).

At autopsy, meningeal thickening, brain atrophy and perivascular infiltration with plasma cells and lymphocytes are evident; culture from the cortex may reveal an occasional treponema.

CSF – lymphocytes $50/\text{mm}^3$, protein \uparrow 0.5–2 g/l, gammaglobulin \uparrow .

Reagin tests in CSF positive in the majority.

Treatment in the preparalytic phase will halt progression in 40%.

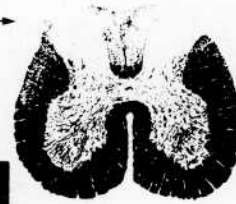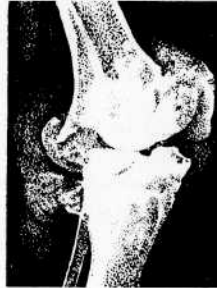TABES DORSALIS

Posterior spinal root and posterior column dysfunction – account for symptoms.

Pupillary abnormality (Argyll Robertson) and optic atrophy occur. Peripheral reflexes are lost and joint position and vibration sensation is impaired. A positive Romberg's test (page 178) indicates a sensory ataxia.

Pain loss results in trophic lesions and occasionally a Charcot joint may develop.

Urinary incontinence, impotence and constipation also occur. 'Lightning pains', visceral crises (abdominal pain/diarrhoea) and rectal crises (tenesmus) are frequent.



Repeated trauma to an insensitive joint results in 'painless' osteoarthritis and joint destruction.

The CSF is more normal than in general paresis. The Reagin test may be negative in 30 per cent. Treatment may produce some improvement; it will not reverse joint destruction.

SYPHILITIC GUMMA presenting as an intracranial mass is extremely rare.

TREATMENT OF NEUROSYPHILIS

Penicillin G.	2–4 megaunits i.v.	(When patient sensitive to penicillin
or	4-hourly for 10 days.	
Procaine Penicillin	600 000 units i.m.	erythromycin or tetracycline may be given orally over 30 days.)
	daily for 15 days.	
Benzathine Penicillin	2–4 megaunits i.m. weekly \times 3.	

The Jarisch-Herxheimer reaction – tachycardia/fever – occurs in one-third of patients within a few hours of commencing treatment; it is believed to be due to endotoxin release from killed organisms. Steroids should counter the reaction, especially in tertiary syphilis.

CSF follow up: CSF is checked initially and at 6 monthly intervals until normal.

Cell count and degree of positivity of VDRL are the best indicators of persistent infection.

Failure of treatment is common in HIV positive patients and more frequent retesting of blood and CSF is necessary.

SPIROCHAETAL INFECTIONS

LYME DISEASE

This is a disorder caused by the spirochaete *Borrelia Burgdorferi*, characterised by relapsing and remitting arthralgia associated with a characteristic skin rash (*erythema chronicum nigrans*) and neurological features. The organism, related to the treponemes, is prevalent throughout Europe and North America and is carried by ixodes ticks.

Clinical features

Only a minority of persons bitten by an infected tick develop the disease. Spirochaetocidal activity in normal serum and the immune response normally provide protection. It rarely occurs in HIV patients.

Stage 1: Spring/summer –

Tick bite → flu-like symptoms, arthralgia and skin rash (*erythema chronicum nigrans*).
Treatment with antibiotics is usually curative.

↓
Untreated and small
number of treated patients.

Stage 2: Several weeks/months later –

Subacute lymphocytic meningitis – both illnesses are often mild, clear
Subacute encephalitis spontaneously and occasionally are unrecognised.

Cranial nerve involvement – Facial nerve palsy with or without
subacute lymphocytic meningitis.

Peripheral neuropathy – Subacute demyelinating and axonal sensory/motor
neuropathy associated with severe root pain
(radiculitis). – Bannwarth's syndrome.

CSF examination in stage 2: Lymphocytosis Elevated immunoglobulins.
Oligoclonal bands. Elevated *antiBurgdorferi* antibodies.
↓
An unknown proportion progress.

Stage 3: Several months/years later –

Arthritis

Diffuse CNS involvement – chronic/subacute encephalitis.
– focal brain disease.
– *psychiatric* disease with fatigue and diffuse muscle pain.

Diagnosis

Antibody tests

– Immunofluorescence assay (IFA)
– Enzyme-linked immunoabsorbent assay (ELISA). } in serum and CSF.

In endemic areas up to 5% of the population are positive, although with lower titres than symptomatic patients.

In patients from endemic areas:

with meningitis/CN palsy encephalitis/radiculitis + CSF profile + positive serology	}	diagnosis is definite, but in stage 3 this is often uncertain and blind trials of therapy are given.	<i>PCR</i> if available gives the definitive answer. <i>MRI</i> is abnormal in 25% with subcortical (T2) white matter lesions.
----------------------------------------------------------------------------------------------	---	---------------------------------------------------------------------------------------------------------------	------------------------------------------------------------------------------------------------------------------------------------------

Treatment

Stage 1 – Oral antibiotics: penicillin, erythromycin or tetracycline.

Stage 2 – I.V. penicillin G. 20 million units for 10 days (or cefotaxime).

Stage 3 – as stage 2.

If symptoms persist – wrong diagnosis with misleading titres, or
– immune mediated damage.

Steroids can be used in late stages when symptoms have not responded to antibiotics

SPIROCHAETAL INFECTIONS

LEPTOSPIROSIS

Leptospira interrogans is transmitted to man in the infected urine of wild and domestic animal carriers. Subclinical infection commonly occurs in high-risk occupations, e.g. sewer workers. Symptomatic illness is usually mild and only 10% of patients develop jaundice and haemorrhagic complications (Weil's disease).

Clinical features

<p>Incubation period (10-12 days)</p>	<p>→ <i>Leptospiraemia</i> (5-7 days)</p> <ul style="list-style-type: none"> - pyrexia and rigors - myalgia - arthritis - trunkal purpura - subconjunctival haemorrhages - lymphadenopathy - hepatosplenomegaly. 	<p>----- → ± Immune phase (variable duration)</p> <ul style="list-style-type: none"> - lymphocytic meningitis - cranial nerve palsies - mononeuritis multiplex - Guillain-Barré syndrome (page 424) - encephalitis and (in Weil's disease) hepatic and renal failure <p>- haemorrhagic complications - (Subarachnoid and intraparenchymal haemorrhage) and circulatory collapse.</p>
-------------------------------------------	-------------------------------------------------------------------------------------------------------------------------------------------------------------------------------------------------------------------------------------------------------------------------------------------	---------------------------------------------------------------------------------------------------------------------------------------------------------------------------------------------------------------------------------------------------------------------------------------------------------------------------------------------------------------------------------------------------------------------------------------------

Diagnosis

A combination of abnormal liver and renal function with elevated creatine kinase suggest the diagnosis. *Leptospirae* can be isolated from blood and CSF but diagnosis is usually confirmed by demonstrating agglutinating antibodies (ELISA detected IgM).

Treatment

The disease is usually self limiting and therapy unnecessary. Early treatment in the leptospiraemic phase with Penicillin G 12 million units daily and tetracycline 500 mg four times per day may minimize the immune-mediated complications. Support of hepatic/renal failure and management of haemorrhagic complications may be life-saving.

PARASITIC INFECTIONS OF THE NERVOUS SYSTEM – PROTOZOA

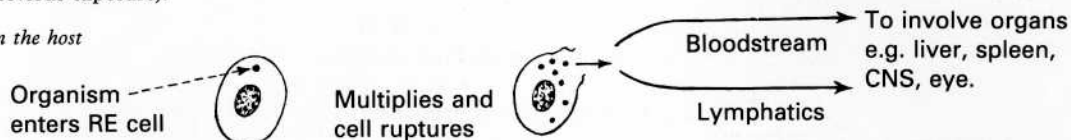
TOXOPLASMOSIS

A world-wide parasitic infection affecting many species, including man.

Organism: An anaerobic intracellular protozoan, *Toxoplasma gondii*.

The majority of infections in man are asymptomatic (30% of the population have specific antibodies indicating previous exposure).

In the host



Transmission: Eating uncooked meat or contact with faeces of an infected dog or cat. (definitive hosts)

There are two forms of toxoplasmosis:

CONGENITAL – when a previously unaffected woman contracts infection during pregnancy (subclinical infection); transplacental spread results in fetal infection.

Premature delivery occurs in 25%.

Neurological complications:

- hydrocephalus,
- aqueduct stenosis,
- microcephaly.

Non-neurological features:

- skin rash, jaundice, hepatosplenomegaly, choroidoretinitis.

Skull X-ray shows:

- curvilinear calcification (basal ganglion and periventricular regions).

Varying degrees of organ involvement may occur.

The only manifestation may be choroidoretinitis in an otherwise healthy child.

Diagnosis:

Organisms are seldom identified.

IgG antibodies indicate previous exposure, positive IgM and high or rising IgG confirm active infection.

Serological tests are negative in AIDS.

In *acquired infection* CT shows characteristic ring shaped contrast enhancement (page 125). MRI is even more sensitive. Brain biopsy is necessary for exclusion of CNS lymphoma and for definitive diagnosis.

N.B. Rubella, cytomegalovirus and herpes simplex can also spread transplacentally and cause jaundice and hepatosplenomegaly. Cytomegalovirus may also produce choroidoretinitis and intracranial calcification.

Treatment


Sulphadiazine and pyrimethamine (Dapaprim) with folinic acid for 3 weeks or longer in immunocompromised patients. Give steroids when choroidoretinitis is present.

MALARIA

Plasmodium falciparum, the agent of malignant tertiary malaria, is responsible for *cerebral malaria*. Infected red blood cells adhere to vascular endothelium and block the microcirculation. Endothelial damage produces cerebral oedema. Confusion, focal signs, convulsions and coma occur. Diagnosis depends on demonstrating parasites in peripheral blood. Parenteral anti malaria treatment (chloroquine), exchange transfusion and supportive therapy may be life saving. Overall mortality is 10%. Complete recovery without sequelae is expected in survivors.

ACQUIRED – symptomatic infection is uncommon and may be associated with underlying systemic disease or immunosuppression. (e.g. AIDS)

Fever and fatigue with muscle weakness and lymphadenopathy result. Abnormal lymphocytes in peripheral blood leads to confusion with *infectious mononucleosis*. The neurological features are those of a meningoencephalitis with focal signs and depressed conscious level. Choroidoretinitis occasionally occurs.



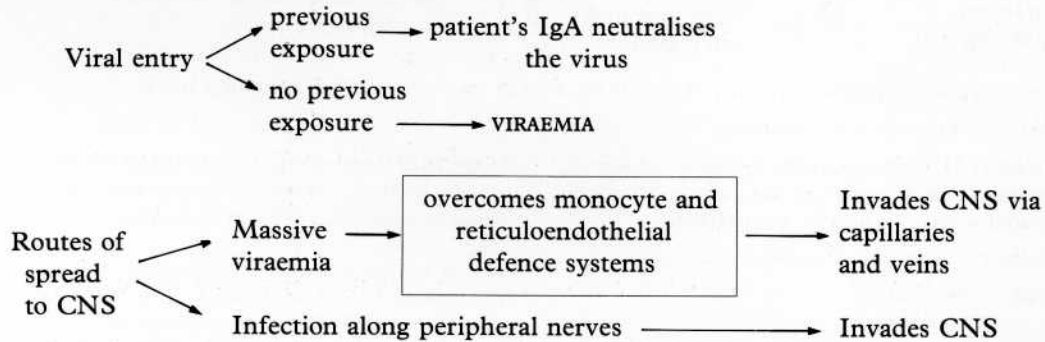
Retinal pigment epithelium becomes hyperplastic – densely pigmented areas result.

VIRAL INFECTIONS

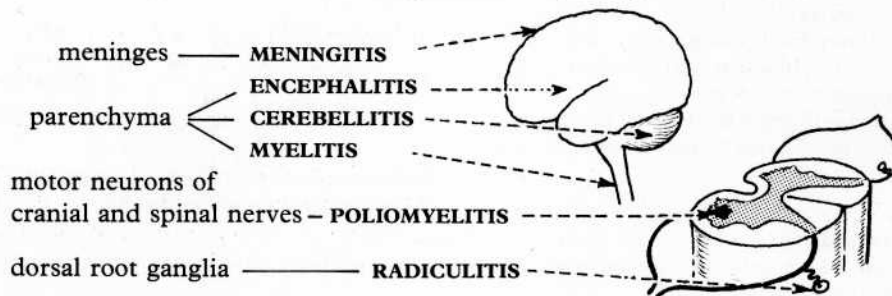
General principles

Invasion of the nervous system may occur as part of a generalised viral infection. Occasionally nervous system involvement is disproportionately severe and symptoms of generalised infection are slight.

Viruses enter the body through the: *respiratory tract, gastrointestinal tract, genitourinary tract or by inoculation through the skin.*



After CNS penetration, the clinical picture depends upon the particular virus and the cells of the nervous system which show a specific susceptibility.



Some viruses cause a chronic, progressive infection, others remain dormant for many years within the nervous system before becoming symptomatic.

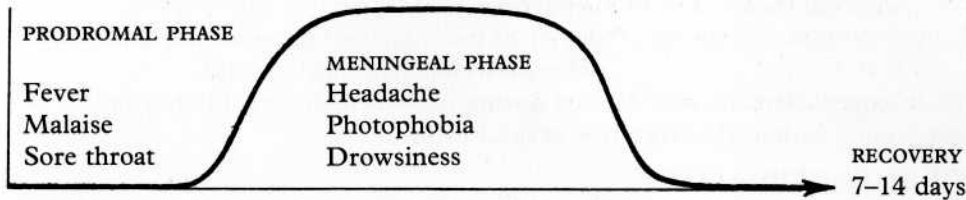
MENINGITIS

Meningitis is the commonest type of viral infection of the central nervous system. The term *aseptic meningitis* includes viral meningitis as well as other forms of meningitis where routine culture reveals no other organisms. A causal virus is identified in 20% of all cases.

Common	ENTEROVIRUSES	Rare	
causal	— MUMPS VIRUS	causal	— LYMPHOCYTIC CHORIOMENINGITIS
viruses	HERPES SIMPLEX (subtype 2)	viruses	HUMAN IMMUNODEFICIENCY VIRUS (HIV)
	EPSTEIN-BARR VIRUS (EBV)		

VIRAL INFECTIONS – MENINGITIS

Clinical features of acute aseptic meningitis



SIGNS:

Mild meningism

Skin rashes

COMPLICATIONS:

Neck stiffness

Parotitis

Febrile seizures

Kernig's sign +ve

± Diarrhoea

Inappropriate ADH secretion.

No focal signs

Myalgia

Enterovirus infection e.g. Cocksackie or echo viruses – affects children/young adults and occurs seasonally in late summer.

Spread is by the faecal/oral route.

Accounts for 80% of cases in USA.

Mumps – affects children/young adults. Winter/spring incidence. Commonest world-wide cause.

Herpes simplex (type 2) – accounts for 5% of viral meningitis. Develops in 25% of patients with primary genital infection (suspect in sexually active adults).

Lymphocytic choriomeningitis – affects any age and is a consequence of airborne spread from rodent droppings.

Human Immunodeficiency Virus (HIV) – suspect in high risk groups (page 495) with meningitis. HIV antibodies are often absent and develop 1–3 months later during convalescence.

Investigations

CSF, obtained early, often contains recoverable virus. The CSF cell count is elevated (lymphocytes or monocytes). PCR detection of viral DNA/RNA in CSF though diagnostic, is rarely thought necessary. Virus may be cultured from throat swabs or stool. Serological tests on serum in acute and convalescent phases are especially valuable in detecting mumps and herpes simplex (type 2).

Differential diagnosis

From other causes of an aseptic meningitis which are usually subacute or chronic in onset:

- *Tuberculous or fungal meningitis*
- *Leptospirosis*
- *Sarcoidosis*
- *Carcinomatous meningitis*
- Partially treated *bacterial meningitis*
- *Parameningeal* chronic infection which evokes a meningeal response, e.g. mastoiditis.

The self-limiting and mild nature of viral meningitis should not lead to confusion with these more serious disorders.

Prognosis is excellent and **treatment** symptomatic.

In severe herpes simplex meningitis with an encephalitic component intravenous acyclovir is required.

VIRAL INFECTIONS – PARENCHYMAL

Viruses may act:

- directly* → acute viral encephalitis or meningoencephalitis,
- or *indirectly via the immune system* → allergic or postinfectious encephalomyelitis and postvaccinial encephalomyelitis.

Also, a 'toxic' encephalopathy may develop during the course of a viral illness in which inflammation is not a pathological feature – REYE'S SYNDROME.

ACUTE VIRAL ENCEPHALITIS

Viral infection causes neuronal and glial damage with associated inflammation and oedema. Viral encephalitis is a worldwide disorder with the highest incidence in the tropics.

Common causal viruses:

World-wide:	Rare forms in specific areas:
- Mumps	Western equine – (vector) mosquito – USA
- Herpes simplex	West Nile – (vector) mosquito – Africa/India
- Varicella zoster	Russian spring/summer – (vector) tick – eastern Europe
- Epstein-Barr	
- Arboviruses	

Encephalitis following childhood infections – measles, varicella, rubella – is presumed to be *postinfectious* and not due to direct viral invasion, though the measles virus has occasionally been isolated from the brain.

Clinical features:

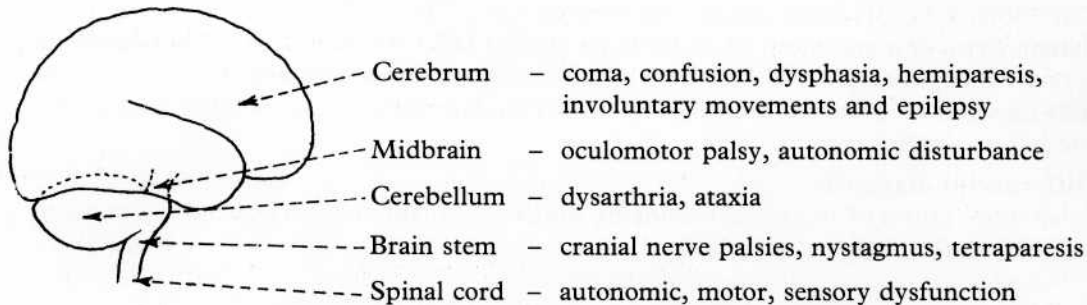
Signs and symptoms:

General: pyrexia, myalgia, etc.

Specific to causative virus, e.g. features of infectious mononucleosis (Epstein-Barr).

Meningeal involvement (slight) → neck stiffness, cellular response in CSF.

Signs and symptoms of parenchymal involvement – focal and/or diffuse.



In general, the illness lasts for some weeks.

Prognosis is uncertain and depends on the causal virus as do neurological sequelae.

VIRAL INFECTIONS – PARENCHYMAL

Herpes Simplex types 1 and 2 and Varicella-Zoster virus commonly cause disease in humans

HERPES SIMPLEX ENCEPHALITIS

HSV-1 – oral and labial rashes as well as ENCEPHALITIS.

HSV-2 – genital and neonatal infection as well as MENINGITIS.

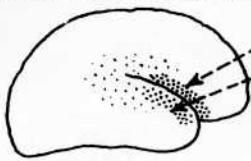
One third occur due to primary infection; two thirds have pre-existing antibodies indicating *reactivation*.

Clinical features

A world-wide disorder occurring during all seasons and affecting all ages.

Incidence: 1/250,000

General symptoms at onset – headache, fever – with evolution over several days to seizures and impaired conscious level.



Inferior frontal and temporal lobes are selectively involved and signs and symptoms reflect this – olfactory or gustatory hallucinations, behavioural disturbance, complex partial seizures, dysphasia (dominant hemisphere) and hemiparesis. Cerebral oedema may result in tentorial herniation.

Investigations

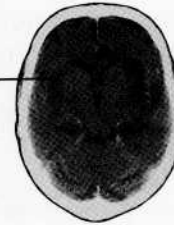
CT scan shows low attenuation in the inferior frontal and temporal lobes but may be normal in early stages. *MRI* is abnormal at an earlier stage, showing bilateral temporal lobe and limbic involvement, often with haemorrhagic change.

CSF examination reveals 5–500 lymphocytes. The protein is mildly elevated and the glucose is normal. IgG is elevated and oligoclonal bands are present.

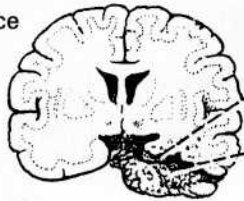
EEG examination shows generalised slowing with bursts of 'periodic' high voltage slow wave complexes over the involved temporal lobe.

Virus specific antibodies appear in serum and CSF. HSV-DNA is detected in CSF by *Polymerase Chain reaction (PCR)*, a new technique for rapid early diagnosis.

Brain biopsy seldom required in view of the above newer diagnostic techniques.



This shows evidence of a necrotising encephalitis with intranuclear eosinophilic inclusion bodies.



Demonstrate herpes simplex antigen by immunofluorescence.
Isolate virus by culture (positive in 48 hours).

Differential diagnosis

Consider:

- other forms of encephalitis
- cerebral abscess
- brain tumour.

Treatment

Acyclovir inhibits DNA synthesis; 30 mg/kg/day is given in divided dosage (to avoid renal toxicity) for 10–14 days.

This treatment has reduced mortality from 70% to 20% with a similar reduction in neurological sequelae (memory disturbance, etc.).

Since acyclovir is relatively non-toxic, treatment should be commenced on suspicion of disease. Delay will adversely affect outcome.

VIRAL INFECTIONS – REYE'S SYNDROME

REYE'S SYNDROME

This rare encephalopathy, associated with fatty changes in the liver and other viscera, is almost exclusively confined to children. It is due to aspirin useage in infection with Influenza A, Influenza B or varicella-zoster viruses.

Incidence

<1 per 100 000 children per year. Commoner in rural communities.

Since 1980 the incidence of this condition has dropped dramatically.

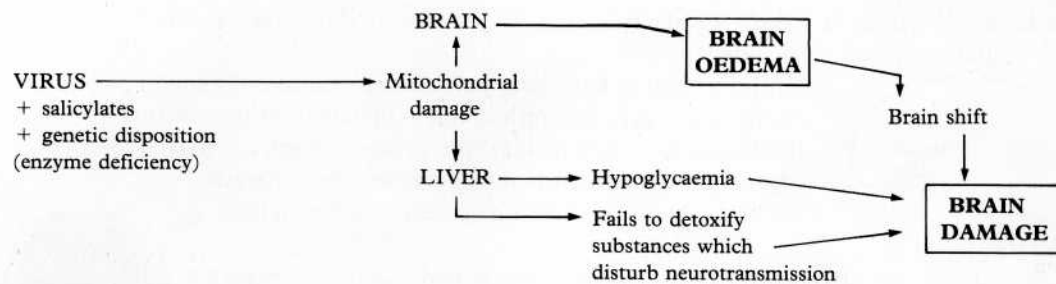
Pathology

Neurons and glial cells are swollen; the liver, heart and kidney show fatty infiltration.

Pathogenesis

Viral synergism with an environmental factor, e.g. salicylates, may be responsible.

Morphological changes in mitochondria indicate a central role.



Clinical features

Prodromal symptoms of 'viral' infection

latent period
variable duration

- rapid onset
- vomiting
- delirium
- convulsions
- coma

- hepatomegaly in 50%
- focal neurological signs usually absent

Death results from raised intracranial pressure.

Investigations

- Raised liver enzymes (ALT & AST)
 - Elevated serum ammonia
 - Hypoglycaemia (in infants)
 - Prolonged prothrombin time
 - Increase in serum fatty acids
 - Aminoaciduria
- CT/MRI show appearances of diffuse cerebral oedema

Differential diagnosis

Consider other causes of raised intracranial pressure in childhood, especially

- lead encephalopathy,
- lateral sinus thrombosis, e.g. following mastoiditis.

Treatment

Treatment aims at lowering intracranial pressure with the aid of intracranial pressure monitoring (see page 50). In addition, blood glucose must be maintained and any associated coagulopathy treated. Reduction of ammonia may be achieved by peritoneal dialysis or exchange transfusion.

Prognosis

Early diagnosis and supportive treatment has reduced the mortality from 80% to 30%.

When raised intracranial pressure is present, mortality increases to 50% and a high proportion of survivors have cognitive disorders.

A condition similar to Reye's syndrome occurs in some children with family history of 'sudden infant death'. A deficiency of medium chain acetyl-CoA dehydrogenase (an enzyme essential for fatty acid metabolism) is found. Carnitine deficiency results as a consequence of 'alternative pathway' fatty acid metabolism. *Siblings of children with Reye's syndrome should be screened for this disorder.*

VIRAL INFECTIONS – CHRONIC DISORDERS

In these disorders the infection results in a chronic progressive neurological condition.

The evidence of a viral etiology is:

- direct* — finding of inclusion bodies,
- demonstration of viral particles,
- isolation of virus,
- and
- indirect* — relationship of onset of symptoms to a preceding viral illness,
- transmission of illness from one host to the next.

Not all these features are present in any one illness.

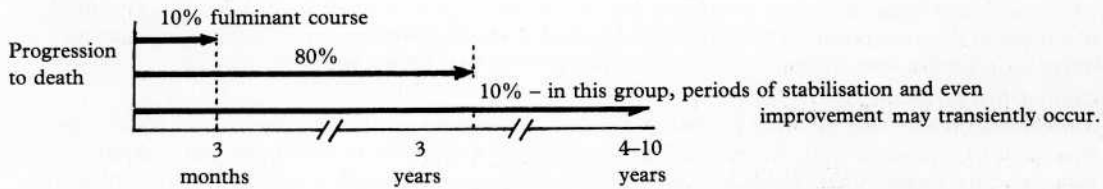
SUBACUTE SCLEROSING PANENCEPHALITIS (SSPE)

Caused by measles-like *paramyxovirus* – isolated from brain biopsy.

Less common with the availability of widespread primary measles vaccination.

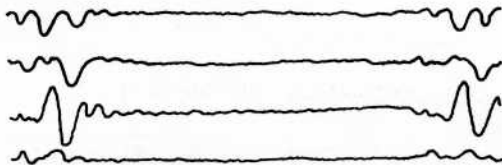
Clinical features: A world-wide disorder. Incidence: 1 per million per year. Onset: between ages 7–10 years.

<i>Stage 1</i>	<i>Stage 2</i>	<i>Stage 3</i>
Behavioural problem	Chorioretinitis,	Lapses into rigid
Declining school performance	Myoclonic jerks	comatose state.
Progression → dementia.	Seizures, ataxia	
	Dystonia.	



The illness may occur after measles vaccination or following clinical infection at an early age (under 2 years). Accompanying features of infection, i.e. pyrexia, leucocytosis, are *absent*.

Investigations



EEG – shows periodic high voltage slow wave complexes on a low voltage background trace.

CSF examination shows elevated γ globulin with IgG oligoclonal bands; elevated measles antibodies (75% of total CSF IgG).

Blood examination shows elevated serum measles antibodies.

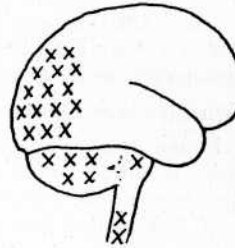
Pathology

Changes involve both white and grey matter, especially in the posterior hemispheres. Brain stem, cerebellum and spinal cord are also affected.

Oligodendrocytes contain eosinophilic inclusion bodies. Marked gliosis occurs with perivascular lymphocyte and plasma cell cuffing.

Treatment: There is no effective treatment. Since the introduction of measles vaccination there has been a marked reduction of SSPE.

Subacute measles encephalitis may follow measles infection in children on *immunosuppressive drug treatment* or with *hypogammaglobulinaemia*. The clinical course is different however from SSPE and EEG and CSF findings are less specific.



VIRAL INFECTIONS – CHRONIC PARENCHYMAL DISORDERS

PROGRESSIVE RUBELLA PANENCEPHALITIS

Similar to SSPE with a fatal outcome, caused by rubella virus.
 Presents at a later age (10–15 years) CSF shows high γ globulin.
 Progressive dementia. EEG does *not* show periodic complexes of SSPE.
 Ataxia. Spasticity. Myoclonus. Antibodies elevated in serum and CSF to rubella.
 Biopsy does *not* show inclusion bodies.

Treatment: No effective treatment

POSTVIRAL OR ACUTE DISSEMINATED ENCEPHALOMYELITIS (see page 510)

PROGRESSIVE MULTIFOCAL LEUKOENCEPHALOPATHY (see page 511)

PRION DISEASES

Fatal conditions characterised by the accumulation of a modified cell membrane protein – Prion protein or PrP (proteinaceous infectious particle) within the central nervous system.

Clinical features are dependent on site and rate of deposition of PrP. A similar disorder in cattle, bovine spongiform encephalopathy (BSE) may be a source of infection in man.

The Prion theory

Experimental and epidemiological evidence supports transmissibility. Physical properties of the infective agent – heat and radiation resistance and absence of nucleic acid – suggests it is comprised solely of protein. This infectious protein when inoculated modifies normal cell membrane protein which acts as a template for further conversion to abnormal protein. This host-encoded protein accumulates without any inflammatory or immune response. In familial cases a point mutation in the prion gene explains disease susceptibility.

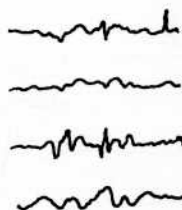
Creutzfeldt-Jacob disease (CJD)

A worldwide disorder with incidence 1:1 000 000. Familial cases account for 10–15%. Age of onset 50–60 years. Non specific symptoms at onset (anxiety and depression) are rapidly followed by myoclonus, ataxia, akinetic rigid state, dementia. Death within 12 months is usual. A new variant (possibly linked to BSE) has been described in younger patients with a slower time course. Iatrogenic disease occurs following corneal or dural grafts, depth electrodes and cadaveric derived human growth hormone treatment.

Investigation

CSF – usually normal.
 EEG – bilateral high voltage sharp waves on a background of slow wave activity.

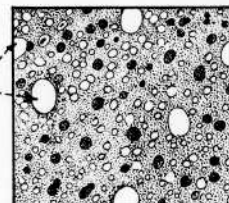
The clinical picture and electroencephalogram suggest the diagnosis only ultimately confirmed at postmortem.



Pathology

No abnormality is seen on gross examination
Microscopically – Neuronal degeneration occurs with marked astrocytic proliferation and amyloid plaque formation. Vacuolation of glial cells results in a characteristic spongiform appearance. Presymptomatic testing in subjects with family history is available.

Vacuolation



Treatment – none available

Gerstmann Straussler syndrome (GSS)

A similar disorder condition to CJD. Cases are familial and characterised by specific pathology of spongiform changes associated with amyloid plaques containing PrP immunoreactive proteins. Clinical features are nonspecific – ataxia, Parkinsonism, dementia. Death occurs within 5 years of contact.

Kuru

An extensively studied disorder of Papua, New Guinea. It is of interest in view of man to man spread from cannibalism.

Prions may have a role to play in other neurodegenerative disorders, e.g. Alzheimer's disease, Parkinson's disease and motor neurone disease.

VIRAL INFECTIONS – MYELITIS AND POLIOMYELITIS

MYELITIS

Acute viral transverse myelitis is rare. It can occur in association with measles, mumps, Epstein-Barr, herpes zoster/simplex, enterovirus infections or small pox. Fever, back and limb pain precede paralysis, sensory loss and bladder disturbance. Initially paralysed limbs are flaccid, but over 1–2 weeks spasticity and extensor plantar responses develop. Good recovery occurs in 30%. Death from respiratory failure is rare (5%).

Investigations

Myelography when performed is normal. MRI may demonstrate focal cord signal changes. CSF shows elevated protein with a neutrophil or lymphocytic response. Serological tests will occasionally identify the causal virus. Electrophysiology distinguishes from Guillain-Barré syndrome.

Treatment

Supportive; the place of steroids remains unproven.

It is not clear whether the pathological effects (perivenous demyelination) result from direct or delayed (immunological) reactions to the virus.

POLIOMYELITIS

An acute viral infection in which the anterior horn cells of the spinal cord and motor nuclei of the brain stem are selectively involved. A major cause of paralysis and death 30 yrs ago, now rare with the introduction of effective vaccines.

Causative viruses:

The poliovirus is an enterovirus (RNA virus).

Three immunologically distinct strains have been isolated.

Immunity to one does *not* result in immunity to the other two.

Coxsackie and echoviruses may produce a clinically identical disorder.

Pathology

Initially – inflammatory meningeal changes, followed by – inflammatory cell infiltration (polymorphs and lymphocytes) around the brain stem nuclei and anterior horn cells. Neurons may undergo necrosis or central chromatolysis.

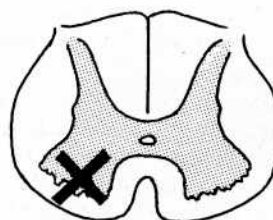
Microglial proliferation follows.

Mode of spread

Spread by faecal/oral route. Once ingested the virus multiplies in the nasopharynx and gastrointestinal tract.



viraemia but CNS involvement occurs in only a very small proportion. Most infected patients are asymptomatic. Virus excretion continues in the faeces for as long as three months after the initial infection – carrier state.



Epidemiology

A highly communicable disease which may result in epidemics.

Seasonal incidence – late summer/autumn.

World-wide distribution, although more frequent in northern temperate climates.

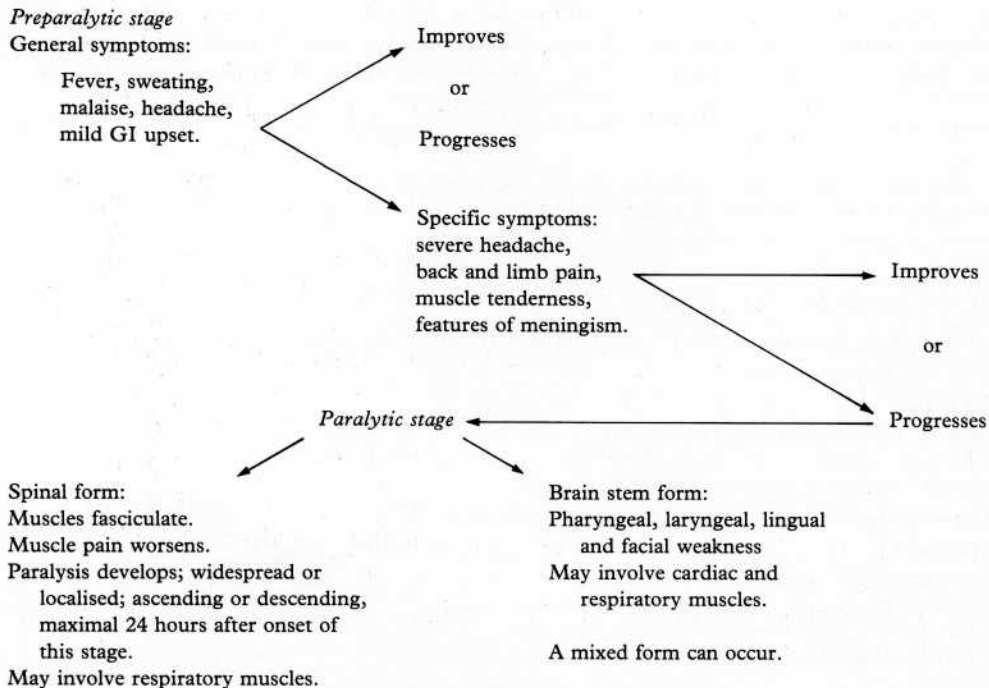
Prophylactic vaccination has produced a dramatic reduction in incidence in the last 25 years. In developing countries without a vaccination programme, the disease remains a problem.

Clinical features

Infection may result in:

- Subclinical course + resultant immunity (majority)
- Mild non-specific symptoms of viraemia + resultant immunity
- Meningism without paralysis (PREPARALYTIC) + resultant immunity
- Meningism followed by paralysis (PARALYTIC) + resultant immunity.

VIRAL INFECTIONS – POLIOMYELITIS



Diagnosis

During the meningeal phase, consider other causes of acute meningitis.

Once the paralytic phase ensues, distinguish from the Guillain-Barré syndrome and transverse myelitis.

The clinical picture + CSF examination (polymorphs and lymphocytes increased; protein elevated with normal glucose) are sufficient to reach the diagnosis.

Serological tests + virus isolation will confirm later.

Prognosis

In epidemics, a mortality of 25% results from respiratory paralysis. Improvement in muscle power usually commences one week after the onset of paralysis and continues for up to a year.

Only a proportion of muscles remain permanently paralysed; in these, fasciculation may persist. In affected limbs, bone growth becomes retarded with shortening as well as thinning.

Treatment

The patient is kept on bed rest and fluid balance carefully maintained.

Respiratory failure may require ventilation.

Avoid the development of deformities in affected limbs with physiotherapy and splinting.

Post-Polio Syndrome

A significant proportion of polio patients develop late sequelae often 30 yrs after initial illness - fatigue, myalgia and new weakness are characteristic.

Prophylaxis

- 2 vaccines are available
- Salk vaccine - Formalin inactivated virus. 2 injections, 1 month apart, are followed by booster at 6 months; this prevents CNS invasion, but does not stop viraemia.
 - Sabin vaccine - Live attenuated virus given orally and will simulate subclinical infection. 3 doses 2 months apart.
- (vaccine of choice)

VIRAL INFECTIONS – VARICELLA-ZOSTER INFECTION

Varicella (chickenpox) and herpes zoster (shingles) are different clinical manifestations of infection by the same virus – *Varicella-Zoster*, a DNA human herpes virus.

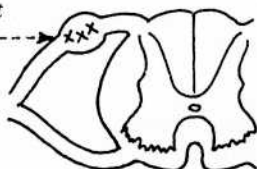
conditions caused:

- an acute encephalitis
- postinfectious encephalomyelitis
- viral meningitis
- postinfectious polyneuropathy (Guillain-Barré syndrome).
- myelitis

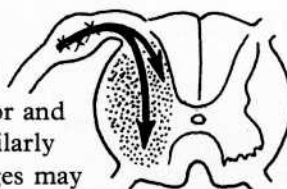
Shingles

This occurs after virus reactivation, dormant after the primary infection (chickenpox).

Pathology: The virus involves the *dorsal root* (sensory) ganglion of the spinal cord or the *cranial nerve* sensory ganglion – trigeminal or geniculate.



The inflammatory process may spread into the spinal cord and involve posterior and anterior horns. Similarly inflammatory changes may occur in the brain stem.



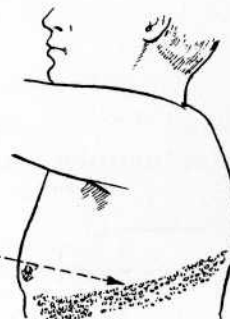
Clinical features

Patients are usually over 50 years of age. Sexes are affected equally. Recurrence is rare.

Often occurs in association with compromised immunity, e.g. lymphoma. Also associated with spinal/nerve root trauma.

Initial feature:

A vesicular skin rash associated with a burning, painful sensation. Vesicles contain clear fluid and conform to a *dermatome distribution*. After 1–3 weeks, the vesicles crust over and leave irregular skin depigmentation with scarring.



Motor weakness occurs in 20% due to damage of the anterior horn cell. More widespread spinal (myelitis) or encephalic involvement occurs in the immunodeficient. In these patients extensive cutaneous lesions are common (disseminated zoster).

Cranial nerve ganglia involvement:

- *Trigeminal*: usually ophthalmic division with vesicles above the eye and associated corneal ulceration – **HERPES ZOSTER OPHTHALMICUS**. Occasionally patients, 7–10 days after onset, develop a necrotising granulomatous angiitis causing stroke-like syndromes. Zoster virus antigen is detected in thrombin in major vessels.
- *Geniculate*: vesicles within the external auditory meatus and ear drum. Ipsilateral deafness and facial weakness result. – **RAMSAY HUNT SYNDROME**.

Diagnosis Based on clinical features.

Treatment

This depends on the severity and location of skin lesions. Mild disease requires symptomatic treatment only. Severe disease, involvement in immunodeficient patients, or ophthalmic vesicles require acyclovir either orally or intravenously.

POST HERPETIC NEURALGIA

This is a condition which occurs in 10% of all patients. The incidence rises with age. A chronic, uncomfortable, burning pain presents in the territory of the involved dermatome. The pathogenesis is unknown.

Treatment with antidepressants, anticonvulsants, e.g. carbamazepine, transcutaneous stimulation (TCS) or sympathetic ganglion block may help, but results are unpredictable.

OPPORTUNISTIC INFECTIONS

These infections occur in immunocompromised patients. Certain types of immunological deficiency tend to be associated with specific forms of infection.

<p><i>T cell/macrophage deficiency</i> Causes: e.g. AIDS Lymphoreticular tumours Immunosuppressant drugs</p> <p>Organisms: <i>Viruses</i> – Cytomegalovirus Herpes simplex/zoster JC virus <i>Bacteria</i> – <i>Listeria</i> <i>Nocardia</i> <i>Mycobacterium</i>, etc. <i>Fungi</i> – <i>Aspergillus</i> <i>Candida</i> <i>Mucoraceae</i> <i>Parasites</i> – <i>Toxoplasmosis</i></p>	<p><i>B cell immunoglobulin deficiency</i> Chronic lymphatic leukaemia Primary hypogammaglobulinaemia</p> <p>Splenectomy</p> <p>Measles Enteroviruses</p> <p><i>Streptococcus pneumoniae</i> <i>Haemophilus influenzae</i> <i>Pseudomonas aeruginosa</i>, etc.</p>	<p><i>Granulocyte deficiency</i> Marrow infiltration Aplastic anaemia</p> <p>Chemotherapy/ radiotherapy</p> <p>Enterobacteria <i>Staphylococcus aureus</i> <i>P. aeruginosa</i>, etc. <i>Aspergillus</i> <i>Candida</i> <i>Mucoraceae</i></p>
---------------------------------------------------------------------------------------------------------------------------------------------------------------------------------------------------------------------------------------------------------------------------------------------------------------------------------------------------------------------------------------------------------------------------------------------------------------------------------------------------------------------------------------	---------------------------------------------------------------------------------------------------------------------------------------------------------------------------------------------------------------------------------------------------------------------------------------------------------------------------------------------	---------------------------------------------------------------------------------------------------------------------------------------------------------------------------------------------------------------------------------------------------------------------------------------------------------------------------------------

CLINICAL SYNDROMES, DIAGNOSIS AND TREATMENT

Clinical syndrome	Diagnosis	Treatment
CEREBRAL ABSCESS	CT scan Blood culture Drainage or biopsy and culture	Common bacteria (see page 346) → <i>Listeria</i> → Ampicillin or erythromycin → <i>Nocardia</i> → Sulphonamide or cycloserine → <i>Candida</i> → Amphotericin B & 5-fluorocytosine
OTHER INTRA-CRANIAL MASS LESIONS	CT/MR scan Serum antibodies Biopsy	→ <i>Aspergillus</i> → Surgical removal (if indicated) Amphotericin B & 5-fluorocytosine → <i>Toxoplasmosis</i> → Pyrimethamine, sulphadiazine & folinic acid
ENCEPHALOPATHY	EEG CT/MR scan Serum antibodies Viral isolation (biopsy) Intracellular inclusion bodies	→ <i>Toxoplasmosis</i> → Pyrimethamine, sulphadiazine & folinic acid → Cytomegalovirus → Gancyclovir or Foscarnet → JC virus → Cytosine arabinoside (progressive multifocal encephalopathy)
CRANIAL NERVE PALSIES	Skull X-ray CT/MR scan CSF/blood culture Serum antibodies Nasal Swab	→ <i>Candida</i> → Amphotericin B & 5-fluorocytosine → <i>Mucoraceae</i> → Radical sinus and orbital surgery and amphotericin B
MENINGITIS	CT/MR scan CSF/blood culture Serum antibodies Antigen agglutination tests	→ Common bacteria (see page 473). → <i>Mycobacterium</i> (see page 474). → <i>Cryptococcus</i> → Amphotericin B & 5-fluorocytosine → <i>Listeria</i> → Ampicillin or erythromycin → <i>Nocardia</i> → Sulphonamide or cycloserine → <i>Candida</i> → Amphotericin B & 5-fluorocytosine
RETINITIS	Serum antibodies Viral isolation	→ <i>Toxoplasmosis</i> → Pyrimethamine, sulphadiazine & folinic acid → Cytomegalovirus → Gancyclovir or Foscarnet

NEUROLOGICAL PRESENTATIONS OF HIV INFECTION

Cerebral tumours

Primary cerebral lymphoma
Metastatic systemic lymphoma
Metastatic Kaposi's Sarcoma

CT/MR scan

Infections

Encephalitis

Cytomegalovirus
Herpes zoster/simplex
Toxoplasmosis
Progressive multifocal
leukoencephalopathy

CT/MR scan
Antibody tests
Biopsy

Cerebral abscess

E. coli
Aspergillus -
Candida
Nocardia

CT/MR scan
Aspiration/culture
Antibody tests

Meningitis

HIV-1
Mycobacterium
Listeria -
Syphilis
Aspergillus

CSF exam and culture
Antibody tests

Peripheral neuropathy

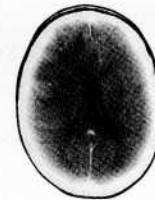Herpes zoster radiculopathy
Cauda equina syndrome (cytomegalovirus)
Acute reversible demyelination
Chronic demyelination

Nerve conduction studies
Antibody tests

Management

Opportunistic infection - treatment of specific infection (see page 494).

With known HIV +ve patients, invasive procedures such as biopsy are often avoided and trials of therapy are administered, e.g. cerebral toxoplasmosis - trial of pyrimethamine and sulphadiazine, monitored with CT scanning. If lesions do not resolve → biopsy (? lymphoma).



Cerebral toxoplasmosis

AIDS dementia (in 15%)

Direct HIV infection with demyelination and perivascular inflammatory changes. Intellectual decline of subcortical type (page 125).

CT/MR scan
Psychometry

Retinopathy

Cytomegalovirus
Toxoplasmosis

Fundal exam.
Antibody tests

Myelopathy

Acute reversible

Compression - abscess
- systemic lymphoma.
Ascending - cytomegalovirus
herpes zoster/simplex

Spinal CT/MRI
Antibody tests

Vascular disorders

Intracranial haemorrhage
cerebral infarction (septic
emboli or thrombosis)

CT/MR scan

Once AIDS is established, fatal infection or malignancy is inevitable. For this reason, treatments which boost the immune system or influence virus replication are considered.

- Zidovudine (AZT), by interfering with nucleic acid synthesis, blocks HIV DNA formation and reduces virus replication. AZT is used at present in ARC and AIDS and prolongs survival. When given with Probenecid the dosage is reduced without loss of effectiveness. AZT also reduces rate of transmission from infected mother to baby.

Immune modulators, e.g. Interferon and Interleukin 2, stimulate the immune system and may be of value.

SUBCUTE/CHRONIC MENINGITIS

This entity is characterised by symptoms and signs of meningeal irritation which persist and progress over weeks without improvement. Unlike acute meningitis, the onset is insidious; cranial nerve signs and focal deficits such as hemiparesis, dementia and gradual deterioration of conscious level may predominate. Predisposing factors include immunosuppression and underlying systemic illness eg diabetes mellitus. The outcome depends upon aetiology and the early instigation of appropriate treatment.

Chronic meningitis is associated with certain CSF findings.

- Lymphocytosis + low glucose
- Lymphocytosis + normal glucose.

Diagnosis depends upon CSF examination.

Lumbar puncture should be performed in suspicious cases as soon as CT scan has ruled out a mass lesion.

SUBACUTE/CHRONIC MENINGITIS WITH A MARKED REDUCTION IN CSF GLUCOSE

Causes	Diagnosis	Specific features	Treatment
M. tuberculosis	See page 475		
Fungi <i>Cryptococcus</i> <i>Nocardia</i> <i>Candida</i> <i>Aspergillus</i>	Diagnosis suggested by chest X-ray – pulmonary infiltrations, CT/MR evidence of meningeal enhancement and associated hydrocephalus CSF abnormalities lymphocytosis, low glucose and high protein with appropriate staining, culture and agglutination/complement-fixation tests.	Clinical features similar to tuberculous meningitis.	Amphotericin B + fluorocytosine or fluconazole
Carcinomatous meningitis – lung/breast/gastrointestinal tract Leukaemia/lymphoma Glioma Medulloblastoma Melanoma.	Evidence of primary neoplasm. CT or MR evidence of meningeal enhancement CSF Malignant cells seen in fresh centrifuged filtered sample. Tumour markers: – carcinoembryonic antigen (CEA) – β -microglobulin Meningeal biopsy rarely necessary but diagnostic	Back pain/radicular involvement common. Hydrocephalus in 30%	Consider irradiation followed by intrathecal methotrexate or monoclonal targeting (see page 305). Leukaemia/lymphoma requires specialist advice

SUBACUTE/CHRONIC MENINGITIS

SUBACUTE/CHRONIC MENINGITIS WITH SLIGHTLY REDUCED OR NORMAL CSF GLUCOSE

Causes	Diagnosis	Specific features	Treatment
Parameningeal infections Cerebral abscess Epidural abscess Sinusitis Mastoiditis	Evidence of primary infected source <i>X-rays</i> Sinuses, mastoids. <i>CT/MR scan</i> – cerebral or cerebellar abscess <i>CSF microscopy/culture</i> <i>Blood cultures</i>	Prodromal sinus or middle ear infection	Appropriate antibiotic therapy and, if indicated, surgical drainage of loculated parameningeal infection
Bacteria: <i>Treponema</i> <i>Brucella</i> <i>Leptospira</i> <i>Listeria</i> <i>Borrelia</i> <i>Burgdorferi</i>	<i>CSF</i> Isolate organism (if possible) Serological tests <i>Serum</i> Serological tests	<i>Treponema</i> – page 480 Sexual contact <i>Brucella</i> Contact with infected cattle <i>Leptospira</i> page 482 Contact with contaminated rat, dog or cattle urine <i>Listeria</i> Contaminated – page 494 foods <i>Borrelia</i> <i>Burgdorferi</i> – page 481 Tick bite	Appropriate antibiotic
Miscellaneous Parasites, e.g. toxoplasma – see page 483 Sarcoidosis – see page 347 Behçet's disease Whipple's disease Systemic lupus erythematosus – see page 261			
Chemical – leakage from epidermoid dermoid cyst or craniopharyngioma – Intrathecal drugs and contrast material			

Despite extensive investigation, a group of patients with chronic meningitis exists in whom no cause is found.

DEMYELINATING DISEASES – INTRODUCTION

Demyelinating disorders of the central nervous system affect *myelin* and/or *oligodendroglia* with relative sparing of *axons*.

The central nervous system is composed of *neurons* with *neuroectodermal* and *mesodermal* supporting cells.

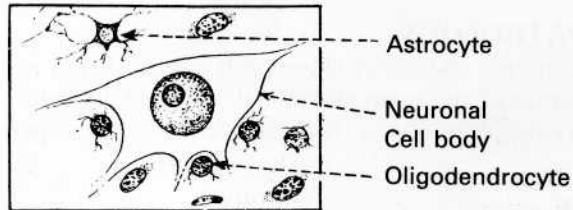
The neuroectodermal cells comprise:

astrocytes
ependymal cells
oligodendrocytes.

The oligodendrocytes, like Schwann cells in the peripheral nervous system, are responsible for the formation of *myelin* around central nervous system *axons*.

One Schwann cell myelinates one axon but one oligodendrocyte may myelinate several contiguous axons, and the close proximity of cell to axon may not be obvious by light microscopy.

Oligodendrocytes are present in grey matter near neuronal cell bodies and in white matter near axons.



Myelin is composed of *protein* and *lipids*.

Protein accounts for 20% of total content.

The lipid fraction may be divided into:

cholesterol
glycophosphatides
(lecithins)
sphingolipids
(sphingomyelins).

The laying down of myelin in the central nervous system commences at the fourth month of fetal life in the median longitudinal bundle, then in frontal and parietal lobes at birth. Most of the cerebrum is myelinated by the end of the 2nd year. Myelination continues until the 10th year of life.

Myelin disorders may be classified as diseases in which:

1. Myelin is inherently abnormal or was never properly formed – these disorders generally present in infancy and early childhood and have a biochemical basis, e.g. *leukodystrophy*.
2. Myelin which was normal when formed breaks down as a consequence of pathological insult, e.g. *multiple sclerosis*.

MULTIPLE SCLEROSIS

Multiple sclerosis (MS) is a common demyelinating disease, characterised by focal disturbance of function and a relapsing and remitting course.

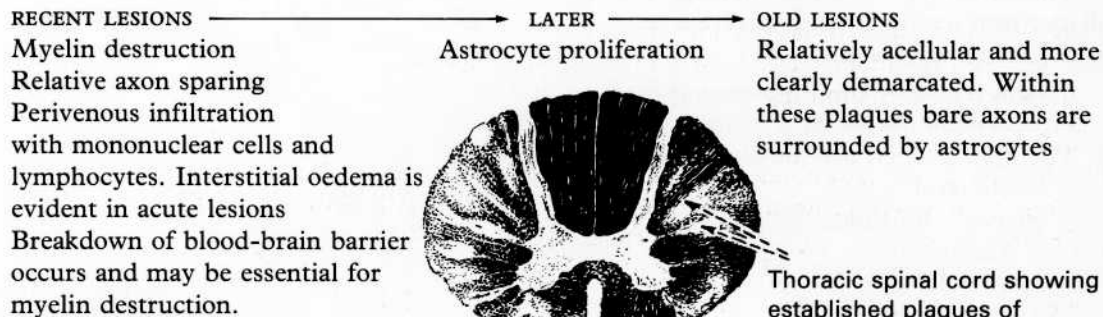
The disease occurs most commonly in temperate climates and prevalence differs at various latitudes:

	Latitude (°N)	Rate/100 000 (adjusted)
Orkneys and Shetlands	60	309
England (Cornwall).....	51	63
Italy (Bari).....	41	13

The disease usually occurs in young adults with a peak age incidence of 20–40 years. Slightly more females than males are affected. There is a 3% risk of disease if a sibling or parent is affected.

PATHOLOGY

Scattered lesions with a greyish colour, 1 mm to several cm in size, are present in the white matter of the brain and spinal cord and are referred to as *plaques*. The lesions lie in close relationship to veins (postcapillary venules) – perivenous distribution.



PATHOGENESIS

Immune deficiency has been suggested. This might explain the possible persistence of a latent virus and variations in immune status could be the basis of 'relapses and remissions'. T lymphocytes and macrophages found in plaques may be sensitized to myelin antigens.

Hereditary/genetic factors appear significant. There is an increased familial incidence of multiple sclerosis. This has led to the study of *histocompatibility antigens* (HL-A). An association between A3, B7, B18 and DW2/DRW2 and multiple sclerosis has been demonstrated. Concordance rate in monozygotic twins is 30% and in dizygotes 5%. Affected women transmit MS to offspring more frequently than affected men suggesting that mitochondrial genes contribute to inheritance.

Viruses may be important in the development of multiple sclerosis, infection perhaps occurring in a genetically/immunologically susceptible host.

Elevated serum and CSF antibody titres have been found to:

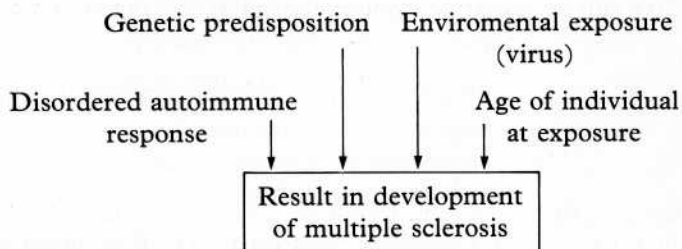
- varicella zoster, measles, rubella and herpes simplex during relapse.

Biochemical: No biochemical effect has been demonstrated – myelin appears normal before breakdown and the proposed excess of dietary fats or malabsorption of unsaturated fatty acids is unproven.

MULTIPLE SCLEROSIS

PATHOGENESIS (contd)

In summary – the causation is probably multifactorial.



CLINICAL FEATURES

Peak age of onset	– 20–25 years
Childhood onset rare	– 2%
Patients presenting > 50 years	– 5%
Patients presenting > 60 years	– 1%

Multiple sclerosis is usually characterised by:

- Signs and symptoms of widespread white matter disease.
- A relapsing and remitting or progressive course.

Symptoms at onset

1. *Vague symptoms*: lack of energy, headache, depression, aches in limbs – may result in diagnosis of psychoneurosis. These symptoms are eventually associated with:
2. *Precise symptoms*:

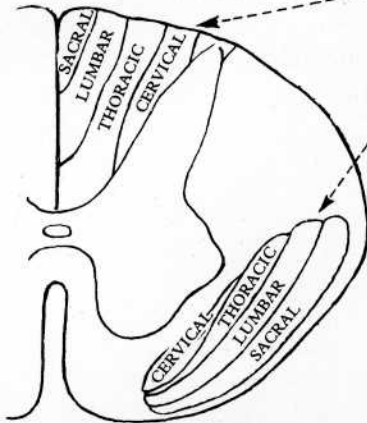
Sensory disturbance	– 40%
Retrobulbar neuritis	– 17%
Limb weakness	– 12%
Diplopia	– 11%
Vertigo	} 20%
Ataxia	
Sphincter disturbance	

Trigeminal neuralgia may be an early symptom of multiple sclerosis, and this should be considered in the young patient with paroxysmal facial pain.

MULTIPLE SCLEROSIS

Sensory symptoms


Numbness and paraesthesia are common and often so transient as to be forgotten. Paraesthesia is more often due to posterior column demyelination than to spinothalamic tract involvement.



Posterior column lesions result in impaired vibration sensation and joint position sensation. In such cases a limb may be rendered 'useless' by the absence of positional awareness.

Lhermitte's sign: with cervical posterior column involvement sudden neck flexion will evoke a 'shock-like' sensation in the limbs.

Spinothalamic lesions result in dysaesthesia – an unpleasant feeling of burning, coldness or warmth, with associated sensory loss to pain and temperature contralateral to the lesion.



A plaque at the posterior root entry zone will result in loss of *all* sensory modalities in that particular root distribution.

Motor symptoms

Monoparesis and paraparesis are the most common motor symptoms. Hemiparesis and quadriparesis occur less commonly.

Paraparesis is the result of spinal demyelination, usually in the cervical region.

- Signs*:
- Increased tone
 - Hyperactive tendon reflexes, extensor plantar response and absent abdominal reflexes
 - Pyramidal distribution weakness.

N.B. A plaque at the anterior root exit zone will result in lower motor neuron signs (reflex loss and segmental wasting)

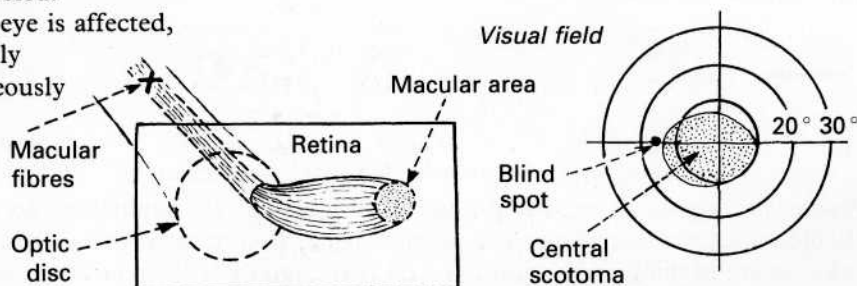


MULTIPLE SCLEROSIS

Disturbance of vision

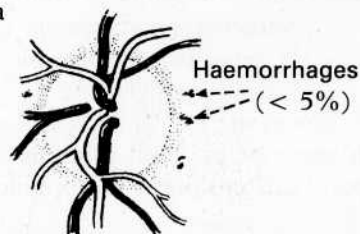
Acute optic neuritis (Retrobulbar neuritis): Visual loss associated usually with a central scotoma and recovery over some weeks. This disorder commonly occurs in young adults. The visual loss develops over several days and is often associated with pain on ocular movement (irritation of the dural membrane around the optic nerve). In milder forms, only colour vision is affected.

Typically only one eye is affected, although occasionally both eyes simultaneously or consecutively are involved. Acuity is usually more than $\frac{6}{24}$.



On examination: Disturbance of visual function ranges from a small central scotoma to complete loss. Fundal examination reveals swelling – papillitis – in up to 50% of patients, depending upon the proximity of the plaque to the optic nerve head.

'Sheathing' from an inflammatory exudate around peripheral retinal venules is common. Reduced visual acuity distinguishes papillitis from papilloedema.



Investigation: Visual evoked responses (VERs) show delay. High resolution CT or MRI of the optic nerve excludes tumour. MR confirms the presence of plaque.

Treatment: Steroids shorten the duration of visual loss and ease pain when present. I.v. methylprednisilone not only speeds recovery but may delay the development of MS.

Outcome: 90% of patients recover most vision, although symptoms may transiently return following a hot bath or physical exercise – Uhthoff's phenomenon. Following recovery the optic disc develops an atrophic appearance with a pale 'punched out' temporal margin.

Subsequent course:

- No evidence of multiple sclerosis occurs in patient's lifetime.
- or
- Symptoms and signs of demyelination elsewhere in the nervous system follow – multiple sclerosis.

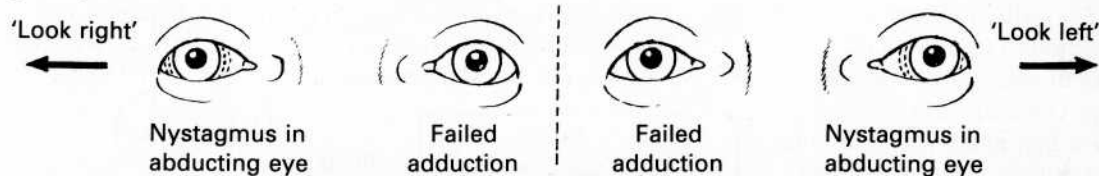
Over a 5-year period from presentation, 75% of patients fall into the last group. Onset in winter, the presence of 'silent' cerebral lesions on cranial MRI and the presence of certain histocompatibility antigens, e.g. HLA DR2, increase the risk of subsequent MS.

Acute bilateral optic neuritis: less common than unilateral disease and progression to MS not as likely. Occasionally followed by a transverse myelitis (Neuromyelitis optica, page 509). Examination of mitochondrial DNA distinguishes from Leber's hereditary optic neuropathy (page 531).

MULTIPLE SCLEROSIS

Disturbance of ocular movement

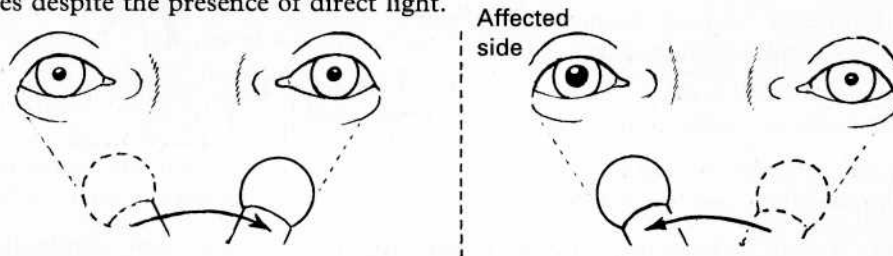
Diplopia may result from demyelination affecting the brain stem pathway of the III, IV or VI cranial nerves. Abnormality of eye movements with or without diplopia occurs when supranuclear or internuclear connections are involved. The latter results from a lesion in the medial longitudinal fasciculus – *internuclear ophthalmoplegia* – and in young persons is pathognomonic of MS.



Nystagmus may be an incidental finding on neurological examination. Its presence should be sought as evidence of a second lesion. It is unusual in multiple sclerosis when the eyes are in the primary position, and is commonly seen on lateral gaze. Pupillary abnormalities may occur from:

- sympathetic involvement in the brain stem (Horner's syndrome)
- III nerve involvement, or
- II nerve involvement.

The swinging light test is a sensitive test of impaired afferent conduction in the II nerve. Alternating the light from one eye to the other results eventually in 'pupillary escape' – the pupil dilates despite the presence of direct light.



OTHER FEATURES

Vestibular symptoms: Vertigo of central type may be a presenting problem or it may develop during the course of the illness. Hearing loss is rare.

Ataxia of gait and limb inco-ordination are frequently present. The gait ataxia may be cerebellar or sensory type (see Romberg's test). Limb inco-ordination, intention tremor and dysarthria indicate cerebellar involvement.

Sphincter disturbance with urgency or precipitancy of micturition and eventual incontinence occurs. Conversely urinary retention in a young person may be the first symptom of disease. On direct questioning, impotence is frequently found.

Mental changes: Mood change – euphoria or depression occur. Dementia develops in advanced cases. Generalised fatigue is common.

Emotional lability: Uncontrolled outbursts of crying or laughing, result from involvement of pseudobulbar pathways.

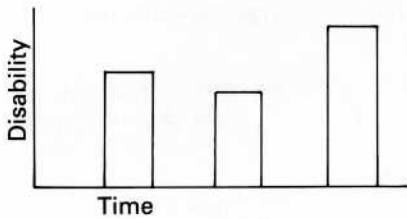
Paroxysmal (symptoms occurring momentarily throughout any stage of the disease):

Paraesthesia, dysarthria, ataxia, pain, e.g. trigeminal neuralgia, photopsia (visual scintillations), epilepsy.

MULTIPLE SCLEROSIS

CLINICAL COURSE

The pattern of illness in individual sufferers cannot be predicted. Several different rates of disease activity and progression have been defined.

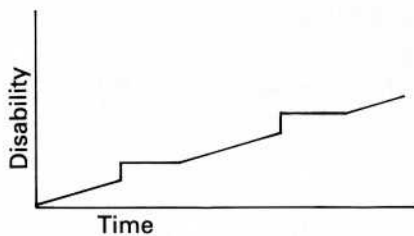
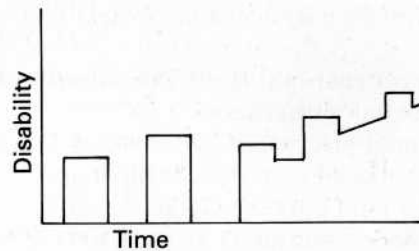


1. Relapsing and remitting

Of all patients with MS, 70% pass through this stage. With each attack recovery is virtually complete. This phase of illness may persist for many years. The explanation of why relapses take place is unknown.

2. Chronic Progressive (Secondary progressive)

After a period of time, relapsing and remitting MS attacks are followed by incomplete recovery and cumulative loss of function and disability. At any one time, the chronic progressive stage accounts for 20% of all sufferers. Converting from relapsing and remitting to secondary progressive occurs on average 6–10 years after the initial symptoms.

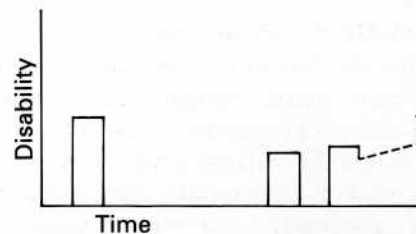


3. Chronic Progressive from onset (Primary progressive)

This form is common in late onset MS (>45 yrs) and accounts for 15% of all patients. Symptoms and signs are usually spinal and relapses barely noticeable in the context of insidious progression.

4. Benign

There is no clear definition of this form. Many years may pass between each attack and if in time progression does occur, the rate is slow and disability negligible. Support for this benign form comes from the occasional incidental finding of incidental MS at autopsy.



Recognition of different phases of MS is essential in giving an informed prognosis as well as selecting patients for, and evaluating results of clinical trials. The degree of disability can be recorded using specific scales such as the Kurtzke score or the Extended Disability Status Score (EDSS).

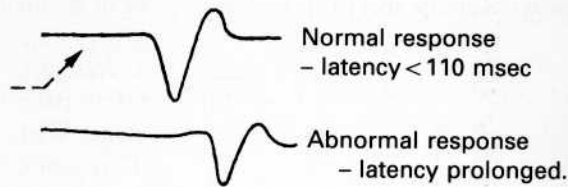
MULTIPLE SCLEROSIS

INVESTIGATIONS

There is no diagnostic test. Investigations only support the clinical suspicion.

Neurophysiological: may detect a second asymptomatic lesion (see page 52).

1. *Visual evoked potential (VEP)*. In optic nerve involvement the latency of the large positive wave is delayed beyond 110 msec. The amplitude of the waves may also be reduced.



2. *Somatosensory evoked response (SSEP)* may detect central sensory pathway lesions.

3. *Brain stem auditory evoked potential (BAEP)* may detect brain stem lesions.

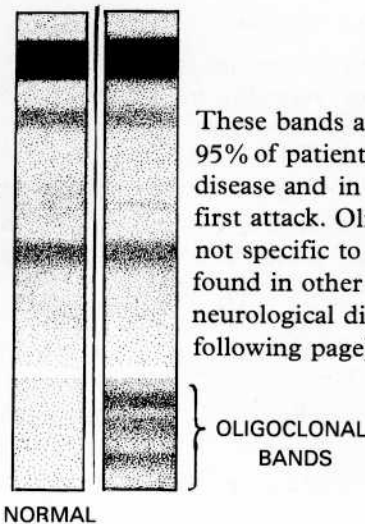
Cerebrospinal fluid examination by lumbar puncture

A mild pleocytosis (25 cells/mm³), mainly lymphocytes, is occasionally found.

The total protein may be elevated, although this rarely exceeds 100 mg/l.

An increase in gammaglobulin occurs in 50–60% of cases.

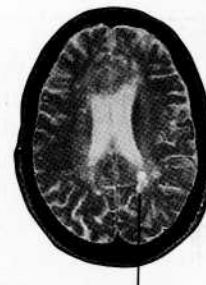Electrophoresis of CSF using agar or acrylamide shows discrete bands which are not present in serum.



These bands are found in up to 95% of patients with established disease and in 50–60% after the first attack. Oligoclonal bands are not specific to MS and can be found in other inflammatory neurological diseases (see following page).

MRI

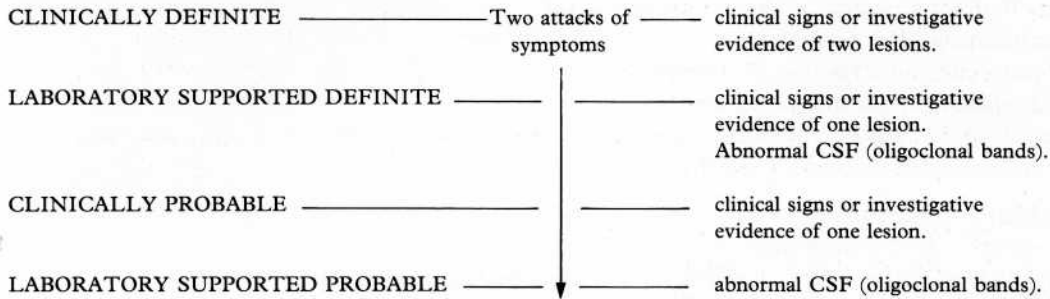
This has contributed enormously to the diagnosis and understanding of MS. Normal white matter appears dark with low signal intensity in T2 weighted images. Myelin breakdown produces a longer relaxation time and increased signal on T2. Gliosis produces similar changes. The presence of white matter abnormalities with a periventricular distribution is suggestive but not diagnostic of MS. Paramagnetic contrast (Gadolinium) will show active inflammation. A combination of MRI and CSF (oligoclonal band) will rule out MS if both are negative. MR may predict long term outcome – following a single episode of demyelination (e.g. optic neuritis or transverse myelitis). Those with cranial MR abnormalities will relapse sooner than those without. At present MRI does not correlate well with disability, but newer techniques may be more sensitive measures of disease progression.



Periventricular lesions, most evident at frontal and occipital horns. Abnormalities are also seen in the brain stem and cerebellum. Lesions of the optic nerves and spinal cord are more difficult to detect.

MULTIPLE SCLEROSIS

Diagnostic criteria have been proposed (Poser Committee 1983). These were primarily conceived for research and clinical trials of therapy but are also of use to the clinician.



(Modified from Poser 1983 *Annals of Neurology* 13:227-231.)

DIFFERENTIAL DIAGNOSIS

Many conditions mimic multiple sclerosis and unless strict diagnostic criteria are adhered to other treatable disorders will be missed.

Conditions with similar clinical presentations to MS

Inflammatory disorders

- Systemic lupus erythematosus
- Polyarteritis nodosa
- Behçet's disease

Isolated cranial disorders

- AVM
- Meningioma

Granulomatous disorders

- Sarcoidosis
- Wegener's granulomatosis

Miscellaneous disorders

- Spinocerebellar degeneration
- Mitochondrial disorders
- Adrenoleukodystrophy

Isolated spinal cord/foramen magnum disorders

- Extrinsic/intrinsic tumours
- Vitamin B₁₂ disease
- Lyme disease
- Acute disseminated encephalomyelitis

Conditions with similar MRI appearances to MS

- Vasculitis
- Sarcoidosis
- Leukodystrophies
- Acute disseminated encephalomyelitis
- Lyme disease
- Chronic inflammatory demyelinating polyneuropathy
- Small vessel vascular disease
- Decompression sickness

Conditions with similar CSF profile to MS (presence of oligoclonal bands)

- HIV infection
- Lyme disease
- Syphilis
- Subacute sclerosing panencephalitis (SSPE)
- Chronic meningitis
- Neurosarcoidosis

MULTIPLE SCLEROSIS – TREATMENT

SYMPTOMATIC

● Spasticity

Drugs that act at spinal or skeletal muscle level

- Baclofen (GABA derivative)
- Dantrolene (direct action on muscle)
- Tizanidine (α_2 adrenergic agonist)

All given orally. Baclofen can be administered intrathecally (implantable drug delivery system) in severe cases.

● Urinary symptoms

Incomplete bladder emptying – intermittent self-catheterisation

- Detrusor instability – anticholinergics (oxybutynin)
– Desmopressin spray.

● Bowel symptoms

Constipation or faecal incontinence

- lactulose
- loperamide (opiate receptor agonist - increases anal sphincter tone).

● Pain

Analgesics, anticonvulsants, antidepressants or NSAIDs

● Paroxysmal symptoms

e.g. tonic seizures – anticonvulsants

● Fatigue

Amantadine or CNS stimulant pemoline

● Tremor

Betablockers, primidone and in severe cases thalamic ablation or stimulation.

ACUTE RELAPSE

Methylprednisolone 1 gram/day i.v. for 3 days followed by a reducing dose of oral prednisolone will speed recovery.

If used in an initial attack of optic neuritis it will reduce the number of relapses within the next 2 years.

MODIFY NATURAL HISTORY

No benefit from long-term steroids. Cyclophosphamide, azathioprine, total lymphoid irradiation and plasma exchange – anecdotal evidence of benefit in aggressive illness. Low dose methotrexate of marginal value in primary and secondary progressive disease.

Interferons (Beta 1B and 1A)

Possibly by down-regulation of antigen recognition will in the short-term reduce relapse rates but have no or little effect on disability.

Similar results have been obtained from **Copolymer I** (a synthetic polypeptide). The interferons and copolymer I show a reduction in the rate of MRI change.

OTHER DEMYELINATING DISEASES

NEUROMYELITIS OPTICA (Devic's disease)

A subacute disorder characterised by simultaneous or consecutive demyelination of the optic nerves and spinal cord. Initially considered a distinct entity, it is now regarded as a form of multiple sclerosis. An identical syndrome occurs in systemic lupus erythematosus.

Clinical features

Visual loss is rapid, bilateral and occasionally total.

Spinal cord symptoms follow – hours, days or occasionally weeks later.

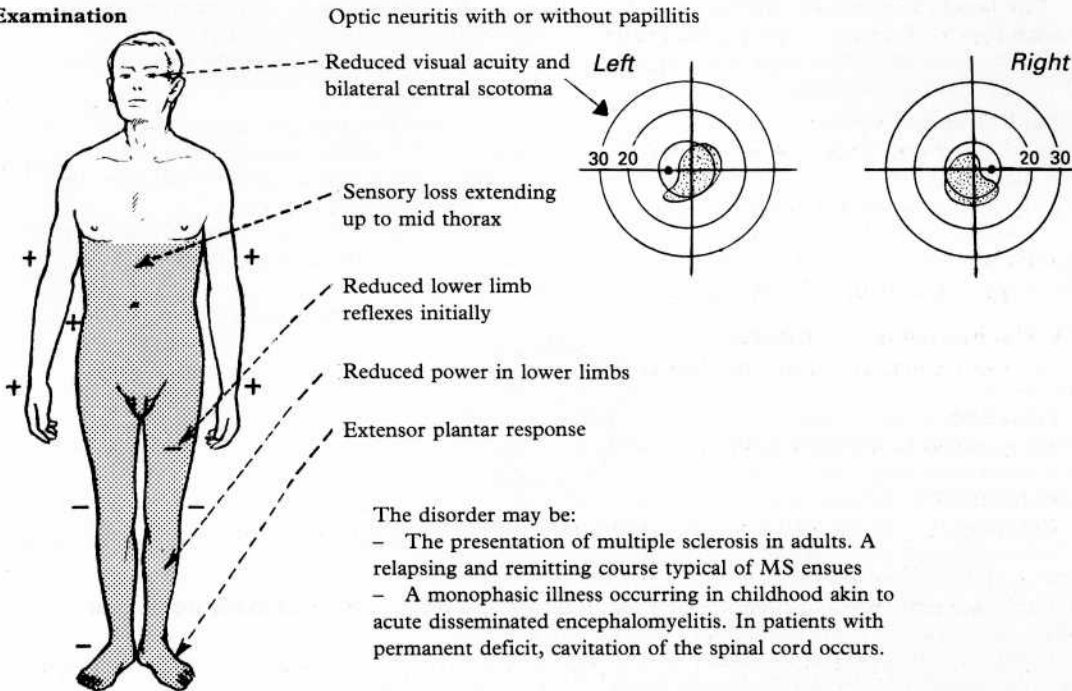
Back pain and girdle pain. Paraesthesia in lower limbs.

Paralysis may ascend to involve respiratory muscles.

Urinary retention is common.

Recovery is complete in 60–70% of patients.

Examination



Investigations

Visual evoked responses are prolonged.

The CSF shows an elevated protein with a lymphocytosis occasionally as high as 1000 cells per mm³. Gammaglobulin may be elevated and oligoclonal bands present.

MRI may be abnormal in those who go on to a relapsing and remitting course.

TRANSVERSE MYELITIS

This occasionally occurs as the first manifestation of MS but this also occurs with viral infection (e.g. herpes virus), vasculitis and atherosclerotic vascular disease. Only 10% of patients with idiopathic transverse myelitis progress to MS. Investigations should exclude other causes of acute spinal cord syndrome – spinal cord compression – by MRI or myelography.

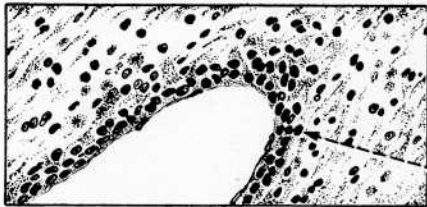Treatment

Steroids are often given, (I.V. Methylprednisolone).

Treatment is otherwise supportive.

OTHER DEMYELINATING DISEASES

ACUTE DISSEMINATED ENCEPHALOMYELITIS (ADEM) (postinfectious encephalomyelitis)



ADEM is an acute immune-mediated demyelinating disorder in which small foci of demyelination with a perivenous distribution are scattered throughout the brain and spinal cord. Lesions are 0.1–1.0 mm in diameter.

Microglial, plasma cell and lymphocyte exudate around venules. Myelin becomes fragmented.

This disorder may follow upper respiratory and gastrointestinal infections (viral), viral exanthems (measles, chickenpox, rubella, etc.) or immunisation with live or killed virus vaccines (influenza, rabies).

Measles is the commonest cause occurring in 1 per 1000 primary infections; next Varicella zoster (chickenpox), 1 per 2000 primary infections.

Clinical features: Within days or weeks of resolution of the viral infection, fever, headache, nausea and vomiting develop. Meningeal symptoms (neck stiffness, photophobia) are then followed by drowsiness and multifocal neurological signs and symptoms – hemisphere brain stem/cerebellar/spinal cord and optic nerve involvement. Myoclonic movements are common.

Predominantly *spinal*, *cerebral* or *cerebellar* forms occur, though usually the picture is mixed. Optic nerve involvement takes the form of optic neuritis. Rarely the peripheral nervous system is involved.

Diagnosis: No diagnosis test.

CSF – 20–200 mononuclear cells.

Total protein and γ globulin raised.

Peripheral blood may be normal or show neutrophilia, lymphocytosis or lymphopenia.

The electroencephalogram (EEG) shows diffuse slow wave activity.

CT scan is normal. MRI shows small focal white matter changes, simultaneously enhancing with contrast indicating that all are of the same degree of acuteness (unlike MS).

Diagnosis is straightforward when there is an obvious preceding viral infection or immunisation. When viral infection *immediately* precedes, distinction from acute encephalitis is often impossible.

Separation from acute MS may be difficult. Fever, meningeal signs with elevated CSF protein above 100 mg/ml with cell count greater than 50 per mm^3 suggest ADEM.

Pathology: demyelination is limited to perivascular areas and lesions do not approach the same size as in MS.

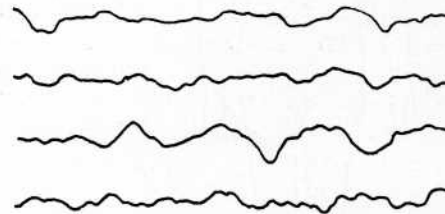
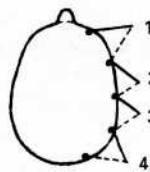
Outcome: The illness is typically monophasic.

The mortality rate is 20%.

Full recovery occurs in 50%.

Poor prognosis is associated with an abrupt onset and the degree of deficit.

Treatment: Steroids are used, although no controlled trials have been conducted. Large dosage is recommended during the acute phase. Cyclophosphamide may be used in refractory cases.



Generalised asynchronous delta activity

OTHER DEMYELINATING DISEASES

ACUTE HAEMORRHAGIC LEUKOENCEPHALITIS

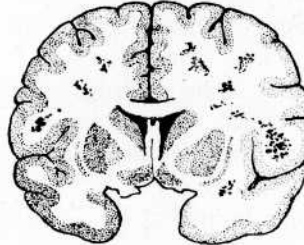
This is a rare demyelinating disease. It is regarded as a very acute form of postinfectious/acute disseminated encephalomyelitis.

Clinical picture: Antecedent viral infection, depression of conscious level and multifocal signs and symptoms. Focal features may suggest a mass lesion or even herpes simplex encephalitis.

The diagnosis is only really possible at biopsy or autopsy, but elevated CSF pressure, lymphocytosis and erythrocytes in CSF and xanthochromic appearance of fluid are all suggestive.

Pathology: Perivascular polymorph infiltration. Microscopic and macroscopic haemorrhage. Perivascular demyelination and necrotising changes in vessels.

Treatment: Steroids in high dosage should be used though evidence of value in this rare condition is scant.



PROGRESSIVE MULTIFOCAL LEUKOENCEPHALOPATHY

This is a demyelinating disease occurring in association with systemic illness in which cell-mediated and occasionally humoral immunity is depressed, e.g. AIDS (4% of cases), lymphoma, sarcoidosis, systemic lupus erythematosus. The disorder is due to reactivation of previous papavirus (SV40 or JC virus) infection.

Clinical picture: Features of diffuse process – personality change, hemiparesis, cortical visual loss, seizures, etc. Duration of illness: 3–6 months. Non-remitting and fatal.

Pathology: Demyelination without inflammatory response, especially in subcortical white matter. Electron microscopy – papovavirus in oligodendroglia.

Diagnosis: CT scanning and MRI reveal widespread multifocal white matter damage. Definitive diagnosis is made from brain biopsy. Virus can be isolated by inoculation on to glial tissue culture.

Treatment: Interferon – alpha and cytosine arabinoside may slow progression.

LEUKODYSTROPHIES

Inborn errors of metabolism may affect the normal development of myelin. These genetic disorders usually present in infancy or childhood but occasionally produce their first manifestations in adult life.

3 specific types are recognised

- Metachromatic leukodystrophy
- Globoid cell leukodystrophy
- Adrenomyeloneuropathy or adrenoleukodystrophy (ADL).

The last condition is sex linked, characterised by adrenal insufficiency and disordered myelin in brain, spinal cord and peripheral nerve. The clinical picture is highly variable and results from a defect in beta oxidation of very long chain fatty acids (VLCFA) which build up in blood and skin fibroblasts. Dietary treatments (Lorenjo's oils) lower these and may slow progression of this fatal disorder. Heterozygote female carriers may become symptomatic with a late onset progressive myelopathy.

NEUROLOGICAL COMPLICATIONS OF DRUGS AND TOXINS

Introduction

Drugs and toxins commonly affect the nervous system. They cause a spectrum of disorders of which most are potentially reversible on withdrawal of the causal agent.

Diagnostic suspicion is especially dependent upon history:

- Availability of drugs.
- Occupational/industrial exposure to toxins.

Drug toxicity may result from:

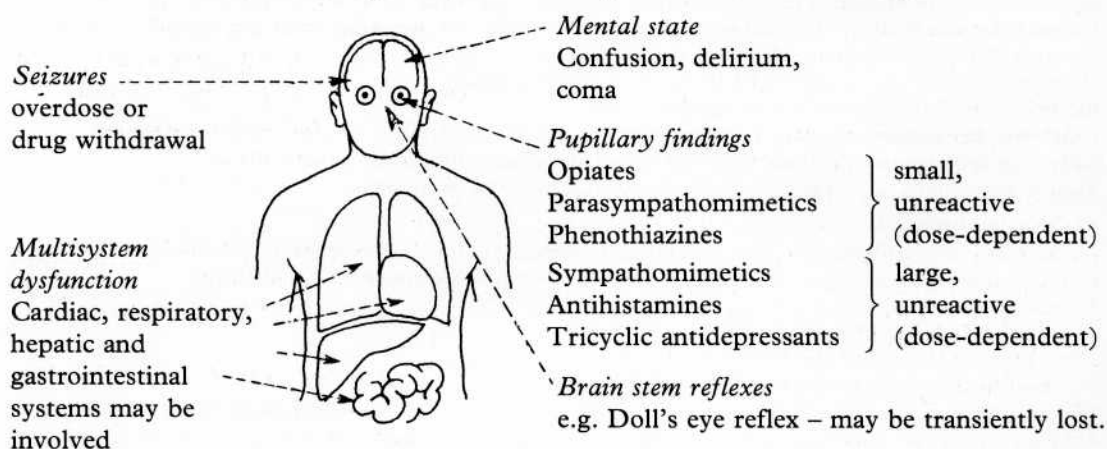
- The chronic abuse of drugs, e.g. barbiturates, opiates.
- The side effects of drug therapy, e.g. anticonvulsants, steroids.
- The wilfull overdosage of drugs, e.g. sedatives, antidepressants.

Toxin exposure may be:

- Accidental: industrial or household poisons, e.g. organophosphates, carbon monoxide, turpentine.
- Wilful: solvent abuse.

History and examination

When acute intoxication is suspected, the following clinical features are supportive.



Also: Note

- Puncture marks in narcotic addicts
- The presence of a snout area rash in solvent abusers
- Rashes in barbiturate poisoning
- Respiration rate in salicylate poisoning
- Skin colour in carbon monoxide poisoning.

Clinical features:

While the neurological picture is generally diffuse, certain pronounced symptoms occur with one drug or toxin and not with another. The following table should act as a guide to diagnosis and alert the clinician to the possible offending substance.

For treatment, the reader is advised to consult an appropriate pharmacology or general medical text.

DRUG-INDUCED NEUROLOGICAL SYNDROMES

HEADACHE

Vasodilators: antihistamines, sympathomimetics, calcium channel blockers, bronchodilators, ergotamine, cocaine

Dopamine agonists

Non-steroidal anti-inflammatories

SEIZURES

Antidepressants, antimicrobials: cycloserine, isoniazid, metronidazole, penicillin

Antineoplastics: vincristine, methotrexate.

Analgesics: pentazocine, fentanyl, opiates

Anaesthetics: ketamine, halothane, althesin

Bronchodilators. Sympathomimetics

Miscellaneous: amphetamine, baclofen, lithium, iodinated contrast media, insulin

CONFUSION/DELIRIUM

Anticholinergics. Anticonvulsants

Antimicrobials: isoniazid, rifampicin

Antineoplastics: vincristine

Dopamine agonists. Tranquillisers

Miscellaneous: cimetidine, ranitidine, lithium

PERIPHERAL NEUROPATHY

Antimicrobials: ethambutol, isoniazid, nitrofurantoin, metronidazole, dapsone

Antineoplastics: cytosine arabinoside, cisplatin, procarbazine, vincristine (and other vinca alkaloids)

Antirheumatics: colchicine, D-penicillamine, gold, indomethacin

Miscellaneous: cimetidine, phenytoin

RETINOPATHY

Antimalarials: chloroquine, mepacrine

VIII NERVE DAMAGE

Aminoglycoside antibiotics: gentamicin, kanamycin, neomycin, streptomycin

Miscellaneous: cisplatin, ethyrcinic acid, quinine, salicylates

VISUAL DISTURBANCE

Phenothiazines Miscellaneous:

ethambutol, indomethacin, tamoxifen

OPTIC NEURITIS

Antimicrobials: chloramphenicol dapsone, isoniazid, streptomycin

Miscellaneous: chlorpropamide

MOVEMENT DISORDERS

Antiemetics: metoclopramide

Butyrophenones: haloperidol, droperidol

Dopamine agonists. Phenothiazines:

chlorpromazine, thioridazine

Tricyclic antidepressants

ATAXIA

Anticonvulsants: carbamazepine, phenytoin, primidone

Antineoplastics: cytosine arabinoside, fluoracil

Phenothiazines: sedatives; barbiturates, chloral hydrate. Tranquillisers: diazepam

MUSCLE PAIN AND WEAKNESS

Antineoplastics: cytosine arabinoside, methotrexate, thiopeta

Miscellaneous: clofibrate, D-penicillamine, danazol, L-tryptophan.

Drug screen in suspected overdoseage

Too often the clinician, when managing drug or toxin overdosage, requests a 'drug screen'. The techniques used in detection, e.g. gas chromatography, thin-layer chromatography and immunological tests, are sophisticated and time-consuming and may require samples of serum, urine or both.

The clinician must 'narrow down the field' from the history and presenting symptoms/signs and discuss with the laboratory the class of drug or toxin he suspects.

A knowledge of the blood level of some drugs, e.g. salicylates, barbiturates, is important in deciding the approach to treatment.

SPECIFIC SYNDROMES OF DRUGS AND TOXINS

NEUROLEPTIC MALIGNANT SYNDROME

A rare life-threatening disorder induced by initiation, increase or reintroduction of neuroleptic drugs (e.g. chlorpromazine, haloperidol). The condition appears to result from acute dopamine receptor blockade and is characterised by *hyperpyrexia, bradykinesia, rigidity, autonomic disturbance, alteration of consciousness* and *high serum muscle enzymes (creatinase)*. The causal drug should be withdrawn and the patient cooled. Give dopamine agonists with dantrolene sodium to control bradykinesia and rigidity respectively. Death occurs in 15% from renal failure and/or cardiovascular collapse.

SOLVENT ABUSE

The abuse of volatile solvents is an increasing problem especially in children. The purpose of inhalation is to achieve a state of euphoria. Habituation develops. Commonly used substances are: aerosols, cleaning fluids, nail varnish remover, lighter fluids, 'model' glue. The 'active' components of these are simple carbon-based molecules, e.g. benzene, hexane and toluene.

Symptoms of acute intoxication:

- Euphoria
- Dysarthria, ataxia, diplopia
- Delusions and hallucinations occur, followed by seizures if exposure has been prolonged.

Death may result:

- Aspiration/asphyxiation
- Cardiac arrhythmias
- Renal or hepatic damage.

Treatment of acute intoxication is symptomatic; there are no specific antidotes.

Industrial exposure to hydrocarbons produces similar symptoms.

Symptoms of chronic abuse:

- Behavioural disturbance.
- Chronic ataxia.
- Sensorimotor peripheral neuropathy.

ORGANOPHOSPHATES

These are widely used as insecticides (sheep dip) and herbicides. They cause symptoms by phosphorylation of the enzyme acetyl cholinesterase. Acute intoxication produces seizures, autonomic disturbance and coma. Chronic exposure results in fatigue, muscle weakness and fasciculation associated with non-specific weight loss and cognitive impairment.

LEAD EXPOSURE

Lead has no biological function. It is present in normal diet as well as in the atmosphere from automobile fumes and in the water supply of old buildings containing lead tanks and piping. Occupation exposure occurs in plumbers, burners and smelters.

Lead excess interferes with *haem* synthesis. This results in the accumulation of 'blocked' metabolites such as aminolevulinic acid (ALA) in serum and urine. It also inhibits oxidative enzymes (e.g. Superoxide dismutase).

Anaemia occurs with a characteristic finding in the blood film (basophilic stippling).

Both the peripheral and central nervous systems are affected.

ADULTS

A chronic motor neuropathy with minor sensory symptomatology. Axonal damage predominates.

Acute encephalopathy

rarely

CHILDREN

Peripheral neuropathy is rare. Encephalopathy is characteristic. (Lead salts cross blood brain barrier more easily in children)

Acute fulminating with confusion, impaired conscious level, coma, seizures, papilloedema.

Chronic with fatigue and irritability, headache, apathy.

Treatment

Chelating agents (e.g. calcium disodium edetate - EDTA - or D-penicillamine) and i.v. mannitol in acute encephalopathy with papilloedema.

In acute fulminating encephalopathy the mortality has been reduced to 5%, but neurological sequelae are common.

SPECIFIC SYNDROMES OF DRUGS AND TOXINS

COMPLICATIONS OF RECREATIONAL DRUG ABUSE

The problems of drug abuse are of epidemic proportions. An increasing number of neurological syndromes are recognised.

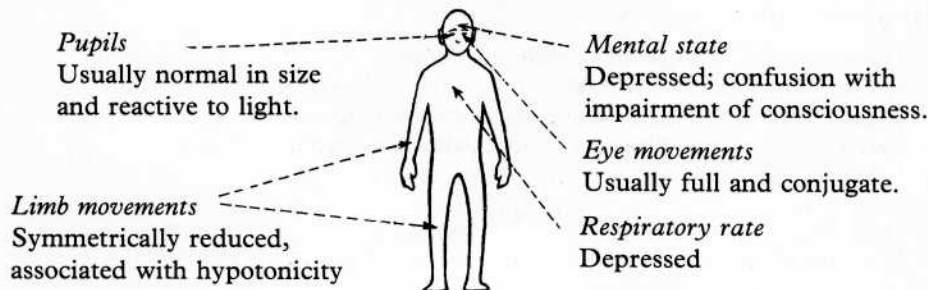
	Cocaine	Metamphetamine and Ecstasy	Heroin	Phencyclidine
<i>Origin</i>	Alkaloid from leaves of erythroxyton coca plant	Synthetic amphetamines	Alkaloid from poppy – papaver somiferin	Synthetic anaesthetic agent
<i>Clinical use</i>	Pain relief	Anorexia Narcolepsy Depression	Pain relief	Anaesthetic agent
<i>Popular name(s)</i>	'Coke', 'Snow', 'Crack' (potent pica base form)	'Speed' 'Uppers'		'Angel dust'
<i>Method of taking</i>	Oral Intranasal Intravenous	Oral Intravenous 'high speeding'	Oral Smoked Intravenous	Oral Smoked Intranasal
<i>Mode of action</i>	Blocks reuptake of dopamine and noradrenaline and augments neurotransmission (sympathomimetic)	Increases release of dopamine and adrenaline and augments neurotransmission (sympathomimetic)	Acts as opiate receptors located on the surface of neurons	Interference with multiple neurotransmitter function
<i>Moderate dosage</i>	Alertness ↑ Euphoria Blood pressure ↑	Alertness ↑ Euphoria Blood pressure ↑	Pupillary constriction Pleasurable abdominal sensation Facial flushing	Alertness ↑ Sweating Blood pressure ↑ Heart rate ↑
<i>Excessive dosage</i>	Blood pressure ↑↑ Temperature ↑ Respiration ↓ Cardiac dysrhythmia and sudden death	Blood pressure ↑↑ Temperature ↑ Respiration ↓ Cardiac dysrhythmia and sudden death	Pin-point pupils Respiration ↓ Coma	Dysarthria Psychosis Nystagmus Cardiac Ataxia dysrhythmia Vigilant but and sudden unresponsive death
<i>Treatment</i>	Haloperidol (blocks dopamine reuptake) Hypotensive agents Dysrhythmic agents Anticonvulsants	As for cocaine	Naloxone (opiate antagonist) Clonidine or Methadone (for withdrawal symptoms)	Haloperidol (for psychosis)
<i>Neurological complications</i>	Headache Tremor Myoclonus Seizures	Chorea Intracranial haemorrhage (drug-induced vasculitis)	Myelitis Neuropathies and Plexopathies (immune mediated)	Dystonia Athetosis Seizures Rhabdomyolysis

All recreational drugs are associated with increased risk of cerebral or spinal infarction or intracerebral haemorrhage. (Mechanisms are varied – drug-induced hypertension, coagulopathies, foreign body (tal) embolisation and septic emboli from infective endocarditis.)

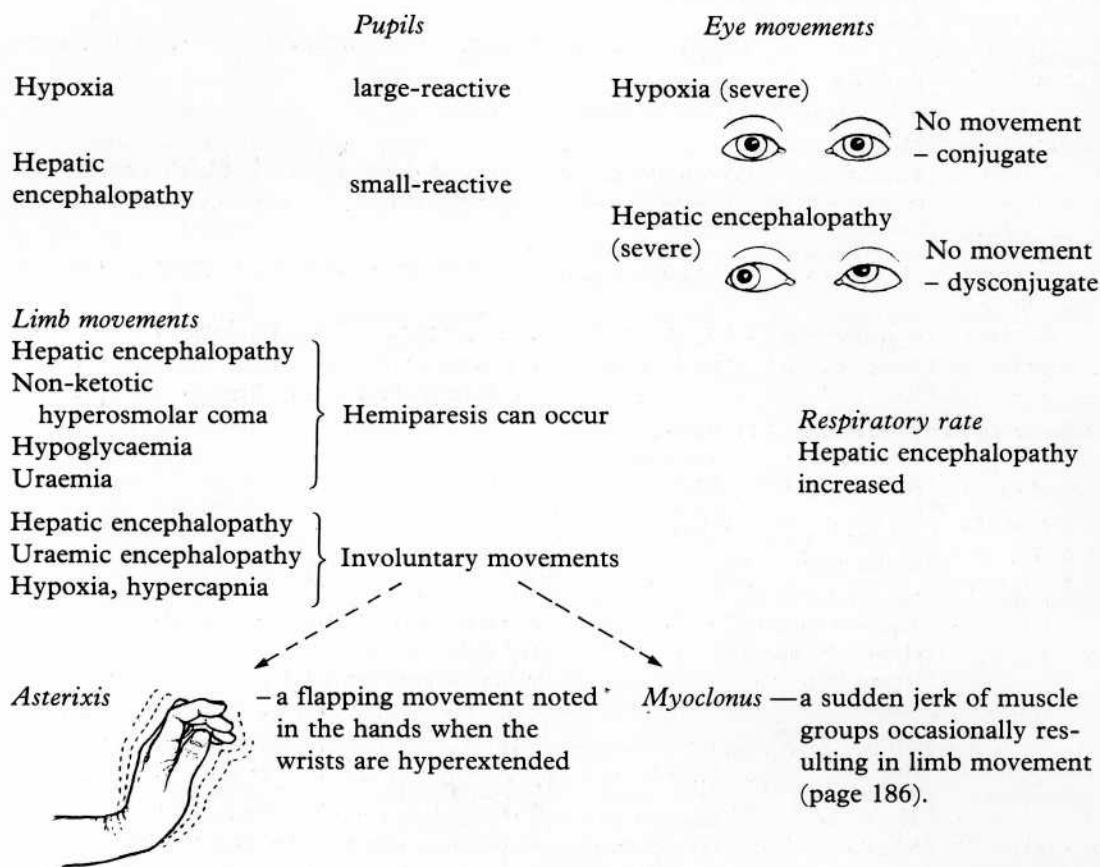
All intravenous drug abusers are at risk of HIV infection and its complications (page 495)

METABOLIC ENCEPHALOPATHIES

In general terms, the clinical features of metabolic encephalopathy are relatively stereotyped.



These features are characteristic but exceptions occur in specific encephalopathies —



Beware of the possibility of multiple pathology, e.g. an alcoholic patient with a chronic subdural haematoma may also have liver failure and thiamine deficiency.

CLASSIFICATION AND BIOCHEMICAL EVALUATION

Many metabolic disturbances cause an *acquired* encephalopathy in adults.

The most frequently encountered are:

- | | |
|-------------------------------------------------------------------------------------------------------------------------------------------------------------------------------|----------------------------------------------------------------------------------------------------------------------------------------------------------------------------------------------------------------------------------------------------------------------|
| <ul style="list-style-type: none"> - Hypoxic - Hypercapnoeic - Hypoglycaemic - Hyperglycaemic - Hepatic - Uraemic | <p>Less commonly:</p> <ul style="list-style-type: none"> - Hyponatraemia. Hypernatraemia. - Hypokalaemia. Hyperkalaemia. - Hypocalcaemia. Hypercalcaemia. - Hypothyroidism. Lactic acidosis. - Addison's disease. |
|-------------------------------------------------------------------------------------------------------------------------------------------------------------------------------|----------------------------------------------------------------------------------------------------------------------------------------------------------------------------------------------------------------------------------------------------------------------|

Drugs and toxins producing encephalopathy are dealt with separately (page 512).

Laboratory assessment of suspected metabolic encephalopathy

All patients should have a basic biochemical screen:

- Serum urea and electrolytes.
- Liver function (albumin, globulin, bilirubin, alkaline phosphatase and enzymes) and random blood glucose.
- Blood gases (pH, PO_2 , PCO_2).
- Serum ammonia.
- Electroencephalography – slow wave activity (theta or delta) supports the diagnosis of a diffuse dysfunction: hepatic encephalopathy shows a specific triphasic slow wave configuration.
- CT scan – if the above tests are normal or coexisting structural brain disease is suspected.

Calculation of the *anion gap* may be helpful in the diagnosis of encephalopathies, especially *lactic acidosis*. The sum of the anions (Cl^- and HCO_3^-) normally equals the sum of the cations (Na^+ and K^+). An increase in the gap in the absence of ketones, salicylates and uraemia suggests lactic acidosis.

HYPOXIC ENCEPHALOPATHY

Impaired brain oxygenation results from:

- Reduced arterial oxygen pressure – lung disease.
- Reduced haemoglobin to carry oxygen – anaemia or blood loss.
- Reduced flow of blood containing oxygen (ischaemic hypoxia) – due to reduced cardiac output (with reduced cerebral blood flow).
- Biochemical block of cerebral utilisation of oxygen – rare (e.g. cyanide poisoning).

When cerebral arterial PO_2 falls below 35 mmHg (4.5 kPa), anaerobic metabolism takes over; this is not efficient and a further drop in PO_2 will result in neurological dysfunction. The extent of hypoxic damage depends not only upon the duration of hypoxia but also on other factors, e.g. body temperature – hypothermia protects against damage. The irreversibility of hypoxic damage is explained by the 'no flow phenomenon' – after 3–5 minutes the endothelial lining of small vessels swells – even with reversal of hypoxia, flow through these vessels is no longer possible.

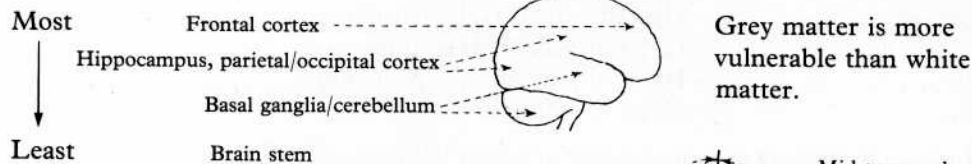
SPECIFIC ENCEPHALOPATHIES

HYPOXIC ENCEPHALOPATHY (contd)

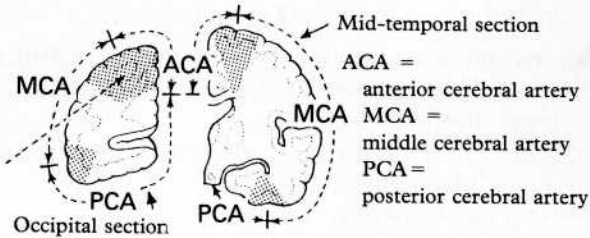
Pathology

As a consequence of high metabolic demand, some areas are more susceptible than others.

Vulnerability to hypoxia



Damage begins in the 'watershed' areas – at the extremes of their blood supply, e.g. between the anterior cerebral and middle cerebral artery territory.



Microscopic changes depend upon the delay between the hypoxic event and death.

Immediate:

Scattered petechial haemorrhages.

At 48 hours:

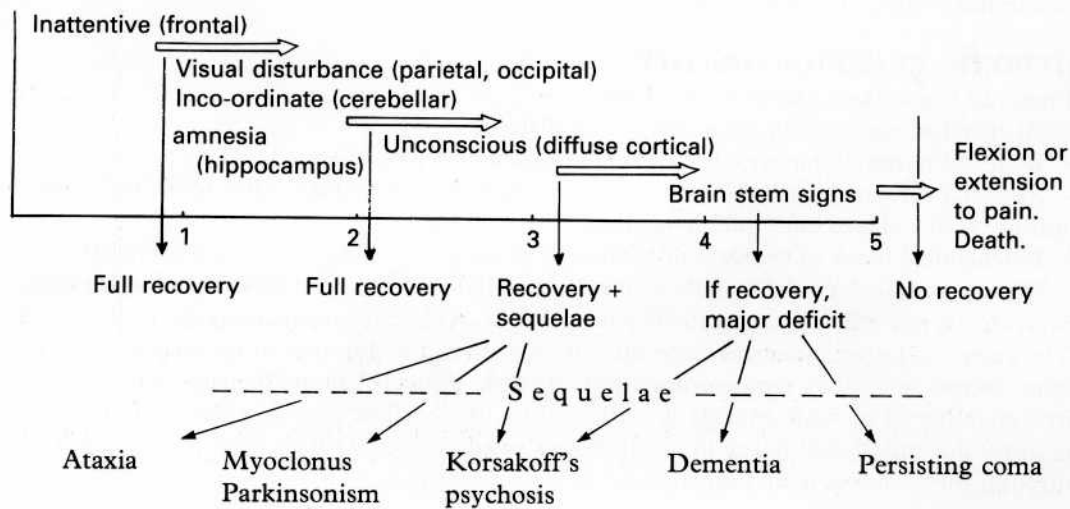
Cerebral oedema associated with petechial haemorrhage.

At several days/weeks:

Necrosis in cortical grey matter and globus pallidus with associated astrocytic proliferation. The cerebellum and brain stem may also be affected.

Clinical features:

e.g. Severe hypoxia from circulatory arrest



Delayed hypoxic encephalopathy refers to the rare occurrence of a full clinical recovery followed after some weeks by a progressive picture → deterioration of conscious level → death. Widespread subcortical demyelination is found at autopsy.

SPECIFIC ENCEPHALOPATHIES

HYPERCAPNOEIC ENCEPHALOPATHY: the consequence of an elevated arterial carbon dioxide level.

Clinical features:

Headache, confusion, disorientation, involuntary movements.
Papilloedema, depressed limb reflexes, extensor plantar responses.

Diagnosis:

A P_{CO_2} greater than 50 mmHg (6 kPa) with a reduced PO_2 is found on arterial blood sampling.

The presence of headache, confusion and papilloedema may suggest intracranial tumour. If hypercapnia has not been diagnosed, such patients inevitably are referred for CT brain scan.

HYPOGLYCAEMIC ENCEPHALOPATHY: the consequence of insufficient glucose reaching the brain and may result from: – overdosage of diabetic treatment

- insulin secreting tumour – insulinoma
- hepatic disease with reduction of liver glycogen.

Serum glucose levels of 1.5 mmol/l are associated with the onset of encephalopathy. Levels at 0.5 mmol/l are associated with coma.

Pathology:

Changes occur in the cerebral cortex – focal necrosis surrounded by neuronal degeneration. Subcortical grey matter (caudate nucleus) and cerebellum are vulnerable.

Clinical features:

These, as with hypoxia, depend upon the duration and severity of hypoglycaemia.

Minor symptoms

Sweating, pallor, headache, palpitation, trembling, hunger, (symptoms of sympathetic overactivity)

↓
Full recovery

Moderate

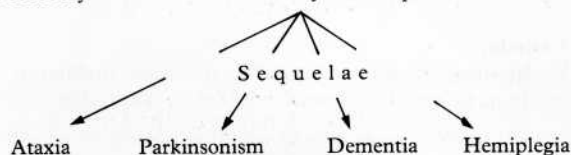
Abnormal behaviour, confusion, unsteadiness, drowsiness

↓
Full recovery

Severe

Hemiparesis, muscle spasms, myoclonus deepening coma

↓
Recovery with sequelae



Repeated mild to moderate episodes may result in a chronic cerebellar ataxia.

Repeated severe attacks may result in a mixed myelopathy/peripheral neuropathy which is distinguished from motor neuron disease by the presence of sensory signs.

HYPERGLYCAEMIC ENCEPHALOPATHY

Two types of encephalopathy develop as a consequence of hyperglycaemia:

Diabetic ketoacidotic coma

Accumulation of acetone and ketone bodies in blood results in acidosis. Hyperventilation ensues with a reduction in P_{CO_2} and HCO_3^- . Osmotic diuresis due to hyperglycaemia results in dehydration.

The neurological presentation is that of confusion progression to coma and, if untreated, death.

Diabetic hyperosmolar non-ketotic coma

This results from the hyperosmolar effect of severe hyperglycaemia. Reduction of the intracellular compartment results. Involuntary movements, seizures and hemiparesis may occur. Vascular thrombosis is not uncommon. Ketoacidosis is mild or does not occur.

SPECIFIC ENCEPHALOPATHIES


HEPATIC ENCEPHALOPATHY

Neurological signs and symptoms secondary to hepatic dysfunction may arise in:

- acute liver failure.
- chronic liver failure complicated by infection or gastrointestinal haemorrhage.
- chronic liver failure producing characteristic *hepatocerebral degeneration*.

Clinical features:

These may be divided into two groups:



The encephalopathy is progressive.

Pathology

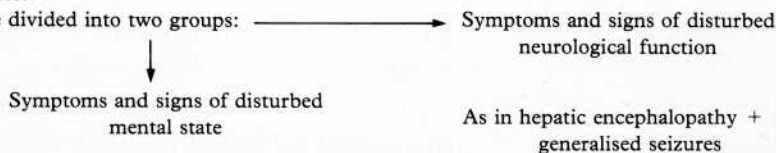
Neuronal loss with gliosis is noted in the cerebral cortex as well as basal ganglia, cerebellum and brain stem. Astrocytes with irregular and enlarged nuclei are characteristic.

Hepatocerebral degeneration produces varying symptoms and signs. Dementia is associated with dysarthria and ataxia. Primitive reflexes, choreoathetosis, myoclonus, tremor and pyramidal signs may also be present. Consciousness is *not* impaired.

URAEMIC ENCEPHALOPATHY

Clinical features:

These may be divided into two groups:



Pathology:

Uraemia may produce non-specific pathological findings in the nervous system. Peripheral nervous system involvement occurs in chronic renal failure (page 421).

Dialysis encephalopathy is encountered in persons on renal dialysis exposed to high aluminium levels in the dialysate. The features are those of dementia, behavioural changes, seizures and myoclonus. The condition progresses unless aluminium levels are controlled.

Specific investigations and treatment of individual metabolic encephalopathies do not come within the scope of this book.

NUTRITIONAL DISORDERS

INTRODUCTION

Nutritional deficiency presents a major problem in the developing world. In Western countries, alcoholism is the major cause of the neurological syndromes resulting from dietary deficiency with faddism and malabsorption disorders accounting for only a small number.

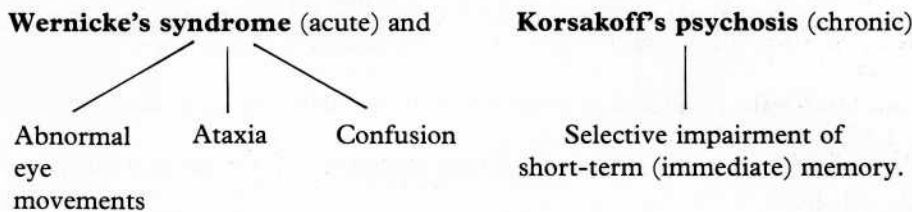
Vitamins appear important nutrients and certain disorders such as Wernicke Korsakoff syndrome (thiamine) or subacute combined degeneration (vit. B₁₂) are attributed to a single deficiency. Others such as polyneuropathy result from multiple deficiency.

Vitamin deficiency in itself does not always produce symptoms; a dietary excess of carbohydrate seems essential for the development of the neurological features of thiamine deficiency.

As a rule, nutritional disorders of the nervous system present clinically in a symmetrical manner.

WERNICKE KORSAKOFF SYNDROME

This syndrome is comprised of an acute and a chronic phase:



Patients often demonstrate additional features of nutritional deficiency – peripheral neuropathy, trophic skin changes and autonomic dysfunction (arrhythmias, postural hypotension and hypothermia).

Cause

Thiamine deficiency arising from poor nutrition. Thiamine is an important coenzyme in the Krebs' cycle. Deficiency results in reduced cerebral metabolism, axonal conduction, synaptic transmission and DNA synthesis.

- Chronic alcoholism
- Hyperemesis
- Carcinoma
- Renal dialysis
- Anorexia nervosa

N.B. Korsakoff's psychosis may also be caused by head injury, anoxia, epilepsy, encephalitis and vascular diseases.

WERNICKE'S SYNDROME

Diagnosed in 0.1–0.4% of hospital admissions

Pathology:

Neuronal, axonal and myelin damage occur symmetrically in the mamillary bodies, the walls of the third ventricle, thalamus and periaqueductal grey matter. Secondary vascular proliferation and haemorrhages occur within these lesions.

WERNICKE KORSAKOFF SYNDROME

WERNICKE'S SYNDROME (contd)

Clinical features: *Acute in onset*

Ocular involvement: -----

Horizontal and vertical nystagmus is evident.

Unilateral or bilateral VI nerve paresis commonly occur.

Gaze palsies are less common.

Retinal haemorrhages occasionally occur.

Pupillary involvement and complete ophthalmoplegia are rare.

Polyneuropathy is present in 80% of cases.

Vestibular disturbances will occur occasionally and accentuate the ataxia.

Autonomic disturbance is common.



Confusion:

Disorientated.

Disinterested and inattentive.

Coma may dominate presentation.

Withdrawal symptoms of alcohol

– agitation, delusions and hallucinations – develop following admission to hospital.

Ataxia – is often the presenting symptom. May be mild or severe with inability to stand.

Lower limb (heel to shin) ataxia is modest.

Upper limbs are spared.

Investigation

Haematological and biochemical evidence of alcohol/nutritional deficiency, e.g. elevated MCV, abnormal LFTs, elevated γ GT.

The erythrocyte *transketolase* (enzyme in hexose monophosphate shunt), an index of thiamine levels, is reduced.

The blood *pyruvate* is elevated. MRI may show mamillary body atrophy.

Treatment

100 mg of thiamine i.v. is given on suspicion of diagnosis. Thereafter daily infusions of 500 mg until a normal diet supplemented by 100 mg thiamine three times per day is tolerated. *Never* give glucose infusions *prior* to thiamine as this may precipitate or aggravate the disorder.

With treatment – Eyes improve – in days, though nystagmus may persist for months.
– Ataxia improves – in weeks.

Overall mortality: 15% → coma → death.

KORSAKOFF'S PSYCHOSIS

When patients survive Wernicke's syndrome up to 80% develop this condition.

Pathology

Lesions are identical in distribution to those of Wernicke's syndrome without haemorrhagic change.

Clinical features

There is a disturbance of memory in which new information cannot be stored. In addition the normal temporal sequence of established memories is disrupted, resulting in a semifictionalised account of the circumstances which the patient may find him/herself in (*confabulation*). This memory disturbance can only be tested for when the confusion of Wernicke's disease has cleared.

Treatment

Oral thiamine 100 t.d.s. should be continued for some months, although only 20% of patients show improved memory function.

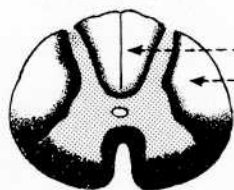
SUBACUTE COMBINED DEGENERATION OF THE SPINAL CORD

This 'selective' disorder of the spinal cord results from B₁₂ vitamin deficiency

Causes

- Impaired absorption due to lack of intrinsic factor (idiopathic)
- Following total or partial gastrectomy or gastrojejunostomy
- Gastric malignancy
- Coeliac disease
- Chronic pancreatic insufficiency

Pathology



Spinal cord demyelination with eventual axon loss – affects: posterior columns and lateral columns (corticospinal and spinocerebellar tracts). Corticospinal degeneration is most evident in the lower cord, posterior column degeneration in the upper cord. Peripheral nerve large myelinated fibre degeneration also occurs.

B₁₂ deficiency resulting in neurological damage is usually associated with a *megaloblastic anaemia*, though a normal peripheral blood film may be found.

Vitamin B₁₂ deficiency results in the formation and accumulation of abnormal fatty acids with defective choline and phospholipids within the nervous system.

Clinical features

Onset is subacute

Paraesthesia of extremities is the presenting symptom.

Numbness and distal weakness follow.

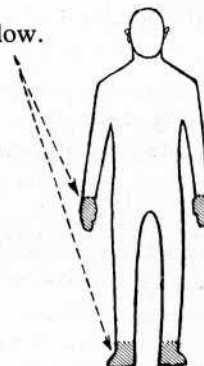
Walking becomes unsteady and spasticity is evident in the lower limbs with flexor or extensor spasms. More widespread neurological features including optic atrophy, cerebral demyelination with encephalopathy and dementia develop in untreated cases.

Examination

- Gait is ataxic with positive Romberg's test (sensory ataxia).
- Motor power is diminished distally.
- Plantar responses are extensor.
- Sensory loss: loss of vibration and joint position sensation in the lower limbs. Stocking/glove sensory loss is found when peripheral nerves are involved.
- Reflex findings are variable and depend on the predominance of peripheral nerve or corticospinal tract involvement.

Mini mental function test may suggest dementia.

Optic pallor and centrocaecal scotoma can be demonstrated.



SUBACUTE COMBINED DEGENERATION OF THE SPINAL CORD

Diagnosis

Suspect in paraparesis with combined upper and lower motor neuron signs with 'stocking/glove' sensory loss.

Differentiate from other causes of acute myelopathy, e.g. cord compression, multiple sclerosis.

Investigation

Peripheral blood film – megaloblastic anaemia

B₁₂ (serum) low – less than 100 pg/ml.

Bone marrow – megaloblastic erythropoiesis.

Investigation of underlying causes of B₁₂ deficiency is essential:

- Radioactive B₁₂ absorption tests.
- Endoscopy and biopsy.
- Barium meal and follow through.
- Investigation of small intestine function.

MRI may show high signal changes on T2 weight images of the spinal cord.

Treatment

When neurological dysfunction is present vit. B₁₂ therapy must be started promptly – 1000 µg cyanocobalamin daily for several weeks and monthly thereafter.

Course and progression

Untreated, the disorder is progressive, the patient eventually becoming bed-bound and comatose. If diagnosed and treated early (within 2 months of onset), complete recovery can be anticipated. In established cases, only progression may be halted.

Caution:

When folic acid is prescribed for megaloblastic anaemia, it will improve the haematological picture of B₁₂ deficiency but causes rapid and occasionally irreversible deterioration of the neurological symptoms and signs.

Calciferol (vit. D)

This vitamin is involved in muscle metabolism. Deficiency results in fatigue, muscle weakness and atrophy. These neurological features are associated with hypocalcaemia and osteomalacia.

Tocopherol (vit. E).

In its active form – D α tocopherol – it acts as a membrane stabilizer and anti-oxidant. Deficiency occurs in chronic fat malabsorption (e.g. coeliac disease or cystic fibrosis) and results in widespread neurological disturbances – ataxia, ophthalmoplegia, seizures and corticospinal tract dysfunction. These are halted and often reversed by i.m. vit. E. It has been speculated that the antioxidant effect might make vitamin E a candidate for cytoprotection and repair within the nervous system. Studies in Parkinson's disease, multiple sclerosis and stroke are disappointing.

NUTRITIONAL POLYNEUROPATHY

Deficiency of vitamin B complex – B₁ (Thiamine), B₂ (Riboflavin), B₃ (Nicotinic acid), B₅ (Pantathenic acid) or B₆ (Pyridoxine) – results in peripheral nerve damage.

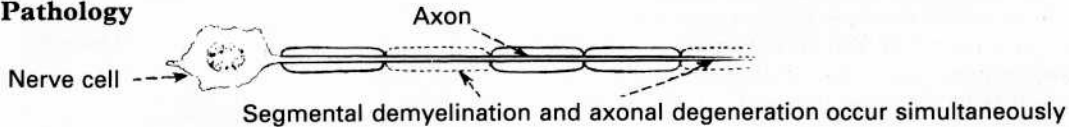
The combination of polyneuropathy and cardiac involvement is referred to as BERI-BERI.

When oedema is also present it is termed wet beri-beri and, when absent, dry beri-beri.

Beri-beri occurs in rice eating countries.

In Western countries, alcoholism is the major cause of nutritional polyneuropathy with or without cardiac involvement, otherwise world wide famine and starvation is responsible.

Pathology



The distal portions of nerves are initially affected.

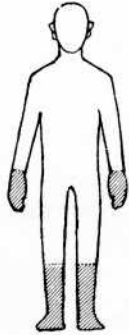
Anterior horn cells and dorsal root ganglion cells undergo chromatolysis.

Vagus nerve and sympathetic trunk involvement occurs in severe cases.

Clinical features *Symptoms:* Progressive distal weakness and sensory loss with painful tingling paraesthesia involving initially lower limbs.

Onset: gradual

Autonomic complaints – impotence, dizziness (orthostatic hypotension) and disordered sweating – are common.



Signs:

- Varying degrees of *areflexia* (only ankle reflexes are lost initially).
- *Weakness* which is more marked distally than proximally and initially involves the lower limbs.
- *Sensory loss* of a 'stocking/glove' type involving all modalities of sensation.
- *Autonomic* involvement results in sweating soles of feet and postural blood pressure drop.
- *Vagus nerve* involvement results in a hoarse voice and disturbance of swallowing.

Associated signs

Shiny skin on legs with poor distal hair growth. 'Hyperpathic' painful soles of feet.

Evidence of liver failure.

Diagnosis

Suggested by nutritional/alcohol history.

Supported by investigations such as peripheral blood film (elevated MCV) and disturbed liver function tests.

Nerve conduction studies reveal mildly reduced motor and sensory conduction velocities.

Differential diagnosis

Consider other causes of subacute or chronic sensorimotor neuropathy (see page 420).

Treatment

A high calorie (3,000) diet should be supplemented daily with Thiamine (25 mg), Niacin (100 mg), Riboflavin (10 mg), Pantathenic acid (10 mg) and Pyridoxin (5 mg).

Burning paraesthesia may respond to carbamazepine or phenytoin.

Recovery may be very slow and incomplete but with the withdrawal of alcohol and adequate vitamin supplementation some improvement should occur.

TOBACCO-ALCOHOL AMBLYOPIA

A large number of toxic substances can produce impaired vision. Methyl alcohol causes sudden and permanent blindness. Chronic visual loss from optic neuritis develops in malnourished patients with a high tobacco consumption (Tobacco-alcohol amblyopia). The mechanism producing this disorder is uncertain, tobacco contains cyanide which in high dosage can damage the optic nerves.

Pathology

Damage involves the papillomacular bundle within the optic nerves, chiasma and optic tracts. Retinal ganglion cells in the macular region are also affected.

Clinical features

- The condition slowly develops over weeks.
- Vision in each eye becomes hazy and blurred.
- Colour vision (red/green discrimination) is involved early.

Examination

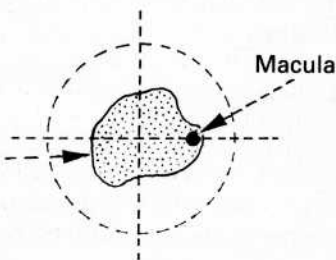
- Bilateral involvement.
- Reduced visual acuity.
- Centrocaecal scotoma

(a central field defect spreading from blind spot to macula and most easily detected with a red target).

- Fundal examination is normal, though optic atrophy will occur eventually.
- Coexistent Wernicke Korsakoff syndrome or polyneuropathy are common.

Treatment

Vitamin B supplementation, including B₁₂, should be administered. B₁₂ possesses the capacity for cyanide detoxification. Recovery is poor if visual loss is well established.



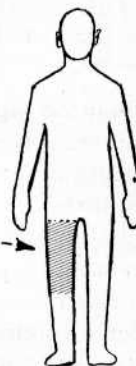
ALCOHOL RELATED DISORDERS

ALCOHOLIC MYOPATHY

Muscle damage (elevated creatine phosphokinase) is not uncommon in alcoholics following acute ingestion, but this is rarely symptomatic.

Acute necrotizing myopathy occurs after 'binge' drinking.

- Acute muscle necrosis ensues with pain/cramping and muscle tenderness/swelling.
- Myoglobin is excreted in the urine (myoglobinuria) after release from damaged muscles.
- Symptoms of alcohol withdrawal - delirium, etc. - coexist.
- Limb involvement may be markedly asymmetrical.
- Sometimes calf muscles are swollen and tender.
- Improvement occurs over weeks to months.
- Serum creatine phosphokinase (CPK) is elevated. Marked myoglobinuria when present may result in renal failure.
- Elevated serum K⁺ may provoke cardiac arrhythmias.



Aetiology appears due to the direct toxic effect of alcohol on muscle.

Chronic proximal myopathy has been described, but is relatively rare.

ALCOHOL RELATED DISORDERS

ALCOHOLIC DEMENTIA

Experimentally, chronic alcohol consumption results in neuronal loss. CT evidence of atrophy and neuropsychological impairment is common in alcoholics. However, whether or not these result from the direct toxic and dementing effect of alcohol remains uncertain.

ALCOHOLIC CEREBELLAR DEGENERATION

Probably the commonest cause of acquired ataxia, alcoholic patients may develop a chronic cerebellar syndrome either as a sequel of Wernicke's syndrome or as a distinct clinical entity.

A long history of alcohol abuse is obtained. Males are predominantly affected.

Onset is gradual and symptoms often stabilise.

Ataxia of gait with lower limb inco-ordination predominates. The upper limbs are spared.

Nystagmus is rarely present. Cerebellar dysarthria is usually mild.

Coexistent signs of peripheral neuropathy are often found.

Investigations: – Abnormal liver function tests e.g. elevation of enzymes – γ GT.
 – Macrocytosis in peripheral blood film.
 – CSF examination normal.
 – CT and MRI reveal cerebellar vermal atrophy.

Progression → may evolve rapidly and reverse with improved nutrition and alcohol withdrawal.
 → may evolve subacutely.
 → may evolve chronically and slowly progress over many years.

Pathology: – Purkinje cell loss in cerebellar hemispheres and in superior cerebellar vermis.

Pathogenesis: – The disorder may be due to *nutritional deficiency*, especially thiamine, or else result from the direct toxic effect of alcohol or electrolyte disturbance on the cerebellum.

Differential diagnosis: – Distinguish from hereditary and other acquired ataxias, e.g. hypothyroidism, remote effects of carcinoma.

Treatment: – Alcohol withdrawal, a well balanced diet and adequate vitamin supplementation.

CENTRAL PONTINE MYELINOLYSIS

Alcohol abuse, debilitating disease or rapid correction of hyponatraemia may precipitate presentation.

The lesion is one of demyelination with cavitation. Microscopically, myelin is lost, oligodendrocytes degenerate but neurons and axons are spared.

Clinically, an acute or subacute pontine lesion is suspected, evolving over a few days, with bulbar weakness and tetraparesis. (locked-in syndrome).

The limbs are flaccid with extensor plantar responses.

With progression of the lesion, eye signs become evident and conscious level becomes depressed → coma → death.

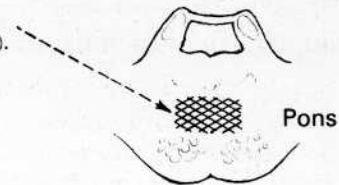
Investigations:

Electrolytic disturbances (low sodium, low phosphate) are found.

Liver function is normal. CSF examination is normal.

MRI is more sensitive than CT showing an abnormality in the pons.

Recognition of this condition before death is important in view of its reversibility, though prior to CT/MRI availability it was diagnosed at autopsy. Vigorous supportive therapy with correction of metabolic abnormalities and vitamin supplementation is advised. In patients with severe hyponatraemia (< 110 mmol/l), especially alcoholics, slow correction is essential.



CORPUS CALLOSUM DEMYELINATION (syn: Marchiafava-Bignami disease)

This is a rare disorder occurring in malnourished alcoholics. Occasionally diagnosed premortum by MRI, progressing to death over some weeks. The clinical picture is that of personality change with signs of frontal lobe disease. The condition occurs most commonly in persons of Italian origin.

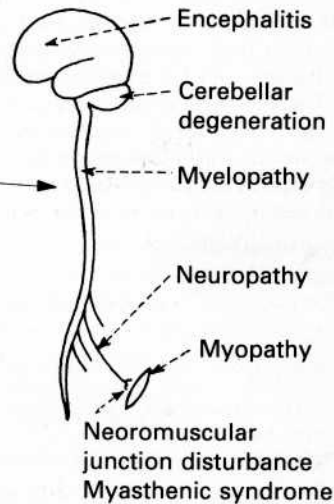
NON-METASTATIC MANIFESTATIONS OF MALIGNANT DISEASE

Disturbance of neurological function can occur in association with malignancy without evidence of metastases (0.1% of all cancer patients). Brain, spinal cord, peripheral nerve and muscle may be affected, either separately or in combination.

Small cell carcinoma of the lung, gynaecological malignancy and lymphoma are the commonest associated disorders. These syndromes are antibody-mediated, the targeted antigen being a part of the nervous system. Specific antibodies, (anti-neuronal), are responsible for certain syndromes.

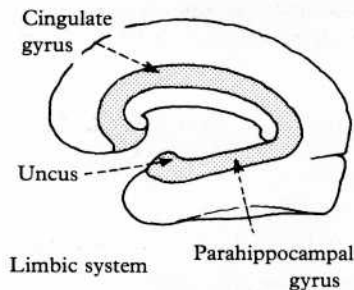
The non-metastatic manifestations of malignancy are rare.

These are not discreet, e.g. neuropathy and myopathy may coexist → carcinomatous neuromyopathy; encephalitis and myelopathy → carcinomatous encephalomyelitis.



ENCEPHALITIS (anti-Hu syndrome)

Associated commonly with small cell lung cancer (SCLC) usually *before* this becomes clinically manifest.



Pathology

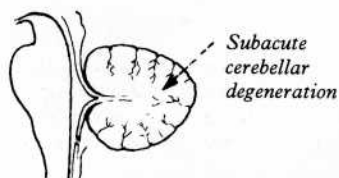
The encephalitic process selectively affects the limbic system – with neuronal loss, astrocytic proliferation and perivascular inflammatory changes.

Clinical features

Disturbance in behaviour precedes the development of complex partial (temporal lobe) seizures and memory impairment. Autonomic dysfunction and sensory neuropathy often co-exist. Progression is rapid.

Investigations. Most cases are anti-Hu antibody positive. MRI is normal. EEG may show temporal lobe abnormalities. CSF reveals a mild lymphocytosis with protein elevation.

CEREBELLAR DEGENERATION (anti-Yo syndrome) associated with breast or ovarian carcinoma.



Pathology:

Characterised by Purkinje cell loss with some involvement of the dentate nucleus. Brain stem changes also occur.

Clinical features:

The patient presents with a rapidly developing ataxia. Brain stem involvement results in nystagmus, opsiclonus and vertigo. The course is usually rapid.

Investigations

MRI shows cortical and vermal cerebellar atrophy. CSF is mildly abnormal and anti-Yo antibodies are present in 50% of suspected cases.

NON-METASTATIC MANIFESTATIONS OF MALIGNANT DISEASE

NEUROPATHY (see page 427)

Sensory neuropathy: Destruction of the posterior root ganglion combined with axonal and demyelinating peripheral nerve damage causes progressive sensory symptoms. The neuropathy is subacute or chronic in evolution. Clinically dysaesthesia and numbness starts in extremities and spreads. Associated with SCLC and anti-Hu antibodies.

Sensorimotor neuropathy: A mixed neuropathy with weakness and sensory loss. The syndrome may predate the recognition of the underlying neoplasm. Rate of progression is slow and predominantly motor forms may be mistaken for ALS (page 535) associated with Hodgkin's and other lymphomas.

Rarely an acute neuropathy indistinguishable from postinfectious polyneuropathy occurs.

NECROTISING MYELOPATHY:

Flaccid paraplegia develops subacutely. Spinal MRI may show a swollen cord. Mechanism is uncertain. Associated with lymphoma and leukaemia.

MYOPATHY

Muscle weakness in malignancy takes several forms.

Proximal myopathy: A slowly progressive syndrome with weakness of proximal limb muscles.

Inflammatory myopathy (polymyositis/dermatomyositis) (see page 456):

The overall incidence of associated neoplasm in inflammatory myopathy is 15%. The typical patient is in middle age with a proximal weakness, elevated ESR and muscle enzymes with or without the skin features of dermatomyositis.

Myopathy with endocrine disturbance: Ectopic hormone production (by malignant cells) may induce a myopathy characterised by chronic progressive proximal weakness, e.g. ectopic ACTH production from small cell carcinoma of lung.

Cachetic myopathy occurs in terminally ill, wasted patients.

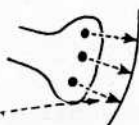
In all suspected non-metastatic syndromes, a search for the causal tumour is essential (pelvic CT/ultrasound, CT chest/bronchoscopy). Identification and treatment may result in regression of neurological symptoms.

Specific treatments

Apart from direct treatment of the tumour, immunotherapy – steroids, IVIG, cyclophosphamide, plasmapheresis have all been tried in deteriorating patients with variable success.

THE MYASTHENIC SYNDROME (Eaton-Lambert syndrome)

A disorder of the neuromuscular junction in which antibodies develop against Ca^{2+} channels on the presynaptic membrane.



Acetylcholine release following nerve stimulation is deficient.

This autoimmune disease is occasionally associated with malignancy.

Clinical features

The patient develops weakness of lower than upper limbs with a tendency to fatigue. Following brief exercise, power may paradoxically suddenly improve – second wind phenomenon. In contrast to myasthenia gravis ocular and bulbar muscles are rarely affected. Examination reveals a proximal pattern of wasting and weakness with diminished tendon reflexes. Up to 50% of patients experience symptoms of autonomic (cholinergic) dysfunction – impotence, dry mouth and visual disturbance.

Diagnosis

Confirmed electrophysiologically; the 'second wind phenomenon' is shown up as an incrementing response to repetitive nerve stimulation (as opposed to the decrementing response in myasthenia gravis, page 463). Antibodies to Ca^{2+} gated channels are detected in serum.

Treatment

Guanidine hydrochloride and 4-aminopyridine enhance acetylcholine release by acting on calcium and potassium channels. These treatments are effective but toxic. 3, 4-diaminopyridine (less toxic), steroids, anticholinesterases, plasmapheresis or IVIG may help.

This syndrome may respond to the removal of the underlying neoplasm if present.

DEGENERATIVE DISORDERS

Introduction

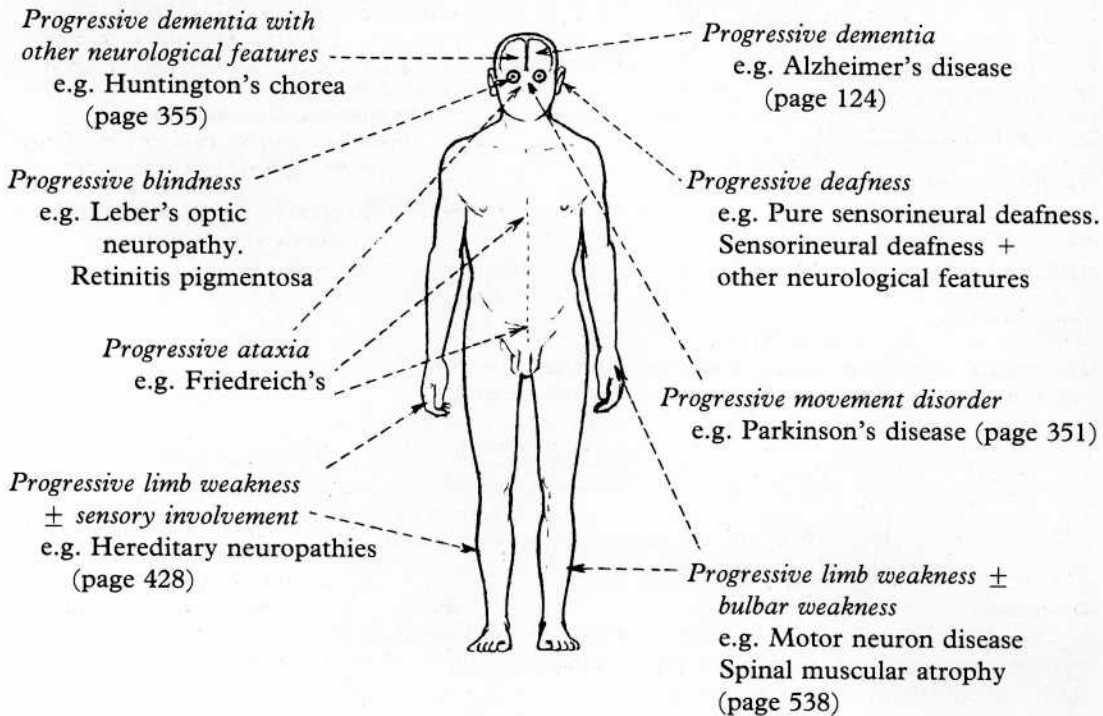
This heterogeneous group of neurological diseases characterised by selective neuronal loss, is grouped together by the lack of known aetiology. As causes of such disease are identified (e.g. metabolic, viral) they have been reclassified in their appropriate category. Of the remaining conditions many are age related or familial and in some there is an identifiable genetic basis.

Characteristically these disorders:

- are gradually progressive
- are symmetrical (bilateral symptoms and signs)
- may affect one or several specific systems of the nervous system
- may demonstrate a specific pathology or just show neuronal atrophy and eventual loss without other features.

Classification

Degenerative disorders are classified according to the specific part or parts of the central/peripheral nervous system affected and according to the ensuing clinical manifestations. These degenerative disorders may be alternatively termed the *system degenerations* because of their propensity to affect only part of the nervous system.



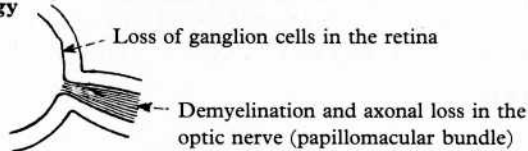
Most of these conditions are discussed in other chapters.

PROGRESSIVE BLINDNESS

LEBER'S OPTIC NEUROPATHY

Leber's optic neuropathy is a familial disorder of maternal inheritance with a tendency to affect males significantly more than females. It is classified as a mitochondrial disorder due to DNA mutation (page 503).

Pathology



Clinical features

Onset of visual loss in late teens/early twenties.

- The first symptom is blurring of vision
- Both eyes are simultaneously affected (rarely one eye months before the other).
- Central vision is lost with large bilateral scotomata.

Characteristically, blue/yellow colour discrimination is affected before red/green. The optic disc initially appears pink and swollen with an increase in small vessels, eventually becoming pale and atrophic.

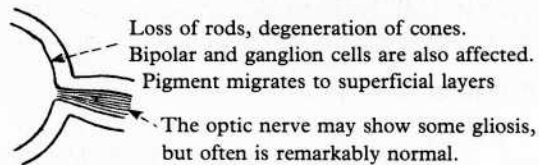
Visual impairment progresses with peripheral constriction of the fields. Complete visual loss seldom occurs. Occasionally vision can marginally improve.

Associated symptoms and signs of a more generalised nervous system disorder occur in a proportion of cases – dementia, ataxia, progressive spastic paraplegia – and confusion with multiple sclerosis may arise. Diagnosis is based on family history. In contrast to bilateral optic neuritis, 'leakage' occurs with fluorescein angiography. Several mitochondrial DNA mutations are detected in the peripheral blood.

Treatment: No treatment is effective.

RETINITIS PIGMENTOSA

A hereditary disorder of the retina which may be inherited as an autosomal dominant, recessive or X-linked disorder. All layers of the retina are affected. Posterior pole cataracts and glaucoma are occasionally associated.



Clinical features

Onset of visual loss in childhood. Both eyes are simultaneously affected. Initially there is a failure of twilight vision. The patient has difficulty in making his/her way as darkness falls (nyctalopia). The retina around the macular area is first affected resulting in a characteristic ring scotoma. This gradually spreads outwards; eventually only a small 'tunnel' of central vision is left. Finally, complete blindness occurs. The majority of patients are completely blind by 50 years of age.

The fundal appearance is diagnostic as a result of the superficial migration of pigment.

The *electroretinogram* – recording the electrical activity of the retina – is eventually lost.

Treatment

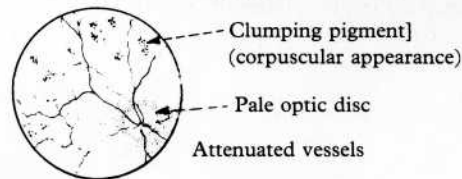
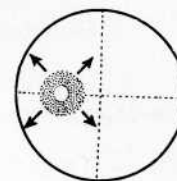
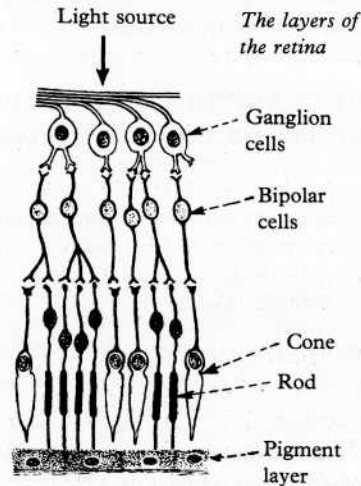
None. Vitamins and steroids have been tried unsuccessfully.

Associated conditions in retinitis pigmentosa

Several conditions are associated with retinitis pigmentosa:

- Hypogonadism/obesity/mental deficiency
- Laurence Moon syndrome
- Spinocerebellar ataxia
- Friedreich's ataxia

The association with neuropathy and ataxia (NARP), or progressive external ophthalmoplegia and heart block (Kearns-Sayre syndrome) are due to mitochondrial disease (page 462)



PROGRESSIVE ATAXIA

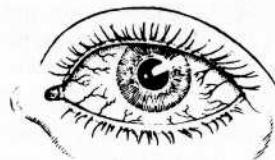
The degenerative disorders manifested by progressive ataxia are termed *spinocerebellar-ataxias*

These may be classified by age of onset, presence of associated features, but increasingly by mode of inheritance.

RECESSIVELY INHERITED ATAXIAS

ATAXIA TELANGIECTASIA (Louis-Bar Syndrome)

This multisystem disorder is characterised by progressive cerebellar ataxia, ocular and cutaneous telangiectasia and immunodeficiency. The gene defect has been localised to chromosome 11.



Pathologically, widespread cerebellar Purkinje and granular cell loss occurs.

A progressive ataxia develops in infancy. Telangiectasia develops later, becoming more obvious after exposure to the sun. Prevalence similar to Friedreich's ataxia.

Patients are eventually confined to a wheelchair and, because of associated low serum immunoglobulin levels are susceptible to repetitive infections.

Malignant neoplasms occur in 10%.

Giving radiotherapy for these tumours causes an increased incidence of chromosomal breakage and rearrangement, suggesting defective DNA repair mechanisms.

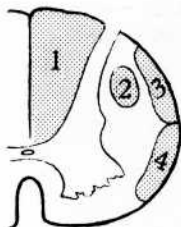
Death occurs in second or third decade from infection or malignancy (often lymphoma).

FRIEDRICH'S ATAXIA

Prevalence: 2 per 100 000 persons.

The responsible gene has been localised to chromosome 9. The spectrum of abnormalities relating to the gene locus is wide but ataxia, areflexia, dysarthria and decreased proprioception are present in all cases.

Pathology:



Spinal: The spinal cord is shrunken, especially in the thoracic region.

There is degeneration, demyelination and gliosis of:

1. - Posterior columns
2. - Corticospinal tracts
3. - Dorsal spinocerebellar tracts
4. - Ventral spinocerebellar tracts.

Dorsal roots and peripheral nerves are shrunken in advanced cases.

Cerebellar: Changes in the cerebellum are less marked, there is Purkinje cell loss and atrophy of the dentate nucleus.

Peripheral nerves show loss of large myelinated axons and segmental demyelination. The corticobulbar tract and cerebrum are relatively spared.

RECESSIVELY INHERITED ATAXIA

FRIEDREICH'S ATAXIA (*contd*)

Clinical features

Sexes are equally affected. Age of onset ranges from 5 to 20 years.

Disturbance of balance is the initial symptom, often associated with the development of scoliosis. A spastic, ataxic gait develops with inco-ordination of the limbs.

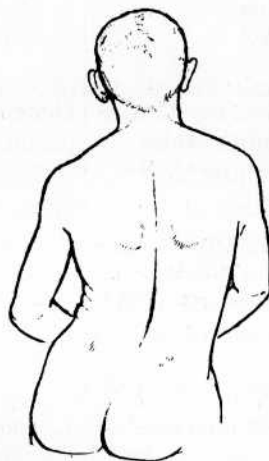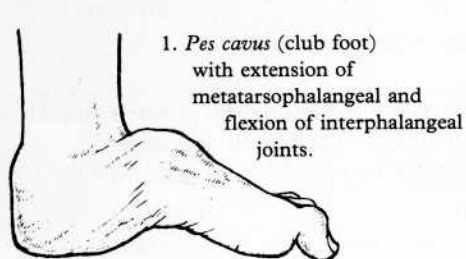
Corticospinal tract involvement results in limb weakness with absent abdominal reflexes and extensor plantar responses.

Posterior column involvement results in loss of vibration and proprioception in the extremities.

Dorsal root and peripheral nerve involvement results in absent lower limb reflexes.

Involvement of myocardial muscle (cardiomyopathy) is common and results in cardiac failure or dysrhythmias.

Musculoskeletal abnormalities occur in 80% of cases.



Optic atrophy, deafness and diabetes coexist in many cases.

The disease is progressive. Patients are usually unable to walk within 5 years of onset, and death from cardiac (cardiomyopathy) or pulmonary (kyphoscoliosis) complications occurs within 10–20 years. Mild forms with near-normal life expectancy occur.

Diagnosis

This is made on clinical grounds, usually with a known family history and by excluding other causes of early-onset areflexic ataxia.

Abetalipoproteinaemia (Bassen Kornzweig disease)

- Malabsorption syndrome
- Acanthocytes (thorn-shaped red blood cells)
- Low serum cholesterol, triglycerides and fatty acids.

Hexosaminidase deficiency

- Accumulation of GM₂ gangliosides in brain and skin.

Vitamin E deficiency

- Undetectable serum vit E levels.

Xeroderma pigmentosum

- Sensitive to ultraviolet light
- Keratosis and skin cancer.

DOMINANTLY INHERITED AND OTHER ATAXIAS

Adult onset disorders. Previous classification was clinically based. Now, increasingly 'gene-locus' syndromes have been defined.

	Autosomal dominant Cerebellar ataxia (ADCA) Type 1	Autosomal dominant Cerebellar ataxia (ADCA) Type 2	Autosomal dominant Cerebellar ataxia (ADCA) Type 3
Clinical Features	Ataxia ± Ophthalmoplegia Mild dementia Optic atrophy Spasticity	Ataxia + Retinopathy (progressive visual loss) ± Dementia – extrapyramidal features	Ataxia (alone) – Age of onset > 50 years
Genetic Basis	Chromosome 6 – expanded trinucleotide repeat (CAG similar to Huntington's disease) termed Spinocerebellar ataxia locus – 1 – SCA I also Chromosome 12–SCA 2 Chromosome 14–SCA 3	Gene mutation, probably unstable trinucleotide repeat – chromosome location unknown	Chromosome II – expanded trinucleotide repeat

IDIOPATHIC LATE ONSET ATAXIA

Some may be new mutations of ADCA. For diagnosis all other causes of acquired ataxia – inflammatory, infective, nutritional, metabolic, endocrine and non-metastatic – must be excluded by appropriate investigations.

Type 1 – Age of onset 35–55 years – ataxia ± dementia, spasticity
Type 2 – Age of onset > 55 years – mid-line ataxia sparing speech/limbs
Type 3 – Age of onset 50–60 years – ataxia, titubation and tremor

INTERMITTENT ATAXIAS

These syndromes have childhood onset and usually a metabolic basis

- e.g. Aminoaciduria – Hartnup's disease
- Hyperammonaemia – Arginase deficiency
- Pyruvate/lactate – Mitochondrial disorders

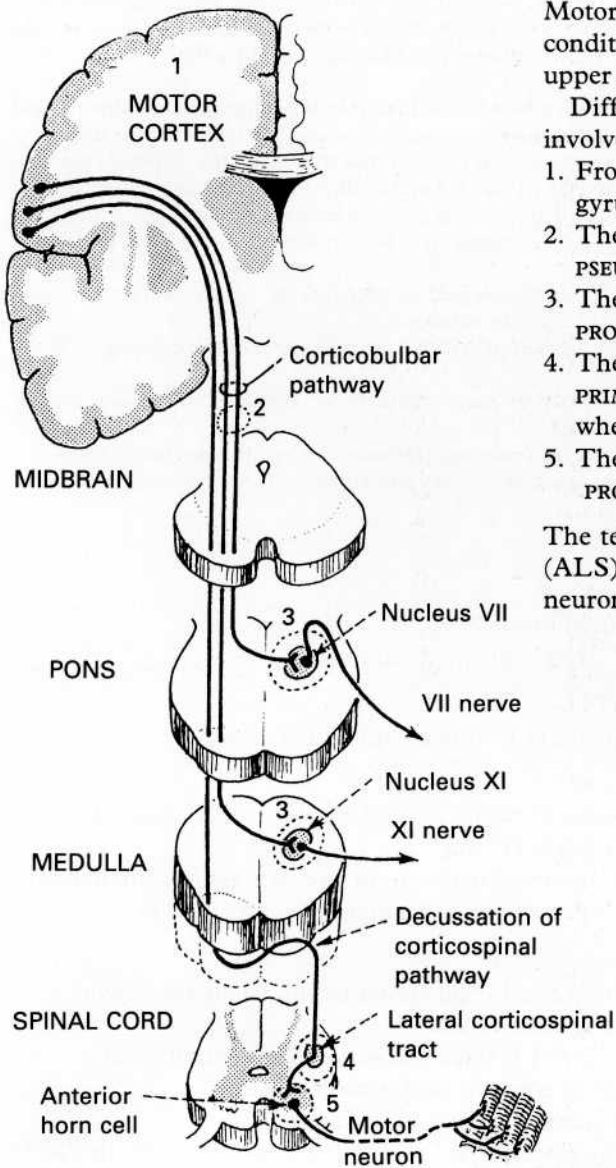
A rare condition – *autosomal dominant periodic ataxia* – presents in childhood with episodic dysarthria/ataxia/vertigo and nystagmus. Mapped to chromosome 9 (similar to familial hemiplegic migraine) and uniquely responsive to the carbonic anhydrase inhibitor, acetazolamide.

PROGRESSIVE SPASTICITY

Autosomal dominant: Onset 20–40 years, predominantly lower limb involvement, power preserved.

Autosomal recessive: Childhood onset. Diagnosis by exhaustive exclusion. Significantly disabling.

MOTOR NEURON DISEASE/AMYOTROPHIC LATERAL SCLEROSIS (ALS)



Motor neuron disease (MND) is a progressive condition characterised by degeneration of upper and lower motor neurons.

Different terms are used to describe involvement at each level:

1. Frontal atrophy in the precentral gyrus – **FRONTAL DEMENTIA**
2. The corticobulbar pathway: **PSEUDOBULBAR PALS**.
3. The cranial nerve nuclei: **PROGRESSIVE BULBAR PALS**.
4. The corticospinal tract: (Called **PRIMARY LATERAL SCLEROSIS** when this tract alone is affected)
5. The anterior horn cell: **PROGRESSIVE MUSCULAR ATROPHY**.

The term **AMYOTROPHIC LATERAL SCLEROSIS (ALS)** is now used synonymously with motor neuron disease.

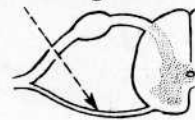
Epidemiology

Incidence: 2 per 100 000 per year, with a prevalence of 6 per 100 000. Clusters and conjugal cases have been reported. Familial ALS accounts for 5% of cases and is usually inherited as a dominant trait. Sex ratio: male/female – 1.5:1 Mean age of onset – 55 years. Mean survival – 3 years (50%), over 5 yrs (28%)

Pathology

Naked eye: Thinning of anterior roots of spinal cord. Most noticeable in cervical and lumbosacral regions.

Microscopic: Loss of neurons in motor cortex.
Loss of neurons in cranial nerve nuclei and anterior horns.
Section of brain stem: reduction of corticobulbar and corticospinal fibres.



No evidence of inflammatory response is seen in involved structures.

MOTOR NEURON DISEASE/ ALS

AETIOLOGY

The cause of motor neuron disease is unknown. Several possibilities have been suggested:

- **Ageing:** Premature ageing in certain motor cells may result in increasing metabolic demand upon survivors. As a consequence the survivors also suffer premature loss. This process could be 'triggered' by genetic and environmental factors.
- **Viruses:** Chronic virus infection has been suggested. Polio virus will acutely damage the anterior horn cell and chronic polio infection could theoretically produce motor neuron disease. Some claim that motor neuron disease follows acute poliomyelitis; however, when this occurs the clinical picture is not typical and may resemble more closely Spinal Muscular Atrophy (see later). Polio antibody titres remain normal. Virus-like particles have been reported in some patients with MND, but transmission to non-human primates has been unsuccessful.
- **Toxins:** Certain metals, lead, selenium, mercury and manganese have been incriminated, but again evidence is inconclusive.
- **Minerals:** Clinical similarities between MND and neurological involvement in hyperparathyroidism and phosphate deficiency suggest a relationship with chronic calcium deficiency.
- **Genetic** - in a proportion of such cases the gene for familial ALS has been localised to chromosome 21 at the locus for the enzyme superoxide dismutase (S.O.D.)
- **Excitotoxins** - excitatory amino acids are implicated in many 'degenerative' disorders. Glutamate may be important in ALS.

An increased incidence of *gastric surgery* in sufferers, the presence of *immune complexes* in small bowel biopsies and disordered *cellular immunity* have been noted but causative relationships are unclear. Antibodies against voltage-gated Ca^{++} channels have been detected.

CLINICAL FEATURES

At onset:

Asymmetric weakness and wasting of extremities - 75%

Bulbar or pseudobulbar features - 25% - dysphagia or dysarthria

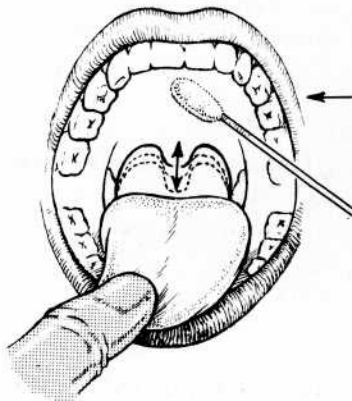
Frontal dementia

This occurs in 3-5% of all patients, but is more prevalent in familial cases.

Pseudobulbar palsy

Features are due to degeneration of corticobulbar pathways to V, VII, X, XI and XII cranial nerve motor nuclei (with sparing of III, IV and VI).

There is an apparent weakness of the muscles of mastication and expression, the patient has difficulty in chewing and the face is expressionless. The jaw jerk (page 15) is exaggerated.



Food and fluid enter nasopharynx when swallowing - palatal weakness (X).

Gag reflex is brisk when soft palate is stimulated.

Speech is drawling and monotonous.

Swallowing for solids is difficult (X).

Tongue is immobile, pointed and cannot protrude (XII).

Emotional lability - unprovoked outbursts of laughing or crying occur.

MOTOR NEURON DISEASE/ALS

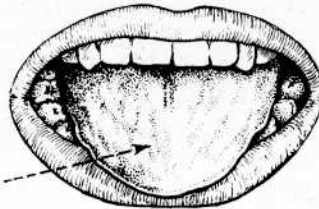
Progressive bulbar palsy

The symptoms and signs are due to a disturbance of the motor cranial nuclei rather than corticobulbar tracts. The condition is distinguished from pseudobulbar palsy by the presence of lower motor neuron (nuclear) signs.

Atrophy and *fasciculations* are present in cranial nerve innervated muscles.

Fasciculations are visible muscle twitches which occur spontaneously and represent groups of discharging motor units.

The tongue appears wasted and folded; fasciculations produce a writhing appearance. Jaw jerk and gag reflex are absent.



Corticospinal involvement

Signs of corticospinal tract disturbance with:

- Increased tone.
- Brisk reflexes.
- Extensor plantar responses.
- Distinctive distribution of weakness (extensors in upper limbs; flexors in lower limbs).

Spasticity is rarely severe (intact extrapyramidal inhibition).

(*Primary lateral sclerosis* is a slowly progressive form of ALS restricted to the cortical spinal tract.)

Progressive muscular atrophy

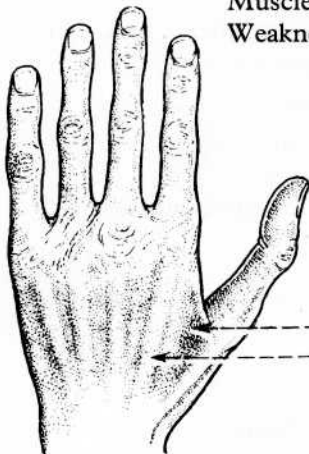
Signs and symptoms are due to anterior horn cell involvement.

Atrophy, weakness and fasciculations are the cardinal features.

The patient is often aware of fasciculation.

Muscle cramps are common.

Weakness is not as severe as the degree of wasting suggests.



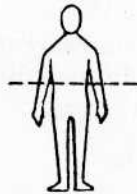
In the hand: wasting is evident.
1st dorsal interosseous muscle and tendons become prominent as hand muscles waste, giving 'guttered' appearance – SKELETON HAND.

As the disease progresses, all levels of the motor system become involved. Respiratory muscle weakness ultimately occurs and is the usual cause of death.

MOTOR NEURON DISEASE/ALS

Differential diagnosis includes disorders which produce combined upper and lower motor neuron signs, e.g.

- Cervical spondylosis*
- Spinal tumours.*



Segmental (LMN signs) weakness

Corticospinal muscle weakness

Hexosaminidase deficiency (autosomal recessive disorder) may mimic ALS.

An ALS like syndrome can occur with *elevated serum paraproteins and lymphoproliferative disease.*

Hyperthyroidism and hyperparathyroidism produce muscle wasting and hyperreflexia.

Pseudobulbar palsy may result also from cerebrovascular disease or multiple sclerosis.

Progressive muscular atrophy may be confused with a spinal muscular atrophy, limb girdle dystrophy, diabetic amyotrophy or lead neuropathy.

- N.B. IN MOTOR NEURON DISEASE:
- *Sensory signs do not occur*
 - *Bladder is never involved*
 - *Ocular muscles are never affected.*

Investigations

EMG reveals denervation with fibrillation.

Nerve conduction studies shows normal velocities and exclude in all limbs multifocal neuropathy with conduction block.

MRI (or myelography) where appropriate excludes foramen magnum or spinal cord compression.

Thyroid and calcium studies exclude endocrine or metabolic disease.

In selected cases screen for paraproteinaemia, lymphoreticular disease and hexosaminidase deficiency.

Diagnostic criteria

- Clinical features*
- UMN signs
 - LMN Signs
 - Absence of sensory signs
 - Progression

- Supported by*
- fasciculations
 - Neurogenic EMG
 - Normal nerve conduction studies
 - exclusion of other cause(s)

TREATMENT

Discuss the diagnosis fully with the patient and carers, and either multidisciplinary support and counselling.

Symptomatic treatment:

Anarthria and dysarthria: - Speech assessment and communication aids when indicated.

Dysphagia and aspiration: - Percutaneous endoscopic gastrostomy (PEG)

Nutrition: - Estimate calorific content and supplement diet with vitamins.

Muscle weakness: - Physiotherapy, walking aids. Splints, etc.

Respiratory failure: - Management poses problems. The role of tracheostomy and assisted ventilation in a disorder that leads eventually to total paralysis is debatable.

Therapeutic trials

There is no proven treatment, nonetheless patients are only too keen to participate in clinical trials. These must always be properly designed and have scientific rationale.

- Recent studies have evaluated:
- Branch chain amino acids
 - Neurotrophic growth factors
 - Immunotherapy
 - Glutamate antagonists (Riluzole) for pseudobulbar presentation

Trials are 'dogged' by the need for placebo controls in a relentless fatal illness.

INHERITED MOTOR NEURON DISORDERS

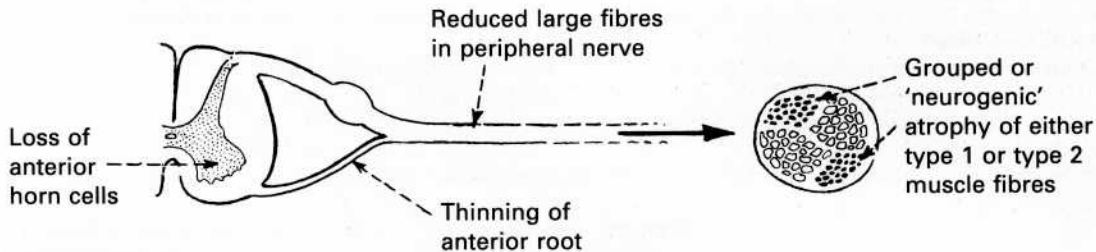
SPINAL MUSCULAR ATROPHIES (SMAs)

A group of anterior horn cell disorders. An estimated 1 in 40 persons carry the SMA gene. Classification relies on age of onset, rate of progression, distribution and mode of inheritance.

Type I – Werdnig Hoffman disease (Acute Infantile SMA)

This is an autosomal recessive disorder.

Incidence 1:25 000 births



Clinical features:

Reduced fetal movements in late pregnancy with weakness and hypotonia at birth.

Swallowing and sucking are impaired

The child lies with arms and legs abducted and externally rotated (hypotonic posture)

Contractures, wasting and fasciculation gradually become evident

} different from other causes of 'floppy' infant.

All motor milestones are delayed; 95% of all patients are dead by 18 months.

Type II – Kugelberg Welander disease (Late infantile or juvenile SMA)

Pathological features similar to Werdnig Hoffman disease.

Autosomal excessive (1:25 000 births) autosomal dominant (1:100 000 births)

Clinical features:

Limb girdle muscles affected.

It is slowly progressive with great variability even within the same family. Median age at death 12 years. Survival to adulthood occurs in the dominant form.

Type III (Adult onset SMA)

Caused by three distinct genes – autosomal dominant, recessive and X linked recessive. Onset between 2nd and 5th decade with progressive limb girdle weakness. Distinction from progressive muscular atrophy form of ALS is difficult. A benign course supports the former.

Distal and scapuloperoneal forms

Differentiation from HMSN types I and II (page 428) and scapuloperoneal dystrophy (page 453) is clinically difficult and separation may only be possible on histological and neurophysiological grounds.

Juvenile bulbar palsy (Kennedy syndrome)

X linked recessive disorder presenting in late childhood with drooling and dysarthria, progressing to aspiration pneumonia and respiratory failure characterised at Xq12 (androgen receptor gene). Limb involvement and pyramidal tract signs can occur. Few patients survive the second decade.

Management of spinal muscular atrophies

There is no specific treatment. Care is supportive. Genetic counselling is essential.

NEUROCUTANEOUS SYNDROMES

Previously called Phakomatoses – Phakos Greek: birthmark

These disorders are hereditary, characterised by multiorgan malformations and tumours. The literature includes many varieties of such conditions; most are extremely rare. Only the more major disorders are described below.

NEUROFIBROMATOSIS

Two distinct types occur:

Type 1 (NF1)

Characterised by café au lait spots and neurofibromas (Von Recklinghausen's disease).

Incidence: 1:4000

Inheritance: Autosomal dominant gene on chromosome 17 with a spontaneous mutation rate of 50%.

Type 2 (NF2)

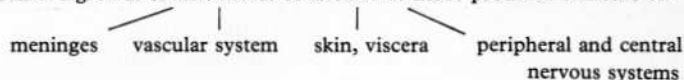
Characterised by tumours (schwannomas) of the eighth cranial nerve (vestibular division).

1:50 000

Autosomal dominant gene on chromosome 22.

Pathology (type 1):

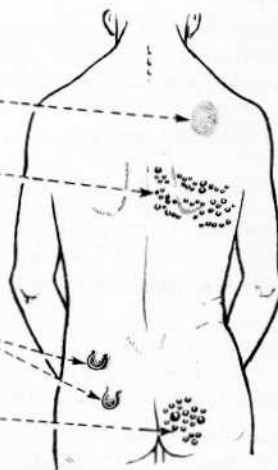
An embryological disorder in which localised overgrowth of mesodermal or ectodermal tissue produces tumours of:



Pathology (type 2): See page 385

Clinical features (type 1):

Skin manifestations:— Café au lait spots: light brown patches on the trunk with well demarcated edges. Subcutaneous neurofibromata lying along peripheral nerves and enlarging with age. Mollusca fibrosa: cutaneous fibromas – large, pedunculated and pink in colour. Plexiform neuroma: diffuse neurofibroma associated with skin and subcutaneous overgrowth and occasional underlying bony abnormality.



Skeletal manifestations:— 50% of patients exhibit scoliosis. Subperiosteal neurofibromas may give rise to bone hypertrophy or rarification with pathological fractures. Sphenoid wing dysplasia is a rare but diagnostic abnormality.

Ocular:— Lisch nodules are melanocytic hamartomas of the iris and are seen on slit-lamp examination in 90% of patients

Neoplasia:— A high incidence of leukemia, neuroblastoma, medullary thyroid carcinoma, and multiple endocrine neoplasia occurs.

Neurological manifestations:— Mental retardation and epilepsy occur in 10–15% of patients without intracranial neoplasm.

Cerebrovascular accidents as a consequence of intimal hyperplasia are not uncommon. Three patterns of neurological neoplasia are recognised:

- | | | |
|-----------------------------------|----------------------------------|---------------------------------------|
| 1. Intracranial neoplasms: | 2. Intraspinal neoplasms: | 3. Peripheral nerve neoplasms: |
| Optic nerve glioma | Meningioma | Neurofibroma – a |
| Multiple meningioma. | Neurofibroma | proportion of which |
| | Glioma. | become sarcomatous. |

Clinical features (type 2)

Skeletal manifestations are absent. Café au lait spots rare. Posterior subcapsular cataracts occur in 50% of cases. Eighth nerve tumours are *bilateral*.

Other intracranial and intraspinal neoplasms occasionally occur.

NEUROCUTANEOUS SYNDROMES

NEUROFIBROMATOSIS (continued)

Diagnosis

A family history is obtained in over 50% of patients. In type 1, the cutaneous manifestations are characteristic, though they may be extremely mild with only café au lait spots (more than 6 in an individual is diagnostic). As a rule, the more florid the cutaneous manifestations the less likely is there nervous system involvement. CT scanning, MRI and myelography may be necessary when nervous system involvement is suspected. Type 2 is diagnosed when imaging (MRI) confirms bilateral vestibular schwannomas. The recent cloning of the type 2 gene to chromosome 22 may lead to direct gene testing in persons at risk.

Treatment

Plexiform neuromas may be removed for cosmetic reasons. The management of intracranial and intraspinal tumours has already been discussed.

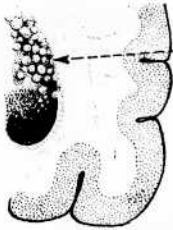
TUBEROSE SCLEROSIS

Incidence: 1:30 000.

Autosomal dominant inheritance with high sporadic mutation rate. Linkage studies suggest a locus on chromosome 9.

Characterised by cutaneous, neurologic, renal, skeletal, cardiac and pulmonary abnormalities.

Pathology



An embryological disorder.

Hard gliotic 'tubers' arise anywhere within the hemisphere but commonly around the ventricles. Projection into the ventricles produces a typical appearance like 'dripping candle wax'.

Tubers in the brain result from astrocytic overgrowth with large vacuolated cells and loss of surrounding myelin.

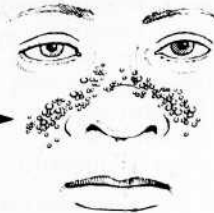
Transition may occur from gliosis to a subependymal astrocytoma.

As well as skin lesions, primitive renal tumours and cystic lung hamartomas occur.

Clinical features

Skin manifestations

The cutaneous lesions are characteristic – adenoma sebaceum, a red raised papular-like rash over the nose, cheeks and skin, appears towards the end of the 1st year, though occasionally as late as the 5th year. Depigmented areas on the trunk resembling vitiligo are common. Fibromas and café au lait spots occur occasionally.



Neurological manifestations: – Mental retardation is present in 60% of patients, though the onset and its recognition may be delayed.

Seizures occur in almost all patients, often as early as the 1st week of life. Attacks are initially focal motor and eventually become generalised. The response to anticonvulsants is variable.

Intracranial neoplasms – astrocytomas – arise from tubers usually close to the ventricles and may result in an obstructive hydrocephalus.

Neoplasia: – Renal carcinoma occurs in 50% of patients. Retinal tumours (hamartomas) and muscle tumours (rhabdomyomas) are common, the latter often involving the heart.

Diagnosis:

The presence of epilepsy and adenoma sebaceum is diagnostic.

CT scan may show subependymal areas of calcium deposition. MRI shows uncalcified subependymal tubers. Other developmental abnormalities may be evident, e.g. microgyria.

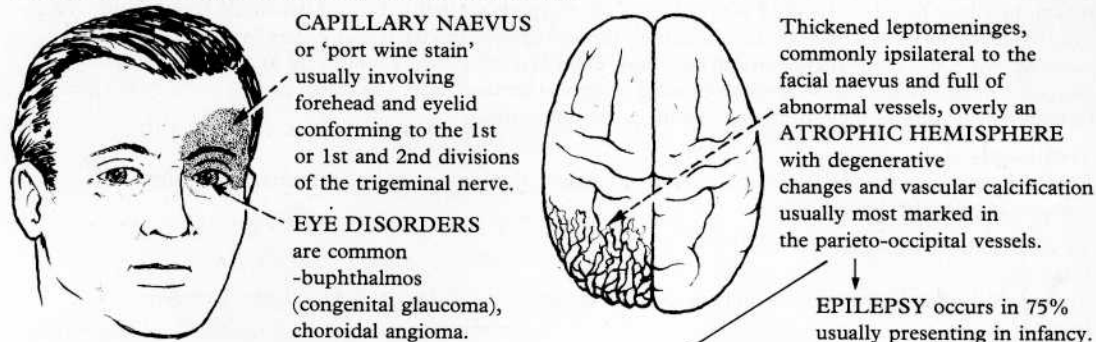
Treatment:

Anticonvulsant therapy for epilepsy. Surgical removal of symptomatic lesions.

NEUROCUTANEOUS SYNDROMES

STURGE-WEBER SYNDROME

This disorder is characterised by a facial angioma associated with a leptomeningeal venous angioma. There is no clear pattern of inheritance. Practically all cases are sporadic.



HEMIPARESIS, HOMONYMOUS HEMIANOPIA, occur in 30%.

BEHAVIOURAL DISORDER AND MENTAL RETARDATION occur in 50%.

Skull X-rays shows parallel linear calcification (tram-line sign) and CT scan, in addition, shows the associated atrophic change. Angiography demonstrates dilated deep cerebral veins with decreased cortical drainage. Arteriovenous and dural venous sinus malformations are present in 30%.

Treatment

Intractable epilepsy may require lobectomy, or even hemispherectomy. Some recommend early excision of the surface lesion, but the rarity of the condition prevents thorough treatment evaluation.

VON HIPPEL-LINDAU DISEASE

An autosomal dominant disorder in which haemangioblastomas are found in the cerebellum, spinal canal and retina, and are associated with a number of visceral pathologies:

- Renal angioma
- Renal cell carcinoma
- Pheochromocytoma
- Pancreatic adenoma/cyst
- Erythrocytosis
- Cysts and haemangiomas in liver and epididymis.

The gene responsible has been localised to chromosome 3 though gene linkage diagnosis is not yet available.

Any of the above may produce signs and symptoms.

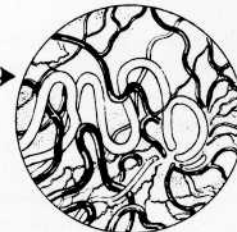Retinal haemangioblastoma is seen on fundoscopy and may produce sudden blindness. These often produce the earliest clinical manifestation of disease. Confirm with fluorescein angiography and treat with cryosurgery or photocoagulation.

Cerebellar haemangioblastoma presents with progressive ataxia. Compression of the fourth ventricle may cause hydrocephalus with a subsequent rise in intracranial pressure.

Spinal canal haemangioblastoma - intradural or intramedullary lesion presenting with signs and symptoms of cord or root compression.

Diagnosis is established from family history and cranial imaging (MRI or CT). Renal ultrasound, abdominal CT and urinary amine estimations are required to complete the evaluation.

ATAXIA TELANGIECTASIA - see page 532.



FURTHER READING

- ADAMS, H.J., and GRAHAM, D.D. (1994) *An Introduction to Neuropathology*, 2nd Edition, Churchill Livingstone, Edinburgh.
- BRADLEY, W.G., DAROFF, R.B., FENICHEL, G.M., and MARSDEN, C.D. (eds) (1996) *Neurology in Clinical Practice*. 2nd Edition, Butterworth-Heinemann, Oxford.
- BRODAL, A. (1981) *Neurological Anatomy*. 3rd Edition, Oxford University Press, Oxford.
- GRAHAM, D.I. and LANTOS, P.L. (eds) (1997) *Greenfield's Neuropathy*. 6th Edition, Edward Arnold, London.
- PATTEN, J.P. (1995) *Neurological differential diagnosis*. 2nd Edition, Springer, London.
- YOUMANS, J.R. (ed) (1995) *Neurological Surgery*. 6th Edition, Saunders, London.